



Published in final edited form as:

J Invest Dermatol. 2011 August ; 131(8): 1615–1621. doi:10.1038/jid.2011.107.

Clinical and dermoscopic stability and volatility of melanocytic nevi in a population-based cohort of children in Framingham school system

Alon Scope¹, Stephen W. Dusza¹, Ashfaq A. Marghoob¹, Jaya M. Satagopan², Casagrande Tavoloni Juliana Braga¹, Estee L. Psaty¹, Martin A. Weinstock³, Susan A. Oliveria¹, Marilyn Bishop⁴, Alan C. Geller⁵, and Allan C. Halpern¹

¹ Dermatology Service, Memorial Sloan-Kettering Cancer Center, New York, NY

² Department of Epidemiology and Biostatistics, Memorial Sloan-Kettering Cancer Center, New York, NY

³ Dermatoepidemiology Unit, VA Medical Center and Department of Dermatology, Rhode Island Hospital and Brown University, Providence, RI

⁴ School Health Services, Framingham Public Schools, Framingham, MA

⁵ Division of Public Health Practice, Harvard School of Public Health, Boston, MA

Abstract

Nevi are important risk markers of melanoma. The study aim was to describe changes in nevi of children using longitudinal data from a population-based cohort. Overview back photography and dermoscopic imaging of up to 4 index back nevi was performed at age 11 (baseline) and repeated at age 14 (follow-up). Of 443 children (39% females) imaged at baseline, 366 children (39% females) had repeated imaging three year later. At age 14, median back nevus counts increased by 2; 75% of students (n=274) had at least one new back nevus and 28% (n=103) had at least one nevus that disappeared. Of 936 index nevi imaged dermoscopically at baseline and follow-up, 69% (645 nevi) had retained the same dermoscopic classification from baseline evaluation. Only 4% (n=13) of nevi assessed as globular at baseline were classified as reticular at follow-up, and just 3% (n=3) of baseline reticular nevi were classified as globular at follow-up. Of 9 (1%) index nevi that disappeared at follow-up, none showed halo or regression at baseline. In conclusion, the relative stability of dermoscopic pattern of individual nevi in the face of the overall volatility of nevi during adolescence suggests that specific dermoscopic patterns may represent distinct biologic nevus subsets.

Users may view, print, copy, and download text and data-mine the content in such documents, for the purposes of academic research, subject always to the full Conditions of use:http://www.nature.com/authors/editorial_policies/license.html#terms

Correspondence to: Allan C. Halpern, MD MS, Dermatology Service, Memorial Sloan-Kettering Cancer Center, 160 East 53rd Street, New York, NY 10022, Phone: 212-610-0766; Fax: 212-308-0739, halperna@mskcc.org.

Conflicts of interest

The authors state no conflict of interest

Introduction

The Study of Nevi in Children (SONIC) aims to elucidate the epidemiology and biology of nevi, which in turn may inform studies related to melanoma biology and public health efforts in melanoma prevention (Oliveria *et al.*, 2009). Nevi are important risk markers of melanoma (Gandini *et al.*, 2005). Longitudinal studies of nevi have shown that childhood and adolescence are dynamic periods for nevi appearance and evolution (English *et al.*, 2006; Green *et al.*, 1995; Luther *et al.*, 1996; Siskind *et al.*, 2002; Milne *et al.*, 2008). More recently, our understanding of nevogenesis during childhood has been advanced with the use of dermoscopy, which allows a detailed classification of nevi based on global dermoscopic pattern (Hofmann-Wellenhof *et al.*, 2001). We previously reported that dermoscopically-recognizable globular and reticular nevi in children are two subsets of nevi that are distinguishable based on their anatomic distribution, size, and differing associations with pigmentation phenotype (Scope *et al.*, 2008). These subsets of nevi also correlate with specific histopathologic patterns, and taken together, suggest the existence of distinct pathways of nevogenesis (Zalaudek *et al.*, 2006; Argenziano *et al.*, 2007).

Prior studies of nevus evolution in children have been based on assessment of changes in overall nevus counts, not on tracking of changes in individual nevi. Advances in high-resolution total body photography and digital dermoscopy allow for longitudinal tracking of evolution of individual nevi (LaVigne *et al.*, 2005). In addition, dermoscopic imaging at baseline and follow-up enables assessment of more subtle changes in the pattern of nevi.

The purpose of this study was to describe changes in melanocytic nevi of pre-adolescent children using longitudinal data from a population-based cohort. We describe dermoscopic changes in individual index nevi and new nevi occurring on the backs of children over a three-year period.

Results

The baseline cohort included 443 children imaged in 5th grade (age 11). Of these children, 366 children, 39% females, had repeat imaging at 8th grade (age 14). The overall retention rate was 83%, with 100% retention of the 363 students who remained in the school system. Of the 27 students who moved out of Framingham and an additional 53 who remained local but left the school system, only 3 students who had left the school system agreed to return for repeat imaging despite multiple invitations and offered accommodations. The demographic and phenotypic characteristics of children who were imaged in 5th and 8th grade and children lost to follow-up are presented (Table 1). Children that were retained in the study were more likely to have lighter hair color, light skin that burns easily and to be Caucasian than those lost to follow-up; no differences were observed for sex, degree of freckling, ability to tan, or having prior sunburns.

New and disappearing nevi

Analysis of overview back images was performed for all participants. In general, back nevus counts increased by a median of 2 nevi. Of the 8th graders, 75% (n=274) had at least one new back nevus. Of note, 103 (28%) of students had at least one nevus that disappeared.

Nine of the disappearing nevi were index nevi for which baseline dermoscopic images were available. In total, 80% of the children had at least one nevus appear or disappear (Figure 1). The change in nevus count from 5th to 8th grade ranged from -2 (indicating that back nevus counts decreased due to disappearing nevi) to +26.

There was a correlation between total back nevus counts at baseline, appearance and disappearance of nevi. Children with higher back nevus counts at baseline were more likely to develop new nevi (correlation coefficient 0.59, $p < 0.0001$) and to have disappearing nevi (Table 2). Similarly, children with multiple new nevi were more likely to also have disappearing nevi than children without new nevi (Table 2).

Dermoscopic patterns of index nevi

Analysis of individual dermoscopic images was performed for all participants. A total of 945 index nevi were evaluated for dermoscopic assessment at baseline (5th grade, 2004); of these, 936 nevi were available for dermoscopic assessment at follow-up evaluation (8th grade, 2007), while 9 of the index nevi imaged at baseline (i.e. nevi selected for dermoscopic imaging at baseline) disappeared at follow-up. In addition, up to two new index nevi (i.e. not present at baseline), one from the upper back and one from the lower back, were imaged dermoscopically at follow-up; in total, 186 new index nevi were imaged dermoscopically at follow-up evaluation.

A total of 936 nevi were available for baseline and follow-up dermoscopic evaluations (945 nevi at baseline minus 9 nevi that disappeared by follow-up). Table 3 depicts the distribution of the dermoscopic patterns of these nevi at baseline and follow-up. At follow-up, 13% of the nevi were reticular, 32% globular, 10% complex and 45% were homogenous (i.e. without pattern). Of these nevi, 69% (645 nevi) had retained the same dermoscopic classification from baseline. There was almost no shift in dermoscopic pattern between globular and reticular nevi: only 4% ($n=13$) of nevi assessed as globular at baseline were classified as reticular at follow-up and just 3% ($n=3$) of baseline reticular nevi were classified as globular at follow-up.

In addition, we observed that 132 (28%) of the 468 nevi that were homogenous in 2004 developed a dermoscopic pattern by 2007 and that 85 (18%) of the 468 nevi that were patterned in 2004 became homogenous by 2007. In general, nevi were 65% more likely to become patterned during follow-up than lose their pattern, i.e. become homogenous (OR=1.65; 95% CI: 1.3–2.2). Compared to lesions “never” having a distinct nevus pattern (homogenous nevi), lesions “ever” having a pattern (reticular, globular or complex nevi) were 2.4 times more likely (OR=2.4; 95% CI: 1.2–4.9) to be observed in students with the darkest skin color when compared to lesions from those with the lightest skin color. In a multivariate model whereby gender, skin phototype and sunburns were independent predictors of a shift in dermoscopic classification among index nevi between homogeneous and patterned, students with fairer skin and a greater tendency to burn were more likely to have at least one nevus that shifted from homogenous to patterned ($p < 0.001$) or from patterned to homogenous over the study period ($p = 0.08$). Furthermore, a history of two or more sunburns prior to study inception was associated with the greatest dermoscopic pattern volatility (i.e., at least one homogenous nevus becoming patterned and one patterned nevus

becoming homogenous in the same student, $p < 0.05$). Changes in dermoscopic pattern were not associated with gender.

Of 936 index nevi that were available for dermoscopic analysis for both baseline and follow-up, 34 nevi (4%) significantly faded in color between the two time points, i.e. became significantly lighter in pigmentation. The baseline dermoscopic patterns of these 34 nevi were homogenous in 17 (50%), globular in 14 (41.2) and reticular in 3 (8.8%); their dermoscopic patterns at follow-up were homogenous in 21 (61%), globular in 8 (24%) and reticular in 5 (15%). In addition, 9 (1%) of the 945 index imaged at baseline (i.e. nevi selected for dermoscopic imaging at baseline) disappeared at follow-up; their dermoscopic patterns at baseline were reticular in 1 (11%), globular in 4 (44%) and homogeneous in 4 nevi (44%). None of the nevi that completely disappeared showed any evidence of halo or regression structures on baseline dermoscopic images.

A total of 186 “new” index lesions were identified in 165 participants. The most frequent dermoscopic pattern expressed by new nevi that were imaged at follow-up was globular (41%, $n=76$), followed by homogeneous (28%, $n=52$), reticular (19%, $n=35$), and complex (11%, $n=20$).

The overall size of index nevi measured by area was relatively dynamic during the study period with 735 (79%), of 936 nevi with dermoscopic images at baseline and follow-up, either increasing or decreasing in total area by at least 20% between baseline and follow-up (Table 4). The majority of nevi (682 of 936, 73%) increased in area by at least 20% during follow-up, while a minority (53 of 936, 6%) of nevi decreased in area by at least 20%. Compared to lesions that remained relatively stable in overall size between baseline and follow-up, lesions that decreased in size by greater than 20% over the course of follow-up were 60% less likely to be patterned (reticular, globular or complex) at the baseline assessment (OR=0.4; 95% CI: 0.2–0.8). Lesions that increased in size during follow-up were not more likely to be patterned at the baseline assessment compared to those that remained stable in size (OR=1.1; 95% CI: 0.8–1.5). Interestingly, of the 34 nevi that became significantly fainter during follow-up, 18 nevi (53%) actually did so while increasing in overall lesion area.

Discussion

The SONIC study is a population-based investigation of nevus epidemiology in childhood and adolescence. The student population from Framingham, MA has a racial, ethnic and socio-economic makeup comparable to the general U.S. population. We previously published the baseline (5th grade) analysis of the index back nevi demonstrating an interrelationship between dermoscopic pattern, nevus size, anatomic location, and pigment phenotypes (Scope *et al.*, 2008). We also made the observation of dermoscopic patterns in normal appearing background skin (Scope *et al.*, 2009). Herein, we report the analysis of the initial longitudinal phase of the study, at 3-year follow-up of the children.

Consistent with previous studies of children and adolescents (Dogan, 2007; Oliveria *et al.*, 2004; Green *et al.*, 1995; Sigg and Pelloni, 1989; Milne *et al.*, 2008), we found that between

5th and 8th grades, nevus counts increased. High-resolution imaging allowed for detection of changes in individual nevi. We observed that there is “turnover” or volatility of nevi in children, albeit with an overall increase in nevus counts. Children with higher back nevus counts had greater nevus volatility, being more likely to both develop new nevi and to have nevi that disappeared during follow-up. The concept of “nevus volatility” is novel; it would be interesting to examine in future studies whether higher nevus volatility (e.g., having more new nevi or disappearing nevi per follow-up period) is an independent predictor of melanoma risk, akin to the well-established risk factor of total nevus counts.

Twenty eight percent of children had at least one nevus that disappeared. The observation of disappearance of nevi in children is intriguing. Nevus involution is well documented in adults and is mostly seen with advanced age; nevus counts have been shown to peak around age 30 and thereafter decrease in numbers (MacKie *et al.*, 1985). Suggested mechanisms to nevus involution in adults include maturation, neurotization, cellular senescence and telomere shortening (Bataille *et al.*, 2007; Terushkin *et al.*, 2010). An immune-mediated process primarily involving T-lymphocytes (Zeff *et al.*, 1997) has been implicated in nevus involution via a halo phenomenon. Involution via regression can be identified with dermoscopy as regression structures, namely granularity and white scar-like areas; dermoscopic regression has been shown to correlate on histopathology with presence of melanophages and fibroplasias of the superficial dermis. Trans-epidermal elimination of melanocytic nests and apoptosis of melanocytes are other speculated mechanisms of nevus involution (Kantor and Wheeland, 1987; lee *et al.*, 2000). We did not observe a halo phenomenon or regression structures at baseline in nevi that subsequently disappeared. We did, however, see many nevi fade without associated signs of halos or regression structures and speculate that some of these fading nevi may eventually disappear. The biologic mechanism of fading nevi is currently not known. It is interesting to note that some nevi faded while growing, possibly suggesting a mechanism of senescence. It has been shown that growth driven by BRAF mutation can simultaneously induce senescence in nevi (Michaloglou *et al.*, 2005).

In the baseline dermoscopic analysis, we observed that two types of nevi (globular vs. reticular-patterned nevi) differ in anatomic distributions and in size (Scope *et al.*, 2008). Other studies of nevi showed a difference in distribution of globular and reticular nevi between the trunk and extremities (Seidenari *et al.*, 2006; Changchien *et al.*, 2007). We, therefore, hypothesized that these subsets of nevi are biologically distinct. The findings of the present study support this notion. Most nevi retained the same dermoscopic classification from baseline to follow-up evaluation, while new index nevi demonstrated a diversity of dermoscopic patterns. Cross-over of pattern between globular and reticular nevi was seen in less than 2% of nevi.

Our study has strengths. First, we retained for follow-up imaging all students who consented for 5th grade assessment and remained in the school system at 8th grade. Second, the unique observations of nevus volatility and relative dermoscopic pattern stability were made because of the novel use of longitudinal tracking of individual nevi with high-resolution digital photography and because of the focus on early adolescence, a period with rapid

changes in nevus counts. Finally, the fact that these observations were made in a population-based cohort is more likely to make them generalizable.

Our study has limitations. First, imaging of nevi was limited to the back, because overview imaging of curved surfaces, such as extremities, is technologically challenging. We are currently testing three-dimensional imaging of curved surfaces. Second, sample size was limited. In addition, while the SONIC cohort encompasses a full spectrum of pigment phenotypes from fair to dark, students lost to follow-up were more likely to have darker skin phenotype and to be non-Caucasian in ethnicity (Table 1); this limits the analysis of the impact of skin phenotype and ethnicity on nevus evolution. We are currently expanding the cohort, with particular attention to increasing the number of students across the phenotypic and ethnic spectrum. This will allow for a more comprehensive analysis of predictors of nevus phenotype. In addition, although we were not able to obtain more comprehensive demographic and phenotypic characteristics of the source population, the distribution of race/ethnicity among the enrolled student cohort (73% White, 18% Hispanic, 4% African-American, 5% Asian) is comparable to that of the Framingham, MA School District as a whole (70% White, 21% Hispanic, 4% African-American, 5% Asian). Third, the implications of our findings for melanoma risk are not apparent and further study is warranted. We anticipate that more students with a high-risk phenotype (e.g. with atypical nevi) will be seen with aging of the cohort. Fourth, dermoscopic imaging of index nevi samples the student's nevi, and may not be representative of the student's signature nevus phenotype (Suh *et al.*, 2009). With imaging of more nevi per student in the future, we hope to mitigate this potential sampling bias. Fifth, classification of dermoscopic patterns is probably dependent on the level of nevus pigmentation. Classification of nevus pattern (e.g., as homogenous or patterned) when dermoscopic structures are very faint depends on observers' threshold. Thus, dermoscopy is likely to be an imperfect surrogate of tissue pathology, particularly for less pigmented nevi. We plan to perform dermoscopic-histopathological correlation studies to better understand the limitations of using dermoscopic pattern as proxy for tissue morphology. In addition, we analyzed change in nevus phenotype and dermoscopic pattern using only two time points over three years; it is likely that as more time points and longer follow-up are used to assess what has already proven to be a very dynamic process, additional insights may be gained. For example, dermoscopic pattern may prove to be less consistent over longer follow-up periods. To this end, the SONIC study will continue to observe this cohort to age 18. Finally, we did not address relationship of nevus counts and dermoscopic patterns with sun-exposure. Over the 3 years of follow-up, we have obtained annual questionnaires of sun-exposure from children and parents. The effects of these factors on nevi will be explored in a separate paper.

In conclusion, we found that early adolescence is a period of nevus volatility. Appearance of new nevi and disappearance or fading of existing nevi are common events. Despite this volatility, the majority of nevi retain their baseline dermoscopic pattern. In particular, nevi with reticular and nevi with globular dermoscopic patterns appeared to be distinct subsets of nevi that were exceedingly unlikely to cross-over in dermoscopic pattern. Finally, none of the nevi that disappeared, grew smaller, or faded showed dermoscopic evidence of halo or regression. We hypothesize that non-immunological mechanisms of nevus involution exists

in early adolescence which are related to loss of pigmentation, cellular senescence or trans-epidermal elimination.

Materials and methods

The study was approved by the Institutional Review Board at Boston University. The study adhered to the guidelines of the Helsinki Declaration

Study population

Study population included students from all 10 schools in Framingham, Massachusetts school system who were enrolled in 5th grade in Fall 2004. The school system offers a racial/ethnic mix similar to the general U.S. population. A list of all 691 5th-graders (age 11 years) was obtained from the school system. Mailings were sent to all families, requesting participation, and including a description of the study, consent and assent form (for student). Two weeks after the initial mailing, follow-up telephone calls were conducted. Of 691 Framingham families with a 5th grader, 443 (64%) provided written consent for the study; we were also able to reach all but 10% of the 248 non-participants. In addition, skin examination and digital photography of participating students (described in detail below) were carried out in 5th grade (baseline) and 8th grade (follow-up) during the School's annual scoliosis examinations (mandatory in Massachusetts); skin type and demographics were assessed for all 5th grade students receiving the scoliosis examination, including non-participants. Participating students (n=443) were more likely to be white (70% vs. 58%, $p<0.0014$), fair or very fair (63% vs. 38%, $p=0.0004$), and male (62% vs. 48%, $p<0.0001$) than non-participants (n=248). Additional details about the approach used in planning and implementing this study and reasons for nonparticipation have been described (Oliveria *et al.*, 2009; Geller AC *et al.*, 2007).

Data collection—At both 5th and 8th grades, students underwent a brief visual examination by the study nurse to assess hair, eye and skin color and freckling, and standardized high-resolution overview digital photography of the back was performed. Photography at baseline also included close-up clinical and dermoscopic images of up to 4 index back nevi (the largest nevus on upper and lower back and one randomly-selected nevus from upper and lower back). Definition of upper and lower back and method of selection of the random nevus have been previously described (Scope *et al.*, 2008). Close-up clinical and dermoscopic photography of index nevi was repeated at 8th grade and, in addition, dermoscopic imaging of up to 2 new nevi (i.e. that were not present at 5th grade) was obtained, one from the upper and one from the lower back. Digital photography was performed with Phase One P25 Camera Back, Hasselblad 503w Camera System, 1 kW Studio Flash System (Canfield Scientific, Inc., Fairfield, NJ, U.S.A.). Dermoscopic images were obtained using a Fuji S2 SLR digital camera and 60 mm Macro Nikkor lens with Epi-Lume dermoscopy attachment (Canfield Scientific). Color-coded adhesive dot were placed inferior to index nevi. These dots permitted consistent tracking, at follow-up photography, of the locations of the four index nevi that had been selected in 5th grade by real-time reference to the original tagged overview photograph. These dots also served as fiducial markers for spectral and spatial calibration of overview images on review and for data assessment of

nevus surface contour (e.g., flat or raised). Images were archived in DermaGraphix, a database housed on a secured server at resolution of 3 million pixel (Canfield Scientific).

Children completed self-administered questionnaires. The survey included questions on demographics, phenotype (skin type, eye and hair color), sun sensitivity, sun exposure, sun protection practices including use of hats and sunscreen, limiting time in the sun, seeking shade, and frequency of sunburns. A parent survey was completed by one of the child's parents. Parents were also asked questions regarding their child's sun protection practices and exposure and family history of skin cancer. By collecting data from both parent and child, we were able to assess concordance and examine both sets of responses to identify the best source for each variable of interest. In all, 432 student surveys and 424 parent surveys were obtained.

Image analysis—Image analysis was performed on high-resolution monitors. Back nevus counts were performed with images projected on two monitors, side-by-side. Reference lines were overlaid on back images to create quadrants for evaluation. All images were viewed at 100% magnification. Total back nevus counts were assessed at both time points. Individual nevus size was assessed on the monitor using standardized diameter scale. In addition, side-by-side comparisons of images were made to track longitudinal changes in nevi, thereby identifying new and disappearing nevi, and noting stable nevi and nevi that increased or decreased in size during follow-up. We used anatomic landmarks (e.g., angle of neck and shoulders, scapulae) to triangulate and compare the location of individual nevi on both images.

Baseline and follow-up dermoscopic images of individual index nevi were also magnified 100% on the monitors and viewed side-by-side. Dermoscopic images were jointly reviewed by 2 dermatologists who analyzed each image and compared images for global dermoscopic pattern, color and dermoscopic structures. Dermoscopic images of new nevi at 8th grade were assessed for the same parameters, without side-by-side comparison. We assigned nevi into 3 patterned categories based on global dermoscopic pattern – reticular, globular, complex (reticular-globular), or if they lacked these patterns, into a 4th category of homogenous nevi. Patterned nevi were classified as follows: (i) reticular –lesion showed pigment network (diffuse or patchy); no globules were seen; (ii) globular –lesion showed globules and no network was seen. Of note, globules were considered as present if three or more globules were observed; (iii) complex pattern – both network and globules were seen, with or without structureless areas. Of note, nevi with reticular pattern and peripheral rim of globules, known to be a pattern of growing reticular nevi, were not coded as complex but as reticular. Homogeneous (structureless) nevi were defined as lesions in which neither network nor globules were seen.

Nevus size (total lesion area) was calculated from dermoscopic images for each index nevus using a measurement tool incorporated into the image archiving software (Mirror, Canfield Scientific, Inc). Lesion borders were visually identified. A random sample of 50 study lesions was selected, and lesion measurements were completed by a second study dermatologist. Concordance for lesion measurements between the two reviewers was high ($\rho=0.96$). Lesion area was further classified as percent change compared to baseline

assessment. A change in nevus area greater than $\pm 20\%$ was considered to be clinically apparent, while setting a threshold that will likely minimize misclassification due to inherent measurement inaccuracy. Therefore, change in lesion size was categorized into 3 groups: 1) lesions that decreased in area by $>20\%$ during follow-up, 2) lesions that remained within $\pm 20\%$ of baseline measurement, and 3) lesions that grew by at least 20% .

Statistical analysis—Descriptive statistics were used to characterize the study population. Descriptive frequencies were calculated to assess student distribution and lesion characteristics. T-tests and χ^2 statistics were used to compare characteristics of students lost to follow-up with those who were retained. Lesions were classified by their global dermoscopic pattern. In addition, lesions were also broadly classified as ever having a distinct dermoscopic pattern (reticular, globular or complex) or never having a pattern (homogeneous). Univariate comparisons of ever having a dermoscopic pattern and baseline phenotypic characteristics of participants were completed. McNemar's χ^2 were used to assess paired comparisons between baseline and follow-up assessments. Since lesions were nested within students, mixed effect regression models were used. In these models, a variable for the student was entered as a random effect. The odds ratios estimated in the dermoscopic pattern analyses were obtained from these random effects models. In these models the dependent variable was presence or absence of a discernable dermoscopic pattern at baseline or follow-up evaluations. The main independent variable was skin color categorized on three levels, very fair, fair to light olive, and light brown to dark brown, with very fair students acting as referent category. Student sex was included in all regression models as a potential confounding factor. All analyses were carried out using Stata v.10.1 software (Stata Corp.).

Acknowledgments

The manuscript was prepared in New York, NY, USA. The research was funded through NIH/NIAMS AR049342-02: "The Framingham School Nevus Study". The authors thank Dennis DaSilva and Jed Smith from Canfield Scientific.

Abbreviations used

SONIC Study of Nevi in Children

References

- Argenziano G, Zalaudek I, Ferrara G, et al. Proposal of a new classification system for melanocytic naevi. *Br J Dermatol.* 2007; 157:217–27. [PubMed: 17553053]
- Bataille V, Kato BS, Falchi M, et al. Nevus size and number are associated with telomere length and represent potential markers of a decreased senescence in vivo. *Cancer Epidemiol Biomarkers Prev.* 2007; 16:1499–502. [PubMed: 17627017]
- Changchien L, Dusza SW, Agero AL, et al. Age- and site-specific variation in the dermoscopic patterns of congenital melanocytic nevi: an aid to accurate classification and assessment of melanocytic nevi. *Arch Dermatol.* 2007; 143:1007–14. [PubMed: 17709659]
- Dogan G. Melanocytic nevi in 2783 children and adolescents in Turkey. *Pediatr Dermatol.* 2007; 24:489–94. [PubMed: 17958793]

- English DR, Milne E, Simpson JA. Ultraviolet radiation at places of residence and the development of melanocytic nevi in children (Australia). *Cancer Causes Control*. 2006; 17:103–7. [PubMed: 16411059]
- Gandini S, Sera F, Cattaruzza MS, et al. Meta-analysis of risk factors for cutaneous melanoma. I. Common and atypical naevi. *Eur J Cancer*. 2005; 41:28–44. [PubMed: 15617989]
- Geller AC, Oliveria SA, Bishop M, et al. Study of health outcomes in school children: key challenges and lessons learned from the Framingham Schools' Natural History of Nevi Study. *J Sch Health*. 2007; 77:312–8. [PubMed: 17600588]
- Green A, Siskind V, Green L. The incidence of melanocytic naevi in adolescent children in Queensland, Australia. *Melanoma Res*. 1995; 5:155–60. [PubMed: 7640516]
- Hofmann-Wellenhof R, Blum A, Wolf IH, et al. Dermoscopic classification of atypical melanocytic nevi (Clark nevi). *Arch Dermatol*. 2001; 137:1575–80. [PubMed: 11735707]
- Kantor GR, Wheeland RG. Transepidermal elimination of nevus cells. A possible mechanism of nevus involution. *Arch Dermatol*. 1987; 123:1371–4. [PubMed: 3662570]
- LaVigne EA, Oliveria SA, Dusza SW, et al. Clinical and dermoscopic changes in common melanocytic nevi in school children: the Framingham school nevus study. *Dermatology*. 2005; 211:234–9. [PubMed: 16205068]
- Lee HJ, Ha SJ, Lee SJ, et al. Melanocytic nevus with pregnancy-related changes in size accompanied by apoptosis of nevus cells: a case report. *J Am Acad Dermatol*. 2000; 42:936–8. [PubMed: 10767710]
- Luther H, Altmeyer P, Garbe C, et al. Increase of melanocytic nevi counts in children during 5 years of follow-up and analysis of associated factors. *Arch Dermatol*. 1996; 132:1473–8. [PubMed: 8961877]
- MacKie RM, English J, Aitchison TC, et al. The number and distribution of benign pigmented moles (melanocytic naevi) in a healthy British population. *Br J Dermatol*. 1985; 113:167–74. [PubMed: 4027184]
- Michaloglou C, Vredeveld LC, Soengas MS, et al. BRAF600-associated senescence-like cell cycle arrest of human naevi. *Nature*. 2005; 436:720–4. [PubMed: 16079850]
- Milne E, Simpson JA, English DR. Appearance of melanocytic nevi on the backs of young Australian children: a 7-year longitudinal study. *Melanoma Res*. 2008; 18:22–8. [PubMed: 18227704]
- Oliveria SA, Satagopan JM, Geller AC, et al. Study of Nevi in Children (SONIC): baseline findings and predictors of nevus count. *Am J Epidemiol*. 2009; 169:41–53. [PubMed: 19001133]
- Oliveria SA, Geller AC, Dusza SW, et al. The Framingham school nevus study: a pilot study. *Arch Dermatol*. 2004; 140:545–51. [PubMed: 15148098]
- Scope A, Marghoob AA, Dusza SW, et al. Dermoscopic patterns of naevi in fifth grade children of the Framingham school system. *Br J Dermatol*. 2008; 158:1041–9. [PubMed: 18363751]
- Scope A, Marghoob AA, Chen CS, et al. Dermoscopic patterns and subclinical melanocytic nests can be observed in background skin. *Br J Dermatol*. 2009; 160:1318–21. [PubMed: 19416274]
- Seidenari S, Pellacani G, Martella A, et al. Instrument-, age- and site dependent variations of dermoscopic patterns of congenital melanocytic naevi: a multicentre study. *Br J Dermatol*. 2006; 155:56–61. [PubMed: 16792752]
- Sigg C, Pelloni F. Frequency of acquired melanocytic nevi and their relationship to skin complexion in 939 schoolchildren. *Dermatologica*. 1989; 179:123–8. [PubMed: 2591618]
- Siskind V, Darlington S, Green L, et al. Evolution of melanocytic nevi on the faces and necks of adolescents: a 4 y longitudinal study. *J Invest Dermatol*. 2002; 118:500–4. [PubMed: 11874490]
- Suh KY, Bologna JL. Signature nevi. *J Am Acad Dermatol*. 2009; 60:508–14. [PubMed: 19231649]
- Terushkin V, Scope A, Halpern AC, et al. Pathways to involution of nevi: insights from dermoscopic follow-up. *Arch Dermatol*. 2010; 146:459–60. [PubMed: 20404249]
- Zalaudek I, Hofmann-Wellenhof R, Soyer HP, et al. Naevogenesis: new thoughts based on dermoscopy. *Br J Dermatol*. 2006; 154:793–4. [PubMed: 16536840]
- Zeff RA, Freitag A, Grin CM, et al. The immune response in halo nevi. *J Am Acad Dermatol*. 1997; 37:620–4. [PubMed: 9344203]

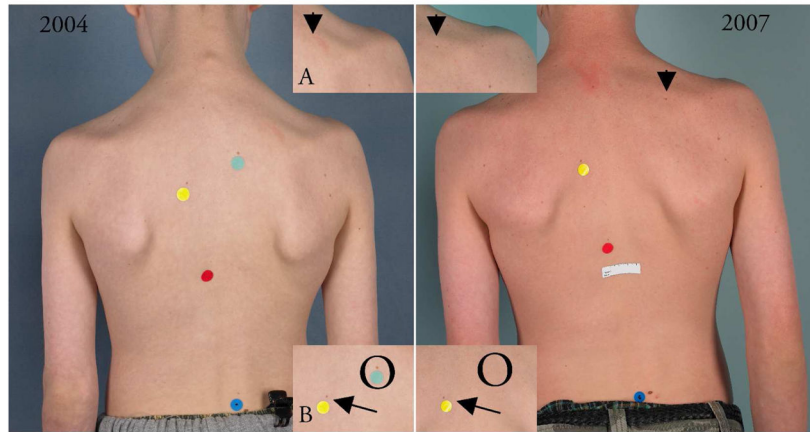


Figure 1.

High-resolution overview photography allows for comparison of total back nevus counts from baseline (2004) and follow-up (2007). Side by side assessment of images allows for evaluation of new nevi (Insert A, arrowhead; the new nevus is also indicated by an arrowhead on 2007 overview), disappearance of nevi (Insert B, circle; the disappearing nevus is also indicated on 2004 overview with a light blue marker) and the stability of lesions (Insert B, arrows; stable nevi also indicated on both overview images by the yellow marker).

Table 1Characteristics of students imaged in 5th and 8th grade (n=366) and students lost to follow-up (n=77)

Characteristic	Students imaged in 5 th and 8 th grade	students lost to follow-up	
	n (%)	n (%)	
Sex			
Female	141 (39)	32 (42)	P=0.62
Male	225 (61)	45 (58)	
Race/Ethnicity			
Native American	1 (0)	0 (0)	P=0.01
Asian	17 (5)	5 (7)	
African American	14 (4)	5 (7)	
Hispanic	65 (18)	26 (34)	
White	269 (73)	41 (53)	
Skin Color			
Very fair/Fair	245 (67)	33 (43)	P<0.001
Light olive	30 (8)	4 (5)	
Dark olive, brown, black	91 (25)	40 (52)	
Hair Color			
Dark brown	212 (58)	62 (81)	P=0.005
Light brown	84 (23)	10 (13)	
Blonde	60 (16)	3 (4)	
Red	10 (3)	2 (3)	
Skin burns easily			
No	216 (59)	43 (56)	P=0.03
Yes	135 (37)	25 (32)	
Tanning ability			
Deep tan	108 (30)	24 (31)	P=0.80
Moderate tan	130 (36)	27 (35)	
Mild/Occasional tan	60 (16)	11 (14)	
Not able to tan	18 (5)	2 (3)	
Do not know	26 (7)	5 (7)	
Back Freckles			
Absent	302 (83)	61 (79)	P=0.50
Present	64 (17)	16 (21)	
Nevus count (geometric mean, SD)	5.4 (2.8)	6.3 (2.5)	P=0.17
Sunburns in summer prior to study enrollment (2004)			
None	230 (63)	56 (73)	P=0.12
1	98 (27)	12 (16)	
2 or more	38 (10)	9 (12)	

Association between at least one disappearing nevus and total back nevi at baseline and number of new nevi at the follow-up assessment

Table 2

	No Disappearing Nevus n (%)	1 Disappearing Nevus n (%)	Total	P-Value ¹
Total Back Nevi at Baseline				
0-4	132 (85)	24 (15)	156 (100)	
5-9	67 (71)	27 (29)	94 (100)	
10-14	31 (57)	23 (43)	54 (100)	
15-19	16 (62)	10 (38)	26 (100)	
20+	22 (61)	14 (39)	36 (100)	<0.001
Number of New Nevi at Follow-up Assessment				
0	78 (89)	10 (11)	88 (100)	
1	44 (76)	14 (24)	58 (100)	
2	39 (72)	15 (28)	54 (100)	
3	30 (73)	11 (27)	41 (100)	
4+	77 (62)	48 (38)	125 (100)	0.009 ²
Total	268 (73)	98 (27)	366 (100)	

¹ P-values for trend

² Association adjusted for total nevus count at baseline

Table 3
 Dermoscopic patterns for nevi (n=936) that were evaluated at baseline (2004) and were available for dermoscopic assessment at follow-up (2007)

		2007				Total
		Reticular	Globular	Homogeneous	Complex	
2004	Reticular	63	3	12	24	102
	Row %	62	3	12	23	100
	Col %	50	1	3	27	11
	Globular	13	215	72	22	322
	Row %	4	67	22	7	100
	Col %	10	72	17	24	34
	Homogeneous	44	75	336	13	468
	Row %	9	16	71.8	3	100
	Col %	35	25	79.8	14	50
	Complex	6	6	1	31	44
Row %	14	14	2.3	70	100	
Col %	5	2	0.2	34	5	
Total	126	299	421	90	936	
Row %	13	32	45	10	100	
Col %	100	100	100	100	100	

Change in lesion area between baseline and 3-year follow-up by dermoscopic pattern at baseline

Table 4

Change in lesion area	Dermoscopic Pattern at baseline					Total
	Reticular	Globular	Homogeneous	Complex		
Decreased by at least 20%	1	12	38	2	53	
Row %	1.9	22.6	71.7	3.8	100	
Col %	1.0	3.7	8.1	4.6	5.6	
Remained within +/- 20%	20	71	101	9	201	
Row %	10.0	35.3	50.3	4.5	100	
Col %	19.6	22.1	21.6	20.4	21.5	
Increased by at least 20%	81	239	329	33	682	
Row %	11.9	35.0	48.2	4.8	100	
Col %	79.4	74.2	70.3	75.0	72.9	
Total	102	322	468	44	936	
Row %	10.9	34.4	50.0	4.7	100	
Col %	100	100	100	100	100	