

Received: 2019.12.26

Accepted: 2020.01.29

Available online: 2020.02.10

Published: 2020.03.24

A Case of Strangulation Ileus Due to a Low-Grade Appendiceal Mucinous Neoplasm

Authors' Contribution:

Study Design A
Data Collection B
Statistical Analysis C
Data Interpretation D
Manuscript Preparation E
Literature Search F
Funds Collection G

ABCDEF 1 **Ryohei Takei**
B 1 **Keiichiro Kanamoto**
B 1 **Yuta Tamaru**
B 1 **Koki Nojima**
B 1 **Kazuyoshi Mitta**
BC 1 **Ryosuke Zaimoku**
D 1 **Ayako Kanamoto**
D 1 **Hirohumi Terakawa**
D 1 **Yuki Higashi**
DF 1 **Yuji Tsukioka**
CD 2 **Kiyoshi Takagawa**
DE 1 **Masato Kiriya**

1 Department of Surgery, Kurobe City Hospital, Kurobe, Toyama, Japan

2 Department of Pathology, Kurobe City Hospital, Kurobe, Toyama, Japan

Corresponding Author: Ryohei Takei, e-mail: ryohei_20@hotmail.com

Conflict of interest: None declared

Patient: Male, 92-year-old
Final Diagnosis: Strangulation
Symptoms: Abdominal distension • abdominal pain
Medication: —
Clinical Procedure: —
Specialty: Surgery

Objective: Rare disease

Background: Strangulation ileus is caused by external obstruction to the small bowel, which results in ischemia and loss of bowel peristalsis. Low-grade appendiceal mucinous neoplasm (LAMN) is a low-grade adenocarcinoma that arises in the appendix. LAMN is usually asymptomatic but can present with appendiceal rupture and pseudo-myxoma peritonei (PMP). This report is of a rare presentation of LAMN with strangulation ileus in a 92-year-old man.

Case Report: A 92-year-old man was admitted to the emergency room with sudden onset of lower abdominal pain and abdominal distension. Laboratory investigations showed a leukocytosis with a white blood cell (WBC) count of $14.6 \times 10^3/\mu\text{L}$ with 85.5% neutrophils, blood urea nitrogen (BUN) of 26.6 mg/dL, and serum creatinine of 2.6 mg/dL, consistent with acute renal failure. Arterial blood gas analysis showed lactic acidosis (pH of 7.11) with a base excess of -20.8 mmol/L and lactate of 13.7 mmol/L. Abdominal computed tomography (CT) showed ascites and a dilated obstructed closed loop of the distal ileum associated with an external mass (3.9×2.8 cm). An initial diagnosis was of strangulation ileus due to Meckel's diverticulum. Emergency ileocecal resection was performed. Histopathology showed a low-grade mucinous tumor arising from the mucosa of the appendix, consistent with LAMN. At a 13-month follow-up, the patient was well with no tumor recurrence.

Conclusions: This report is of a rare case of LAMN that presented as a surgical emergency with strangulation ileus.

MeSH Keywords: Appendiceal Neoplasms • Case Reports • Ileus

Full-text PDF: <https://www.amjcaserep.com/abstract/index/idArt/922405>




1020



—



3



19



Background

Low-grade appendiceal mucinous neoplasm (LAMN) is a rare low-grade primary mucinous adenocarcinoma of the appendix as low-grade adenocarcinoma of the appendix according to current classification by the 2010 World Health Organisation (WHO) (2010) [1], the 2016 Peritoneal Surface Oncology Group International (PSOGI) modified Delphi classification [2]. Although LAMN is a low grade, slow-growing tumor, it has the potential for local spread to the peritoneum and rupture of the wall of the appendix followed by pseudomyxoma peritonei (PMP) [3].

Early-stage LAMN is usually asymptomatic and is diagnosed incidentally on laparotomy, surgery, or abdominal imaging, as the presentation may mimic appendicitis [4]. When tumors are large, LAMN may be palpated as a right lower abdominal mass, or with abdominal pain due to intestinal obstruction or intussusceptions, or with intestinal bleeding, or PMP. Complete surgical resection is the most appropriate treatment for LAMN. A rare case is presented of strangulation ileus due to LAMN that presented as a surgical emergency in a 92-year-old man.

Case Report

A 92-year-old man was admitted to the emergency room with sudden onset of lower abdominal pain and abdominal distension. He had no previous history of abdominal surgery. On physical examination, his abdomen was distended, and he had generalized tenderness with mild guarding on palpation. Laboratory investigations showed mild anemia with a hemoglobin of 12.6 g/dL, a leukocytosis with a white blood cell (WBC) count of $14.6 \times 10^3/\mu\text{L}$ with 85.5% neutrophils, blood urea nitrogen (BUN) of 26.6 mg/dL, a raised serum potassium of 5.1 mmol/L, and serum creatinine of 2.6 mg/dL, consistent with acute renal failure due to dehydration. Arterial blood gas analysis showed lactic acidosis (pH of 7.11) with a base excess of -20.8 mmol/L and lactate of 13.7 mmol/L.

Abdominal computed tomography (CT) showed ascites and a dilated obstructed closed loop of the distal ileum associated with an external mass (3.9×2.8 cm) (Figure 1). An initial diagnosis was of strangulation ileus due to Meckel's diverticulum, and emergency surgery was performed. During laparotomy, 1.5 L of hemorrhagic ascites was drained. The distal ileum was dilated with ischemic change. The mesentery of the ischemic ileum was obstructed externally by the appendiceal mass in the space between the appendix and the mesentery of the terminal ileum (Figure 2).

Ileocecal resection with lymph node dissection was performed, based on the possibility of an appendiceal mucinous

adenocarcinoma. The surgical resection specimen showed a 5.0×2.5 cm cystic tumor with mucus in the lumen (Figure 3A). Histopathology showed a columnar cell mucinous tumor without invasion or desmoplasia and with low-grade dysplasia of the neoplastic glandular cells (Figure 3B). There was no metastatic tumor in 17 resected regional lymph nodes. These findings supported a diagnosis of low-grade appendiceal mucinous neoplasm (LAMN). The diagnosis was made of strangulation ileus due to LAMN. The patient made a good postoperative recovery and was discharged home. Postoperative follow-up at 13 months showed no increase in serum tumor markers, including carcinoembryonic antigen (CEA) and carbohydrate antigen 19-9 (CA19-9), and no evidence of tumor recurrence.

Discussion

Low-grade appendiceal mucinous neoplasm (LAMN) is a rare tumor that is found in 0.2–0.3% of appendectomy specimens [7]. AMN was first described in 1940 by McDonald and Woodruff for a range of benign and malignant neoplasms arising in the appendix [8]. Subsequently, there have been several classification schemes [9–11], including the 2010 World Health Organisation (WHO) classification [1], and the 2016 Peritoneal Surface Oncology Group International (PSOGI) modified Delphi classification [2]. LAMN is characterized by low-grade dysplasia of the glandular epithelium, with or without mucin production. The histology of LAMN shows a villous tumor with expansive growth that may be associated with submucosal fibrosis involving the muscularis propria [1,2]. An important complication of LAMN is rupture through the wall of the appendix with the release of mucin into the peritoneum, or pseudomyxoma peritonei (PMP) [12]. In the early stage of the growth of LAMN, most patients have no symptoms, and the tumor is diagnosed incidentally during abdominal imaging or laparotomy for presumed acute appendicitis [4]. In larger tumors, patients may present with right lower quadrant abdominal pain, a palpable abdominal mass, weight loss, and change in bowel habit. Some patients also experience intestinal obstruction, intussusception, PMP, appendicitis, and localized appendiceal rupture due to LAMN [13].

Abdominal imaging has an important role in the diagnosis of LAMN and patient follow-up. Abdominal ultrasound may identify a cystic mass with mucinous content in the right lower quadrant of the abdomen [14]. Abdominal computed tomography (CT) may show a well-demarcated cystic mass in the appendix with low attenuation of the contents [15]. The cyst wall is usually smooth, with varying degrees of thickness, and calcification is present in up to 50% of cases [15]. Magnetic resonance imaging (MRI) of the abdomen may show hyperintense intraluminal fluid of the appendiceal cystic mass on T2-weighted imaging [16].

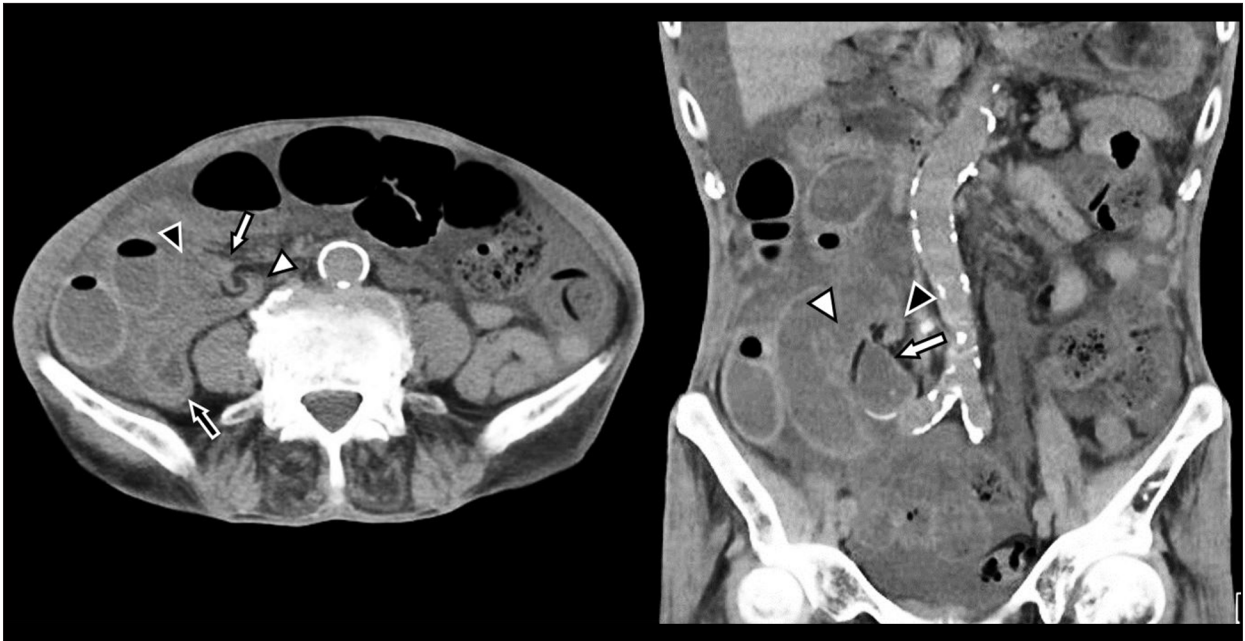


Figure 1. Computed tomography (CT) imaging in a case of low-grade appendiceal mucinous neoplasm (LAMN) presenting with strangulation ileus in a 92-year-old man. Transverse and sagittal abdominal computed tomography (CT) scans show dilatation of an obstructed small bowel loop and cord-like and dilated structures of the cecum (white arrow) and strangulation of the ileum (black arrow).

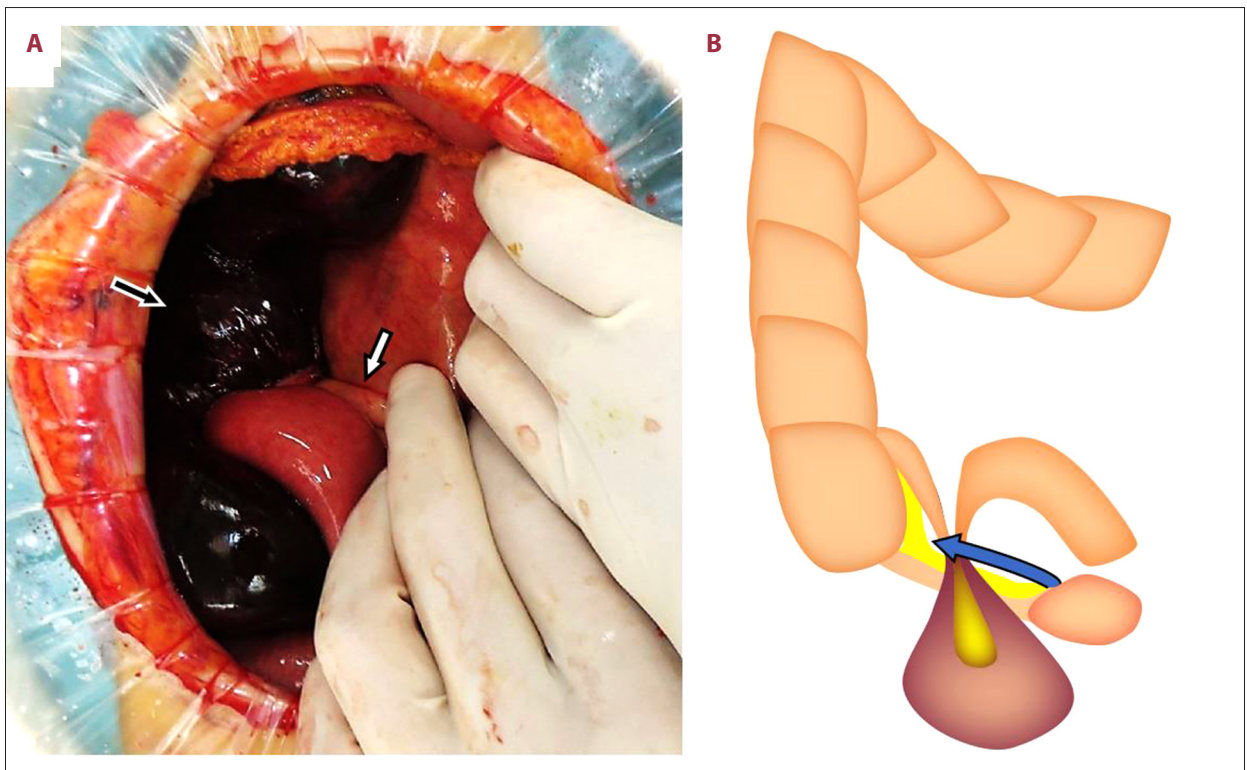


Figure 2. Diagrams of the surgical management of low-grade appendiceal mucinous neoplasm (LAMN) presenting with strangulation ileus in a 92-year-old man. (A) A diagram of the surgical resection shows the mesentery of the distal ileum that is obstructed by the appendix (white arrow). The ileum is dilated and shows ischemic change (black arrow). (B) A diagram of the appendix and space between the distal ileum and the mesentery of the appendix.

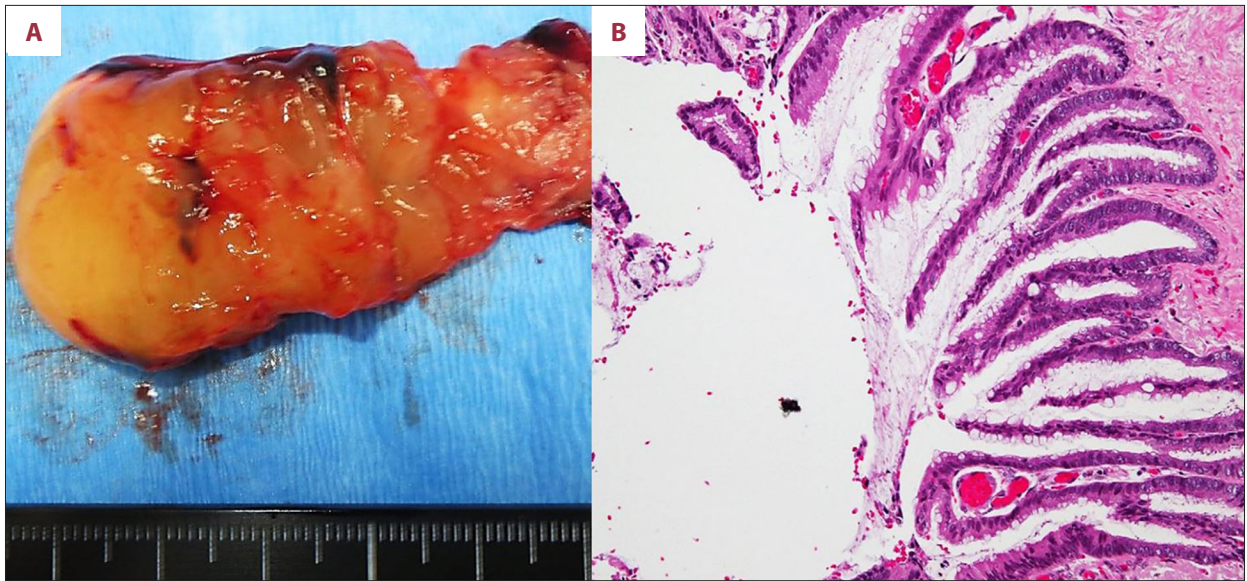


Figure 3. The surgical resection specimen and the histopathology of the low-grade appendiceal mucinous neoplasm (LAMN) presenting with strangulation ileus in a 92-year-old man. **(A)** The gross surgical resection specimen shows a cystic appendiceal cystic mass filled with mucinous material. **(B)** The low power photomicrograph of the histopathology of the resected appendix shows a proliferation of mucinous columnar epithelium. The tumor cells do not invade the small bowel wall, and there is no desmoplastic response. The neoplastic epithelium showed low-grade dysplasia, consistent with a diagnosis of a low-grade appendiceal mucinous neoplasm (LAMN). Hematoxylin and eosin (H&E).

Intestinal obstruction is most commonly due to adhesions following surgery, or due to neoplasms, hernia, inflammatory bowel disease, intussusception, and volvulus. Intestinal strangulation caused by LAMN is extremely rare, with only a few cases reported in the literature [17,18]. Emergency surgery is the standard treatment for strangulated ileus due to LAMN, and complete resection with negative resection margins should be performed without spilling the contents into the peritoneum, which can result in PMP [19]. However, because LAMN is rare and may not be diagnosed preoperatively, and patients may present as a surgical emergency, surgical management remains controversial. In the case presented in this report, ileocecal resection with regional lymph node dissection was performed due to the possibility of an appendiceal mucinous adenocarcinoma, the patient's age, and the requirement to resect the ischemic terminal ileum.

Conclusions

This report is of a rare case of LAMN that presented as a surgical emergency with strangulation ileus in a 92-year-old man. This case has shown that although LAMN can be completely excised by surgical resection, its symptomatic presentation may be as a surgical emergency. In this case, accurate emergency pre-operative and intra-operative evaluation was required during laparotomy with consideration of the patient's age and their underlying medical condition. Because LAMN is a rare tumor, consensus management guidelines remain to be established.

Conflict of interest

None.

References:

1. Carr NJ, Sobin LH: Tumours of the appendix. In: Bosman FT, Carneiro F, Hruban RH, Theise ND (eds.), WHO classification of tumours of the digestive system. 4th ed. Lyon: IARC Press, 2010; 122–25
2. Carr NJ, Cecil TD, Mohamed F et al: A consensus for classification and pathologic reporting of pseudomyxoma peritonei and associated appendiceal neoplasia: The results of the Peritoneal Surface Oncology Group International (PSOGI) Modified Delphi Process. *Am J Surg Pathol*, 2016; 40: 14–26
3. Umetsu SE, Shafizadeh N, Kakar S: Grading and staging mucinous neoplasms of the appendix: A case series and review of the literature. *Hum Pathol*, 2017; 69: 81–89
4. Sieren LM, Collins JN, Weireter LJ et al: The incidence of benign and malignant neoplasia presenting as acute appendicitis. *Am Surg*, 2010; 76: 808–11
5. Assenza M, Ricci G, Bartolucci P, Modini C: Mechanical small bowel obstruction due to an inflamed appendix wrapping around the last loop of ileum. *G Chir*, 2005; 26: 261–66
6. Chen YG, Chang HM, Chen YL et al: Perforated acute appendicitis resulting from appendiceal villous adenoma presenting with small bowel obstruction: A case report. *BMC Gastroenterol*, 2011; 11: 35–38
7. Smeenk RM, van Velthuysen ML, Verwaal VJ, Zoetmulder FA: Appendiceal neoplasms and pseudomyxoma peritonei: A population-based study. *Eur J Surg Oncol*, 2008; 34: 196–201
8. Woodruff R, McDonald JR: Benign and malignant cystic tumors of the appendix. *Surg Gynecol Obstet*, 1940; 71: 750–55
9. Pai RK, Beck AH, Norton JA, Longacre TA: Appendiceal mucinous neoplasms: Clinicopathologic study of 116 cases with analysis of factors predicting recurrence. *Am J Surg Pathol*, 2009; 33: 1425–39
10. Misdraji J, Yantiss RK, Graeme-Cook FM et al: Appendiceal mucinous neoplasms: A clinicopathologic analysis of 107 cases. *Am J Surg Pathol*, 2003; 27: 1089–103
11. Carr NJ, McCarthy WF, Sobin LH: Epithelial noncarcinoid tumors and tumor-like lesions of the appendix. A clinicopathologic study of 184 patients with a multivariate analysis of prognostic factors. *Cancer*, 1995; 75: 757–68
12. Lamps LW, Gray GF Jr, Dilday BR, Washington MK: The coexistence of low-grade mucinous neoplasms of the appendix and appendiceal diverticula: A possible role in the pathogenesis of pseudomyxoma peritonei. *Mod Pathol*, 2000; 13: 495–501
13. Akagi I, Yokoi K, Shimanuki K et al: Giant appendiceal mucocele: Report of a case. *J Nippon Med Sch*, 2014; 81: 110–13
14. Kameda T, Kawai F, Taniguchi N et al: Evaluation of whether the ultrasonographic onion skin sign is specific for the diagnosis of an appendiceal mucocele. *J Med Ultrason*, 2014; 41(4): 439–43
15. Pickhardt PJ, Levy AD, Rohrmann CA, Kende AI: Primary neoplasms of the appendix: Radiologic spectrum of disease with pathologic correlation. *Radiographics*, 2003; 23: 645–62
16. Pai RK, Longacre TA: Appendiceal mucinous tumors and pseudomyxoma peritonei: Histologic features, diagnostic problems, and proposed classification. *Adv Anat Pathol*, 2005; 12: 291–311
17. Kawai K, Murata K, Kagawa Y et al: [A case of strangulating intestinal obstruction caused by coiling of low-grade appendiceal mucinous neoplasm to terminal ileum.] *Gan To Kagaku Ryoho*, 2019; 46: 291–93 [in Japanese]
18. Komo T, Kohashi T, Hihara J et al: Intestinal obstruction caused by low-grade appendiceal mucinous neoplasm: A case report and review of the literature. *Int J Surg Case Rep*, 2018; 51: 37–40
19. Arnason T, Kamionek M, Yang M et al: Significance of proximal margin involvement in low-grade appendiceal mucinous neoplasms. *Arch Pathol Lab Med*, 2015; 139: 518–21