

# Results of hip arthroscopy in elite level water polo players with femoroacetabular impingement: return to play and patient satisfaction

Nicholas Ramos \*, Keon Youssefzadeh , Michael Gerhardt and Michael Banffy

Kerlan Jobe Institute, 6801 Park Terrace, Los Angeles, CA 90045, USA.

\*Correspondence to: N. Ramos. E-mail: nikko.ramos@gmail.com

Submitted 26 June 2019; Revised 17 December 2019; revised version accepted 24 December 2019

## ABSTRACT

Water polo places significant stress on the hip joint requiring repetitive hip flexion and rotation to elevate the body out of water for passing, shooting and blocking. Femoroacetabular impingement (FAI) is common in water polo athletes; however, no study to date has investigated the results of hip arthroscopy in this patient population. The purpose of this study was to determine return to play rates and satisfaction following hip arthroscopy for FAI in a cohort of elite level water polo players. A retrospective review of our surgical database was performed. Collegiate water polo players with clinical and radiographic FAI who underwent hip arthroscopy were identified. Pre- and post-operative modified Harris hip scores (mHHSs) were obtained. Patient surveys were administered to determine return to play rates, level of return to play, timing of return and patient satisfaction. A Wilcoxon ranked sum test was performed to compare pre- and post-operative outcome scores. Ten patients met inclusion criteria. Average age was 19.5 years old (SD  $\pm 1.08$ ). All patients were male Division 1 collegiate water polo players. Median mHHS improved from 66.0 (SD  $\pm 7.9$ ) pre-operatively to 89.5 (SD  $\pm 3.2$ ) at average 1.6 years (range: 0.4–3.6 years) post-operatively. Patient survey responses demonstrated a 100% return to water polo and 100% return to the same level of play (NCAA Division 1) at mean 5.75 months (SD  $\pm 1.8$ ). All patients (10/10) reported being satisfied with their surgical result. Our study results, suggest that return to sport rates and patient satisfaction are high in water polo players who undergo hip arthroscopy for FAI.

## INTRODUCTION

Femoroacetabular impingement (FAI) is an increasingly recognized clinical entity that can be a source of hip/groin pain in the young individual. Shown to be more prevalent in athletic populations [1, 2], FAI can be a significant source of hip dysfunction and disability which may affect an athlete's ability to participate in sporting activities. Arthroscopic management of FAI has grown markedly over the past two decades [3] with advances in arthroscopic techniques, better understanding of underlying pathology, and increased clinical recognition by both surgeons and patients. Numerous studies have demonstrated improvements in pain and dysfunction after arthroscopic management of FAI with durable, good to excellent

results. For the young athletic patient, in addition to symptomatic improvement, prognosis regarding ability to return to sport following surgery is also an important consideration. Specifically following hip arthroscopy for FAI, high rates of return to sport have been demonstrated across a wide variety of sporting activities, including ice hockey, baseball, football, high intensity interval training, yoga, Pilates and running [4–12]. The data produced by these types of study is paramount in the surgical decision-making process for both the athletes and surgeons.

Water polo is a sport which places unique demands on the hip joint. Despite being an aquatic endeavor not subjecting the body to the same ground reactive forces as land-based sports, the various swimming motions utilized

during water polo play subject the hip to a variety of flexion and rotational forces. In particular, the eggbeater kick—an important technical skill for the water polo player—places high demands on the hip; requiring rapid repetitive hip rotation and flexion to achieve sufficient propulsion and elevate the player's upper body out of the water. The literature is markedly limited with regards to FAI pathology in the water polo athlete. Frank *et al.* recently reported on the results of arthroscopic FAI management in a cohort of recreational and amateur swimmers. In this study, the authors demonstrated improvements in patient reported outcomes and a 100% return to play rate at average 3.4 months following surgery [13]. While the aquatic environment and some swimming motions may translate to the water polo population, competitive water polo play places a unique stress on the hip joint and the results of hip arthroscopy in the recreational swimmer may not be generalizable to the elite water polo athlete. The purpose of this study is to characterize patients' ability to return to elite level water polo play and satisfaction following hip arthroscopic management of FAI. Despite the demands of the sport, we hypothesized there would be a high rate of return to the same level of play in this cohort.

#### MATERIALS AND METHODS

Institutional review board approval was obtained for this study. A query of the surgical repository of the two senior authors was performed to identify patients who self-reported playing water polo at the collegiate level and had undergone hip arthroscopic management of FAI. Inclusion criteria for this study included those patients who self-reported participation in competitive water polo, had a clinical presentation consistent with FAI (impingement on physical exam and radiographic evidence of cam/pincer bony morphology and or labral pathology), and subsequently underwent surgical treatment of this pathology (acetabuloplasty, femoroplasty and labral repair and/or debridement as indicated). In addition, patients were required to have at least 1 year of NCAA eligibility remaining at the time of surgery. Exclusion criteria included those patients with advanced osteoarthritis (<2 mm joint space on plain radiographs), hip dysplasia (anterior and/or lateral center edge angles <20 degrees and/or Tonnis angle >15 degrees) or diagnoses other than FAI (Legg Calve Perthes, femoral head avascular necrosis, septic arthritis or post-traumatic deformity). Patients who underwent endoscopic treatment of isolated peripheral compartment pathology (i.e. trochanteric bursitis or gluteus medius tears/tendinopathy) or deep gluteal space pathology (piriformis syndrome, proximal hamstring tears/tendinopathy) were also excluded from analysis.

#### Imaging characterization

AP and Dunn lateral plain radiographs were obtained in all patients pre-operatively. Radiographic measurements were recorded for all patients prior to surgery including alpha angle on Dunn lateral films and the lateral center edge angle on AP films. Joint space measurements were recorded on all views to characterize the degree of existing hip arthritis. MRIs were obtained on all patients to evaluate for labral tearing, cartilage lesion or other intra or extra-articular pathology.

#### Operative technique

All surgeries were performed in the supine position using modern hip arthroscopy techniques. In two patients, surgery was performed using a standard traction table. In the remaining eight patients, a post-less table was utilized with reverse trendelenburg positioning. After diagnostic arthroscopy of the central compartment, acetabuloplasty and labral refixation was performed as indicated. Peripheral compartment work was performed either through an interportal or a T-capsulotomy per surgeon preference. Femoroplasty was done with fluoroscopic assistance and a dynamic exam was performed to identify any residual impingement. Full capsular closure was performed in all patients using a previously described technique [14].

#### Rehabilitation

All patients underwent a four-phase rehabilitation protocol summarized in Fig. 1. For the first 3-week weight bearing restrictions (Foot Flat Weightbearing with Crutches) and a hip ROM brace were utilized. Immediate motion was encouraged with CPM use and low resistance stationary bike to prevent adhesions. Patients are progressed through the phases based on pain, neuromuscular control, strength, as well as time. Water polo players are allowed back in the pool at 6 weeks using a pool buoy. Freestyle swimming was initiated at 2 months. Eggbeater movements were not allowed until month 3. Return to full water polo activities was permitted at 4 months provided players demonstrated full strength and had painless ROM.

#### Clinical outcomes: patient satisfaction and return to sport

Baseline modified Harris hip scores (mHHSs) are routinely obtained on all patients undergoing hip arthroscopy at our institution and were recorded for the cohort. Patients were contacted via telephone survey to determine satisfaction with surgery. Binary responses (yes or no) were utilized for ease of data collection, ability to return to water polo, the level of return, as well as timing of return. Return to play was defined as being back in the pool and able to compete in all water polo activities without limitations from the operative hip. Post-operative mHHS was also obtained with this survey.

PHASE	OBJECTIVE	Example Exercises
I	Protect repair, Reduce pain/inflammation, Prevent adhesions	Gluteal, quadriceps, hamstring, isometrics. Stationary bike with no resistance. Passive ROM
II	Continued repair protection, Progression to full ROM, Restoration of normal gait pattern, early strengthening	Short lever hip flexor isometrics, stationary bike with resistance, stairmaster/elliptical
III	Achieve full normal strength, Restoration of normal balance, proprioception, and endurance	Lunges, Side to side lateral agility, running progression
IV	Sport Specific Training, transition to return to competition	Z-Cuts, W-Cuts, Carlocas, Ghiradellis

Fig. 1. Rehabilitation protocol.

The Minimal Clinically Important Difference (MCID) has increasingly been utilized in surgical outcome studies to help delineate between statistical and clinical significance. Defined as the smallest difference in outcome scores that patients perceive as beneficial, the MCID for mHHS has previously been reported for patients undergoing hip arthroscopy as an improvement of eight points by Kemp *et al.* [15]. The percentage of patients who met the MCID improvement threshold was recorded. Complications and reoperations were noted for all patients. Failure was defined as persistent pain, revision hip arthroscopy or conversion to total hip arthroplasty by most recent follow up.

**Statistical analysis**

Patient data were analyzed using Microsoft Excel (version 16.23). Demographic data and patient satisfaction for the cohort were reported with descriptive statistics as means and standard deviations or percentages. Return to water polo variables were presented as continuous data for timing of return. As our pre-op baseline and post-operative mHHSs were not normally distributed, median comparison between groups was performed using the Wilcoxon signed rank test. Significance was set at *P*-value <0.05.

**RESULTS**

**Demographic characteristics**

Review of cases in the surgical registry identified 10 patients who participated in elite level water polo

competition prior to hip arthroscopy. No patients were removed from analysis based on pre-formulated exclusion criteria. All patients were male athletes who participated at the NCAA Division I Level. Demographic data is listed in Table I. Average symptom duration prior to surgery was 13.5 months (SD ±21.5). All patients had previously failed a 6-week trial of conservative management prior to undergoing surgery. Three out of the 10 players had undergone staged bilateral hip arthroscopy. Return to play characterization was determined after the second surgery in these cases.

**Imaging characterization**

The average alpha angle for the surgical hip was 73.7 (SD ±6.1) and the average LCEA was 29.6 (SD ±2.4) indicating a large cam deformity amongst the cohort. No patient was found to have joint space <2.5 mm on any view. All patients had evidence of labral tearing on MRI.

**Intraoperative data**

Procedures performed during hip arthroscopy included acetabuloplasty, labral refixation, femoroplasty and capsular closure (Table II). All patients underwent labral refixation, femoroplasty and capsular closure. Light rim trimming was performed to facilitate labral healing, no patients underwent significant pincer deformity correction. No intraoperative complications were noted.

**Clinical outcomes: patient satisfaction and return to sport**

High rates of patient satisfaction were demonstrated in the survey results with 100% of patients reporting satisfaction with their surgical outcome. Of the patients included, 10/10 were able to return to water polo; 100% were able to return to the same collegiate level as prior to surgical intervention. The mean time for return to sport was 5.75 months (SD ±1.84, range: 4–9 months). Individual improvements in mHHS are listed in Table III. Comparison of baseline and post-op mHHS using the Wilcoxon signed rank test demonstrated a statistically significant difference at average 1.6 years post-operatively [pre-op mHHS: median 66.0 (SD ±7.9) versus post-op mHHS: median 89.5 (SD ±3.2), Critical Value: 8, test statistic: 0, *P* = 0.05] (Fig. 2). All patients in our study met the MCID threshold (Table III). There were no clinical failures during the follow up period.

**DISCUSSION**

Our study results demonstrate that there is a high rate of return to elite level water polo following arthroscopic management of FAI with 100% of our cohort returning to the same level of play. In addition, our survey results indicate

high rates of patient satisfaction with the procedure. This data provides valuable information for athletes with this condition, coaches, trainers and treating orthopedic surgeons, allowing for appropriate counseling and management of patient expectations with goals of maximizing patient outcome.

Return to play rates following hip arthroscopy for FAI across a myriad of different sporting activities are generally high with upwards of 80–100% of patients being able to return to their previous level of play. The results of our study are consistent with these published results and further

confirm that arthroscopic management of FAI can reliably return athletes to the same level of prior athletic endeavors.

A variety of lower extremity movements are required for the various swimming motions utilized during water

**Table I. Cohort demographics**

<i>Total number of patients</i>	
<i>Age</i>	Mean 19.5 years old (SD $\pm$ 1.1)
<i>Gender (male)</i>	100%
<i>Pre-op symptom duration</i>	Mean 13.5 months (SD $\pm$ 21.5)
<i>Average alpha angle</i>	Mean 73.7 degrees (SD $\pm$ 6.1)
<i>Average lateral center edge angle</i>	Mean 29.6 degrees (SD $\pm$ 2.4)
<i>Labral repair</i>	100%
<i>Capsular closure</i>	100%
<i>Bilateral surgery</i>	3/10 patients

**Table II. Surgical procedures performed**

<i>Patient number</i>	<i>Acetabuloplasty (Y/N)</i>	<i>Femoroplasty (Y/N)</i>	<i>Labral refixation (Y/N)</i>	<i>Capsulotomy type (interportal versus T)</i>	<i>Capsular closure</i>
1	Y	Y	Y	T	Y
2	N	Y	Y	T	Y
3	N	Y	Y	T	Y
4	N	Y	Y	T	Y
5	N	Y	Y	T	Y
6	N	Y	Y	Interportal	Y
7	N	Y	Y	Interportal	Y
8	N	Y	Y	T	Y
9	N	Y	Y	T	Y
10	N	Y	Y	T	Y

**Table III. Pre- versus post-op mHHS (individual differences and MCID)**

<i>Patient number</i>	<i>Pre-op mHHS</i>	<i>Post-op mHHS (mean 1.6 years post-op)</i>	<i>Interval change</i>	<i>MCID threshold met<sup>a</sup> (Y/N)</i>
1	60	91	+31	Y
2	61	84	+23	Y
3	74	82	+8	Y
4	75	91	+16	Y
5	71	90	+19	Y
6	56	89	+33	Y
7	71	91	+20	Y
8	63	87	+24	Y
9	69	91	+22	Y
10	52	86	+34	Y

<sup>a</sup>mHHS MCID threshold = 8 point improvement.

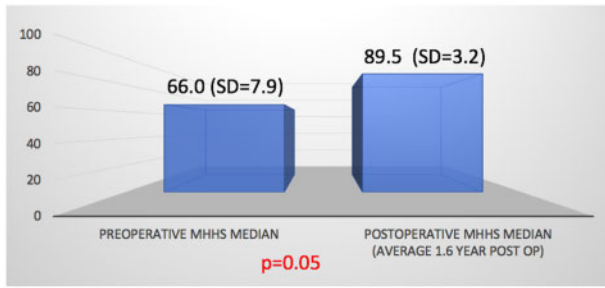


Fig. 2. Median pre- versus post-op mHHS.

polo play. Repetitive flexion moments during freestyle and butterfly stroke and rapid rotational moments during the breaststroke and eggbeater kick place the water polo hip at risk for impingement. Despite these rigors, a high rate of return to play was found in the athletes in our study. Furthermore, the return to play timing in our study [5.75 months (range: 4–9 months)] was quicker than recent reports in land-based athletes (range: 6.7–7.4 months) [16–19]. It is plausible that the aquatic environment of play for water polo athletes may contribute to this high rate of return—the buoyant force of water counteracts gravitational force leading to a reduction in apparent body weight and overall joint forces about the hip [20]. This is supported by the findings of Frank *et al.* [13] which demonstrated a 100% return to sport rate in recreational and amateur swimmers following arthroscopic management of FAI—the lessened joint impact/loading of the hip in aquatic environment may facilitate a return to previous level of sporting play following surgery. The return to play timing in our study was longer than that reported in the swimming cohort of Frank *et al.* [5.75 months (SD  $\pm$ 1.8) versus 3.4 months (SD  $\pm$ 1.7)] and this may reflect the increased demands and stresses on the hip in competitive water polo play.

#### Limitations

There are several limitations to our study. The retrospective design inherently assumes selection bias; however, continuous patients who met inclusion criteria during the study period were included for analysis to minimize this risk. The use of survey data also risks recall bias and this should be considered when interpreting our results. While our sample size is small, given the specificity of the elite level water polo athlete cohort in question, we feel reporting results in this limited cohort provides valuable prognostic information regarding return to play and patient satisfaction which can help manage patient expectation and optimize overall outcome following surgery. No control group (i.e. water polo players with FAI managed non-operatively) was utilized in this study, which would have

strengthened the result—similarly, the specificity of the patient population in question precluded our ability to perform this type of comparison. Our follow up duration for this study was relatively short- (mean 1.6 years, range: 0.4–3.6 years) and longer-term outcomes would indeed be valuable. However; we feel reporting our results in light of short follow up was justified in that it did allow for capture of a main desired outcome metric: time to return to sport. Lastly, while we were able to determine that all patients were able to successfully return to the same level of play; we were unable to characterize their performance following return. While water polo-specific performance metrics have been evaluated [21], their utilization is not routine at the collegiate level and this data was not available for analysis. In addition, the mHHS may not be the most suitable outcome tool for the athletic FAI population as it was designed to evaluate treatment response in patients with arthritic disease [22]. Despite these shortcomings, the mHHS remains a commonly reported metric in hip arthroscopy outcome studies in athletic patients [23–25]. The mHHS was utilized in this study as it is routinely captured at our institution with patient intake and was readily available for analysis in our cohort.

#### CONCLUSIONS

Return to play rates and patient satisfaction were found to be high (100%) in this cohort of elite water polo players undergoing hip arthroscopy for FAI. Larger, prospective studies with further objective return to sport metrics would be valuable in corroborating these results; however, these findings can help guide initial management for both water polo players with symptomatic FAI as well as the treating orthopedic surgeon.

#### CONFLICT OF INTEREST STATEMENT

The authors declare no conflict of interest in performing this study.

#### REFERENCES

1. Ayeni OR, Banga K, Bhandari M *et al.* Femoroacetabular impingement in elite ice hockey players. *Knee Surg Sports Traumatol Arthrosc* 2014; **22**: 920–5.
2. Agricola R, Bessems JHJM, Ginai AZ *et al.* The development of Cam-type deformity in adolescent and young male soccer players. *Am J Sports Med* 2012; **40**: 1099–106.
3. Bonazza NA, Homcha B, Liu G *et al.* Surgical trends in arthroscopic hip surgery using a large national database. *Arthroscopy* 2018; **34**: 1825–30.
4. Lubbe RJ, Freshman RD, Singh G *et al.* Performance outcomes and return-to-sport rate of National Hockey League athletes vary

- after common orthopedic surgical procedures. *Clin J Sport Med* 2018; doi: 10.1097/JSM.0000000000000696.
5. Byrd JW, Jones KS. Hip arthroscopy in high-level baseball players. *Arthroscopy* 2015; **31**: 1507–10.
  6. Menge TJ, Bhatia S, McNamara SC *et al.* Femoroacetabular impingement in professional football players: return to play and predictors of career length after hip arthroscopy. *Am J Sports Med* 2017; **45**: 1740–4.
  7. Riff AJ, Ukwuani G, Clapp I *et al.* High rate of return to high-intensity interval training after arthroscopic management of femoroacetabular impingement syndrome. *Am J Sports Med* 2018; **46**: 2594–600.
  8. Frank RM, Ukwuani G, Allison B *et al.* High rate of return to yoga for athletes after hip arthroscopy for femoroacetabular impingement syndrome. *Sports Health* 2018; **10**: 434–40.
  9. Levy DM, Kuhns BD, Frank RM *et al.* High rate of return to running for athletes after hip arthroscopy for the treatment of femoroacetabular impingement and capsular plication. *Am J Sports Med* 2017; **45**: 127–34.
  10. Keating TC, Chahla J, Beck EC *et al.* Return to Pilates following hip arthroscopy for treatment of femoroacetabular impingement syndrome. *J Hip Preserv Surg* 2019.
  11. Sochacki KR, Jack RA, Hirase T *et al.* Performance and return to sport after hip arthroscopy for femoroacetabular impingement syndrome in National Hockey League players. *J Hip Preserv Surg* 2019; **6**: 234–40.
  12. Domb BG, Dunne KF, Martin TJ *et al.* Patient reported outcomes for patients who returned to sport compared with those who did not after hip arthroscopy: minimum 2-year follow-up. *J Hip Preserv Surg* 2016; **3**: 124–31.
  13. Frank RM, Ukwuani G, Chahla J *et al.* High rate of return to swimming after hip arthroscopy for femoroacetabular impingement. *Arthroscopy* 2018; **34**: 1471–7.
  14. Aoki SK, Karns MR, Hananouchi T *et al.* Hip arthroscopy capsular closure: the figure of eight technique. *Arthrosc Tech* 2017; **6**: e505–9.
  15. Kemp JL, Collins NJ, Roos EM *et al.* Psychometric properties of patient-reported outcome measures for hip arthroscopic surgery. *Am J Sports Med* 2013; **41**: 2065–73.
  16. Waterman BR, Ukwuani G, Clapp I *et al.* Return to golf after arthroscopic management of femoroacetabular impingement syndrome. *Arthroscopy* 2018; **34**: 3187–93.e1.
  17. Jack RA, Sochacki KR, Hirase T *et al.* Performance and return to sport after hip arthroscopy for femoroacetabular impingement in professional athletes differs between sports. *Arthroscopy* 2019; **35**: 1422–8.
  18. Sochacki KR, Jack RA, Hirase T *et al.* Performance and return to sport after femoroacetabular impingement surgery in National Football League players. *Orthopedics* 2019; **42**: e423–9.
  19. O'Connor M, Minkara AA, Westermann RW *et al.* Return to play after hip arthroscopy: a systematic review and meta-analysis. *Am J Sports Med* 2018; **46**: 2780–8.
  20. Kutzner I, Richter A, Gordt K *et al.* Does aquatic exercise reduce hip and knee joint loading? *In vivo* load measurements with instrumented implants. *PLoS One* 2017; **12**: e0171972.
  21. Ordóñez EG, Pérez MD, González CT. Performance assessment in water polo using compositional data analysis. *J Hum Kinet* 2016; **54**: 143–51.
  22. Papaliodis DN, Banffy MB, Limpisvasti O *et al.* The development and validation of a subjective assessment tool for the hip in the athletic population. *Am J Sports Med* 2017; **45**: 2517–23.
  23. Chen AW, Craig MJ, Mu BH *et al.* Return to basketball after hip arthroscopy: minimum 2-year follow-up. *Arthroscopy* 2019; **35**: 2834–44.
  24. Perets I, Craig MJ, Mu BH *et al.* Midterm outcomes and return to sports among athletes undergoing hip arthroscopy. *Am J Sports Med* 2018; **46**: 1661–7.
  25. Frank RM, Ukwuani G, Clapp I *et al.* High rate of return to cycling after hip arthroscopy for femoroacetabular impingement syndrome. *Sports Health* 2018; **10**: 259–65.