

## Case report

## Adenomyosis presenting as a molar pregnancy: A case report

Bronwyn S. Bedrick<sup>a</sup>, Gregory S. Kazarian<sup>a</sup>, Molly M. Greenwade<sup>b</sup>, Nick Spies<sup>c</sup>, Tiffany Chen<sup>d</sup>,  
Horacio Maluf<sup>cd</sup>, Jeffrey Dicke<sup>c</sup>, Premal H. Thaker<sup>b,\*</sup>

<sup>a</sup> Washington University School of Medicine, St. Louis, MO, USA

<sup>b</sup> Division of Gynecologic Oncology, Washington University School of Medicine, St. Louis, MO, USA

<sup>c</sup> Department of Obstetrics and Gynecology, Washington University School of Medicine, St. Louis, MO, USA

<sup>d</sup> Department of Pathology, Washington University School of Medicine, St. Louis, MO, USA

## ARTICLE INFO

## Keywords:

Cystic adenomyosis  
Gestational trophoblastic disease  
Hook effect  
Hypothyroidism  
Abnormal uterine bleeding

## 1. Introduction

Abnormal uterine bleeding (AUB) is a common symptom with a broad differential diagnosis. One cause of AUB is adenomyosis, a condition that results from benign proliferation of endometrial glands and stroma into the myometrium. Adenomyosis is characterized by a histologically glandular appearance and patchy solid proliferation of endometrial glands and stroma, with cystic adenomyosis being less common (Troiano et al., 1998; Dogan et al., 2008; Brosens et al., 2015). Patients with adenomyosis classically present with AUB, pelvic pain, and dysmenorrhea. Due to the non-specific nature of these symptoms, a conclusive diagnosis of adenomyosis often relies on imaging or histological findings. As adenomyosis can affect pre- and postmenopausal women, the work-up must exclude pregnancy-related causes of AUB.

While there are many possible causes of vaginal bleeding, molar pregnancy is life-threatening and requires rapid evaluation and management. Molar pregnancy, the result of abnormal fertilization and subsequent aberrant proliferation of an egg, occurs in about 1 in every 1000 pregnancies. Clinical findings include vaginal bleeding, rapid uterine growth with uterine size exceeding expected gestational age, ovarian cysts, emesis, anemia, and preeclampsia. Sonographic imaging often demonstrates a “snowstorm” appearance of the uterus, and metastatic lesions may appear on chest imaging (Berkowitz and Goldstein, 2009). Given the life-threatening nature of molar pregnancy, it is important to promptly rule out this diagnosis in women of child-bearing age presenting with vaginal bleeding and abdominal pain.

Here, we report a case of histologically atypical adenomyosis in a

woman presenting with clinical, laboratory, and imaging findings concerning for a molar pregnancy.

## 2. Case

A 30-year-old G1P0010 premenopausal female presented to an outside hospital emergency department after a week of profuse vaginal bleeding with large blood clots, nausea, lightheadedness, diffuse lower abdominal pain, and a syncopal episode. Her past medical history included a spontaneous abortion at 11 weeks gestational age at age 18 and a BMI of 48.4 kg/m<sup>2</sup>. Her menstrual history was significant for menarche at age 13 and regular monthly cycles until age 27, when she developed AUB. She denied recent hormonal contraceptive use and was last sexually active six months ago.

Upon initial presentation, laboratory testing revealed an elevated quantitative  $\beta$ -hCG of 25.0 mIU/mL and a Hgb of 9.6 g/dL. She was diagnosed with a spontaneous abortion and acute blood loss anemia and discharged with plans to repeat labs in 48 h to confirm this diagnosis. However, her symptoms continued, prompting her return to the emergency department two days later. On return, Hgb had decreased to 8.3 g/dL, and  $\beta$ -hCG was 24.0 mIU/mL. Transvaginal ultrasound demonstrated an enlarged, globular uterus (21.2 × 16.6 × 12.6 cm) with a heterogeneously hyperechoic mass, demonstrating small cystic foci within the uterus (12.6 × 14 × 10.6 cm). The mass extended distally into the cervix and appeared to invade posteriorly into the myometrium (Fig. 1). Thyroid function tests were also obtained, and TSH was found to be elevated at 9.59 mU/L with normal T3 and T4. Given her enlarged

\* Corresponding author at: Washington University School of Medicine, 660 South Euclid Avenue, Mail Stop 8064-37-905, St. Louis, MO 63110, USA.

E-mail address: [thakerp@wustl.edu](mailto:thakerp@wustl.edu) (P.H. Thaker).

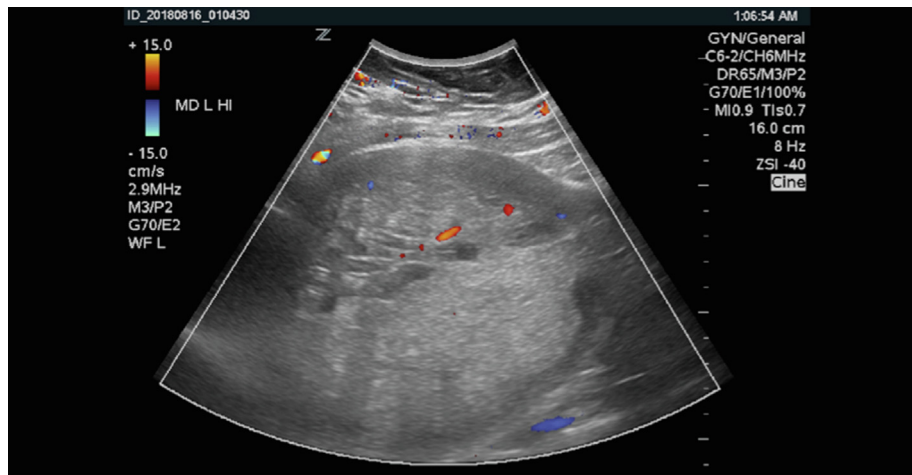
<https://doi.org/10.1016/j.gore.2020.100573>

Received 28 February 2020; Received in revised form 17 April 2020; Accepted 18 April 2020

Available online 23 April 2020

2352-5789/ © 2020 Published by Elsevier Inc. This is an open access article under the CC BY-NC-ND license

(<http://creativecommons.org/licenses/by-nc-nd/4.0/>).



**Fig. 1.** Transabdominal ultrasound image from the emergency department demonstrating an enlarged uterus and a heterogeneously hyperechoic mass demonstrating small cystic foci within the uterus.

uterus, persistently elevated  $\beta$ -hCG, ultrasound findings, and suggestive symptoms, she was transferred to our gynecologic oncology service for further evaluation of a suspected molar pregnancy.

On admission, a chest radiograph was obtained that demonstrated a nodular opacity within the left lung concerning for metastasis of gestational trophoblastic disease. A subsequent CT scan did not support metastatic disease to the lungs, but it demonstrated an enlarged uterus and hypovascular mass concerning for molar pregnancy and ovarian changes concerning for theca lutein cysts.

Although the patient's history appeared to be most concerning for molar pregnancy, her BMI and hence elevated estrogen exposure, raised our suspicion for other potential causes of AUB, including endometrial hyperplasia, adenomyosis, and malignancy (Templeman et al., 2008).  $\beta$ -hCG levels were repeated and remained elevated at 12.0 mIU/mL. The patient was consented for exam under anesthesia with diagnostic and therapeutic suction dilation and curettage and was counseled regarding the risks of surgery and the potential need for total abdominal hysterectomy to achieve hemostasis. The patient was not interested in future fertility. Immediately prior to surgery, the patient had a urine  $\beta$ -hCG test, which was negative.

While performing a bimanual exam, manipulation of the cervix prompted profuse, bright red vaginal bleeding, with an estimated blood loss of 300 cc within minutes. The decision was made to proceed urgently with a total abdominal hysterectomy. The ovaries appeared grossly normal at the time of surgery and were left in situ, and bilateral salpingectomy was performed. The uterus was grossly inspected by the surgeon and noted to be enlarged and globular. Bivalving the uterus revealed poorly defined myometrium, and an endometrial cavity filled with cystic material. The specimen was sent to pathology for frozen section, but pathology was unable to confirm a histological diagnosis intraoperatively. She received a total of four units of packed red blood cells. Her post-operative course was routine except for a superficial wound separation. Final pathology reported a 1620.9 g uterus measuring 17.5 cm. The endocervix measured  $5 \times 2$  cm and was lined by a herringbone pattern of tan-pink mucosa with no discernible lesions. The majority of the myometrium, endocervical cavity, and lower uterine segment demonstrated a spongy trabeculated tan-white homogenous cut surface with no areas of firmness or necrosis. Analysis of permanent sections yielded a diagnosis of cystic adenomyosis of the cervix and uterus (Fig. 2).

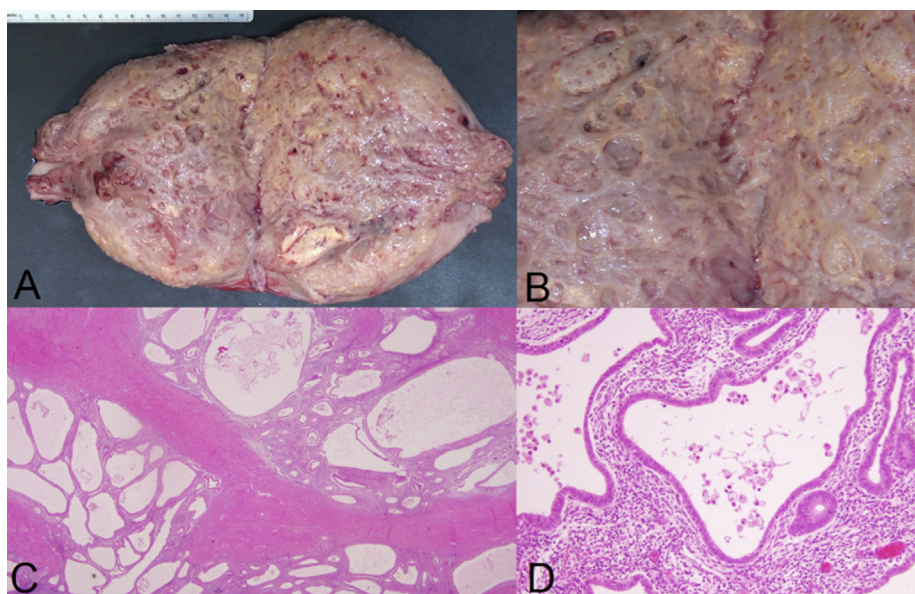
### 3. Discussion

Adenomyosis has historically been diagnosed through histologic examination of hysterectomy specimens, and thus has been thought to

be a disease of women in their 40 s and 50 s. However, with improvements in radiologic imaging, adenomyosis is being detected at earlier ages. Cystic adenomyosis also tends to present in younger women, even in adolescents, and with more severe symptoms (Brosens et al., 2015). However, adenomyosis can present diagnostic challenges, as cysts can mimic uterine malformation or ovarian masses (Dogan et al., 2008; Brosens et al., 2015), and imaging and histologic features may suggest malignancy (Goldblum et al., 1995; Funaki et al., 2011). Identification of adenomyosis in these cases may be critical as definitive treatment varies drastically and may eliminate future fertility or induce earlier menopause in young women without malignancy. To our knowledge, this is the first case report of a presentation of adenomyosis presenting with symptoms, imaging, and laboratory findings concerning for molar pregnancy, which further highlights the challenges in diagnosing this condition.

Like adenomyosis, the definitive diagnosis for a molar pregnancy is by histology. However, an accurate diagnosis can be made in the setting of classic radiographic appearance, especially with elevated  $\beta$ -hCG levels and clinical symptoms such as nausea and vomiting. With 70% sensitivity and 99% specificity, ultrasound can accurately identify complete molar pregnancies, which frequently presents as a diffuse, heterogenous echogenic pattern of villi and blood clots, or "snowstorm" appearance (Ross et al., 2018). Additionally, theca lutein cysts are found in 15–25% of patients with molar pregnancies and can aid in diagnosis. Overall, cystic uterine and ovarian changes are more common in the setting of molar pregnancies than in adenomyosis. In our case, it is likely that the "snowstorm" appearance identified on ultrasound represented small cysts associated with cystic adenomyosis, and that the ovarian changes were simply functional cysts.

Markedly elevated levels of  $\beta$ -hCG are responsible for many of the classic signs and symptoms of molar pregnancies including theca lutein cysts and nausea and vomiting. While molar pregnancy is frequently associated with  $\beta$ -hCG  $> 100,000$  mIU/mL, our patient's levels were marginally elevated. Negative or falsely low levels of  $\beta$ -hCG can occur in the setting of molar pregnancies due to the "hook effect," in which the signaling antibodies used to detect  $\beta$ -hCG are oversaturated and lead to faulty measurements (Tabas et al., 2003). While rare, the hook effect can lead to delayed therapy and life-threatening complications. In our case, serial dilutions were not performed because it would not have changed the initial plan for diagnostic curettage. On the other hand, falsely elevated levels of  $\beta$ -hCG levels can occur in the setting of heterophile antibodies, in which serum antibodies interfere with the  $\beta$ -hCG immunoassay. A negative urine  $\beta$ -hCG test in the setting of a positive serum  $\beta$ -hCG test, as seen with our patient, may indicate the presence of heterophile antibodies, which are not renally excreted (Check et al.,



**Fig. 2.** (A) Gross picture of bivalved (anteposteriorly) uterus with a uniformly, diffusely cystic cut surface (B) involving the endometrium, myometrium, and lower uterine segment. Hematoxylin and eosin (H&E) histology at 40 $\times$  (C) shows diffuse cystic adenomyosis. All examined areas of the adenomyosis shows endometrial glands with minimal cytologic atypia and mitoses, as illustrated in the H&E image at 200 $\times$  in (D).

1988). Falsely elevated  $\beta$ -hCG levels can be seen with obesity and hypothyroidism. Given that hCG and TSH have a common  $\alpha$  subunit, elevated TSH levels can falsely increase hCG readings, and this is another potential explanation in our patient.

This case also illustrates an important lesson in the hemodynamic management of patients with adenomyosis. Given our patient's profuse bleeding with cervical manipulation during the bimanual exam, it is important to acknowledge the potential for hemorrhage when examining patients with adenomyosis, especially in the clinical setting. While recent data suggest that the use of uterotonics such as oxytocin prior to dilation and evacuation can reduce blood loss and hemorrhage frequency (Whitehouse et al., 2019), it is unlikely that the use of uterotonics in our case could have prevented significant hemorrhage given the extensive cystic distortion of the uterus and lower uterine oxytocin receptor concentration in a nonpregnant uterus.

#### 4. Conclusion

We report a case of extensive adenomyosis with clinical, imaging, and laboratory findings concerning for molar pregnancy. This case highlights how hypothyroidism may obfuscate the interpretation of  $\beta$ -hCG levels in reproductive age women and that it should be considered in the differential diagnosis of an elevated  $\beta$ -hCG. Although rare, cystic adenomyosis should also be considered in women with abnormal uterine bleeding and a "snowstorm" appearing uterus on ultrasound. Finally, this case illustrates how a constellation of symptoms may be explained by relatively common conditions rather than one relatively more rare condition.

#### 5. Ethics approval

This retrospective case report was exempt for Institutional Review Board approval.

#### 6. Consent

Informed consent was obtained from the patient, which approved reporting of this case and accompanying images.

#### Author contribution

GSK, BSB, NS, MMG, and PHT wrote the main manuscript body. MMG and PHT were involved in patient treatment. TC and HM were responsible for reviewing pathology. JD was responsible for reviewing radiology. All authors reviewed the final manuscript.

#### Declaration of Competing Interest

The authors of this case report declare no conflicts pertaining to the current study.

#### References

- Troiano, R.N., Flynn, S.D., McCarthy, S., 1998. Cystic adenomyosis of the uterus: MRI. *J. Magn. Reson. Imaging* 8 (6), 1198–1202.
- Dogan, E., Gode, F., Saatli, B., Secil, M., 2008. Juvenile cystic adenomyosis mimicking uterine malformation: a case report. *Arch. Gynecol. Obstet.* 278 (6), 593–595.
- Brosens, I., Gordts, S., Habiba, M., Benagiano, G., 2015. Uterine cystic adenomyosis: a disease of younger women. *J. Pediatr. Adolesc. Gynecol.* 28 (6), 420–426.
- Berkowitz, R.S., Goldstein, D.P., 2009. Clinical practice. Molar pregnancy. *N. Engl. J. Med.* 360 (16), 1639–1645.
- Templeman, C., Marshall, S.F., Ursin, G., Horn-Ross, P.L., Clarke, C.A., Allen, M., et al., 2008. Adenomyosis and endometriosis in the California Teachers Study. *Fertil. Steril.* 90 (2), 415–424.
- Goldblum, J.R., Clement, P.B., Hart, W.R., 1995. Adenomyosis with sparse glands. A potential mimic of low-grade endometrial stromal sarcoma. *Am. J. Clin. Pathol.* 103 (2), 218–223.
- Funaki, K., Fukunishi, H., Maeda, T., Ohbayashi, C., Yamaguchi, S., 2011. Adenomyosis with extensive glandular proliferation simulating infiltrating malignancy on magnetic resonance imaging. *Jpn. J. Radiol.* 29 (4), 272–275.
- Ross, J.A., Unipan, A., Clarke, J., Magee, C., Johns, J., 2018. Ultrasound diagnosis of molar pregnancy. *Ultrasound* 26 (3), 153–159.
- Tabas, J.A., Strehlow, M., Isaacs, E., 2003. A false negative pregnancy test in a patient with a hydatidiform molar pregnancy. *N. Engl. J. Med.* 349 (22), 2172–2173.
- Check, J.H., Nowroozi, K., Chase, J.S., Lauer, C., Elkins, B., Wu, C.H., 1988. False-positive human chorionic gonadotropin levels caused by a heterophile antibody with the immunoradiometric assay. *Am. J. Obstet. Gynecol.* 158 (1), 99–100.
- Whitehouse, K., Tschann, M., Soon, R., Davis, J., Micks, E., Salcedo, J., et al., 2019. Effects of prophylactic oxytocin on bleeding outcomes in women undergoing dilation and evacuation: a randomized controlled trial. *Obstet. Gynecol.* 133 (3), 484–491.