

# Paths of femoral nerve catheters placed using ultrasound-guided in plane vs out of plane techniques

## A randomized controlled clinical trial

Benedikt Büttner, MD<sup>a,\*</sup>, Joschka Dracklé, MD<sup>a</sup>, Katalin Kristof, MD, PhD<sup>a</sup>, José Hinz, MD, PhD<sup>b</sup>, Alexander Schwarz, MD<sup>c</sup>, Martin Bauer, MD, PhD<sup>b</sup>, Ashham Mansur, MD, PhD<sup>a</sup>, Ingo Bergmann, MD, PhD<sup>a</sup>

### Abstract

**Background:** Continuous blockade of the femoral nerve is widely used for postoperative analgesia after hip surgery. It can be achieved by ultrasound-guided placement of a femoral nerve catheter via either the in plane (IP) or out of plane (OOP) technique. On the basis of postoperative radiographs, we evaluated the paths of femoral nerve catheters with respect to both techniques and its effect on postoperative analgesia.

**Methods:** Thirty-four patients were randomized to receive a radiopaque femoral nerve catheter via either the IP or OOP technique. The paths and tip position of the catheters were evaluated in postoperative frontal radiographs of the operated hip joint concerning a predefined target region and four neighboring regions. Pain scores were assessed using a numeric rating scale (0–10).

**Results:** Sixteen IP patients and 18 OOP patients were included in the study. The catheter path was radiographically evaluated in 13 IP patients and in 10 OOP patients. The catheter tips were located within the target region in 39% of the IP group and in 50% of the OOP group. The catheter tip was 0.00 cm [–3.80 to 3.84] and –1.19 cm [–12.27 to 0.00] (median [range]) from the target region in the OOP group and IP group, respectively ( $P = .045$ ). Catheters flipped distally more often in the IP group (IP: 61.5%, OOP: 10.0%;  $P = .01$ ). There were no marked differences in the pain scores of either group.

**Conclusion:** Femoral nerve catheters inserted by the ultrasound-guided IP technique flip distally more frequently than catheters inserted by the OOP technique. Moreover, the distance between the catheter tip and the trunk of the femoral nerve is greater for IP catheters than for OOP catheters. Despite these findings, postoperative analgesia did not seem to differ between the 2 techniques.

**Abbreviations:** ASA = American Society of Anesthesiologists, BW = body weight, DHS = dynamic hip screw, GA = general anesthesia, HTEP = hip total endoprosthesis, IP = in plane, MRC = Medical Research Council, NRS = numeric rating scale, OOP = out of plane, PFN = proximal femoral nail, POD = postoperative day, SAX = short axis, SD = standard deviation, SPA = spinal anesthesia.

**Keywords:** continuous femoral nerve block, in plane vs out of plane, nerve catheter displacement, radiopaque nerve catheters, X-ray analysis

Editor: Joho Tokumine.

AM and IB contributed equally to this study.

This work was supported only by departmental funding sources.

The authors declare that the co-author Ashham Mansur, associate professor, is an Academic Editor of *Medicine* (Section Anesthesiology). This does not alter the authors' adherence to all the *Medicine* policies.

The authors have no funding and conflicts of interest to disclose.

<sup>a</sup> Department of Anesthesiology, Emergency and Intensive Care Medicine, University Medical Center, University of Goettingen, Goettingen, <sup>b</sup> Department of Anesthesiology, Emergency and Intensive Care Medicine, Klinikum Region Hannover, Hannover, <sup>c</sup> Department of Neuroradiology, University Medical Center Goettingen, University of Goettingen, Goettingen, Germany.

\* Correspondence: Benedikt Büttner, Department of Anesthesiology, Emergency and Intensive Care Medicine, University Medical Center Goettingen, Robert-Koch Str 40, 37075 Goettingen, Germany (e-mail: Benedikt.Buettner@med.uni-goettingen.de).

Copyright © 2018 the Author(s). Published by Wolters Kluwer Health, Inc. This is an open access article distributed under the terms of the Creative Commons Attribution-Non Commercial License 4.0 (CCBY-NC), where it is permissible to download, share, remix, transform, and buildup the work provided it is properly cited. The work cannot be used commercially without permission from the journal.

*Medicine* (2018) 97:43(e12958)

Received: 8 August 2018 / Accepted: 29 September 2018

<http://dx.doi.org/10.1097/MD.00000000000012958>

## 1. Introduction

Continuous blockade of the femoral nerve is an effective technique for postoperative analgesia after hip surgery and rarely leads to complications.<sup>[1–3]</sup> Two different techniques for ultrasound-guided placement of the catheter—in plane (IP) and out of plane (OOP) techniques—are usually available using nerves via the short axis (SAX).<sup>[4,5]</sup> In the OOP technique, the needle is guided in parallel to the course of the femoral nerve and vertically to the ultrasound plane. The catheter is advanced parallel along the path of the femoral nerve and may be located close to the femoral nerve. However, visualization of the needle tip is more difficult in the OOP technique, with higher potential of accidental puncture of the femoral nerve or neighboring vessels.<sup>[4]</sup> In contrast, in the IP technique, the needle is inserted parallel to the ultrasound plane but vertically to the femoral nerve. In this technique, the catheter is advanced vertically to the path of the femoral nerve so that malposition of the catheter above the nerve is possible and deficient postoperative analgesia is expected.<sup>[4]</sup> Studies conducted regarding the placement of femoral nerve catheters in the IP or OOP techniques have revealed no differences in satisfactory, postoperative analgesia,<sup>[6,7]</sup> although postoperative catheter dislocation or therapy failure are reported in up to 25%.<sup>[8,9]</sup> Different techniques to

optimize the path of peripheral nerve catheters and to determine the catheter tip position are currently under investigation.<sup>[5]</sup> However, no data exists thus far regarding the path of the femoral nerve catheter or the tip position with respect to the IP or OOP technique.

In this study, we evaluated the course of radiopaque femoral nerve catheters on the basis of postoperative radiographs of the hip joint with respect to IP or OOP technique of ultrasound-guided placement. We assessed the paths of the catheters in the radiographs with regard to the proximal-distal axis of the femoral nerve. Furthermore, we documented the position and distance of the catheter tip with respect to a predefined target region, which could be projected on the inguinal position of the femoral nerve in the radiograph of the hip joint. Additionally, the quality of femoral and lateral femoral cutaneous nerve blocks and the incidence and intensity of postoperative pain were recorded. The aim of this study was to determine whether the position of the catheter tip within the target region was dependent on the technique used (the IP vs OOP technique) and its potential positive effects on postoperative analgesia.

## 2. Methods

This prospective randomized study was approved by the local ethics committee of the University Goettingen (No 11/5/14) and was registered at the *Deutsches Register klinischer Studien* under clinical trial number DRKS00011585 on January 18, 2017.

### 2.1. Patient recruitment

American Society of Anesthesiology (ASA) I to III patients aged 18 to 100 years and scheduled for a hip joint operation (implantation of a total hip endoprosthesis, a proximal femoral nail, or a dynamic hip screw) between February 1, 2017 and August 1, 2017 and with no contraindications for a continuous femoral nerve blockade was recruited for the study. After providing informed consent, the patients were randomized by a computer-based online tool (Research Randomizer©, Urbaniak GC, Plous S) to either IP or OOP technique groups for ultrasound-guided continuous femoral nerve block. Either spinal or general anesthesia was induced with respect to the patient's comorbidities or preference.

### 2.2. Placement of femoral nerve catheter

A peripheral vein was cannulated, and patient monitoring (noninvasive blood pressure, pulse oximetry, continuous electrocardiography) was established. Midazolam was given intravenously as a premedication dose titrated to render the patient relaxed but still cooperative (1–3 mg). For the placement of the femoral nerve catheter, patients were placed in a supine position. All femoral nerve catheters were placed by staff anesthesiologists or senior residents under staff supervision. The femoral nerve was located by ultrasound (12 MHz transducer, M-Turbo; FUJIFILM SonoSite, Bothell, WA) just distal to the inguinal ligament with the nerve in the SAX view. The appropriate puncture site was disinfected, draped and anesthetized with 1% mepivacaine. In the OOP group, puncture was performed using a 19-gauge needle with a facet profile (SonoLong NanoLine 50 mm; Pajunk GmbH, Geisingen, Deutschland) 2 to 3 cm distal to the ultrasound probe. The needle tip was placed under ultrasound guidance via the “walk down” technique under the fascia iliaca lateral to the femoral nerve. In the IP group, puncture was performed using an

18-gauge Tuohy needle (SonoLong NanoLine, 50 mm; Pajunk GmbH) 1 cm lateral to the ultrasound probe. The needle was guided under the fascia iliaca near the lateral aspect of the femoral nerve under continuous ultrasound visualization. In both groups, after identifying the correct position of the needle tip by ultrasound, 10 milliliters of prilocaine 1% and 10 milliliters ropivacaine 0.75% were injected under the fascia iliaca until the entire circumference of the nerve was surrounded by the local anesthetic. In both groups, the needle tip was orientated with the orifice facing proximally in the direction of the nerve, and the radiopaque one-orifice catheter (SonoLong Sono Catheter, 20G, 50 cm; Pajunk GmbH) was blindly advanced beyond the needle tip 3 to 6 cm (depending on if this could be done smoothly). The correct catheter position was indirectly confirmed upon observing the spread of saline solution injected via the catheter. The catheter was fixed on the skin with sutures, and sterile tape was applied. Immediately afterwards, general anesthesia or spinal anesthesia was performed.

A postoperative femoral nerve catheter was connected to a mobile infusion pump (PEGA PCA; Venner Medical, Dänischhagen, Deutschland) with continuous application of ropivacaine 0.2% (rate: 7 mL/h). Patients were able to dispense boluses of local anesthetics on demand each half-hour (10 mg ropivacaine, 0.2%). Patients were followed up each day by a study doctor (JD). In cases of unacceptable pain levels (numeric rating scale [NRS]  $\geq 3$ ), the delivery rate of the infusion pump was increased in steps of 1 mL/h.

### 2.3. General anesthesia

General anesthesia was a total intravenous technique with sufentanil and propofol. Anesthesia was induced with a bolus injection of sufentanil (0.3  $\mu$ g/kg body weight [BW]) followed by a bolus injection of propofol (2 mg/kg BW given over 2 minutes). After a sufficient depth of anesthesia was reached, muscle relaxation using rocuronium (0.6 mg/kg BW) was induced, and the patient was intubated endotracheally. Lungs were ventilated with 40% oxygen, a tidal volume of 7 mL/kg BW and a frequency of 15 breaths/min (adjusting to end-tidal CO<sub>2</sub>, 35–45 mm Hg). Anesthesia was maintained with continuous infusion of propofol (4 mg/kg BW/h) and repeated administration of sufentanil (0.1  $\mu$ g/kg BW). The endotracheal tube was removed when the patients had regained adequate control over their airways and had a respiratory rate  $>10$  breaths/min, which usually occurred before the dressing was applied.

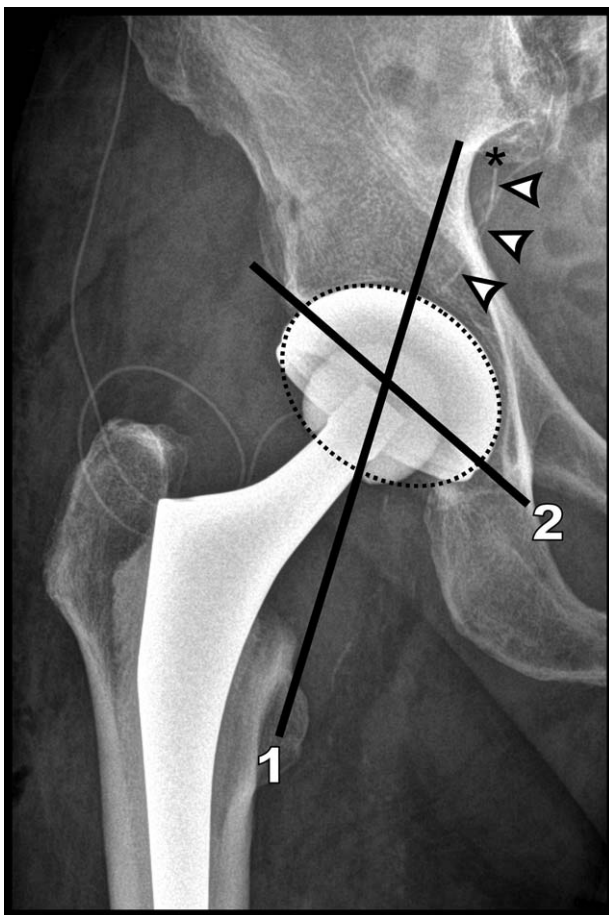
### 2.4. Spinal anesthesia

Spinal anesthesia was induced with the patient in a sitting position. The skin was anesthetized with mepivacaine 1%, the L4 spinous process identified by palpation based on a line connecting the superior iliac crests, and a 26-gauge spinal needle (Atraucan, B. Braun Melsungen, Melsungen, Germany) was inserted through the L4/L5 or L3/L4 interspace. When clear spinal fluid appeared in the hub, 0.5% isobaric bupivacaine (Carbostesin; AstraZeneca, London, UK) was injected.

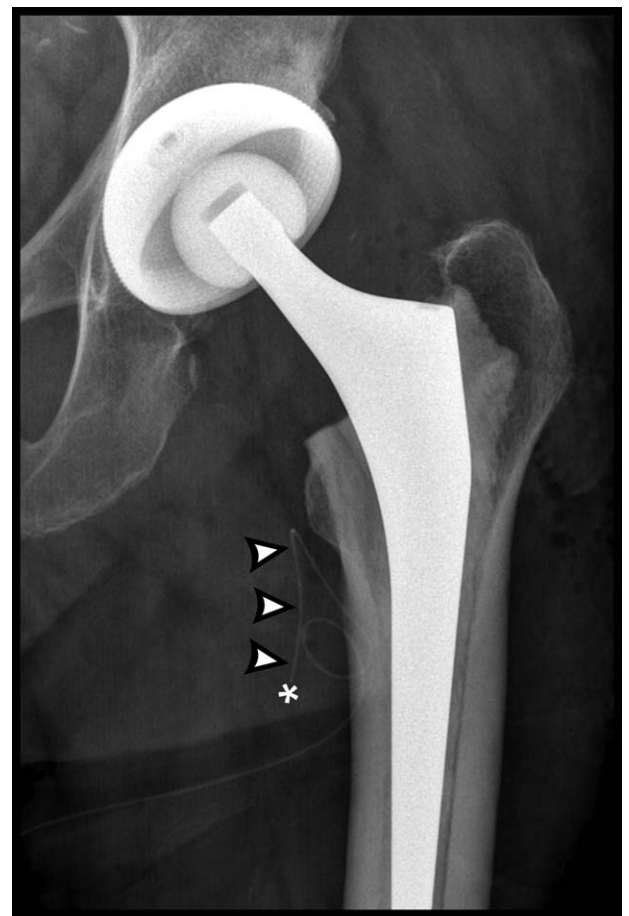
### 2.5. X-ray analysis of the course of radiopaque femoral nerve catheters

For standardized postoperative frontal radiographs of the operated hip joint, patients were adjusted to a supine position with their legs rotated inward. In cases of total hip replacement,

an X-ray in axial view of the femoral neck was performed. For standardized evaluation of the catheter tip position, a target region (region 0) and four additional neighboring regions (regions 1a, 1b, 2, 3) were predefined in frontal radiographs according to the following anatomical conditions. The target region is projected on the frontal radiographs on the hip joint (Fig. 1), which is crossed by the trunk of the femoral nerve running distally along the iliacus muscle and lateral to the psoas major muscle. Under the inguinal ligament, both muscles unite and cross the hip joint to insert on the lesser trochanter of the femur. To define the 4 neighboring regions, line 1 is drawn from the trochanter minor proximally through the center of the target region (=hip joint). In the center of the target region, line 1 crosses a second line 2, which runs parallel to the inguinal band (Fig. 1). Lines 1 and 2 divide the area around the target region into the following 4 neighboring regions: proximal-medial (1a) and proximal-lateral (1b) according to group 2 and group 3 of Capdevila et al,<sup>[10]</sup> respectively, and distal-lateral (2) and distal-medial (3). In cases of implanted endoprosthesis, the planes of this endoprosthesis were used equivalently to the hip joint bone as the target region. In cases where the catheter tip is overlapped by the socket of the prosthesis, an axial X-ray of the hip joint was used for better interpretation.



**Figure 1.** Dotted line marks the target region. Adjacent regions are divided by lines 1 and 2 (see the text for further details). Arrowheads mark the end portion of an out of plane femoral nerve catheter. Asterisk marks the catheter tip located in region 1a proximal-medial to the target region.



**Figure 2.** Arrowheads mark the end portion of an in plane femoral nerve catheter flipped distally. Asterisk marks the catheter tip located in region 3 distal-medial to the target region.

## 2.6. Data assessment

Patient characteristics were documented. Vital parameters and intravenously administered drugs were regularly recorded. The depth of needle puncture and catheter placement related to the skin were recorded. If the catheter became unintentionally dislodged during the postoperative period, only the data collected before dislodgement were used for statistical processing. X-ray evaluation was performed by 2 physicians working as consultant anesthetists (BB, JD) and controlled by a consultant radiologist (AS). First, a specific region (0–3) was documented on which the catheter tip was projected. If the catheter tip was located inside regions 1–3, the distance to region 0 was measured proximally (positive value) or distally (negative value). The path of the catheter was evaluated as “flipped distally,” if the orientation of the total 4.5-cm-long end of the catheter drifted  $>90^\circ$  from line 1 (Fig. 2). The incidence of pain near the hip joint scheduled for surgery at rest and under motion as well as the pain intensity were recorded by a study doctor (JD) using an NRS (0=no pain to 10=worst pain imaginable). Furthermore, the sensory quality of the nerve blockade in the innervated area of the femoral nerve (anterior aspect of the thigh) and of the lateral femoral cutaneous nerve (lateral aspect of the thigh) by the application of cold ice was recorded using a numerical rating scale (1=no anesthesia, 2=partial, 3=complete). Muscle strength based on hip flexion was graded on the 0 to 5 Medical



Research Council (MRC) scale<sup>[11]</sup> (5=normal strength, 4=still able to move against resistance, 3=only able to move against gravity, 2=only able to move with gravity eliminated, 1=flicker or trace contraction, 0=no movement). Mobilization was graded into 4 categories (0=lying, 1=sitting, 2=impaired walking, 3=free walking). All these parameters were documented preoperatively and on the first and second postoperative day (POD) by a study physician (JD). The use of local anesthetics and counts of on-demand boluses of anesthetics administered by the patient-controlled electric pump were documented on POD 1 and POD 2 and on the POD of catheter removal. In the ward of the trauma surgery department of the University Medical Center of Goettingen patients were given ibuprofen (600mg po, 3 times a day) and oxycodone/naloxone (10mg/5 mg po, twice daily) according to standardized protocol and after exclusion of contraindications. Symptoms and signs of nerve damage of the affected extremity were noted. Patient satisfaction of the specific analgesic procedure (Likert scale, 1=very unsatisfied to 10=very satisfied) was recorded.

### 2.7. Statistical analysis

The primary outcome was the location of the catheter tip inside the target region (yes/no). Secondary outcomes were the distance of the catheter tips to the target region and their location in neighboring regions. Further secondary outcomes were pain scores, patient satisfaction, consumption of local anesthetics via infusion pumps, loss of sensation, muscle strength, and postoperative grade of mobilization in the operated leg. The data were analyzed with the statistics program StatSoft (Dell Inc, Round Rock, TX). Continuous data were tested for a normal distribution using the Kolmogorov–Smirnov test. Normally distributed data were described by the mean and standard deviation, and other data were described by the median and range. Categorical data are reported as percentages. Normally distributed data were compared with Student *t* test, and non-normal data were compared with the Mann–Whitney *U* test. Categorical data were compared with Fisher exact test. A *P*-value <.05 was defined as statistically significant.

### 3. Results

Thirty-four patients were enrolled in the study. Sixteen patients were randomized into the IP group, and 18 patients were randomized into the OOP group. The groups did not differ with regard to anthropometric data, ASA classification, type of anesthesia or type of surgery (Table 1). Procedural data regarding

**Table 1**  
Patient characteristics, type of anesthesia, and type of surgery.

	IP n=16	OOP n=18	<i>P</i>
Age, y	69±13	65±19	.53
Gender male, %	44	44	.97
Weight, kg	79±9.4	76±14.7	.53
Height, cm	172±10	170±8	.58
ASA (I/II/III), n	0/10/6	3/10/5	.22
SPA/GA, n	11/5	10/8	.43
HTEP/PFN/DHS, n	15/2/0	16/1/1	.47

The values are expressed as mean ± standard deviation.

ASA=American Society of Anesthesiology, DHS=dynamic hip screw, GA=general anesthesia, HTEP=hip total endoprosthesis, IP=in plane, OOP=out of plane, PFN=proximal femoral nail, SPA=spinal anesthesia.

**Table 2**  
Placement and removal of femoral nerve catheters.

	IP n=16	OOP n=18	<i>P</i>
Attempts, n	1.1±0.3	1.2±0.6	.55
Needle insertion depth, cm	5.1±1.5	4.8±1.2	.62
Catheter insertion depth, cm	8.6±2.8	9.3±1.7	.33
POD of catheter removal	3.9±1.0	3.3±1.4	.26

The values are expressed as mean ± standard deviation.

IP=in plane, OOP=out of plane, POD=postoperative day.

the placement of femoral nerve catheters also showed no differences between groups (Table 2).

The catheter paths from postoperative X-rays on POD 2 to POD 5 were evaluated in 13 patients in the IP group and in 10 patients in the OOP group (Table 3). In both groups, we found no differences on radiographs in the location of the catheter tip within regions 0, 1a, 1b, 2, and 3 (*P*=.20). Within the target region catheter tips were located in 39% of the IP group and in 50% of the OOP group. In both groups, most of the catheter tips lying outside of the target region 0 were located in region 3 (distal-medial to the target region) (IP: 46%, OOP: 30%). Only 2 catheter tips of the OOP group (20%, region 1a) were found in proximally located regions (for example, see Fig. 1). The distance between the catheter tip and the target region was 0.00 cm [−3.80 to 3.84] and −1.19 cm [−12.27 to 0.00] (median [range]) in the OOP group and the IP group, respectively (*P*=.045). Catheters were flipped distally more often in the IP group (IP: 61.5%, OOP: 10.0%; *P*=.01; for example, see Fig. 2).

Table 4 summarizes the results of loss of sensation and muscle strength at POD 1 and POD 2. At POD 1, complete loss of sensation (grade 2) was more often found in the OOP group at the anterior and lateral aspect of the thigh than in the IP group. This tendency disappeared at POD 2. For muscle strength in hip flexion and grade of mobilization, we found no differences at POD 1 and 2 between groups (Table 4).

The preoperative incidence of pain in the hip joint scheduled for surgery was similar in both groups (Table 5). However, reported preoperative pain intensity at rest was higher in patients

**Table 3**  
X-ray analysis of nerve catheter paths.

	IP n=13	OOP n=10	<i>P</i>
X-ray on			
POD 2	7 (53.9%)	6 (60.0%)	
POD 3	4 (30.8%)	3 (30.0%)	
POD 4	1 (7.7%)	1 (10.0%)	.84
POD 5	1 (7.7%)	0 (0.0%)	
Catheter tips			
target region 0, n	5 (38.5%)	5 (50.0%)	
region 1a, n	0 (0.0%)	2 (20.0%)	
region 1b, n	0 (0.0%)	0 (0.0%)	.20
region 2, n	2 (15.4%)	0 (0.0%)	
region 3, n	6 (46.2%)	3 (30.0%)	
Distance to target region, cm	−1.19 [−12.27 to 0.00]	−0.0 [−3.80 to 3.84]	.045
Catheters flipped distally, n	8 (61.5%)	1 (10.0%)	.01

The values are expressed as median [range].

IP=in plane, OOP=out of plane, POD=postoperative day.

**Table 4**  
Grades of loss of sensation, muscle strength, and mobilization.

	IP n=16	OOP n=18	P
Loss of sensation			
Anterior aspect of the thigh on POD 1 (grade 0/1/2), n	3/12/1	2/8/8	.04
Anterior aspect of the thigh on POD 2 (grade 0/1/2), n	7/8/1	7/8/3	.64
Lateral aspect of the thigh on POD 1 (grade 0/1/2), n	4/11/1	1/11/6	.07
Lateral aspect of the thigh on POD 2 (grade 0/1/2), n	7/8/1	7/10/1	.95
Muscle strength			
POD 1 (MRC grade 1/2/3/4/5), n	0/2/1/13/0	0/2/2/14/0	.88
POD 2 (MRC grade 1/2/3/4/5), n	0/0/1/1/14/0	0/0/0/1/17/0	.56
Mobilization			
POD 1 (0/1/2/3), n	0/3/13/0	0/9/9/0	.06
POD 2 (0/1/2/3), n	0/2/13/1	0/3/15/0	.54

IP=in plane, MRC=medical research council, NRS=numeric rating scale, OOP=out of plane, POD=postoperative day.

in the OOP group (mean ± SD, NRS IP: 1.6 ± 1.2; OOP: 2.6 ± 1.9; P=.05), while NRS scores under motion were similar in both groups (NRS IP: 5.4 ± 1.5; OOP: 5.8 ± 1.8; P=.41). At POD 1, we found no differences in the incidence and intensity of pain between the groups (Table 5). At POD 2, pain was reported in all patients in the OOP group and in 75% of patients in the IP group (P=.02), while pain intensity at rest was higher in the OOP group (NRS IP: 1.3 ± 0.6; OOP 1.9 ± 1.4; P=.01). Local anesthetic consumption and counts of additional on-demand boluses of local anesthetics were equal in both groups (Table 5).

Femoral nerve catheters were removed after 3.9 days (±1.0) in the IP group and after 3.3 days (±1.4) in the OOP group (P=.26). Accidental complete dislodgement of the catheter was observed in

**Table 5**  
Perioperative pain in the operated hip joint and local anesthetics consumption.

	IP n=16	OOP n=18	P
Preoperative pain			
Patients with pain, n	16 (100%)	16 (88.9%)	.17
Intensity at rest (NRS 1–10)	1.6 ± 1.2	2.6 ± 1.9	.05
Intensity under motion (NRS 1–10)	5.4 ± 1.5	5.8 ± 1.8	.41
Postoperative pain			
Patients with pain on POD 1, n	14 (87.5%)	18 (100%)	.12
Intensity at rest on POD 1 (NRS 1–10)	1.6 ± 1.1	2.3 ± 5.2	.16
Intensity under motion on POD 1 (NRS 1–10)	2.9 ± 1.2	3.6 ± 2.0	.31
Patients with pain on POD 2, n	12 (75%)	18 (100%)	.02
Intensity at rest on POD 2 (NRS 1–10)	1.3 ± 0.6	1.9 ± 1.4	.01
Intensity under motion on POD 2 (NRS 1–10)	2.0 ± 1.2	2.9 ± 1.8	0.15
Local anesthetics consumption			
Rate of infusion on POD 1 (mL/h)	5.8 ± 2.0	6.0 ± 1.0	.73
Boluses requested on POD 1 (n)	5.5 ± 4.2	5.2 ± 7.0	.89
Rate of infusion on POD 2 (mL/h)	4.0 ± 3.5	3.7 ± 3.2	.81
Boluses requested on POD 2 (n)	3.4 ± 4.5	2.2 ± 3.6	.37

The values are expressed as mean ± SD.

IP=in plane, NRS=numeric rating scale, OOP=out of plane, POD=postoperative day.

1 IP patient (6.25%) and in 2 OOP patients (11.11%). No patient showed symptoms or signs of nerve damage on the operated extremity. Patients in the IP group (9.5 ± 0.9) rated their analgesic procedure as more satisfactory than those in the OOP group (8.4 ± 1.8; P=.03).

#### 4. Discussion

In this study, we evaluated the course of radiopaque femoral nerve catheters on the basis of postoperative radiographs of the hip joint placed by IP vs OOP techniques. Catheter tips placed via the OOP technique were located closer to our predefined target region near the trunk of the femoral nerve, while IP catheters flipped distally more often. Surprisingly, these different positions of radiopaque femoral nerve catheters had no impact on the postoperative analgesic quality in either group.

Continuous blockade of the femoral nerve is a reliable form of postoperative analgesic therapy after hip surgery and rarely leads to complications.<sup>[1–3]</sup> There is great interest in evaluating the position of the catheter tip after insertion.<sup>[5]</sup> However, until now, there have been no studies on whether the technique used for ultrasound-guided catheter placement (IP vs OOP) may influence the path and position of the tip of the femoral catheter and have an impact on postoperative pain. Capdevila and coworkers<sup>[10]</sup> examined the position of the tip of 3-in-1-catheters for continuous 3-in-1-block in pelvic radiographs after injection of contrast media through the catheters. The technique of needle insertion was comparable to the OOP technique used in our study, with a path parallel to the nerve. However, in contrast to our results, the catheters were advanced 17.5 cm over the needle tip. In accordance with our findings, more than 90% of the catheter tips placed via this technique were located proximal to the hip joint, while rotation of the catheter far away from the femoral nerve was only sporadically found.<sup>[10]</sup> In our study, the catheters placed via the IP technique rotated distally in relation to the hip joint in more than 60% of cases, and the tip of the catheter was more often found to be located distal of the target region of the femoral nerve. This supports the fear that many catheters placed via the IP technique may move during their insertion perpendicular to the nerve, thus taking unforeseeable paths and ultimately being positioned beyond the nerve.<sup>[4]</sup> Confirming results has been shown in a magnetic resonance imaging study comparing placement of popliteal sciatic nerve catheters in SAX-IP vs SAX-OOP technique.<sup>[12]</sup> Catheters placed via the IP technique had a four times larger relative risk for displacement compared to OOP catheters.<sup>[12]</sup>

However, in the case of a distally misplaced femoral nerve catheter, we would have expected incomplete blockade because the trunk of the femoral nerve divides into branches in the inguinal area distal to the target region. Surprisingly, although catheter tips located significantly more distally rotated and were far from the target region, we found the same quality of postoperative analgesia in both groups. Additionally, 2 other studies comparing IP and OOP techniques for the placement of femoral nerve catheters found no differences in postoperative analgesia.<sup>[6,7]</sup> In our study, we found higher pain levels at rest at POD 2 in the OOP group. However, these patients already had preoperatively higher pain levels; thus, this higher pain level as well as the lower satisfaction with the technique in the OOP group may be influenced by these circumstances. This interpretation is supported by the fact that neither local anesthetic consumption nor the number of on-demand boluses differed between the groups. Therefore, we concluded that, to some

extent, the position of the femoral catheter tip along the medio-lateral or cranio-caudal axis does not influence postoperative analgesia. This conclusion is supported by 2 further studies that investigated the position of 3-in-1-catheters by computed tomography<sup>[13]</sup> and motor responses upon electrical stimulation.<sup>[14]</sup> In both studies, various positions along the femoral nerve could be observed, while in all patients, a sufficient sensory blockade could be achieved.<sup>[13,14]</sup>

Several studies have concluded that the essential factor for an effective blockade of the femoral nerve is the application of the local anesthetic agent in the compartment under the fascia iliaca.<sup>[7,10,13,15–17]</sup> The femoral nerve lies in this tight compartment under the fascia iliaca running between the iliacus and the psoas muscles and close to the lateral femoral cutaneous nerve, which runs along the iliacus muscle more laterally. In the classical fascia iliaca compartment block, needle guidance is characterized by a “double pop” technique to position the needle tip under the fascia iliaca. In our study and in previous ultrasound-guided studies, the local anesthetic is injected directly into this compartment by visualization, and sufficient analgesia is achieved independent of the technique (IP vs OOP).<sup>[6,7]</sup>

The fascia iliaca block performed with the “double pop” technique more often provides a combined blockade of the femoral nerve and the lateral femoral cutaneous nerve than stimulation-guided 3-in-1-blockade.<sup>[16]</sup> It can be assumed that the fascia iliaca is not always perforated by the injection needle via the latter technique. Subsequently, the injected local anesthetic cannot spread in the compartment under the fascia iliaca from the medially located femoral nerve to the lateral femoral cutaneous nerve.<sup>[16]</sup> Comparing ultrasound-guided placement of femoral nerve catheters in the IP or OOP technique, our results indicate that a combined blockade of the femoral nerve and the lateral femoral cutaneous nerve can be more often achieved using the OOP technique. This may be explained by the different paths of the catheter depending on the ultrasound-guided technique employed. In the OOP group, 90% of the catheter tips were located proximal toward the femoral and lateral femoral cutaneous nerves. This may favor a distribution of local anesthetics under the fascia iliaca toward both femoral nerves. In cases of distally flipped catheters placed by the IP technique, the proximal-lateral distribution of local anesthetics may not be possible. Rotation of the catheter distally in the IP technique can be potentially avoided by advancing the catheter tip only a few centimeters over the needle tip and the target region of the nerve. Different depths of insertion of sciatic nerve catheters have already been compared.<sup>[18]</sup> In this study, catheters were placed via the IP technique and advanced either 0 to 1 cm or 5 to 6 cm over the needle tip. With regard to postoperative pain, no differences were found in either group. However, catheters inserted a short distance frequently become dislodged.<sup>[18]</sup> The latter may occur more frequently in the femoral region, in which the catheter—in contrast to the sciatic nerve enclosed by muscles—is solely surrounded and fixed by skin and a thin layer of connective tissue.

There are some limitations to our study. In addition to the relatively small trial, we had no placebo control group to differentiate the effect of the procedure of placing the nerve catheter. Due to procedural reasons, the study physician performing examinations and interviews postoperatively could not be blinded for used ultrasound guided technique. Furthermore, additional consumption of oral analgesics was not documented.

We conclude that femoral nerve catheters inserted with ultrasound guidance via the IP technique frequently rotate distally compared with catheters inserted via the OOP technique. Furthermore, the tips of these IP catheters are located further away from the trunk of the femoral nerve. However, we found no influence of either technique on postoperative analgesia. Therefore, we cannot provide clear advice for the use of either the IP or OOP ultrasound-guided technique for placing femoral nerve catheters.

## Acknowledgment

The authors acknowledge support by the German Research Foundation and the Open Access Publication Funds of the Goettingen University.

## Author contributions

BB: conceptualization, data curation, formal analysis, investigation, methodology, project administration, resources, supervision, validation, visualization, writing – original draft, writing – review & editing

JD: conceptualization, data curation, formal analysis, investigation, methodology, writing – original draft

KK: formal analysis, investigation, project administration, validation, writing – original draft

JH: conceptualization, data curation, formal analysis, investigation, methodology, project administration, software, supervision, validation, writing – original draft, writing – review & editing

AS: formal analysis, investigation, project administration, visualization, writing – original draft

MB: conceptualization, investigation, methodology, project administration, supervision, validation, writing – original draft, writing – review & editing

AM: conceptualization, data curation, formal analysis, investigation, methodology, resources, software, supervision, validation, visualization, writing – original draft, writing – review & editing

IB: conceptualization, data curation, formal analysis, investigation, methodology, project administration, resources, software, supervision, validation, writing – original draft, writing – review & editing

All authors had full access to all of the data and can take responsibility for the integrity of the data and the accuracy of the data analysis.

**Conceptualization:** Benedikt Büttner, Joschka Dracklé, José Hinz, Martin Bauer, Ashham Mansur, Ingo Bergmann.

**Data curation:** Benedikt Büttner, Joschka Dracklé, José Hinz, Ashham Mansur, Ingo Bergmann.

**Formal analysis:** Benedikt Büttner, Joschka Dracklé, Katalin Kristof, José Hinz, Alexander Schwarz, Ashham Mansur, Ingo Bergmann.

**Investigation:** Benedikt Büttner, Joschka Dracklé, Katalin Kristof, José Hinz, Alexander Schwarz, Martin Bauer, Ashham Mansur, Ingo Bergmann.

**Methodology:** Benedikt Büttner, Joschka Dracklé, José Hinz, Martin Bauer, Ashham Mansur, Ingo Bergmann.

**Project administration:** Benedikt Büttner, Katalin Kristof, José Hinz, Alexander Schwarz, Martin Bauer, Ingo Bergmann.

**Resources:** Benedikt Büttner, Ashham Mansur, Ingo Bergmann.

**Software:** José Hinz, Ashham Mansur, Ingo Bergmann.

**Supervision:** Benedikt Büttner, José Hinz, Martin Bauer, Ashham Mansur, Ingo Bergmann.

**Validation:** Benedikt Büttner, Katalin Kristof, José Hinz, Martin Bauer, Ashham Mansur, Ingo Bergmann.

**Visualization:** Benedikt Büttner, Alexander Schwarz, Ashham Mansur.

**Writing – original draft:** Benedikt Büttner, Joschka Dracklé, Katalin Kristof, José Hinz, Alexander Schwarz, Martin Bauer, Ashham Mansur, Ingo Bergmann.

**Writing – review & editing:** Benedikt Büttner, José Hinz, Martin Bauer, Ashham Mansur, Ingo Bergmann.

## References

- [1] Richman JM, Liu SS, Courpas G, et al. Does continuous peripheral nerve block provide superior pain control to opioids? A meta-analysis. *Anesth Analg* 2006;102:248–57.
- [2] Capdevila X, Pirat P, Bringuier S, et al. Continuous peripheral nerve blocks in hospital wards after orthopedic surgery: a multicenter prospective analysis of the quality of postoperative analgesia and complications in 1,416 patients. *Anesthesiology* 2005;103:1035–45.
- [3] Chaudet A, Bouhours G, Rineau E, et al. Impact of preoperative continuous femoral blockades on morphine consumption and morphine side effects in hip-fracture patients: a randomized, placebo-controlled study. *Anaesth Crit Care Pain Med* 2016;35:37–43.
- [4] Ilfeld BM, Fredrickson MJ, Mariano ER. Ultrasound-guided perineural catheter insertion: three approaches but few illuminating data. *Reg Anesth Pain Med* 2010;35:123–6.
- [5] Elsharkawy H, Maheshwari A, Farag E, et al. Development of technologies for placement of perineural catheters. *J Anesth* 2016;30:138–47.
- [6] Wang AZ, Gu L, Zhou QH, et al. Ultrasound-guided continuous femoral nerve block for analgesia after total knee arthroplasty: catheter perpendicular to the nerve versus catheter parallel to the nerve. *Reg Anesth Pain Med* 2010;35:127–31.
- [7] Fredrickson MJ, Danesh-Clough TK. Ultrasound-guided femoral catheter placement: a randomized comparison of the in plane and out of plane techniques. *Anaesthesia* 2013;68:382–90.
- [8] Grant SA, Nielsen KC, Greengrass RA, et al. Continuous peripheral nerve block for ambulatory surgery. *Reg Anesth Pain Med* 2001;26:209–14.
- [9] Marhofer D, Marhofer P, Triffirer L, et al. Dislocation rates of perineural catheters: a volunteer study. *Br J Anaesth* 2013;111:800–6.
- [10] Capdevila X, Biboulet P, Morau D, et al. Continuous three-in-one block for postoperative pain after lower limb orthopedic surgery: where do the catheters go? *Anesth Analg* 2002;94:1001–6.
- [11] Medical Research Council Aids to Examination of the Peripheral Nervous System. Memorandum no. 45. Her Majesty's Stationery Office, London:1976.
- [12] Hauritz RW, Pedersen EM, Linde FS, et al. Displacement of popliteal sciatic nerve catheters after major foot and ankle surgery: a randomized controlled double-blinded magnetic resonance imaging study. *Br J Anaesth* 2016;117:220–7.
- [13] Ganapathy S, Wasserman RA, Watson JT, et al. Modified continuous femoral three-in-one block on postoperative pain and knee rehabilitation after unilateral total knee arthroplasty. *Anesth Analg* 1999;89:1197–202.
- [14] Pham Dang C, Difalco C, Guilley J, et al. Various possible positions of conventional catheters around the femoral nerve revealed by neurostimulation. *Reg Anesth Pain Med* 2009;34:285–9.
- [15] Dalens B, Vanneville G, Tanguy A. Comparison of fascia iliaca compartment block with the 3 in 1 block in children. *Anesth Analg* 1989;69:705–13.
- [16] Capdevila X, Biboulet P, Bouregba M, et al. Comparison of the three-in-one and fascia iliaca compartment blocks in adults: clinical and radiographic analysis. *Anesth Analg* 1998;86:1039–44.
- [17] Swenson JD, Davis JJ, Stream JO, et al. Local anesthetic injection deep to the fascia iliaca at the level of the inguinal ligament: the pattern of distribution and effects on the obturator nerve. *J Clin Anesth* 2015;27:652–7.
- [18] Ilfeld BM, Sandhu NS, Loland VJ, et al. Ultrasound-guided (needle-in-plane) perineural catheter insertion: the effect of catheter-insertion distance on postoperative analgesia. *Reg Anesth Pain Med* 2011;36:261–5.