

# A Case Report of the Successful Conversion of One of the Longest Standing KineSpring Joint Unloading Systems

Gerrit Steffen Maier<sup>1</sup>, Uwe Maus<sup>1</sup>, Konstantin Horas<sup>2</sup>, Frank Hartmann<sup>3</sup>, Djordje Lazovic<sup>1</sup>

## Learning Point for the Article:

The KineSpring joint unloading system is possible treatment option for younger patients with mild to moderate osteoarthritis of the knee reluctant to total knee replacement, without compromising further surgical options

## Abstract

**Introduction:** We present the case of a successful conversion of a KineSpring joint unloading system to a total knee replacement. This is, to the best of our knowledge, the so far longest surviving implant in Germany that has been successfully converted.

**Case Report:** The patient is a 75-year-old woman who presented to clinic with problems of her left knee. She had a KineSpring joint unloading system implanted in March 2011 for severe medial osteoarthritis of her left knee that was unresponsive to maximal conservative treatment. After nearly 7 pain-free years, we successfully converted the KineSpring joint unloading system into a total knee replacement (Vega, Aesculap, Germany).

**Conclusion:** The KineSpring joint unloading system is possible treatment option for younger patients with mild-to-moderate osteoarthritis of the knee reluctant to total knee replacement, without compromising further surgical options.

**Keywords:** Arthroplasty, joint, knee, replacement.

## Introduction

We present the case of a successful conversion of a KineSpring joint unloading system to a total knee replacement. This is, to the best of our knowledge, the so far longest surviving implant in Germany that has been successfully converted. Osteoarthritis of the knee is a degenerative disease affecting approximately 13% of females and 10% of males aged 60 years and older [1]. Due to demographic changes and an increase in physical activity even in an older population, the incidence of knee osteoarthritis is rising. Early phase knee osteoarthritis is often limited to a single compartment. The medial compartment bears over two-thirds of the load acting on the knee during normal gait, consequently, increasing the risk of this compartment to joint degeneration [2,3]. The knee adduction moment, a well-known indicator of maximum joint

load in the medial compartment endured during normal gait, is higher in patients with knee osteoarthritis compared to a healthy population [4, 5]. Chronic excess joint loading is associated with greater osteoarthritic pain severity and faster disease progression [6, 7, 8]. Unloading of the medial compartment may improve knee osteoarthritic symptoms and slow down disease progression by providing a local mechanical environment that encourages articular cartilage healing [4, 9]. Many conservative treatments, for example, lateral wedge insoles and valgus knee braces, aim to reduce medial knee compartment joint loading forces. Unfortunately, long-term effect of conservative treatment patterns is often poor largely due to the patient compliance challenges [10,11]. The KineSpring Knee Implant System (Moximed Inc., Hayward, CA, USA) is an implantable extra-articular, extracapsular

Access this article online

Website:  
www.jocr.co.in

DOI:  
2250-0685.1152

## Author's Photo Gallery



Dr. Gerrit Steffen Maier



Dr. Uwe Maus



Dr. Konstantin Horas



Dr. Frank Hartmann



Dr. Djordje Lazovic

<sup>1</sup>Department of Orthopaedic Surgery, Pius-Hospital, Carl-von-Ossietzky-University, Georgstrasse 12, 26121 Oldenburg, Germany,

<sup>2</sup>Department of Orthopaedic Surgery, König Ludwig Haus, Julius-Maximilians-University, Würzburg, Germany,

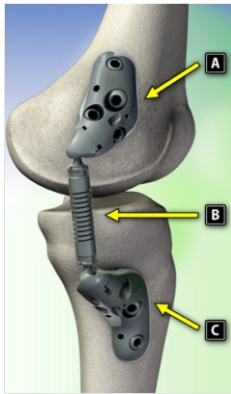
<sup>3</sup>Department of Orthopaedic Surgery, Gemeinschaftsklinikum Mittelrhein, Ev. Stift Koblenz, Germany,

### Address of Correspondence:

Dr. Gerrit Steffen Maier,

Department of Orthopaedic Surgery, Pius-Hospital, Carl-von-Ossietzky-University, Georgstrasse 12, 26121 Oldenburg, Germany.

E-mail: gerrit.maier@uni-oldenburg.de



**Figure 1:** Components of the KineSpring System. (a) Femoral base, (b) absorber, and (c) tibial base. Reproduced with permission from Moximed.

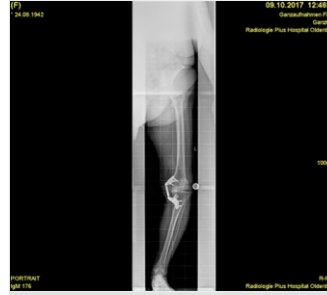prosthesis intended to alleviate knee osteoarthritis symptoms by reducing medial knee compartment loading while overcoming the limitations of traditional joint unloading therapies [4]. This device consists of two base plates, one fixed to the distal femur and the other one to the proximal tibia with an absorber piece in between (Fig. 1). This reduces the load on the knee up to 30 lbs during full extension and is designed primarily

for patients with mild-to-moderate knee osteoarthritis [4]. Several case series examined the effectiveness of the KineSpring system and demonstrated

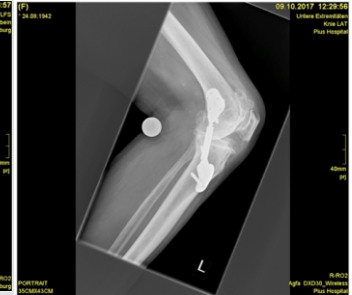
the longitudinal positive outcomes with follow-up periods of 5 years [12]. The presented study reports a case of a patient who underwent successful conversion of the KineSpring system to a total knee replacement nearly 7 years after implantation of the KineSpring system.

**Case Report**

The patient is a 75-year-old woman who presented to clinic with problems of her left knee. She had a KineSpring joint unloading system implanted in November 2011 for severe medial osteoarthritis of her left knee that was unresponsive to maximal conservative treatment (Fig. 2 and 3). The KineSpring procedure followed standard techniques that have already been described [10]. The patient remained hospitalized for 3 days following the procedure. She reported immediate arthritic pain relief postoperatively. For more than 6 years, she remained pain free and the KineSpring joint unloading system functioned well. At the end of October 2017, the patient presented to clinic with increasing the left knee pain. She reported increasing pain with weight-bearing and knee flexion and had been taking anti-inflammatory medication as needed. The knee was stable in varus and valgus testing, although testing was rather difficult due to the KineSpring implant. Radiographically, there were signs of a severe osteoarthritis of the lateral and the



**Figure 4:** X-ray (AP) of the left knee 7 years after implantation of the KineSpring system.

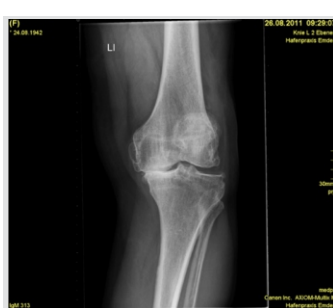

**Figure 5:** X-ray (lat.) of the left knee 7 years after implantation of the KineSpring system.

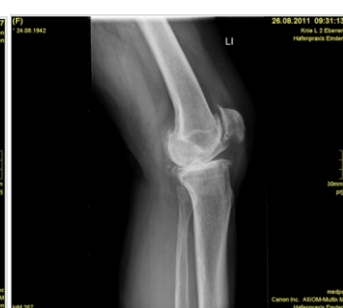patellofemoral compartment (Fig. 4 and 5). In November 2017, the patient underwent conversion of the KineSpring system to a total knee replacement (Vega Femur Size 5 narrow, Columbus Tibia Size 2, PE-Inlay PS 12 mm, Aesculap, Germany). The procedure was performed without any difficulties. Removal of the KineSpring system added an additional 11 min to the operation time. Implementation of the Columbus total knee replacement (Aesculap, Germany) followed our standard techniques and was not complicated by the former KineSpring system. Post-operative radiographs showed that the femoral and tibial implants were placed properly (Fig. 6 and 7). Post-operative course was good, and the patient was discharged 10 days postoperatively to rehabilitation. 3 months after surgery, she is pain free, mobilizing without any walking aid and with a more than satisfactory range of motion of her left knee.

**Discussion**

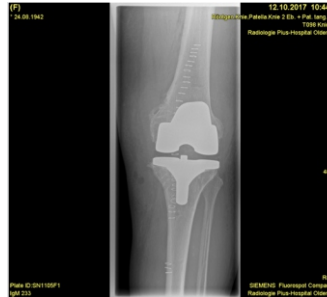
In this case report, we describe the successful conversion of a KineSpring joint unloading system to a total knee replacement. Excessive mechanical stress across the knee joint leads to the onset and progression of knee osteoarthritis [13,14]. A change of the adverse biomechanics that produced the predisposing conditions for osteoarthritis is a key to provide lasting relief from symptoms and to slow down progression of knee osteoarthritis [3,15]. A gait simulation study demonstrated that KineSpring can successfully unload the medial compartment of the knee [16]. Unlike high tibial osteotomy, the KineSpring procedure does not involve significant bone removal and reshaping in an effort to shift loading from the affected to the



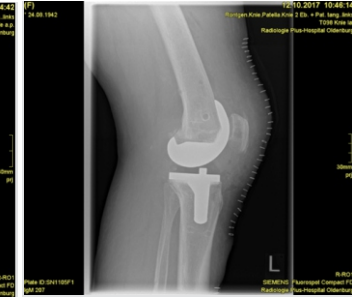
**Figure 2:** X-ray of the left knee AP before the KineSpring procedure.



**Figure 3:** X-ray of the left knee lat. before the KineSpring procedure.



**Figure 6:** X-ray of the left knee (AP) after 2 days successful conversion to a total knee replacement



**Figure 7:** X-ray of the left knee (lat.) after 2 days successful conversion to a total knee replacement.



unaffected compartment. High tibial osteotomy is a very invasive surgery, requiring an average of approximately 10 days of post-operative hospitalization [17]. A substantial delay in return to work of typically 3 months has been described [18]. Significant procedural risks, such as infection, thrombosis, delayed or non-union, and peroneal nerve lesion, limit the utility of high tibial osteotomy [19]. Due to these reasons, many patients refuse to undergo high tibial osteotomy although they were unresponsive to conservative treatments. Furthermore, many patients are not willing to consider total knee replacement due to the invasiveness of the procedure, extended recovery period, and complication risk [20]. As a result, approximately 3.6 million patients with osteoarthritis of the knee in the United States alone linger in a treatment gap, characterized by failure of conservative treatment, and refusal to undergo total knee replacement [11]. For these patients, the KineSpring system is an option to fill this therapeutic gap. Key component of the KineSpring implant is a cobalt/cobalt-chrome alloy absorber with the ability to reduce the load in the affected medial compartment during gait by up to 13 kg [21]. The absorber resides in the subcutaneous tissue and is attached to titanium alloy femoral and tibial bases. The KineSpring system is extracapsular and extra-articular with no removal of bone, ligament, or cartilage required [21]. Despite the simplicity of the implantation, surgeons must be familiar with appropriate revision techniques. Further, treatment options may not be compromised by the KineSpring system. We successfully converted one of the longest standing KineSpring joint unloading systems into a total knee replacement. The

explanation of the absorber system was easily done, without complicating the standard procedure of total knee replacement. After the primary implantation of the KineSpring absorber, our patient was pain free for nearly 7 years, enjoying her daily life. Consequently, the KineSpring is an alternative treatment for mild-to-moderate osteoarthritis of the knee, especially for younger patients reluctant to more invasive procedures.

### Conclusion

With this case report, we were able to show that the KineSpring joint unloading system is an easily reversible procedure that maintains the anatomical integrity of the knee joint, enabling orthopedic surgeons to help patients with medial osteoarthritic knee pain and reluctance to undergo total knee replacement. In our case, the patient gained 6 pain-free years before a total knee replacement was performed. We showed that explanation of the KineSpring system was safe and easy, without compromising further surgical options like total knee replacement. In sum, we can say the KineSpring joint unloading system is not the substitute of total knee arthroplasty, but a temporary option.

### Clinical Message

The KineSpring joint unloading system is a possible treatment option for younger patients with mild-to-moderate osteoarthritis of the knee reluctant to total knee replacement, without compromising fruitful surgical outcomes with other options.

### References

- Zhang Y, Jordan JM. Epidemiology of osteoarthritis. *Clin Geriatr Med* 2010;26:355-69.
- Ledingham J, Regan M, Jones A, Doherty M. Radiographic patterns and associations of osteoarthritis of the knee in patients referred to hospital. *Ann Rheum Dis* 1993;52:520-6.
- Madonna V, Condello V, Piovan G, Screpis D, Zorzi C. Use of the kinespring system in the treatment of medial knee osteoarthritis: Preliminary results. *Joints* 2015;3:129-35.
- Clifford AG, Gabriel SM, O'Connell M, Lowe D, Miller LE, Block JE. The Kine Spring (®) knee implant system: An implantable joint-unloading prosthesis for treatment of medial knee osteoarthritis. *Med Devices (Auckl)* 2013;6:69-76.
- Baliunas AJ, Hurwitz DE, Ryals AB, Karrar A, Case JP, Block JA, et al. Increased knee joint loads during walking are present in subjects with knee osteoarthritis. *Osteoarth Cartilage* 2002;10:573-9.
- Andriacchi TP, Koo S, Scanlan SF. Gait mechanics influence healthy cartilage morphology and osteoarthritis of the knee. *J Bone Joint Surg Am* 2009;91:95-101.
- Thorpe LE, Sumner DR, Wimmer MA, Block JA. Relationship between pain and medial knee joint loading in mild radiographic knee osteoarthritis. *Arthritis Rheum* 2007;57:1254-60.
- Sharma L. The role of varus and valgus alignment in knee osteoarthritis. *Arthritis Rheum* 2007;56:1044-47.
- Waller C, Hayes D, Block JE, London NJ. Unload it: The key to the treatment of knee osteoarthritis. *Knee Surg Sports Traumatol Arthrosc* 2011;19:1823-9.
- Clifford A, O'Connell M, Gabriel S, Miller LE, Block JE. The kine spring load absorber implant: Rationale, design and

- biomechanical characterization. *J Med Eng Technol* 2011;35:65-71.
11. London NJ, Miller LE, Block JE. Clinical and economic consequences of the treatment gap in knee osteoarthritis management. *Med Hypotheses* 2011;76:887-92.
  12. Hayes DA, Waller CS, Li CS, Vannabouathong C, Sprague S, Bhandari M. Safety and feasibility of a kinespring knee system for the treatment of osteoarthritis: A case series. *Clin Med Insights Arthritis Musculoskelet Disord* 2015;8:47-54.
  13. Radin EL. Who gets osteoarthritis and why? *J Rheumatol* 2004;70:10-5.
  14. Block JA, Shakoor N. The biomechanics of osteoarthritis: Implications for therapy. *Curr Rheumatol Rep* 2009;11:15-22.
  15. Brandt KD, Dieppe P, Radin EL. Etiopathogenesis of osteoarthritis. *Rheum Dis Clin North Am* 2008;34:531-59.
  16. Gabriel SM, Clifford AG, Maloney WJ, O'Connell MK, Tornetta P 3rd. Unloading the osteoarthritic knee with a novel implant system. *J Appl Biomech* 2013;29:647-54.
  17. Floerkemeier S, Staubli AE, Schroeter S, Goldhahn S, Lobenhoffer P. Outcome after high tibial open-wedge osteotomy: A retrospective evaluation of 533 patients. *Knee Surg Sports Traumatol Arthrosc* 2013;21:170-80.
  18. Schroter S, Mueller J, van Heerwaarden R, Lobenhoffer P, Stockle U, Albrecht D. Return to work and clinical outcome after open wedge HTO. *Knee Surg Sports Traumatol Arthrosc* 2013;21:213-9.
  19. Dowd GS, Somayaji HS, Uthukuri M. High tibial osteotomy for medial compartment osteoarthritis. *Knee* 2006;13:87-92.
  20. Hawker GA, Wright JG, Badley EM, Coyte PC. Perceptions of and willingness to consider, total joint arthroplasty in a population-based cohort of individuals with disabling hip and knee arthritis. *Arthritis Rheum* 2004;51:635-41.
  21. Bowditch M, Miller LE, Block JE. Successful two-stage revision of a Kine Spring® joint unloading implant: A case study. *Int Med Case Rep J* 2012;5:91-5.

**Conflict of Interest:** Nil  
**Source of Support:** Nil

**Consent:** The authors confirm that Informed consent of the patient is taken for publication of this case report

#### How to Cite this Article

Maier G S, Maus U, Horas K, Hartmann F, Lazovic D. A Case Report of the Successful Conversion of One of the Longest Standing KineSpring Joint Unloading Systems. *Journal of Orthopaedic Case Reports* 2018. July-Aug ; 8(4): 41-44.

