

Trauma and reconstruction

## Acute management of Fournier's gangrene in the setting of massive lymphedema

Katherine Dowd<sup>a,\*</sup>, Belur Patel<sup>a</sup>, Zoe Blumenthal<sup>b</sup>, Nelson Rodriguez-Unda<sup>a</sup>, Erin Bird<sup>a</sup>

<sup>a</sup> Baylor Scott and White Health, United States

<sup>b</sup> Texas AM University College of Medicine, United States



### ARTICLE INFO

#### Keywords:

Scrotal reconstruction  
Fournier's gangrene  
Filariasis

### ABSTRACT

Chronic, massive lymphedema of the scrotum can pose therapeutic challenges to the urologist. Uncommonly encountered in developed countries, this dilemma can be amplified in the emergent setting. Along with voiding limitations and pain, lymphedema can lead to recurrent subcutaneous infections. Recurrence of infections can lead to a cycle of worsening lymphedema. We report a case of Fournier's gangrene complicated by massive lymphedema of the scrotum and right leg in a 43 year-old man from Panama, presumably filarial. This case highlights the surgical management of a patient requiring emergent intervention and multidisciplinary approach of reconstructive repair in the acute care setting.

### Introduction

Although uncommonly encountered in developed countries, chronic, massive lymphedema of the scrotum can pose therapeutic challenges to the urologist. Massive scrotal lymphedema is caused by obstruction, hypoplasia, or aplasia of the lymphatic vessels that are responsible for draining the scrotum.<sup>1</sup> Obstruction of lymphatic flow leads to ductal dilation, hypertrophy of the connective tissue, chronic inflammation, and interstitial edema.<sup>1</sup> Lymphedema can be categorized as primary (idiopathic) or secondary in nature. Secondary lymphedema can occur after a surgical operation, radiation, infections, and tumors.<sup>2</sup> The most common cause of secondary lymphedema is infection, and the most common infections leading to scrotal lymphedema is lymphogranuloma venereum or filarial infestation.<sup>1</sup> Along with voiding limitations and pain, lymphedema can lead to recurrent subcutaneous infections and dermatolymphangioadenitis in the affected area.<sup>1</sup> Recurrence of infections can lead to a cycle of worsening lymphedema due to impaired lymphatic drainage during active infection or adenitis.<sup>3</sup>

### Case presentation

A 43 year-old male from Panama presented to the emergency department with fever, tachycardia, and increasing swelling and drainage from his scrotum. His medical history was limited. He had not sought medical care in many years. Over the past three decades his

scrotal swelling had gradually worsened. He relied on a walker for ambulation and his mother attended to most of his daily needs. He had no prior urologic history and only previous surgery was a diaphragmatic hernia repair as a child.

On examination, there was massive scrotal edema with displacement past the level of his knees (Fig. 1). The scrotal skin was thickened and there were two open wounds with foul smelling, purulent fluid located at the bottom of the left hemi-scrotum. His right lower extremity had extensive edema and skin thickening of the upper leg. His white blood cell count was 24.4 WBC/L with 89% granulocytes. He was anemic with hemoglobin of 8.6 g/dL. He was febrile to 102.2F with a pulse of 137 bpm, concerning for sepsis.

Computed tomography (CT) scan of the abdomen and pelvis revealed a massive left inguinal hernia containing non-inflamed colon and its associated mesentery, a large subcutaneous abscess with gas measuring up to 12.8 cm with draining tract to the skin at the anterior inferior aspect of the scrotum. Massive hydrocele was noted in the left hemi-scrotum, extensive scrotal wall thickening, soft tissue ulceration at the left posterior aspect of the scrotum, severe left hydronephrosis and hydroureter secondary to the extension of the left ureter into the herniation, and extensive bilateral inguinal adenopathy (Fig. 2).

Due to the concern for Fournier's gangrene and patients declining clinical condition, he was taken to the operating room for emergent debridement of infected scrotal skin and subcutaneous tissue.

Intra-operative findings demonstrated a large abscess and sinus tract

\* Corresponding author. Baylor Scott and White Health, 5716 Ellington Ct, Temple, TX, 76502, United States.

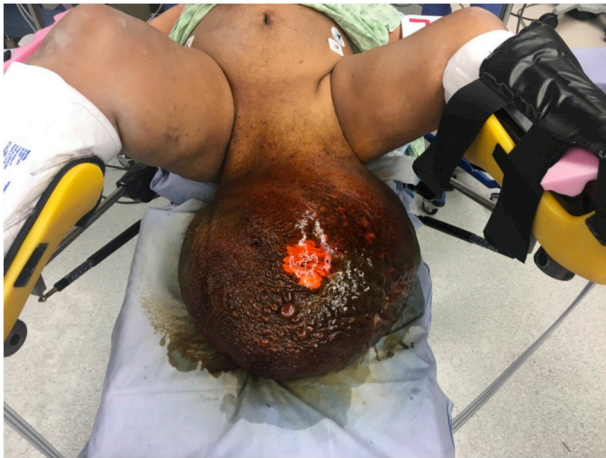E-mail address: [katherine.dowd@bswhealth.org](mailto:katherine.dowd@bswhealth.org) (K. Dowd).

<https://doi.org/10.1016/j.eucr.2019.101013>

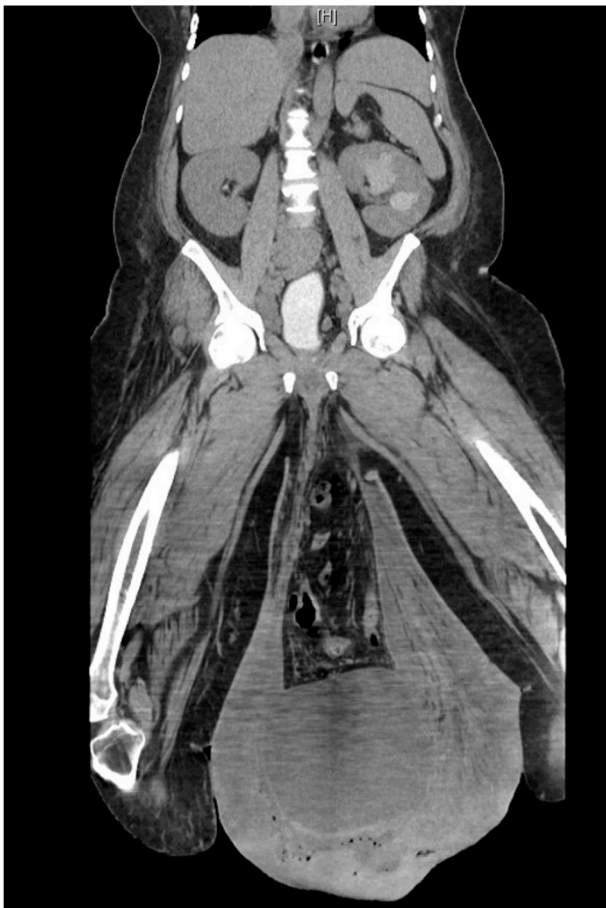
Received 13 July 2019; Received in revised form 10 September 2019; Accepted 11 September 2019

Available online 12 September 2019

2214-4420/© 2019 Published by Elsevier Inc. This is an open access article under the CC BY-NC-ND license (<http://creativecommons.org/licenses/by-nc-nd/4.0/>).



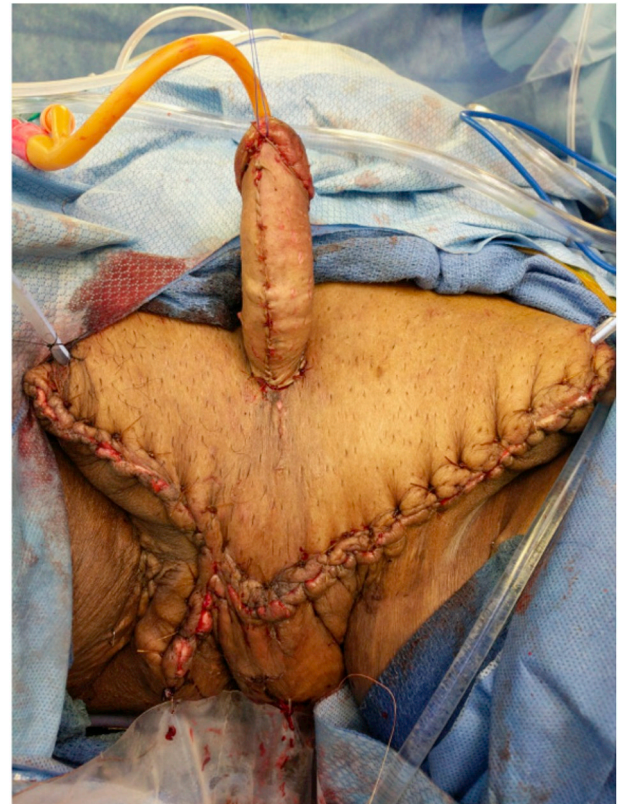**Fig. 1.** Presentation of the patient with massive scrotal edema and open wounds over the left hemi-scrotum.



**Fig. 2.** CT imaging illustrating impressive scrotal edema and massive inguinal hernia.

toward the left inguinal region, with areas of skin and subcutaneous necrosis. Foley catheter placement attempt proved to be difficult due to a buried penis, but was successfully accomplished by a dorsal slit procedure. Initial pathology revealed scrotal skin with extensive deep dermal acute inflammation and liquefactive necrosis.

The next day the patient returned to the operating room for minimal secondary debridement. On hospital day 5, after several days of intravenous antibiotics his wound appeared to be improving but dressing



**Fig. 3.** Initial outcome following surgical debridement and multi-disciplinary staged repair.

changes and wound vacuum were too painful. A decision was made to proceed with multidisciplinary (urology, general surgery, plastic surgery), definitive treatment.

The hernia repair necessitated a laparotomy to reduce the hernia contents and was augmented with biologic mesh(GORE® BIO-A®). Next, the patient then underwent a scrotectomy, left orchiectomy/hydrocele excision. The hydrocele measured up to 3.35kg and was 30.2 × 24.4 × 13.1 cm in size. On hospital day 8, the patient was taken back to the operating room by the plastic surgery team for a split thickness skin graft for the penis and primary closure of the perineum with advancement flap closures. He was discharged two days later to rehabilitation facility. He was seen four weeks postoperatively and was healing well with satisfactory cosmetic and functional outcomes (Fig. 3).

## Discussion

Here, we report a case of Fournier's gangrene that was complicated by massive lymphedema of the scrotum and right leg in a 43 year-old man from Panama, presumably filarial.

The diagnosis of filariasis in the hospital setting relies heavily on clinical suspicion. Detection of antibodies in a patient's serum has a sensitivity of 56–98% and a specificity of 78–98%.<sup>2</sup> While our patient had a filarial IgG4 of 0.59, which would be considered negative, serologic tests are not considered to be beneficial in the diagnostic process as once lymphedema is present these tests are usually negative. “Elephantiasis” or grade four lymphedema is reserved for patients with chronic progression of the disease and can be detrimental to a patient's quality of life. When filariasis progresses to this point, there is usually no role for microfilaricidal agents.<sup>4</sup>

Much literature exists on scrotal reconstruction for chronic scrotal lymphedema. Surgical treatment is indicated instances where the scrotal lymphedema is considered moderate to severe.<sup>4</sup> The techniques for reconstruction involve a partial or complete resection of the skin and

subcutaneous tissue. Often muscle flaps, skin grafts, and or micro-vascular reconstruction is involved in order to achieve improvement in the patient's quality of life.<sup>2</sup> In cases where there is minor lymphatic stasis without fibrotic changes, lymphangioplasty can be utilized to restore lymphatic drainage to the region.<sup>2</sup>

This case highlights the management of a patient requiring emergent intervention and multidisciplinary approach in the acute care setting. Imaging is not routine in Fournier's gangrene cases and may delay care, however was obtained given this patient's clinical stability and unusual presentation. With this treatment plan, initial debridement followed by a staged repair on day 3 and day 8, the patient was spared prolonged wound care, painful dressing changes, without sacrificing cosmetic and functional outcomes.

### Conclusion

In conclusion, chronic lymphedema complicated by Fournier's gangrene is a unique urological clinical entity. We describe a multidisciplinary approach that included emergent debridement followed by

staged repairs in the acute care setting.

### Declarations of interest

None.

### Financial conflict of interest

None.

### References

1. Pastor C, Granick M. Scrotal lymphedema *open access. J Plast Surg.* 2011;11.
2. Vives F, Garcia-Perdomi H, Ocampo-Florez G. Giant lymphedema of the penis and scrotum. *A case report Autopsy Case Reports.* 2016;6(1):57–61.
3. Chen S, Fu J, Wang C, Lee T, Chen S. Fournier gangrene: a review of 41 patients and strategies for reconstruction. *Ann Plast Surg.* 2010;64(6):765–769.
4. Parmar HD. The surgical approach in huge scrotal lymphedema. *Int J Med Sci Public Health.* 2013;2(1):153–155.