



ELSEVIER

Contents lists available at ScienceDirect

Toxicology Reports

journal homepage: www.elsevier.com/locate/toxrep

Indomethacin-induced gastric ulceration in rats: Protective roles of *Spondias mombin* and *Ficus exasperata*



Saheed Sabiu^{a,*}, Taofeeq Garuba^b, Taofik Sunmonu^c, Emmanuel Ajani^a,
Abdulhakeem Sulyman^a, Ismaila Nurain^a, Abdulazeez Balogun^c

^a Phytomedicine, Food Factors and Toxicology Research Laboratory, Biochemistry Unit, Department of Biosciences and Biotechnology, Kwara State University, P.M.B. 1530, Ilorin, Nigeria

^b Department of Plant Biology, University of Ilorin, Ilorin, Nigeria

^c Phytomedicine and Plant Biochemistry Research Laboratory, Biochemistry Unit, Department of Biological Sciences, Al-Hikmah University, Ilorin, Nigeria

ARTICLE INFO

Article history:

Received 9 October 2014

Received in revised form

30 November 2014

Accepted 1 January 2015

Available online 8 January 2015

Keywords:

Antacid

Antioxidative

Gastroprotective

NSAIDS

Proton pump inhibitor

Vagotomy

ABSTRACT

This study investigated the quantitative polyphenolic constituents and gastroprotective effects of aqueous leaf extracts of *Spondias mombin* and *Ficus exasperata* against indomethacin-induced gastric ulcer in rats. Ulceration was induced by a single oral administration of indomethacin (30 mg/kg body weight). Wistar rats were pretreated with esomeprazole (reference drug) at a dose of 20 mg/kg body weight, *S. mombin* or *F. exasperata* at 100 and 200 mg/kg body weight once daily for 21 days prior to ulcer induction. At the end of the experiment, gastric secretions and antioxidant parameters were evaluated. We observed that the significantly increased ($p < 0.05$) ulcer index, gastric volume, malondialdehyde level and pepsin activity were effectively reduced following treatment with *S. mombin* and *F. exasperata*. The extracts also markedly attenuated the reduced activity of superoxide dismutase as well as pH and mucin content in the ulcerated rats. These findings are indicative of gastroprotective and antioxidative potentials of the extracts which is also evident in the degree of % inhibition against ulceration. The available data in this study suggest that the extracts of *S. mombin* and *F. exasperata* proved to be capable of ameliorating indomethacin-induced gastric ulceration and the probable mechanisms are via antioxidative and proton pump inhibition.

© 2015 The Authors. Published by Elsevier Ireland Ltd. This is an open access article under the CC BY-NC-ND license (<http://creativecommons.org/licenses/by-nc-nd/4.0/>).

1. Introduction

Gastric ulceration is a benign lesion on the mucosal epithelium upon exposure of the stomach to excess acid and aggressive pepsin activity [1]. It is the most prevalent gastrointestinal disorder ever known, accounting for an estimated 15 mortality out of every 15,000 complications yearly in the world [2,3]. In spite of the rapidly changing

concept of gastric ulcer management from conventional vagotomy, prostaglandin analogs, H₂ receptor antagonists and antacids to proton pump inhibitors, gastrointestinal toxicity remains an impediment to their application in clinical practice. Specifically, gastrointestinal toxicity of nonsteroidal anti-inflammatory drugs (NSAIDs) origin may be as high as 4–8% per year and the complications are even higher for those with additional risk factors such as prior history of ulcer disease [4]. Various synthetic antiulcer drugs are presently available and some of these like cimetidine, misoprostol, ranitidine, omeprazole and esomeprazole are employed to manage and cure NSAID

* Corresponding author. Tel.: +234 8038179476.
E-mail address: saeed.sabiu@gmail.com (S. Sabiu).

induced gastric ulcer. However, each of these drugs confers simpler to severe side effects, prompting a search for non-toxic, easily accessible and affordable antiulcer medication [5,6]. Investigation on the phytotherapy of medicinal plants that are highly valued and widely used in the traditional systems of medicine might provide efficient formulation for better management. *Spondias mombin* and *Ficus exasperata* belongs to this class of therapeutic plants.

S. mombin (SM) commonly known as “lyeye” in the South-Western part of Nigeria is a fructiferous tree in the Family Anacardiaceae. The plant grows in rain forests and coastal areas, attaining a height of 15–22 m [7]. It is commonly used in folk medicine to cure many diseases due to its potent bioactive principles including tannins, saponins, flavonoids, phenolics and anthraquinone glycosides [8]. Antioxidant vitamins; alpha-tocopherol and ascorbic acid have been detected in its leaves extracts [9]. Tea from its flowers and leaves is taken as an analgesic and anti-inflammatory cure against stomach ache and discomfort [10]. Ayoka et al. [7] have also reported decoction from its leaves to be therapeutic against urethritis, cystitis as well as eye and throat inflammations. The gum from SM has also been exploited as an expectorant and vermifuge. The leaf extract of the plant has been outstandingly advocated for use in speedy wound healing processes, hemorrhoids and inflamed mucous membrane due to its tannin content [11]. Its pharmacological potencies such as antioxidative, antimicrobial, antimalarial and antibacterial have also been documented [8,10,12,13].

F. exasperata Valh (FE), called “Epin”, “Anwerenwa” and “Kawusa” respectively among the Yorubas, Igbos and Hausas in Nigeria, is commonly known as ‘sand paper tree’ belonging to Moraceae Family. Phytochemical analysis of the leaf extract of FE has revealed the presence of flavonoids, tannins, saponins, alkaloids and cyanogenic glycosides [14]. Its medicinal efficacy in treating many diseases has been researched. For instance, the South-Western people of Nigeria uses the decoction and infusion of FE leaves for the management, control and treatment of hypertension, diabetes mellitus and certain cardiovascular dysfunction [15]. Leaves of FE cooked with bananas are eaten for the treatment of gonorrhoea [16]. Its leaf extract is also taken to suppress stomach ache, treat peptic ulcer and as antidote to poison [5].

With the remarkable attributes of SM and FE particularly in alleviating stomach ache related disorders and wound healing enhancement, the present study compared their therapeutic efficacy to a reference drug (esomeprazole) on indomethacin-induced gastric ulceration in rats.

2. Materials

2.1. Chemicals and drugs

Indomethacin and esomeprazole were respectively procured from Kapit Pharmaceutical Limited, Nigeria and Ranbaxy Laboratories, India. Trichloroacetic acid (TCA), dimethylaminobenzaldehyde, epinephrine, acetyl acetone, bovine serum albumin (BSA), gallic acid, aluminum chloride, quercetin and thiobarbituric acid (TBA) were products of Sigma Chemical Co. (St. Louis, MO, USA). Distilled water

was obtained from Biochemistry Laboratory, Kwara State University, Malete, Nigeria. Assay kits used were from Randox Laboratories limited, United Kingdom. Other chemicals used were of analytical grade from reputable companies in the world.

2.2. Plant collection and authentication

Fresh leaves of SM and FE were collected in April 2014 following identification of the two plants at the botanical garden of University of Ilorin, Ilorin, Nigeria. The leaves were authenticated at the University’s Herbarium, where voucher specimens (nos. 14/20567 and 14/20568) were prepared and deposited.

2.3. Experimental animals

Albino rats of the Wistar strain at a mean weight of 180.00 ± 1.85 g were used for the study. The animals were obtained and reared as described by Sabiu et al. [17], following approval from the Independent Ethical Committee on the Use and Care of Laboratory Animals of the Kwara State University, Malete, Nigeria. A certified number KSU/IECCULA/001/05/014 was assigned and issued for the research.

3. Methods

3.1. Preparation of extracts

Leaves of SM and FE were air-dried at room temperature for 10 days to constant weight. The dried samples were then pulverized with an electric blender (model MS-223; Blender/Miller III, Taiwan, China), weighed and kept airtight prior to extraction. Powdered samples (500 g each) of both plants were separately extracted in 5 l of distilled water for 48 h with continuous shaking by orbital shaker maintained at 300 rpm. The solutions obtained were then filtered (with Whatman No. 1 filter paper) and the resulting filtrates lyophilized to give 15.5 g (SM) and 12.4 g (FE) residues, corresponding to yields of 3.1% and 2.48% respectively. The lyophilized samples were separately reconstituted in distilled water to give doses of 100 and 200 mg/kg body weight of each extract used in the study.

3.2. Determination of total phenolics

Following the reported method of Wolfe et al. [18], the total phenol contents in the plant extracts were determined. Briefly, an aliquot of each extract (1 ml) was mixed with 5 ml Folin-Ciocalteu reagent (previously diluted with water 1:10 v/v) and 4 ml (75 g/l) of sodium carbonate. The tubes were vortexed for 15 s and allowed to stand for 30 min at 40 °C for color development. Absorbance was read at 765 nm using a spectrophotometer (Beckman, DU 7400, USA). Extracts were evaluated at a final concentration of 1 mg/ml. Total phenolic content was expressed as mg/g gallic acid equivalent using the equation obtained from a calibration curve of gallic acid.

3.3. Determination of total flavonoids

Total flavonoids were estimated using the method of Ordon-ez et al. [19]. In brief, half a ml of 2% AlCl₃ ethanolic solution was added to 0.5 ml of the extracts. After 1 h at room temperature, the absorbance was read at 420 nm. The development of yellow color was taking as indication of the presence of flavonoids. Extract samples were evaluated at final concentration of 1 mg/ml. Total flavonoid content was calculated as quercetin equivalent (mg/g) using the equation obtained from the calibration curve.

3.4. Ulcer induction

Gastric ulceration was induced in the animals according to the procedure described by Sayanti et al. [20]. Briefly, rats were administered with a single oral dose of indomethacin (30 mg/kg body weight). They were deprived of food but had free access to water 24 h prior to ulcer induction. Various degrees of ulceration have manifested 4 h after indomethacin administration.

3.5. Animal grouping and treatments

Sixty three albino rats were randomized into nine groups of seven rats each. Group 1 (normal control) animals received only distilled water. Rats in group 2 (ulcerated control) were given only indomethacin. Groups 3 and 4 animals were administered respectively with 200 mg/kg b.w. of FE and SM only (to monitor likely negative/toxicological effect of the extracts). Animals in group 5 were given indomethacin after pretreatment with esomeprazole (20 mg/kg b.w.). Groups 6, 7, 8 and 9 comprised ulcerated rats pretreated with FE (100 mg/kg b.w.), FE (200 mg/kg b.w.), SM (100 mg/kg b.w.) and SM (200 mg/kg b.w.) respectively. Treatments with the reference drug and extracts lasted for 21 days prior to indomethacin administration. These were orally administered once daily using oral intubator with *ad libitum* provision of food and water throughout the experimental period.

3.6. Isolation of stomach and collection of gastric juice

On the twenty-third day (4 h post ulcer induction), the animals were humanely sacrificed by cervical dislocation. The abdomen was opened and the stomach excised. The stomach was thereafter opened along greater curvature and gastric content was drained into a centrifuge tube. Five ml of distilled water was added and the resultant solution was centrifuged at 3000 rpm for 10 min. The supernatant obtained was thereafter used for biochemical analyses. The cleaned stomachs were preserved in 0.1 M phosphate saline buffer (1:4 (w/v), pH 7.4) prior to macroscopic examination and homogenization.

3.7. Determination of gastric secretion parameters

Gastric acid output (volume) was determined in the supernatant (2 ml) by titration with 0.0025 N NaOH using Toepfer's reagent as indicator. The pH of gastric juice

Table 1

Ulcer scores and descriptive remark.

| Score | Remark |
|-------|------------------------|
| 0 | Almost normal mucosa |
| 1 | Vascular congestions |
| 2 | One or two lesions |
| 3 | Severe lesions |
| 4 | Very severe lesions |
| 5 | Mucosa full of lesions |

was determined using a pH meter, while the procedures of Sanyal et al. [21] and Corne et al. [22] were used to determine specific pepsin activity and mucin concentration respectively.

3.8. Quantification of ulceration

Degrees of ulceration in the indomethacin-treated animals were quantified using the procedure outlined by Szabo and Hollander [23]. Briefly, cleaned stomachs were pinned on a corkboard and ulcers were scored using dissecting microscope with square-grid eyepiece based on grading on a 0–5 scale (depicting severity of vascular congestions and lesions/hemorrhagic erosions) as presented in Table 1. Areas of mucosal damage were expressed as a percentage of the total surface area of the glandular stomach estimated in square millimeters. Mean ulcer score for each animal was expressed as ulcer index (U.I) and the percentage of inhibition against ulceration was determined using the expressions:

$$\text{U.I.} = [\text{Ulcerated area}/\text{total stomach area}] \times 100.$$

$$\% \text{Ulcer inhibition} = [\text{U.I. in control} - \text{U.I. in test}] \times 100/\text{U.I. in control.}$$

3.9. Preparation of stomach homogenate and assay of antioxidant indices

Immediately after ulcer scoring, whole stomach tissues were ground with liquid nitrogen in a mortar. The ground tissues (0.5 g each) were then homogenized in ice cold 0.1 M phosphate saline buffer (1:4 (w/v), pH 7.4) and the homogenates centrifuged at 2500 rpm for 10 min at 4 °C. The resulting supernatants were frozen at –20 °C to ensure maximum release of the enzymes located in the tissue before being used for the enzyme assay.

Activity of superoxide dismutase (SOD) and level of lipid peroxidation measured in terms of malondialdehyde (MDA) were respectively assayed in the stomach homogenate by the methods of Marklund and Marklund [24] and Devasagayam and Tarachand [25].

3.10. Statistical analysis

Inhibition against ulceration was expressed in percentage. Other results were expressed as mean of seven determinations ± standard error of mean. One-way analysis of variance (ANOVA) complemented with Student's

Table 2

Total phenolic and flavonoid contents of aqueous leaf extracts of *S. mombin* and *F. exasperata*. Values expressed per g of plant extract.

| Aqueous extract | Total phenol (mg gallic acid g ⁻¹) | Total flavonoids (mg quercetin g ⁻¹) |
|----------------------|--|--|
| <i>S. mombin</i> | 85.50 ± 0.20 | 60.53 ± 0.10 |
| <i>F. exasperata</i> | 68.40 ± 0.15 | 42.63 ± 0.20 |

Values were expressed per g of plant extract and are means of triplicate determination ± standard deviation.

t-test using SPSS software package for windows (Version 16) for differences between means was used to detect any significant difference ($p < 0.05$) between the treatment groups in this study.

4. Results

Quantitative phytochemical analysis of aqueous leaf extracts of SM and FE revealed the presence of total phenols and flavonoids (Table 2).

The effects of aqueous leaf extracts of SM and FE on the ulcer index and % inhibition against ulcer in the experimental animals are shown in Figs. 1 and 2 respectively. Oral administration of 30 mg/kg b.w. of indomethacin caused a significant ($p < 0.05$) increase in the degree of ulceration (ulcer index) in the rats. A significant improvement in the level of inhibition against ulceration was however observed in the extracts-treated animals. The extracts at 200 mg/kg b.w. offered better protection against ulceration

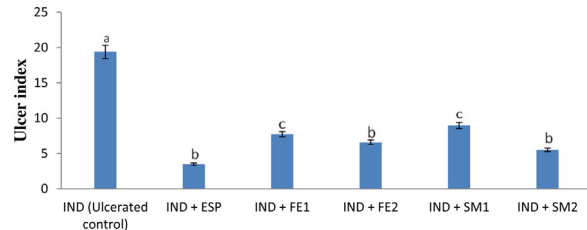


Fig. 1. Effect of aqueous leaf extracts of *S. mombin* and *F. exasperata* on ulcer index of indomethacin ulcerated rats ($n = 7$, $X \pm SEM$). Bars with different superscripts for the parameter are significantly different ($p < 0.05$). IND: indomethacin (30 mg/kg b.w.), ESP: esomeprazole (20 mg/kg b.w.), FE1: *Ficus exasperata* (100 mg/kg b.w.), FE2: *Ficus exasperata* (200 mg/kg b.w.), SM1: *Spondias mombin* (100 mg/kg b.w.), SM2: *Spondias mombin* (200 mg/kg b.w.).

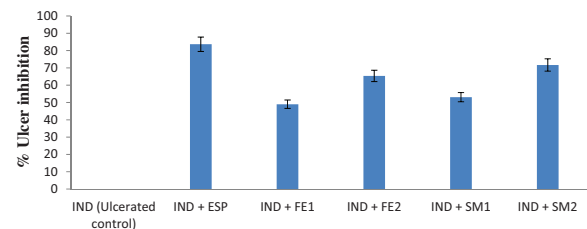


Fig. 2. Effect of aqueous leaf extracts of *S. mombin* and *F. exasperata* on degree of protection against ulceration in indomethacin ulcerated rats ($n = 7$, $X \pm SEM$). Bars represent % degree of protection offered against ulceration. IND: indomethacin (30 mg/kg b.w.), ESP: esomeprazole (20 mg/kg b.w.), FE1: *Ficus exasperata* (100 mg/kg b.w.), FE2: *Ficus exasperata* (200 mg/kg b.w.), SM1: *Spondias mombin* (100 mg/kg b.w.), SM2: *Spondias mombin* (200 mg/kg b.w.).

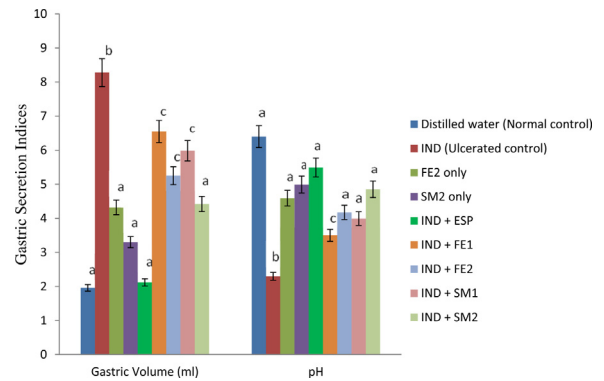


Fig. 3. Effects of aqueous leaf extracts of *S. mombin* and *F. exasperata* on gastric volume and pH of indomethacin ulcerated rats ($n = 7$, $X \pm SEM$). Bars with different superscripts for each parameter are significantly different ($p < 0.05$). IND: indomethacin (30 mg/kg b.w.), ESP: esomeprazole (20 mg/kg b.w.), FE1: *Ficus exasperata* (100 mg/kg b.w.), FE2: *Ficus exasperata* (200 mg/kg b.w.), SM1: *S. mombin* (100 mg/kg b.w.), SM2: *S. mombin* (200 mg/kg b.w.).

than the 100 mg/kg b.w. regimens and compared well with the standard drug (Esomeprazole) used.

Fig. 3 shows the effect of aqueous leaf extracts of SM and FE on gastric secretions of indomethacin ulcerated rats. Indomethacin administration caused significant ($p < 0.05$) decrease in pH value with a corresponding significant ($p < 0.05$) increase in gastric volume of gastric content. Pre-treatment with the extracts produced significant increase in pH value coupled with significant decrease in gastric volume when compared with ulcerated control rats.

Indomethacin administration brought about a significant ($p < 0.05$) increase in specific pepsin activity as well as significant reduction ($p < 0.05$) in mucin content of gastric juice of ulcerated rats when compared with the normal control (Fig. 4). The observed changes in these parameters were significantly attenuated ($p < 0.05$) in the SM and FE extracts-treated rats. Treatment with SM revealed more potent efficacy in the modulation of both pepsin and mucin contents of gastric juice of ulcerated rats.

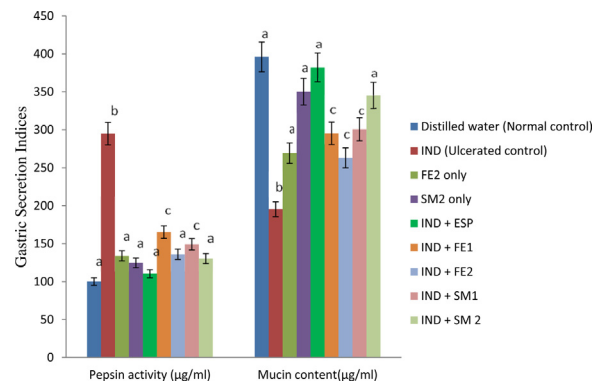


Fig. 4. Effects of aqueous leaf extracts of *S. mombin* and *F. exasperata* on pepsin activity and mucin content of indomethacin ulcerated rats ($n = 7$, $X \pm SEM$). Bars with different superscripts for each parameter are significantly different ($p < 0.05$). IND: indomethacin (30 mg/kg b.w.), ESP: esomeprazole (20 mg/kg b.w.), FE1: *Ficus exasperata* (100 mg/kg b.w.), FE2: *Ficus exasperata* (200 mg/kg b.w.), SM1: *S. mombin* (100 mg/kg b.w.), SM2: *S. mombin* (200 mg/kg b.w.).

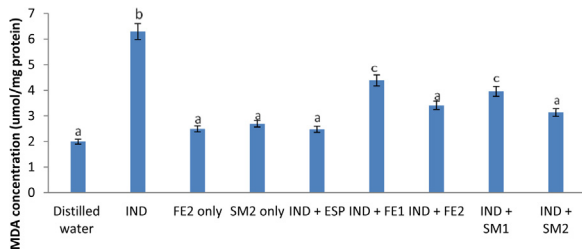


Fig. 5. Effect of aqueous leaf extracts of *S. mombin* and *F. exasperata* on gastric Malondialdehyde (MDA) level of indomethacin ulcerated rats ($n=7$, $X \pm \text{SEM}$). Bars with different superscripts for the parameter are significantly different ($p < 0.05$). IND: indomethacin (30 mg/kg b.w.), ESP: esomeprazole (20 mg/kg b.w.), FE1: *Ficus exasperata* (100 mg/kg b.w.), FE2: *Ficus exasperata* (200 mg/kg b.w.), SM1: *Spondias mombin* (100 mg/kg b.w.), SM2: *Spondias mombin* (200 mg/kg b.w.).

Figs. 5 and 6 revealed the effects of aqueous leaf extracts of SM and FE on the lipid peroxidation and SOD activity of gastric mucosal of indomethacin ulcerated rats. MDA level was significantly increased ($p < 0.05$) in the ulcerated animals (Fig. 1). A significant reduction ($p < 0.05$) was also observed in the activity of SOD (Fig. 2) in the indomethacin-induced animals. Commendably, both extracts particularly at 200 mg/kg b.w. regimen resulted in significant improvement ($p < 0.05$) in these parameters and the observable effects compared favorably well with both normal control and standard drug (esomeprazole) employed in the study.

5. Discussion

Inhibitory action of indomethacin on prostaglandin synthesis coupled with free radicals formation has been opined as critical biochemical events in the pathogenesis of gastric ulceration [26–28]. An understanding of these events might be of utmost relevance in designing new antiulcer drugs. With the inherent adverse side effects and considerably high cost of synthetic drugs, exploiting natural products of plant source which are believed to be non-toxic, efficacious and affordable will be most appropriate in the treatment of gastric ulcer. Phytotherapy is rapidly gaining grounds in sustaining human health and in the prevention

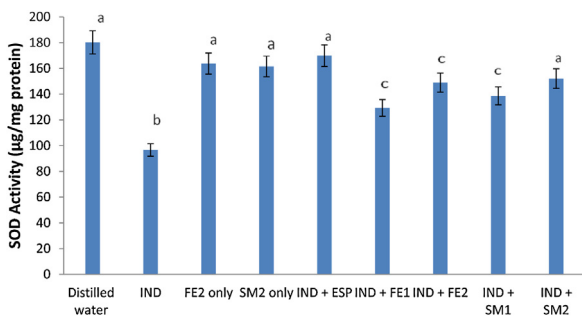


Fig. 6. Effect of aqueous leaf extracts of *S. mombin* and *F. exasperata* on gastric superoxide dismutase (SOD) activity of indomethacin ulcerated rats ($n=7$, $X \pm \text{SEM}$). Bars with different superscripts for the parameter are significantly different ($p < 0.05$). IND: indomethacin (30 mg/kg b.w.), ESP: esomeprazole (20 mg/kg b.w.), FE1: *Ficus exasperata* (100 mg/kg b.w.), FE2: *Ficus exasperata* (200 mg/kg b.w.), SM1: *Spondias mombin* (100 mg/kg b.w.), SM2: *Spondias mombin* (200 mg/kg b.w.).

of certain diseases like gastric ulcer resulting from drug toxicity [28,29]. This has been ascribed to possession of phytonutrients with excellent antioxidant properties that play significant roles in managing toxicity related disorders. Interestingly, studies have revealed the presence of some of these bioactive principles in SM and FE as well as reported them to promote good health [5,8,14,7]. In this study, we have also specifically quantified the polyphenolic constituents of aqueous leaf extracts of SM and FE as well as compared their gastroprotective effects on indomethacin-induced ulceration in rats.

Biochemical analysis of gastric secretions (for pH, gastric volume, bicarbonate, pepsin) and mucosal integrity for stomach is usually employed to ascertain its status following exposure to pharmacological agents [30]. The pH gives an idea of the level of acidity and volume of gastric secretions. Low pH value is a manifestation of decreased hydrogen ion concentration in gastric juice. This has been linked to pathogenesis of ulcer and gastric damage in experimental animals [31]. Inas et al. [27] have also attributed gastrointestinal injury to eroded mucin content. This erosion is facilitated by onslaughts of both internal (pepsin and oxidants produced in the gastric lumen) and external (drugs and chemicals) aggressive agents on mucosal epithelia.

In the present study, the significant increase in ulcer index and gastric volume following oral administration of indomethacin in the ulcerated rats may be attributed to either free radicals formation or inhibition of prostaglandin synthesis. Decreased prostaglandin level has been attributed to impaired gastroprotection and increased gastric acid secretion which are important events in the etiology of mucosal ulceration. This agrees with the reports of Bech et al. [32], Biplab et al. [30] and Muhammed et al. [33] where indomethacin was reported to have caused alterations in gastric secretions of rats. Conversely, pretreatments with the two extracts significantly reduced these parameters. In fact the effects noticed for pH compared favorably well with both normal control and standard drug used in this study and indeed suggestive of their possible gastroprotective attributes.

A combination of events including release of pre-formed mucus, wound retraction and re-epithelialization is involved in ulcer-healing process after toxicological injury [23,34]. Besides providing significant buffering capacity for the neutralization of luminal acid, the mucus also offers protection against both endogenous aggressors and exogenous gastrotoxic agents such as indomethacin, thereby enhancing the rate of local healing process [35]. In this study, the increased pepsin activity coupled with decrease in mucin secretion in the indomethacin-ulcerated rats indicated altered hydrophobicity and reduced protective ability of the mucosal membrane against hemorrhagic erosion, thus, resulting in tissue damage. This implied decreased ability of the gastric mucosa to withstand the offensive onslaught of indomethacin. Besides antioxidant action that protects the mucus layer and arrests ulcer progression, drugs that increase the synthesis and secretion of gastric mucus would accelerate gastric ulcer healing. Pretreatment with the extracts however, facilitated ulcer healing process, which is associated with decreased pepsin

activity and elevated mucin level in the gastric mucosa. This in turn has encouraged speedy wound healing of the ulcerated areas of the mucosal epithelia and shielded the gastrointestinal membrane, thus abrogating the catastrophic influence of indomethacin in the ulcerated rats [34]. This is indicative of enhanced mucus secretory potential of the extracts and suggestive of their significant role in ulcer healing process. Healing of mucosa epithelia cells was prominently displayed by the extracts at 200 mg/kg b.w. dose, depicting a better ulcer healing capacity and compared favorably well with the reference drug used.

Cells or tissues are in a stable state if the rates of free radical formation and scavenging capacity are essentially constant and in equilibrium. However, an imbalance between them results in oxidative stress which further deregulates cellular functions leading to different pathological conditions [17]. In the present study, the increased concentration of MDA as well as reduced activity of SOD in the stomach of indomethacin-ulcerated rats is a manifestation of facilitated lipid peroxidation and over production of free radicals resulting in mucosal damage. Free radicals thwart antioxidant enzymes activities and initiate lipid peroxidation which is an important event in the toxicity mechanism of indomethacin [36]. Indomethacin has previously been reported to decrease antioxidant enzymes (SOD, CAT and GST) activity in rat stomach thereby inducing gastric ulceration [37]. This is associated with overpowering of the cellular antioxidant defense systems by free radicals ravaging influence that subsequently results in stomach oxidative injury. However, the significantly reduced concentrations of MDA coupled with marked increase in the activity of SOD in rats pretreated with aqueous leaf extracts of both plants is an obvious indication of antiperoxidative potential and thus antioxidative potential.

Generally, the protection offered by the aqueous leaf extracts of SM and FE against indomethacin-induced gastric ulceration may be linked to their beneficial medicinal attributes occasioned by phytometabolite constituents. These include ability to scavenge free radicals and regulate mucosal membrane permeability thereby countering the effect of indomethacin on gastric acid secretion. This is in agreement with the submissions of Inas et al. [27], Muhammed et al. [33] and Gege-Adebayo et al. [38], where gastroprotective potentials of plant extracts against indomethacin-ulcerated rats were associated with their polyphenolic compounds and other various bioactive principles. Since esomeprazole is a proton pump inhibitor, then the effect produced by the two extracts might have perhaps mimic its mechanism of action by modulating cells in the mucosal lining of the stomach against excess acid secretion [39,40].

6. Conclusion

Overall, the attenuation of gastric affronts of indomethacin by administration of aqueous leaf extracts of SM and FE at 200 mg/kg b.w. regimen is indicative of their excellent gastroprotective and antioxidative potentials in rats. Efforts are ongoing to investigate the exact antiulcerogenic principle(s) in these extracts and also

harness their possible synergistic efficacy against gastric ulcer.

Conflict of interest

The authors declared that there are no conflicts of interest.

Transparency document

The [Transparency document](#) associated with this article can be found in the online version.

References

- [1] M. Khazaei, H. Salehi, Protective effect of *Falcaria vulgaris* extract on ethanol induced gastric ulcer in rat, *Iranian J Pharmacol Ther* 5 (2006) 1–4.
- [2] A. Sonnenberg, Geographic and temporal variations in the occurrence of peptic ulcer disease, *Scand J Gastroenterol Suppl* 110 (1996) 11.
- [3] B. Shristi, J. Neha, B.P. Indu, G. Rajesh, A review on some Indian medicinal plants for antiulcer activity, *J Sci Res Pharm* 1 (2012) 6–9.
- [4] M.R. Griffin, J.M. Scheiman, Prospects for changing the burden of nonsteroidal anti-inflammatory drug toxicity, *Am J Med* 110 (2001) 335–375.
- [5] P.A. Akah, O.E. Orisakwe, K.S. Gamanies, A. Shittu, Evaluation of Nigerian traditional medicines: 11. Effects of some Nigerian folk remedies on peptic ulcer, *J Ethnopharmacol* 62 (2) (1998) 123–127.
- [6] C. Hawkins, G.W. Hanks, The gastroduodenal toxicity of nonsteroidal anti-inflammatory drugs. A review of the literature, *J Pain Symptom Manage* 20 (2) (2000) 140–151.
- [7] A.O. Ayoka, R.O. Akomolafe, O.S. Akinsomisoye, O.E. Ukponmwan, Medicinal and economic value of *Spondias mombin*, *Afr J Biomed Res* 11 (2008) 129–136.
- [8] K.A. Abo, J.O. Ogunleye, J.S. Asindi, Antimicrobial potential of *S. mombis*, *Croton zambesicus* and *Zygotritonia crocea*, *Phytother Res* 13 (1999) 494–497.
- [9] H.C.C. Maduka, A.N. Okpogba, C.E. Ugwu, C.C. Dike, P.N. Ogueche, D.T. Onwuzurike, et al., Phytochemical, antioxidant and microbial inhibitory effects of *Spondias mombin* leaf and stem bark extracts, *J Pharm Biol Sci* 9 (2) (2014) 14–17.
- [10] L.F. Villegas, T.D. Fernandez, H. Maldonado, R. Torres, A. Zavaleta, A.J. Vaisberg, et al., Evaluation of wound healing of selected plants from Peru, *J Ethnopharmacol* 55 (1997) 193–200.
- [11] P.C. Njoku, M.I. Akumefula, Phytochemical and nutrient evaluation of *Spondias mombin* leaves, *Pakistan J Nutr* 6 (6) (2007) 613–615.
- [12] J. Corthout, L.A. Pieters, M. Claeys, D.A. Vanden-Berghe, A.J. Viletinck, Antibacterial and molluscicidal phenolic acid from *S. mombis*, *Planta Med* 60 (1994) 460–463.
- [13] A. Caraballo, B. Caraballo, A. Rodrigues-Acosta, Preliminary assessment of medicinal plant used as antimalarial in the South-Eastern Venezuelan Amazon, *Rev Soc Bras Med Trop* 37 (2) (2004) 186–188.
- [14] I.I. Ijeh, A.I. Ukwemi, Acute effect of administration of ethanolic extract of *Ficus exasperata* Vahl on kidney function in albino rats, *J Med Plant Res* 1 (2) (2007) 27–29.
- [15] P. Odiba, D. Yusuf, E. Ali, M. Yusuf, E. John, Effect of aqueous extract of *Ficus exasperata* leaf on the body weight and haematological parameters of Wistar rats, *J Appl Sci Environ* 3 (2012) 80–83.
- [16] C.F. Anowi, U. Umanah, A.U. Emezie, A.U. Utoh-Nedosa, Anti-diarrhoeal, antispasmodic and phytochemical properties of ethanolic extract of the leaves of *Ficus exasperata*, *Asian J Res Pharm Sci* 2 (1) (2012) 26–32.
- [17] S. Sabiu, A.M. Wudil, T.O. Sunmonu, Combined administration of *Telfaira occidentalis* and *Vernonia amygdalina* leaf powders ameliorates garlic-induced hepatotoxicity in Wistar rats, *Pharmacologia* 5 (5) (2014) 191–198.
- [18] K. Wolfe, X. Wu, R.H. Liu, Antioxidant activity of apple peels, *J Agric Food Chem* 51 (2003) 609–614.
- [19] A.A.L. Ordon-ez, J.D. Gomez, M.A. Vattuone, M.I. Isla, Antioxidant activity of *Sechium edule* (Jacq.) swart extracts, *Food Chem* 97 (2006) 452–458.
- [20] B. Sayanti, R.C. Susri, C. Subrata, K.B. Sandip, Healing properties of some Indian medicinal plants against indomethacin-induced gastric ulceration of rats, *J Clin Biochem Nutr* 41 (2) (2007) 106–114.

- [21] A.R. Sanyal, O.K. Denath, S.K. Bhattacharya, K.D. Gode, The effect of cyproheptadine on gastric acidity, in: C.J. Pfeiffer (Ed.), *Peptic ulcer*, Scandinavian University Books, Munksgaard, 1971, pp. 312–318.
- [22] S.J. Corne, S.M. Morrissey, R.J. Woods, Proceedings: a method for the quantitative estimation of gastric barrier mucus, *J Physiol* 242 (2) (1974) 116–117.
- [23] S. Szabo, D. Hollander, Pathways of gastrointestinal protection and repair: mechanisms of action of sucralfate, *Am J Med* 86 (6A) (1985) 23–31.
- [24] S. Marklund, G. Marklund, Involvement of superoxide anion radical in the autooxidation of pyrogallol and a convenient assay for superoxide dismutase, *Eur J Biochem* 47 (1974) 469–474.
- [25] T.P. Devasagayam, U. Tarachand, Decreased lipid peroxidation in the rat kidney during gestation, *Biochem Biophys Res Commun* 145 (1987) 134–138.
- [26] L.M. Lichtenberger, The hydrophobic barrier properties of gastrointestinal mucus, *Annu Rev Physiol* 17 (3) (2005) 178–188.
- [27] Z.A. Inas, A.H. Abdallah-Hala, H. Khattab, H.H. Gehan, Gastroprotective effect of *Cordia myxa* L. fruit extract against indomethacin-induced gastric ulceration in rats, *Life Sci J* 8(3) (2011) 433–445.
- [28] E.O. Ajani, S. Sabiu, F.A. Bamisaye, B.V. Adenigba, D.D. Awomoyi, M.N. Adeyanju, Hepatoprotective and antioxidative effect of ethanolic leaf extract of *Langenaria breviflora* (bitter gourd) on indomethacin-ulcerated rats, *J Pharm Biological Sci* 9 (5) (2014) 61–68.
- [29] Y. Raji, W.A. Oyeyemi, S.T. Shittu, A.F. Bolarinwa, Gastro-protective effect of methanol extract of *Ficus asperifolia* bark on indomethacin-induced gastric ulcer in rats, *Nig J Physiol Sci* 26 (1) (2011) 43–48.
- [30] A. Biplab, K.Y. Sudhir, R. Kshama, K.B. Sandip, C. Subrata, Black tea and theaflavins assist healing of indomethacin-induced gastric ulceration in mice by antioxidative action, *Evid Based Complem Alt Med* 11 (2011) 11–22.
- [31] H. Lüllmann, K. Mohr, A. Ziegler, D. Bieger, *Color atlas of pharmacology*, 2nd ed., Thieme Stuttgart, New York, 2000, pp. 166.
- [32] P.L. Bech, R. Xavier, N. Lu, N.N. Nanda, M. Dinauer, D.K. Podolsky, et al., Mechanisms of NSAID-induced gastrointestinal injury defined using mutant mice, *Gastroenterology* 119 (3) (2000) 699–705.
- [33] A.V.K. Muhammed, G. Thamotharan, S. Sengottuvelu, S. Haja-Sherief, T. Sivakumar, Evaluation of antiulcer activity of *Ficus pumila* L. leaf extract in albino rats, *Glob J Res Med Plants Indig Med* 1 (8) (2012) 340–351.
- [34] Y. Naito, T. Yoshikawa, K. Matsuyama, N. Yagi, M. Arai, Y. Nakamura, et al., Effects of oxygen radical scavengers on the quality of gastric ulcer healing in rats, *J Clin Gastroenterol* 21 (1) (1995) 82–86.
- [35] J. Alanko, A. Riutta, P. Holm, I. Mucha, H. Vapatalo, T. Metsa-Ketela, Modulation of arachidonic acid metabolism by phenols: relation to their structure and antioxidant/prooxidant properties, *Free Radic Biol Med* 26 (1–2) (1999) 193–201.
- [36] M. Halici, F. Odabasoglu, H. Suleyman, A. Cakir, A. Aslam, Y. Bayir, Effect of water extract of *Usnea longissima* on antioxidant enzyme activity and mucosal damage caused by indomethacin in rats, *Phytotherapy* 12 (2005) 656–662.
- [37] F. Odabasoglu, A. Cakir, H. Suleyman, A. Aslam, Y. Bayir, M. Halici, Gastroprotective and antioxidant effects of usnic acid on indomethacin induced gastric ulcer in rats, *J Ethnopharmacol* 103 (2006) 59–65.
- [38] G.I. Gege-Adebayo, V.U. Igbokwe, M.O. Shafe, C.O. Akintayo, D.I. Mbaka, Anti-ulcer effect of *Ocimum gratissimum* on indomethacin induced ulcer and percentage of superoxide dismutase on Wistar rats, *J Med Medical Sci* 4 (1) (2013) 8–12.
- [39] Z. Tulassay, M. Stolte, M. Sjölund, L. Engstrand, E. Butruk, P. Malfertheiner, et al., Effect of esomeprazole triple therapy on eradication rates of *Helicobacter pylori*, gastric ulcer healing and prevention of relapse in gastric ulcer patients, *Eur J Gastroenterol Hepatol* 20 (6) (2008) 526–536.
- [40] M. Fornai, R. Colucci, L. Antonioli, O. Awwad, C. Ugolini, M. Tucori, et al., Effects of esomeprazole on healing of nonsteroidal anti-inflammatory drug (NSAID)-induced gastric ulcers in the presence of a continued NSAID treatment: characterization of molecular mechanisms, *Pharmacol Res* 63 (1) (2011) 59–67.