

Clinicopathologic characteristics of primary vaginal clear cell carcinoma in China and an endometriosis malignant transformation case: a case series

Sikai Chen^{1,2}, Zhiyue Gu¹, Jian Sun³, Boju Pan³, Qingbo Fan¹, Ping Zheng^{1,4}, Shu Wang¹, Jinhua Leng¹, Yang Xiang¹, Jinghe Lang¹

¹Department of Obstetrics and Gynecology, Peking Union Medical College Hospital, Chinese Academy of Medical Science and Peking Union Medical College, Beijing 100730, China;

²Department of Obstetrics and Gynecology, Peking University Peoples Hospital, Beijing 100044, China;

³Department of Pathology, Peking Union Medical College Hospital, Chinese Academy of Medical Science and Peking Union Medical College, Beijing 100730, China;

⁴Key Laboratory for Major Obstetric Diseases of Guangdong Province, The Third Affiliated Hospital of Guangzhou Medical University, Guangzhou 510150, China.

To the Editor: Primary vaginal carcinoma is a rare malignant disease, which represents only approximately 1% to 2% of female genital malignancies. Vaginal adenosis is defined by the presence of metaplastic cervical or endometrial epithelium within the vaginal wall, and is associated with a high risk of vaginal carcinoma. In women prenatally exposed to diethylstilboestrol (DES), vaginal adenosis may arise in up to 90%, and these are often associated with vaginal clear cell adenocarcinoma.^[1] DES is an orally active non-steroidal estrogen. The Food and Drug Administration began a clinical trial in 1943, and concluded that DES administration is beneficial for preventing premature deliveries and miscarriages.^[2] In addition to primary vaginal clear cell carcinoma (PVCCC), in-uterus exposure to DES can also lead to T-shaped uterus anomaly.^[3] In the Chinese population, PVCCC is an uncommon malignancy, and there are no reports on the relationship between PVCCC and DES exposure.^[4] Given the rarity of PVCCC, it is significant to analyze relevant cases, and provide some valuable information for future clinical and basic studies. Therefore, the present study described ten cases of PVCCC, and summarized the characteristics of the diagnosis, management, and prognosis of these patients.

The case retrieval was conducted through the electronic medical record and paper case database of Peking Union Medical College Hospital (PUMCH). The initial inclusion criterion was the diagnosis of vaginal malignancy. The exclusion criteria included the following: tumors involving the cervix or vulva, which were not considered from vaginal malignancy, and classified as cervical or vulvar primaries according to the Federation of International

Gynecology and Obstetrics (FIGO) system; the pathological diagnosis being unclear for cell carcinoma; and suspicion of PVCCC metastasizing from other clear cell carcinomas (CCCs). The Ethics Committee of PUMCH approved the present study (Ethical trial No: JS-1532). All patients were informed of the study and provided consent.

Clinical information, including age at diagnosis, symptoms, pathology, immunohistochemical staining, and therapeutic procedures, were extracted from hospital medical records. Follow-up data, including post-operative complications and survival, occupation, and poisonous substance exposure, were collected by telephone inquiry, and from inpatient records. Nine medical records were intact and available in the HIS system, and four patients were lost during the telephone follow-ups. For patients who were lost to telephone follow-up, the last post-operative outpatient information was used as the follow-up outcome.

The overall survival or time to recurrence was calculated from the date of operation to the date of relapse, death, latest time of medical consult, or final follow-up (January 2019). The data were analyzed using Stata 12 (Stata Corporation, College Station, TX, USA). Continuous data were presented as mean and standard deviation, while categorical variables were expressed in percentages.

A total of 228 patients were diagnosed with vaginal malignancy. Furthermore, 11 patients were diagnosed

Sikai Chen and Zhiyue Gu contributed equally to this work.

Correspondence to: Dr. Shu Wang, Department of Obstetrics and Gynecology, Peking Union Medical College Hospital, Chinese Academy of Medical Science and Peking Union Medical College, Beijing 100730, China
E-Mail: wangshu219@hotmail.com;

Dr. Jinhua Leng, Department of Obstetrics and Gynecology, Peking Union Medical College Hospital, Chinese Academy of Medical Science and Peking Union Medical College, Beijing 100730, China
E-Mail: lengjenny@vip.sina.com

Copyright © 2022 The Chinese Medical Association, produced by Wolters Kluwer, Inc. under the CC-BY-NC-ND license. This is an open access article distributed under the terms of the Creative Commons Attribution-Non Commercial-No Derivatives License 4.0 (CCBY-NC-ND), where it is permissible to download and share the work provided it is properly cited. The work cannot be changed in any way or used commercially without permission from the journal.

Chinese Medical Journal 2022;135(6)

Received: 23-08-2021; Online: 13-10-2021 Edited by: Yanjie Yin and Xiuyuan Hao

Access this article online

Quick Response Code:



Website:
www.cmj.org

DOI:
10.1097/CM9.0000000000001734

with vaginal CCC, one patient was diagnosed with metastasis from the ovarian CCC, and ten patients were diagnosed with PVCCC [Supplementary Table 1, <http://links.lww.com/CM9/A740>], accounting for approximately 4.4%. The diagnoses of these patients were all histopathologically confirmed by pathologists specialized in gynecology.

In the time of event study, we conducted a 3-year survival study and five cases were censored because the last follow-up was <36 months from surgery, and five cases were enrolled. The 3-year overall surviving rate was 100% after surgical treatment. No patients died as a result of PVCCC in 3 years. The 3-year recurrence-free survival was 100%; recurrence was reported only in a single patient in 7 years. In addition, for the six patients with a successful telephone follow-up, the occupation and poisonous substance exposure history were investigated. All of these patients denied any DES exposure or poisonous substance contact history. However, the exposure history of the remaining four patients was unclear.

Among the primary vaginal malignancies, PVCCC is extremely rare, and there is no precise data about the incident rate and prevalence rate of PVCCC in all kinds of primary vaginal malignancies. At present, no evidence and report has suggested that PVCCC is correlated to DES exposure in the Chinese population, although the United States demonstrated that prenatal DES exposure is closely correlated to PVCCC, and investigated its epidemiological characteristics over half a century.^[1] The possible explanation is that DES was only prescribed as the endocrinotherapy to malignancy (advanced breast cancer/prostate cancer) and estrogen replacement in China several decades ago, but pregnancy and breastfeeding are absolute contraindications. Besides, in current situations, DES is now clinically marginalized from either endocrinotherapy or estrogen replacement, and gynecologists and oncologists do not intend to prescribe such medication to those patients. In the United States population, PVCCC risk was the greatest in the 40 to 44 age group. However, regardless of whether the patients' mother received DES while pregnant, this may still be a relevant aspect of the medical history of women born during the period of DES use in pregnancy. Huo *et al.*^[1] reported that patients with clear-cell adenocarcinoma had increased mortality across their life span. The excess

mortality risk within 35 to 49 years is mainly due to late recurrences, while the excess mortality risk after 50 years may be due to other life-threatening health conditions in the population of women exposed to DES.

PVCCC may progress from vaginal adenosis. Adenosis is a benign histopathological change, and is also closely correlated to DES exposure. Adenosis induced by DES has been previously reported as the precursor of vaginal carcinomas. For vaginal CCC, glandular epithelium was identified in 80% of patients.^[4]

There are no evidences suggesting that the treatment of PVCCC is different from the other histopathological types of vaginal malignancies. Surgical resection is the primary option,^[5] followed by chemotherapy and radiotherapy. Radiotherapy combined with chemotherapy or concurrent chemoradiation therapy remains as a better option for the survival rate of primary vaginal carcinoma.^[6] The complications of treatments included vulva pain, ulceration, urinary retention, and surgical sites infection. These complications were possibly caused by the radiotherapy or surgical procedures.

In the present study, Case No. 10 was complicated with vaginal endometriosis. After the confirmation from experienced pathologists, these cases were diagnosed with vaginal endometriosis malignant transformation [Figure 1]. The pathological features of the endometriosis transformation malignancy were described by Takeuchi *et al.*^[7] as follows: For the ovarian-endometriosis malignancy, the coexistence of endometriosis and carcinoma with a transitional lesion in the same ovary is a definitive pathologic finding of malignant transformation, but this is not observed in all cases. A cluster of hemosiderin-laden macrophages within a thick fibrous capsule that contains a chocolate-colored hemorrhagic material is suggestive of a cystic-endometrial tumor. Such transformation can be due to the loss of heterozygosity and somatic mutation of tumor suppressor genes, particularly phosphatase and tensin homolog deleted on chromosome ten/mutated in multiple advanced cancers/ telomerase-associated protein 1. The high frequency of mutations in tumor suppressor *p53* in atypical endometriosis and ovarian cancers associated with endometriosis, and alterations in *bcl-2* and *p53* proteins, may be associated with the malignant transformation of endometrioid cysts.^[5]

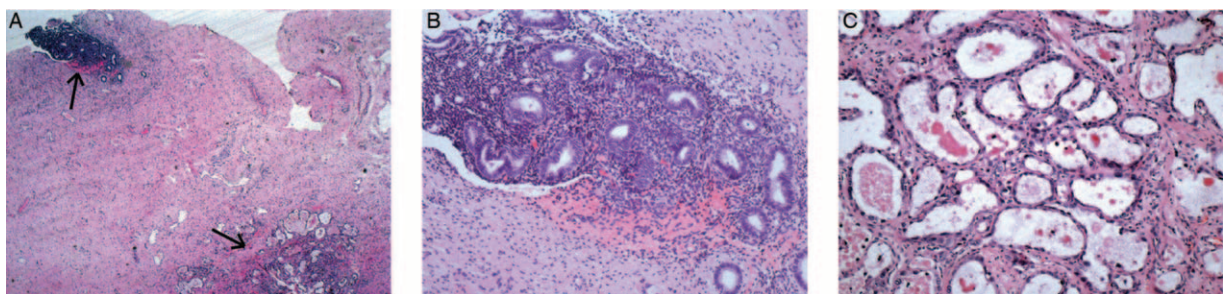


Figure 1: (A) Malignant transformation of vaginal endometriosis, indicating the endometriosis in upper left region and clear cell malignant transformation in lower right region In the same vision (black arrow, HE stained, original magnification $\times 20$); (B) Endometriosis foci in vaginal mucous, endometrial glands were displayed (dark stain area, HE stained, original magnification $\times 100$); (C) Clear cell carcinoma transformation from endometriosis (nearly all glands in vision, HE stained, original magnification $\times 100$). HE: Hematoxylin-eosin.

There are some limitations in the present study. First, since PVCCC is a rare disease, the number of included patients was small, the age span was large, and the follow-up time significantly varied. Second, there was a lack of partial data, such as the patients surgical history and the FIGO stage of some patients. Furthermore, some patients did not participate during the telephone follow-up, resulting in incomplete DES exposure information statistics. Third, due to the retrospective nature of the study, the samples were not processed in time for the corresponding gene analysis. However, these limitations provide suggestions for the further study of PVCCC in the future.

PVCCC is rare in all types of vaginal carcinoma. In Western countries, maternal DES exposure during pregnancy contributes the most to PVCCC. On the contrary, no case of DES-induced PVCCC has been reported in the Chinese population. CCC is a common pathohistological type of endometriosis malignant transformation. After the routine treatment, including surgery resection and radiochemotherapy, these patients continued to have a good prognosis. The present study is the first to document the clinical characteristics, follow-up data, and ascertainment of outcomes in China. Further studies should be conducted to establish a larger scale of cases, and determine the exact epidemiological features and etiology of PVCCC in the Chinese population.

Funding

This study was supported by a grant from the National Key R&D Program of China (No. 2017YFC1001200).

Conflicts of interest

None.

References

1. Huo D, Anderson D, Herbst AL. Follow-up of patients with clear-cell adenocarcinoma of the vagina and cervix. *N Engl J Med* 2018;378:17461748. doi: 10.1056/NEJMc1800097.
2. Laronda MM, Unno K, Butler LM, Kurita T. The development of cervical and vaginal adenosis as a result of diethylstilbestrol exposure in utero. *Differentiation* 2012;84:252260. doi: 10.1016/j.diff.2012.05.004.
3. Garzon S, Laganà AS, Di Spiezio Sardo A, Alonso Pacheco L, Haimovich S, Carugno J, *et al.* hysteroscopic metroplasty for T-shaped uterus: a systematic review and meta-analysis of reproductive outcomes. *Obstet Gynecol Surv* 2020;75:431444. doi: 10.1097/ogx.0000000000000807.
4. Han T, Jin Y, Li Y, Bi Y, Pan L. Clinicopathologic features and outcomes of primary vaginal adenosis as a dermatologic and gynecologic burden: a retrospective study. *Medicine (Baltimore)* 2018;97:e13470. doi: 10.1097/md.00000000000013470.
5. Mahdavi A, Shamshirsaz AA, Peiretti M, Zakashansky K, Idrees MT, Nezhat F. Laparoscopic management of vaginal clear cell adenocarcinoma arising in pelvic endometriosis: case report and literature review. *J Minim Invasive Gynecol* 2006;13:237241. doi: 10.1016/j.jmig.2006.01.011.
6. Miyamoto DT, Viswanathan AN. Concurrent chemoradiation for vaginal cancer. *PLoS One* 2013;8:e65048. doi: 10.1371/journal.pone.0065048.
7. Nezhat F, Apostol R, Mahmoud Mel Daouk M. Malignant transformation of endometriosis and its clinical significance. *Fertil Steril* 2014;102:342344. doi: 10.1016/j.fertnstert.2014.04.050.

How to cite this article: Chen S, Gu Z, Sun J, Pan B, Fan Q, Zheng P, Wang S, Leng J, Xiang Y, Lang J. Clinicopathologic characteristics of primary vaginal clear cell carcinoma in China and an endometriosis malignant transformation case: a case series. *Chin Med J* 2022;135:738–740. doi: 10.1097/CM9.0000000000001734