



Case Report

Purtscher's retinopathy as the presenting manifestation of immune thrombocytopenic purpura



Caroline C. Awh, Bobeck S. Modjtahedi, Dean Elliott*

Massachusetts Eye and Ear, Harvard Medical School, 243 Charles Street, Boston, MA, USA

ARTICLE INFO

Article history:

Received 12 May 2016

Received in revised form

13 January 2017

Available online 9 March 2017

Keywords:

Purtscher's retinopathy

Immune thrombocytopenic purpura

ABSTRACT

Purpose: To report the case of a 52-year-old man with Purtscher's retinopathy as the presenting manifestation of immune thrombocytopenic purpura (ITP).

Observations: Treatment with corticosteroids led to the resolution of hematologic findings within 1 week, and normal visual acuity was achieved after 2 months with no additional treatment.

Conclusions and importance: This is the first reported association between Purtscher's retinopathy and ITP. Complement activation has been implicated in the pathogenesis of both ITP and Purtscher's retinopathy, and we suggest that the patient's systemic process accounted for the retinal findings.

© 2017 The Authors. Published by Elsevier Inc. This is an open access article under the CC BY-NC-ND license (<http://creativecommons.org/licenses/by-nc-nd/4.0/>).

1. Introduction

Purtscher's retinopathy is a rare retinal vasculopathy seen in patients with a history of trauma or a variety of systemic diseases. While the exact pathogenesis is unknown, the presumed mechanism is embolic peripapillary terminal arteriolar occlusion. Suggested emboli include complement-mediated leukoaggregates, air, fat, fibrin, or platelets.¹ Immune thrombocytopenic purpura (ITP) is an autoimmune disease characterized by a low platelet count and the absence of any identifiable cause of thrombocytopenia. We report the case of a man diagnosed with Purtscher's retinopathy and ITP who had recovery of vision after systemic treatment of his ITP.

2. Case report

A 52-year-old Caucasian man was referred with a two-day history of profound visual loss in both eyes. Four days prior, he had developed a severe flu-like illness, consisting of headache, body ache, fever, and shortness of breath. There was no history of trauma. Past medical history was significant for a hospitalization at age 15 following a similar flu-like illness with lower extremity "purple spots."

On our examination, BCVA was 20/800 in each eye. There was no relative afferent pupillary defect. Intraocular pressure and anterior segment findings were normal in both eyes. Fundus examination revealed multiple peripapillary polygonal areas of inner retinal whitening in both eyes (Fig. 1). Optical coherence tomography (OCT) demonstrated cystoid macular edema nasal to the fovea and serous foveal detachment, left eye greater than right (Fig. 2). Fluorescein angiography revealed areas of hyperfluorescence corresponding to some of the areas of retinal whitening seen clinically (Fig. 3).

The patient was diagnosed with Purtscher's retinopathy. A complete blood count obtained from his primary care physician several days earlier revealed a low platelet count of 53,000/ μ L (reference range: 150,000–400,000/ μ L). We initiated a workup, and the patient was referred to the Massachusetts General Hospital for additional systemic evaluation. The patient had no fever, rash, history of recent trauma, or changes in medications. Chest x-ray, thyroid function, renal function, amylase level, and lipase level were normal. A complete blood count revealed a low platelet count of 56,000 but was otherwise normal. Peripheral blood smear showed no evidence of schistocytes. A diagnosis of ITP was made and he was treated with oral prednisone 80 mg/day. The patient's platelet count normalized to 239,000/ μ L and 336,000/ μ L after 4 and 5 days of treatment, respectively. Two months later, his vision improved to 20/20 OD and 20/15 OS, although he continued to complain of difficulty with driving and reading. Fundus examination revealed almost complete resolution of the white lesions (Fig. 4), although OCT demonstrated areas of outer nuclear, outer

* Corresponding author. Department of Ophthalmology, Massachusetts Eye and Ear, Harvard Medical School, 243 Charles Street, Boston, MA 02114, USA.

E-mail address: dean_eliott@meei.harvard.edu (D. Elliott).

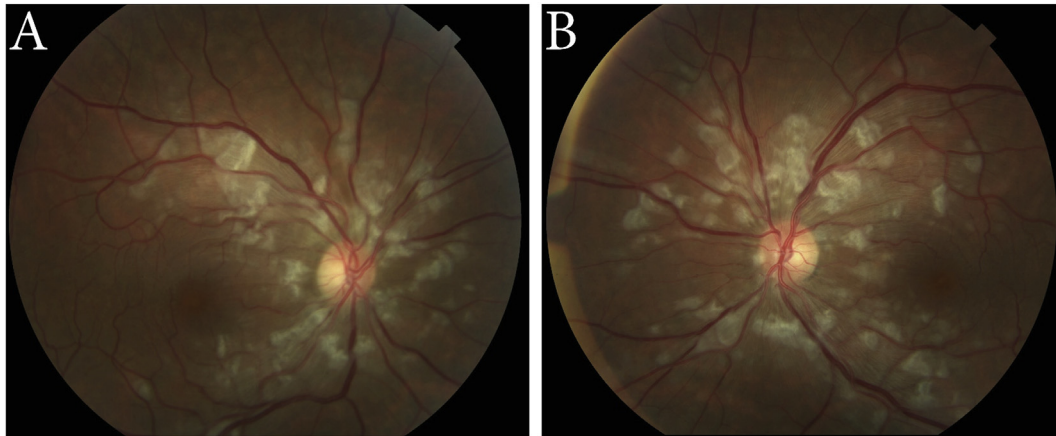


Fig. 1. Baseline color fundus photographs of the right (A) and left (B) eyes demonstrate peripapillary discrete areas of inner retinal whitening (Purtscher flecken). (For interpretation of the references to colour in this figure legend, the reader is referred to the web version of this article.)

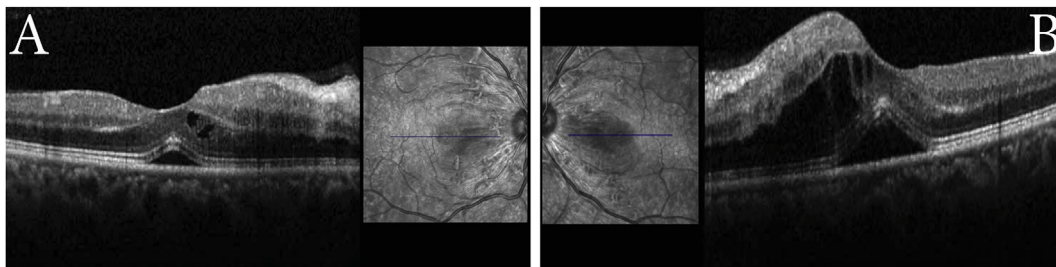


Fig. 2. Baseline optical coherence tomography illustrates cystoid macular edema and serous foveal detachment in the right (A) and left (B) eyes.

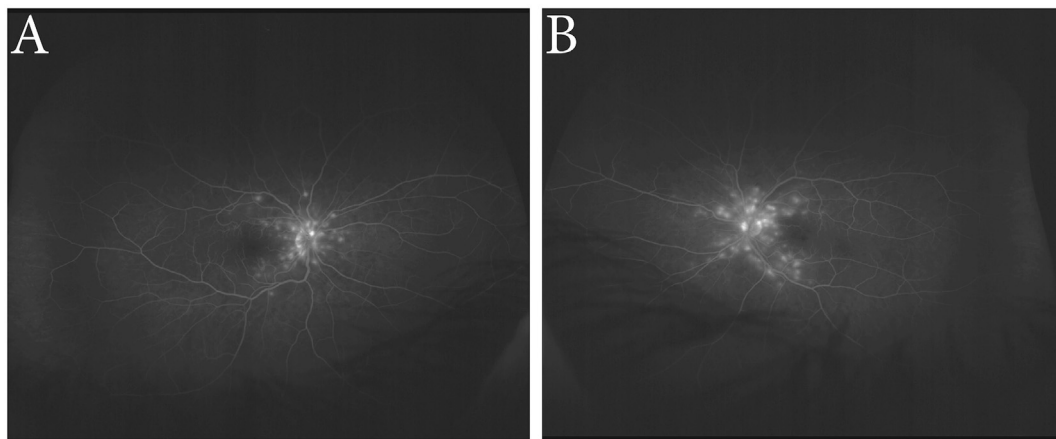


Fig. 3. Baseline fluorescein angiography (late phase) of the right (A) and left (B) eyes demonstrates areas of peripapillary hyperfluorescence.

plexiform, and inner nuclear layer thinning, left eye greater than right (Fig. 5).

3. Discussion

We report the first case of Purtscher's retinopathy in a patient with ITP. Purtscher's retinopathy is a rare vaso-occlusive condition that presents as profound visual loss associated with cotton wool spots, intraretinal hemorrhages, and *Purtscher flecken*, or polygonal areas of inner retinal whitening between the retinal arterioles and venules with a characteristic clear zone between the affected retina

and adjacent arterioles.² While the pathogenesis remains unclear, a commonly accepted mechanism is retinal embolization caused by complement C5a-induced leukocyte aggregates.^{3,4} Purtscher's retinopathy has been associated with complement-activating conditions such as acute and chronic pancreatitis, trauma, and collagen vascular diseases, as well as thrombotic thrombocytopenic purpura and HELLP (hemolysis, elevated liver enzymes, low platelet count) syndrome, which present with hematologic abnormalities similar to ITP.^{1,5–8} Complement activation may be a common causative mechanism of both Purtscher's retinopathy and ITP, and

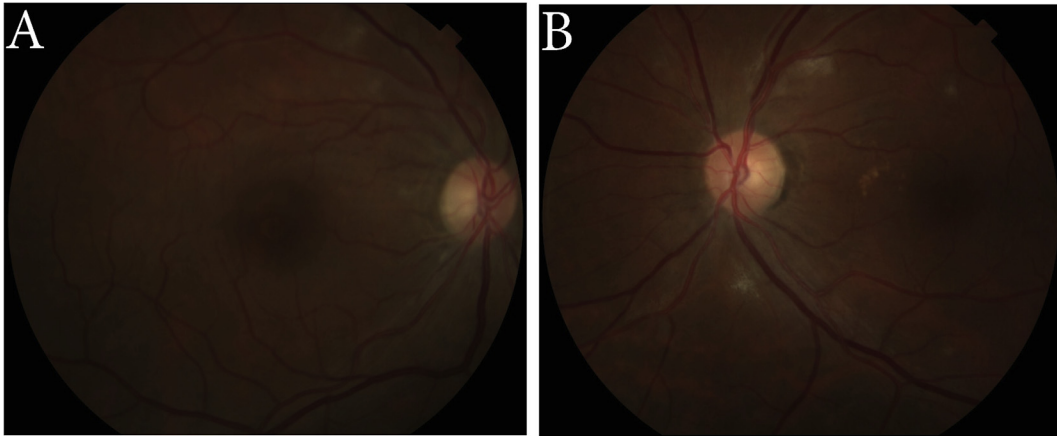


Fig. 4. Fundus photographs of the right (A) and left (B) eyes demonstrate almost complete resolution of findings.

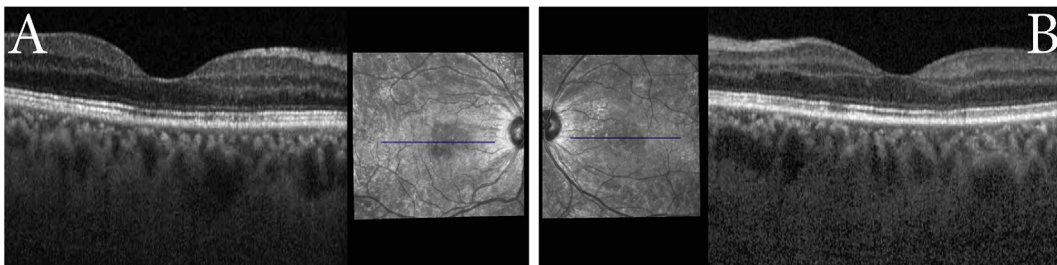


Fig. 5. Optical coherence tomography of the right (A) and left (B) eyes demonstrates areas of outer nuclear, outer plexiform, and inner nuclear layer thinning.

in this case, Purtscher's retinopathy was the presenting manifestation of ITP.

In most patients, ITP is a self-limited, benign disorder. It is mediated by autoantibodies that both accelerate platelet destruction and inhibit platelet production. Although an acute infection is often the initial trigger of ITP, the exact pathophysiology of antibody production remains unknown.⁹ Complement activation is implicated in the pathogenesis of ITP.¹⁰ The majority of patients with ITP have been shown to have platelet autoantibodies that can elevate complement activation above baseline,^{11,12} and complement may contribute to lysis of antibody-coated platelets.⁹ Most patients with ITP experience only minor bleeding symptoms such as mucosal bleeding, petechiae, and bruising. It is possible that our patient's similar illness with "purple spots" at age 15 was childhood ITP and that his most recent illness represented a recurrence.

Visual outcomes of Purtscher's retinopathy are variable and may depend on the underlying systemic condition.¹ We believe this case lends additional support to the proposed role of complement activation in the development of Purtscher's retinopathy, as this pathologic process is an accepted mechanism in the development of ITP. The improvement in our patient's vision and retinal findings occurred in concert with the resolution of his ITP and lends validity to this proposed pathophysiologic relationship. We hypothesize that increased complement activation associated with ITP was the cause of our patient's Purtscher's retinopathy.

Patient consent

No consent was obtained from the patient to report this case. Consequently, all identifiable information has been omitted.

Funding

No funding or grant support.

Conflict of interest

The following authors have no financial disclosures: CCA, BSM, DE.

Authorship

All authors attest that they meet the current ICMJE criteria for Authorship.

Acknowledgements

None.

References

1. Agrawal A, McKibbin MA. Purtscher's and purtscher-like retinopathies: a review. *Surv Ophthalmol.* 2006;51:129–136.
2. Agrawal A, McKibbin MA. Purtscher's retinopathy: epidemiology, clinical features, and outcome. *Br J Ophthalmol.* 2007;91:1456–1459.
3. Buckley SA, James B. Purtscher's retinopathy. *Postgrad Med J.* 1996;72:409–412.
4. Jacob HS, Goldstein IM, Shapiro I. Sudden blindness in acute pancreatitis. Possible role of complement-induced retinal leukoembolization. *Arch Intern Med.* 1981;141:134–136.
5. Massa R, Vale C, Macedo M, et al. Purtscher-like retinopathy. *Case Rep Ophthalmol Med.* doi:10.1155/2015/421329.
6. Sharma AG, Kazim NA, Elliott D, Houghton O, Abrams GW. Purtscher's retinopathy that occurred 6 months before acute pancreatitis. *Am J Ophthalmol.* 2006;141:205–207.

7. Reti M, Farkas P, Csuka D, et al. Complement activation in thrombotic thrombocytopenic purpura. *J Thromb Haemost.* 2012;10:791–798.
8. Cernea D, Dragoescu A, Novac M. HELLP syndrome complicated with postpartum subcapsular ruptured liver hematoma and purtscher-like retinopathy. *Case Rep Obstet Gynecol.* 2012 <http://dx.doi.org/10.1155/2012/856135>.
9. Psaila B, Bussel JB. Immune thrombocytopenic purpura. *Hematol Oncol Clin North Am.* 2007;21:743–759.
10. Verschoor A, Langer HF. Crosstalk between platelets and the complement system in immune protection and disease. *Thromb Haemost.* 2013;110:910–919.
11. Najaoui A, Bakchoul T, Stoy J, et al. Autoantibody-mediated complement activation on platelets is a common finding in patients with immune thrombocytopenic purpura (ITP). *Eur J Haematol.* 2012;88:167–174.
12. Peerschke EI, Andemariam B, Yin W, Bussel JB. Complement activation on platelets correlates with a decrease in circulating immature platelets in patients with immune thrombocytopenic purpura. *Br J Haematol.* 2010;148:638–645.