

# Acute Triceps Tendon Repair: A Technique Utilizing 3 Curved Tunnels and Proximal Knots



Alison K. Sarokhan, M.D., and Nicky L. Leung, M.D.

**Abstract:** Although triceps tendon tears are less common than other tendon tears, complete ruptures require surgical repair to restore the strength of the extensor mechanism of the elbow. There are several described techniques for repair using both transosseous tunnels and suture anchors. Current techniques often result in large suture knots over the dorsal ulna under thin subcutaneous tissue, which can be irritating for patients. Knotless techniques require costly suture anchors. In this technical note, we describe a novel transosseous 3-tunnel technique with proximal suture knots to lessen the potential for postoperative pain.

Triceps tendon ruptures are relatively rare. In 1 review, there were only 16 triceps ruptures over a 25-year period.<sup>1</sup> Although they are uncommon, it is accepted that surgical repair of acute complete triceps tendon ruptures should be recommended for all healthy active individuals to restore the extensor strength of the elbow.<sup>2</sup>

Several studies have described and examined various surgical repair techniques for complete triceps tendon ruptures.<sup>3-7</sup> Traditional techniques involve repair with suture through transosseous tunnels.<sup>4,6,8</sup> Several methods using suture anchors are now popular, including both traditional and knotless anchors. Both single- and double-row configurations are described, borrowing principles from rotator cuff repair.<sup>3,5,7</sup> Biomechanical cadaver studies have suggested certain techniques that provide optimal strength and coverage of the olecranon footprint<sup>7</sup>; however, a superior

repair technique for this condition has yet to be proven clinically.

With the exception of knotless suture anchor repair, all previously described techniques include tying large knots distally on the subcutaneous surface of the proximal ulna, a potential source of postoperative pain. Our technique uses a transosseous repair with proximal knots tied over the triceps tendon, minimizing the potential for prominent suture knots without the added cost of anchors.

## Surgical Technique

Surgery may be performed under general or regional anesthesia. It is our preference to position the patient in a supine position with the arm placed over a bump across the chest, although the lateral decubitus position may also be used. A nonsterile pneumatic tourniquet is applied to the arm as proximal as possible before prepping. A sterile tourniquet may also be used.

An approximately 10-cm longitudinal curvilinear incision is made, curving just lateral to the tip of the olecranon (Fig 1). Full-thickness flaps are elevated and the tendon stump is identified and freed from surrounding tissue using a combination of sharp and blunt dissection. The paratenon is incised longitudinally and preserved for later repair (Fig 2). The tendon end is grasped with a nonpenetrating clamp over a damp sponge to avoid further traumatizing the ruptured end of the tendon (Fig 3). A small extension of the longitudinal split between the heads of the triceps may be made to allow for further mobilization of the tendon (Fig 4). Longitudinal tension is applied to the tendon stump for several minutes so the triceps muscle can regain its normal resting length (Fig 5). When this is

From the Department of Orthopaedic Surgery, Tufts Medical Center (A.K.S., N.L.L.), Boston, Massachusetts, U.S.A.; and Department of Orthopaedic Surgery, Newton-Wellesley Hospital (N.L.L.), Newton, Massachusetts, U.S.A.

The authors report that they have no conflicts of interest in the authorship and publication of this article. Full ICMJE author disclosure forms are available for this article online, as [supplementary material](#).

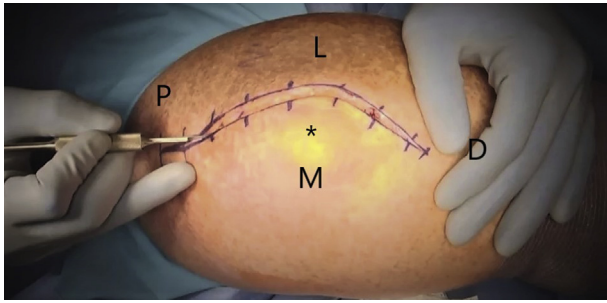
Received December 12, 2018; accepted March 3, 2019.

Address correspondence to: Alison K. Sarokhan, M.D., Department of Orthopaedic Surgery, Tufts Medical Center, 800 Washington Street, TMC Box #306, Boston, Massachusetts 02111, U.S.A. E-mail: [asarokhan@gmail.com](mailto:asarokhan@gmail.com)

© 2019 by the Arthroscopy Association of North America. Published by Elsevier. This is an open access article under the CC BY-NC-ND license (<http://creativecommons.org/licenses/by-nc-nd/4.0/>).

2212-6287/181509

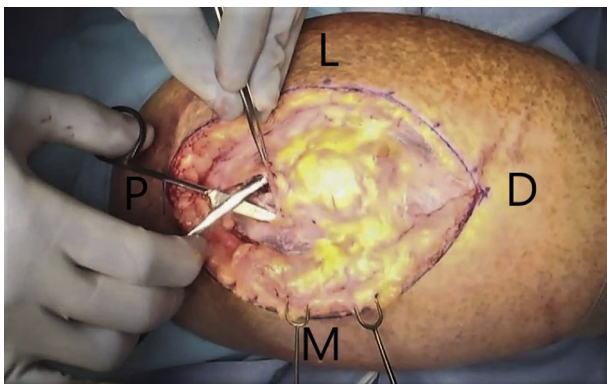
<https://doi.org/10.1016/j.eats.2019.03.005>



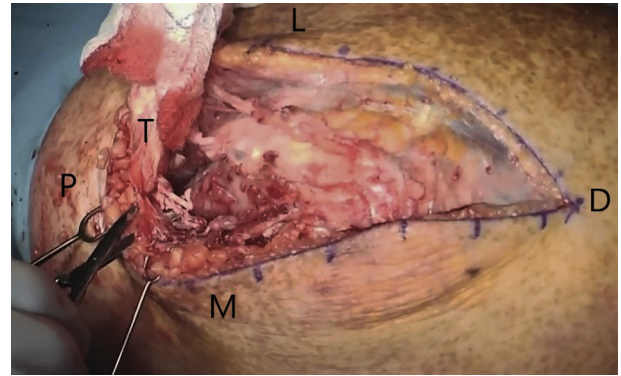
**Fig 1.** An approximately 10-cm longitudinal curvilinear incision is made, curving just lateral to the tip of the olecranon. (\*, olecranon; D, distal; L, lateral; M, medial; P, proximal.)

achieved, the tendon stump should be able to reach its native insertion on the olecranon tip. Occasionally, the elbow needs to be maintained in a slightly extended posture by the first assistant to facilitate direct bone-to-tendon contact. The bony footprint is cleared of residual tendon and soft tissue debris, then lightly decorticated using a curette or burr to create a bleeding bed for healing (Fig 6).

A 2-mm drill is used to create 3 holes in the central, radial, and ulnar aspects of the tendon footprint leaving approximately 1 cm of bone between each hole (Fig 7). Three parallel holes are drilled through the dorsal cortex about 1 cm distal to the first 3 holes. The drill holes are connected to make 3 curved bone tunnels with the assistance of a small curette (Fig 8). A small towel clip, a pointed tenaculum, or curved awls can be helpful as well. A nonabsorbable high-strength suture, such as a No. 5 Ethibond (Ethicon) or a No. 2 FiberWire (Arthrex) is then passed antegrade through the central tunnel (Fig 9A) then shuttled retrograde through the most lateral tunnel (Figs 9 B and C). A second suture is passed antegrade through the central tunnel while holding the first suture taut (Fig 10A). The lateral suture is pulled back and forth through the central bone



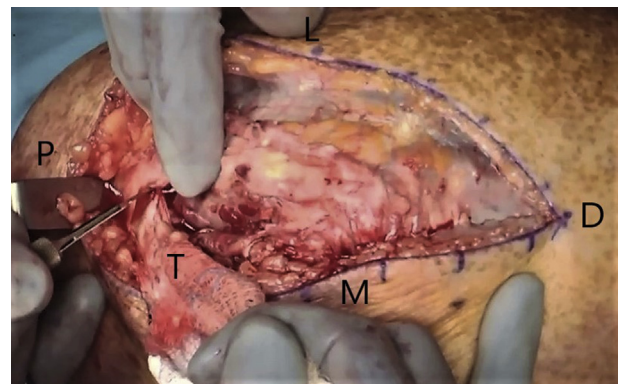
**Fig 2.** The paratenon is incised longitudinally and preserved for later repair. (D, distal; L, lateral; M, medial; P, proximal.)



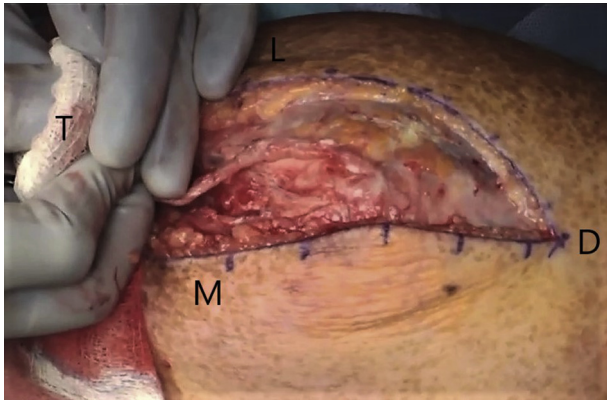
**Fig 3.** The tendon end is grasped with a nonpenetrating clamp over a damp sponge to avoid further traumatizing the ruptured end of the tendon. (D, distal; L, lateral; M, medial; P, proximal; T, triceps tendon.)

tunnel to ensure that the second suture needle did not transect or impale the first suture (Fig 10B). Then the suture is passed retrograde through the most medial tunnel (Fig 10C).

At this point, the suture ends with the needles should be exiting laterally and medially with the free limbs exiting the central tunnel (Fig 10D). The 2 free limbs protruding from the central tunnel will be used as post sutures for a sliding knot at the conclusion of the repair. The lateral suture is then woven proximally and distally within the lateral half of the tendon using a modified Krakow or other running locking stitch (Fig 11). The suture and needle should exit the dorsal surface of the tendon about 1 cm from the distal edge of the tendon and be secured with a fine clamp for tying down later. The free end of the same suture is passed from deep to superficial within the tendon (Fig 12). This post limb along with the limb that was run proximally and distally in the tendon should both be exiting the dorsal surface of the tendon. The same procedure is repeated for the medial half of the tendon (Fig 13A-C).



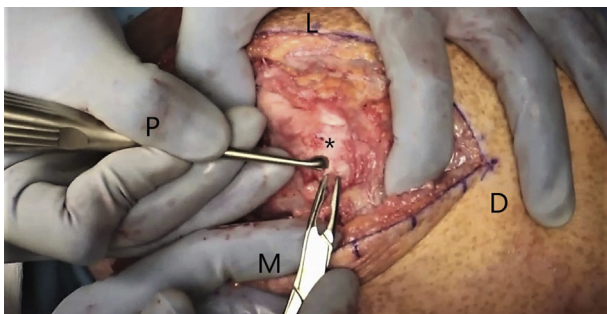
**Fig 4.** A small extension of the longitudinal split between the heads of the triceps may be made to allow for further mobilization of the tendon. (D, distal; L, lateral; M, medial; P, proximal; T, triceps tendon.)



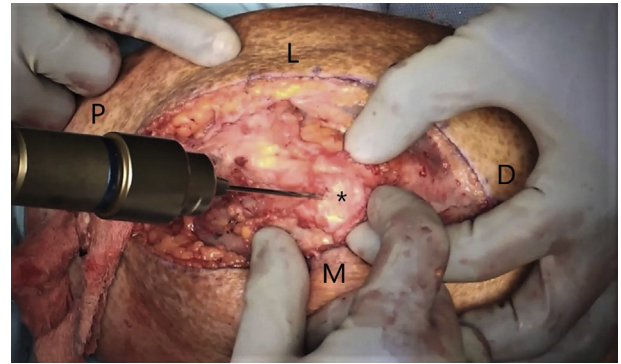
**Fig 5.** Longitudinal tension is applied to the tendon stump for several minutes so the triceps muscle can regain its normal resting length. (D, distal; L, lateral; M, medial; T, triceps tendon.)

Once all sutures have been passed, all sliding knots are tied with the first assistant maintaining enough elbow extension to allow tendon-to-bone contact (Fig 14). Multiple alternating half-hitches over the post limb allow the knot to slide and compress the tendon to its bony footprint (Fig 15). Five to 7 knots are tied into each suture. Although this results in a secure but bulky knot, the knots will end up on the dorsal surface of the triceps tendon about 1 cm proximal to the olecranon tip, where they will be covered by a thicker layer of fat (Fig 16 A and B). This is in contrast to previously described techniques where knots are tied over bone bridges on the dorsal subcutaneous border of the ulna. Sutures are cut and the elbow is brought to 90° to test the construct for gapping between tendon and bone (Video).

The longitudinal split between the heads of the triceps is repaired using nonabsorbable suture (Fig 17). The paratenon is repaired over the entire construct using fine No. 2-0 absorbable suture (Vicryl, Ethicon) (Fig 18). The skin is closed in a layered manner with No. 2-0 absorbable suture (Vicryl) and an alternating No.



**Fig 6.** The bony footprint is cleared of residual tendon and soft-tissue debris, then lightly decorticated using a curette or burr to create a bleeding bed for healing. (\*, olecranon; D, distal; L, lateral; M, medial; P, proximal.)

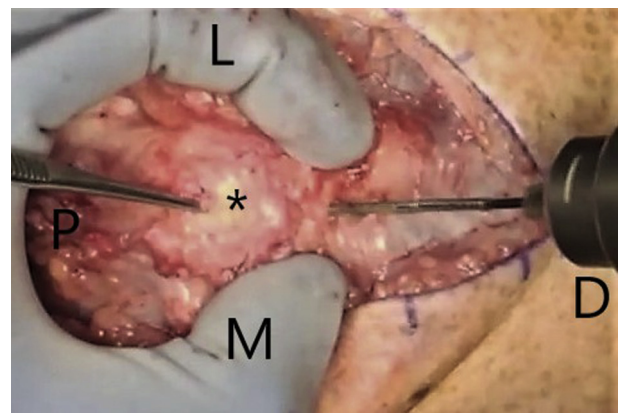


**Fig 7.** A 2-mm drill is used to create 3 holes in the central, radial, and ulnar aspects of the tendon footprint leaving approximately 1 cm of bone between each hole. (\*, olecranon; D, distal; L, lateral; M, medial; P, proximal.)

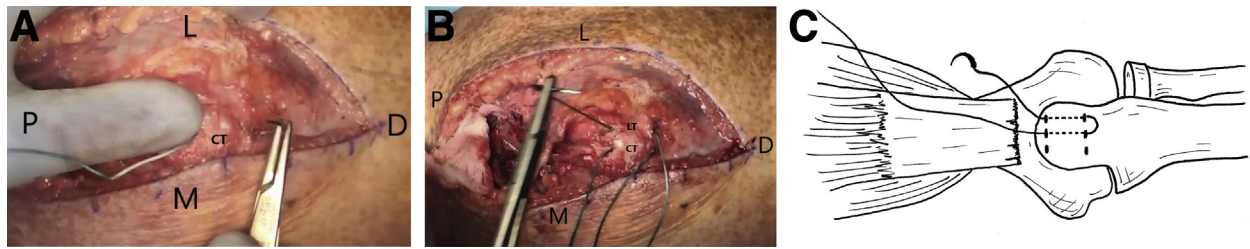
3-0 running nylon suture (Ethilon, Ethicon) (Fig 19 A and B). The arm is placed into a long arm splint or cast in 45° of flexion for 2 weeks, followed by a 90° long arm cast for another 2 weeks. One month postoperatively, the patient begins mobilization with physical therapy. Gentle strengthening including resisted active extension of the elbow may begin after 2 months. Full healing of the tendon should be expected at about 3 months postoperatively; at that point, the patient can return to full unrestricted activity. Tables 1 and 2 outline advantages and disadvantages as well as pearls and pitfalls of this technique.

## Discussion

Given the low prevalence of triceps tendon ruptures, the literature on repair methodology is sparse, especially when comparing different constructs. There are several benefits to our technique. Lack of implants



**Fig 8.** Three parallel holes are drilled through the dorsal cortex about 1 cm distal to the first 3 holes. The drill holes are connected to make 3 curved bone tunnels with the assistance of a small curette. (\*, olecranon; D, distal; L, lateral; M, medial; P, proximal.)

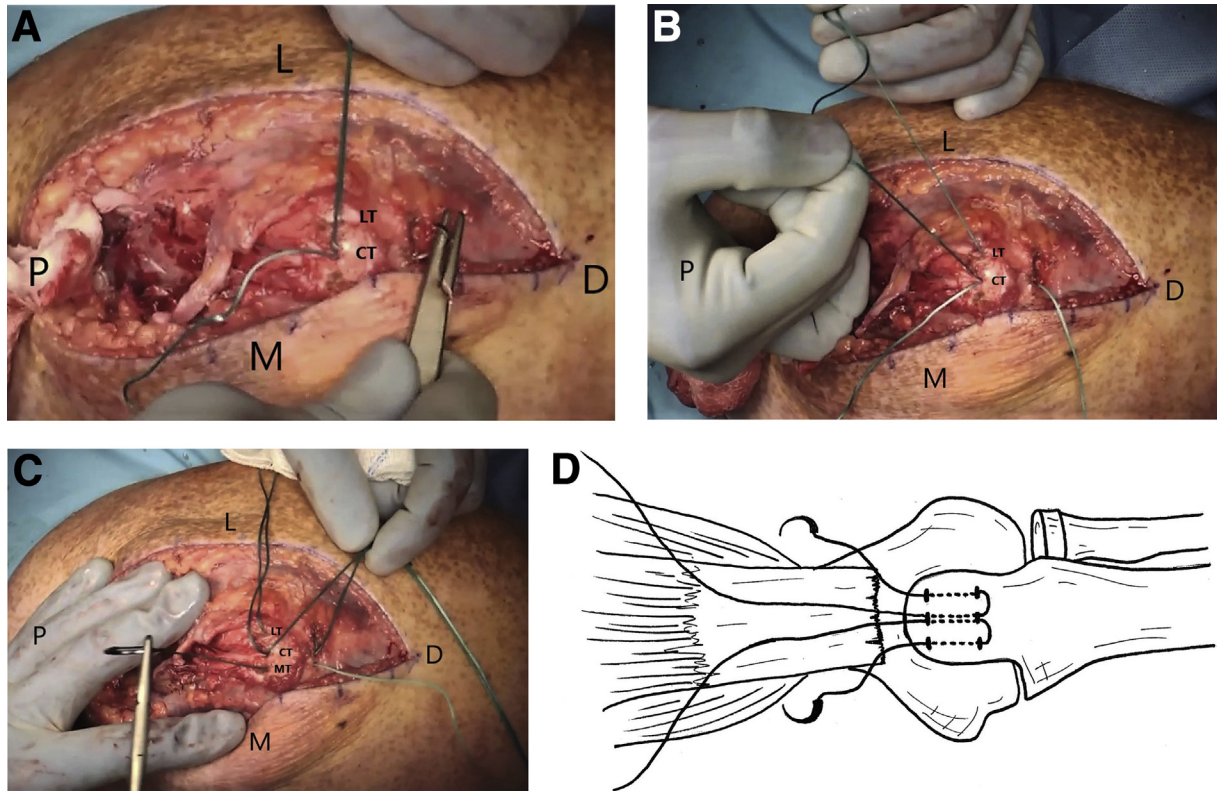


**Fig 9.** (A) A nonabsorbable high-strength suture, such as a No. 5 Ethibond (Ethicon) or a No. 2 FiberWire (Arthrex) is then passed antegrade through the central tunnel. (B) It is then shuttled retrograde through the most lateral tunnel. (C) After the first suture has been passed antegrade through the central tunnel, then shuttled retrograde through the most lateral tunnel. (CT, central tunnel; D, distal; L, lateral; LT, lateral tunnel; M, medial; P, proximal.)

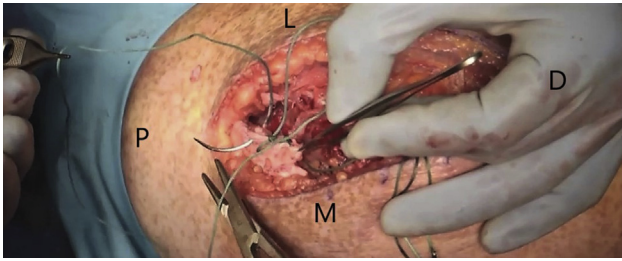
reduces case costs and minimizes instrumentation. Also, the location of the knots proximally reduces the risk of prominence and subsequent postoperative pain.

Traditionally, triceps tendon repairs involved reattaching the tendon with nonabsorbable sutures via bicruciate or parallel bone tunnels.<sup>1,6,8</sup> Most case series report good outcomes, although van Riet et al.<sup>6</sup> had a 21% re-rupture rate. Alternatively, Kose et al.<sup>8</sup> had no re-ruptures and generally good results for their case series of 8 triceps avulsions. Both studies used a

2-strand repair with 1 suture knot.<sup>6,8</sup> In contrast, Sierra et al.<sup>1</sup> used a 3-tunnel technique with a 4-strand repair. In this study, only 1 of 10 patients treated surgically for avulsion injuries had a re-rupture resulting from repeat trauma and there was no mention of failure because of the 3 tunnels. Unfortunately with these techniques, there are large nonabsorbable knots over the subcutaneous dorsal ulna, which have been known to cause postoperative pain and even reoperation for suture removal.<sup>9</sup>



**Fig 10.** (A) A second suture is passed antegrade through the central tunnel while holding the first suture taut. (B) The lateral suture is pulled back and forth through the central bone tunnel to ensure that the second suture needle did not transect or impale the first suture. (C) Then the suture is passed retrograde through the most medial tunnel. (D) The suture ends with the needles should be exiting laterally and medially with the free limbs exiting the central tunnel. (CT, central tunnel; D, distal; L, lateral; LT, lateral tunnel; M, medial; MT, medial tunnel; P, proximal.)



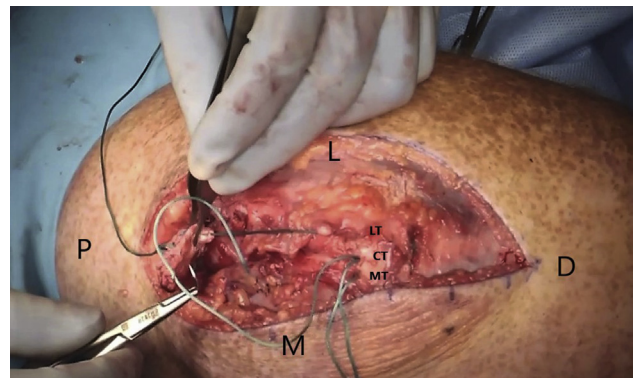
**Fig 11.** The lateral suture is then woven proximally and distally within the lateral half of the tendon using a modified Krakow or other running locking stitch. The suture and needle should exit the dorsal surface of the tendon about 1 cm from the distal edge of the tendon, and secured with a fine clamp for tying down later. (D, distal; L, lateral; M, medial; P, proximal.)

The expansion of suture anchor technology ignited the development of new triceps repair techniques.<sup>3,5,7</sup> Yeh et al.<sup>7</sup> performed a study examining the anatomic footprint of the triceps tendon and compared the biomechanics of a transosseous cruciate repair, a single-row suture anchor repair, and a more anatomic double-row knotless suture anchor repair. They demonstrated that the anatomic double-row method had the lowest repair-site motion and had the most footprint coverage, although peak loads were similar in all 3 groups. Later in 2014, a method was introduced that used a combination of 1 knotless anchor and 2 bone tunnels to minimize cost compared with 4 anchors, knot failure, intra-articular joint breach, as well as subcutaneous irritation.<sup>3,5</sup> This technique demonstrated increased biomechanical strength and resistance to displacement compared with the traditional transosseous cruciate repair.<sup>3,5</sup> This method required 2 Krakow sutures instead of 1 as described in the traditional technique; therefore, the increased amount of suture through the tendon may have contributed to increased strength and durability. More recently, Dorweiler et al.<sup>4</sup> performed a biomechanical study comparing a new anchor-free double row technique with Paci et al.'s<sup>5</sup> double-row knotless anchor suture technique and found similar biomechanical properties between the 2, suggesting that this was a cheaper alternative with a similar strength profile. The benefits of this technique are low cost and lower risk of joint penetration with anchors; however, this method is more technically demanding with the drilling of a total of 4 tunnels, with a theoretical increased risk of iatrogenic fracture. It is important to consider that all of these cadaveric biomechanical studies have not been directly translated to clinical outcomes.

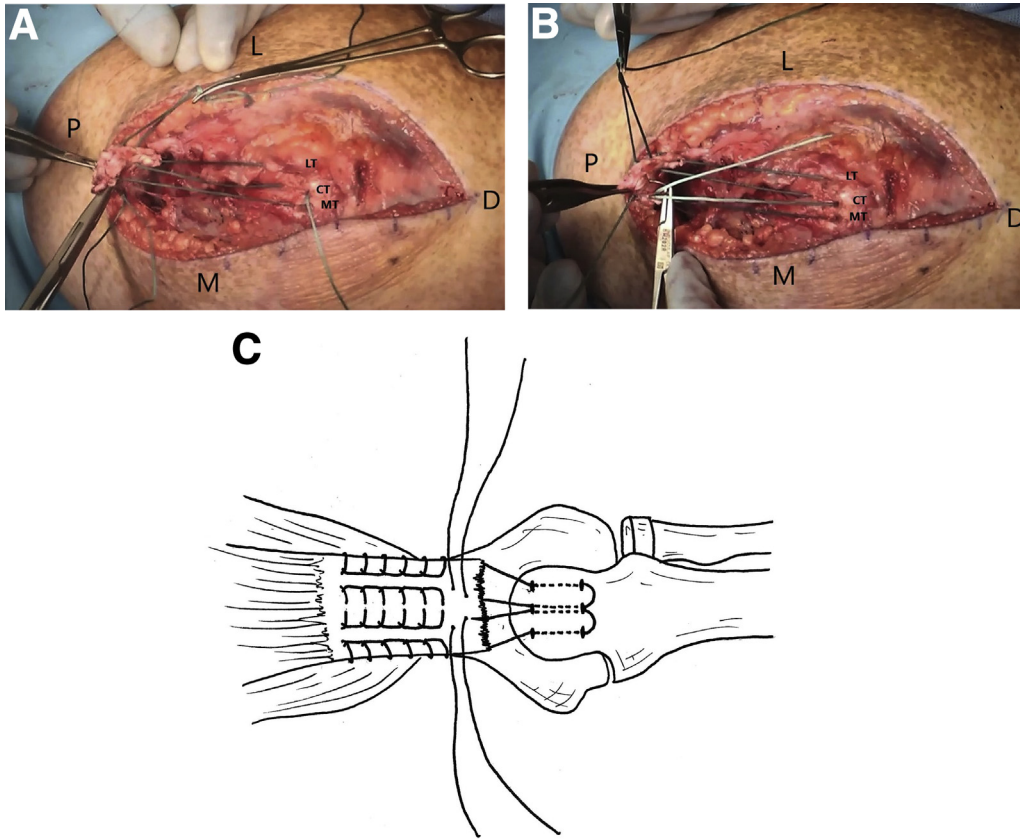
Clinical outcome studies comparing these repair constructs have been limited. Mirzayan et al.<sup>9</sup> retrospectively reviewed 184 cases via a database within a multicenter healthcare system and compared constructs

with at least 1 anchor to those that used a transosseous cruciate technique and found a statistically significant increased rerupture and reoperation rate in the transosseous group but no difference in infection rate. In contrast, Horneff et al.<sup>10</sup> retrospectively reviewed 56 cases, comparing a transosseous repair with suture anchor constructs and examined rerupture rates, patient satisfaction, the visual analog scale, the Mayo Elbow Performance Score, and the postoperative Disabilities of the Arm, Shoulder, and Hand score. They found no statistically significant difference in patient satisfaction, rerupture rates, Mayo Elbow Performance Score, or visual analog scale outcomes based on construct type. They did, however, find a statistically significant difference in the Disabilities of the Arm, Shoulder, and Hand score with the transosseous group averaging 3 points lower, but this was not found to be clinically relevant.<sup>10</sup>

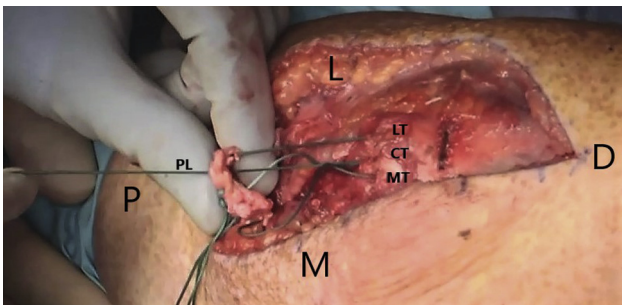
In conclusion, our technique has several strengths. It is relatively simple to perform and it eliminates implant-associated costs. Additionally, this is the only described anchorless technique to our knowledge that has knots proximally without any knots over the ulnar side of the repair, diminishing the potential of postoperative pain and reoperation. A potential drawback to our method includes an additional bone tunnel, which carries a theoretical increased risk of iatrogenic fracture. Furthermore, the careful creation of bone tunnels requires slightly more time and technical skill than insertion of a suture anchor. Several biomechanical studies advocate for an anatomic repair, restoring the anatomic footprint because it provides the construct with the least motion at the tendon-bone interface; however, this has not yet translated to improved clinical outcomes. Further clinical studies are necessary to determine the overall outcomes of this procedure.



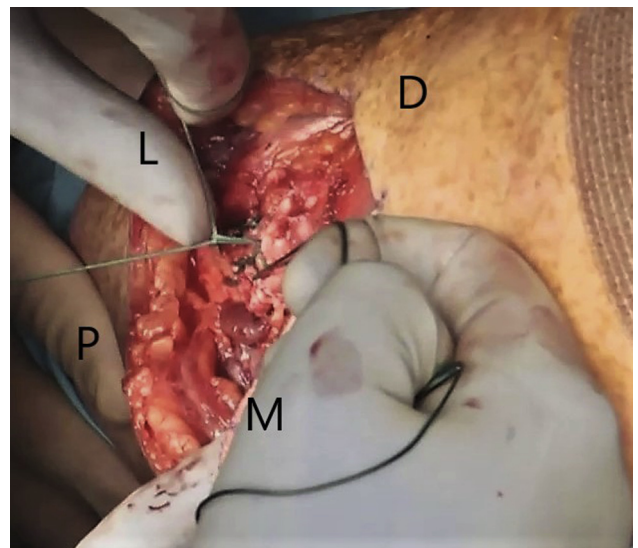
**Fig 12.** The free end of the lateral suture is passed from deep to superficial within the tendon. This post limb along with the limb that was run proximally and distally in the tendon should both be exiting the dorsal surface of the tendon (CT, central tunnel; D, distal; L, lateral; LT, lateral tunnel; M, medial; MT, medial tunnel; P, proximal.)



**Fig 13.** (A) The medial suture is woven proximally and distally within the medial half of the tendon using a modified Krakow or other running locking stitch. The suture and needle should exit the dorsal surface of the tendon about 1 cm from the distal edge of the tendon. (B) The free end of the medial suture is passed from deep to superficial within the tendon. (C) All sutures exiting the dorsal surface of the tendon. (CT, central tunnel; D, distal; L, lateral; LT, lateral tunnel; M, medial; MT, medial tunnel; P, proximal.)

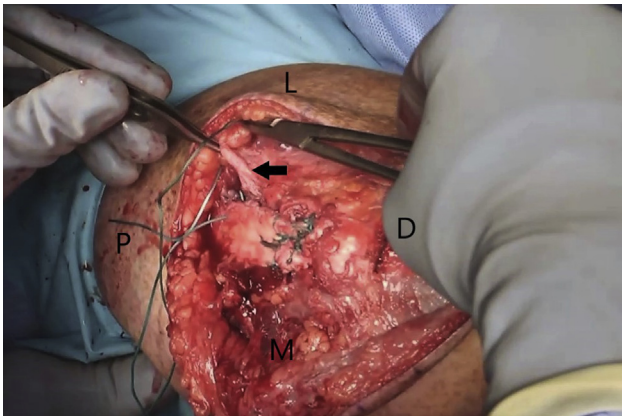
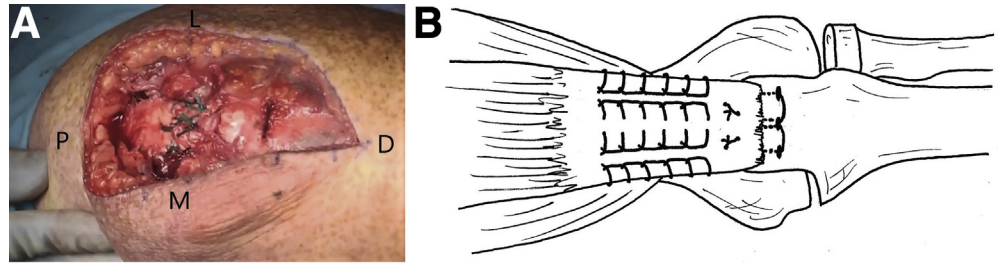


**Fig 14.** Once all sutures have been passed, all sliding knots are tied with the first assistant maintaining enough elbow extension to allow tendon-to-bone contact. The free limbs of the sutures act as posts to allow the tendon to slide directly down to bone. (CT, central tunnel; D, distal; L, lateral; LT, lateral tunnel; M, medial; MT, medial tunnel; P, proximal; PL, post limb.)

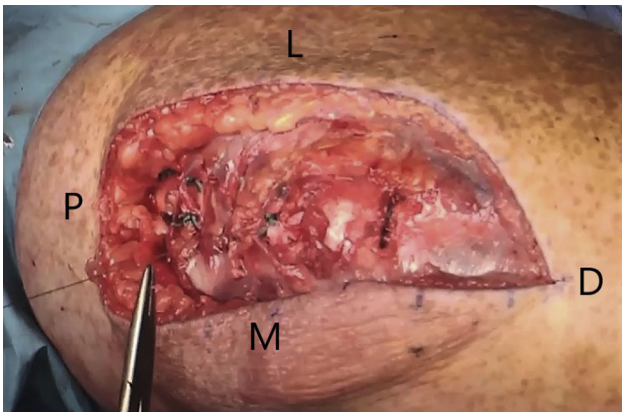


**Fig 15.** Multiple alternating half-hitches over the post limb allow the knot to slide and compress the tendon to its bony footprint. (D, distal; L, lateral; M, medial; P, proximal.)

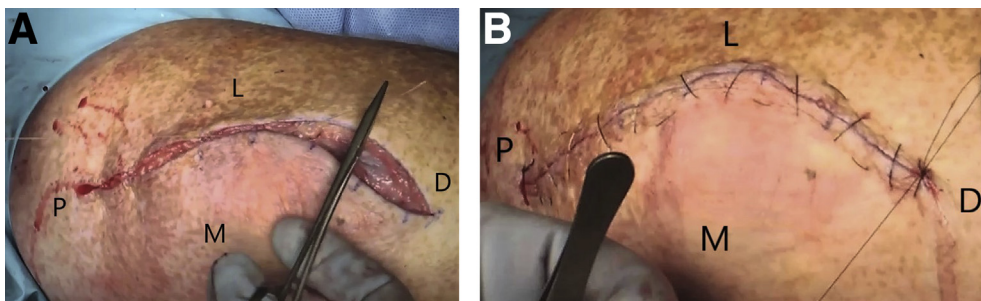
**Fig 16.** (A) The knots will end up on the dorsal surface of the triceps tendon about 1 cm proximal to the olecranon tip, where they will be covered by a thicker layer of fat. (B) The final repair with proximal knots. (D, distal; L, lateral; M, medial; P, proximal.)



**Fig 17.** The longitudinal split between the heads of the triceps is repaired using nonabsorbable suture. (Arrow, split in triceps; D, distal; L, lateral; M, medial; P, proximal.)



**Fig 18.** The paratenon is repaired over the construct using fine No. 2-0 absorbable suture (Vicryl, Ethicon). (D, distal; L, lateral; M, medial; P, proximal.)



**Fig 19.** (A) The incision is closed in a layered manner with an interrupted subcuticular No. 2-0 absorbable suture (Vicryl, Ethicon) and (B) an alternating No. 3-0 running nylon suture (Ethilon, Ethicon). (D, distal; L, lateral; M, medial; P, proximal.)

**Table 1.** Advantages and Disadvantages of Acute Triceps Tendon Repair With 3 Curved Tunnels and Proximal Knots

Advantages	Disadvantages/Limitations
Simple and reproducible	Theoretical increased risk of iatrogenic fracture
No implants/minimal cost	Not ideal for osteoporotic bone
Minimal knot irritation because of proximal location	

**Table 2.** Pearls and Pitfalls of Acute Triceps Tendon Repair With 3 Curved Tunnels and Proximal Knots

Pearls	Pitfalls
Spread drill holes out evenly	If drill holes are too close, may cause fracture
Make sure first suture was not speared by second suture when passing the suture antegrade through central tunnel	
Fully extend elbow when tying down knots	

### Acknowledgments

The illustrations were drawn by Kyle P. Lavery, M.D. Owen McGonigle, M.D., contributed to the technique video.

### References

- Sierra RJ, Weiss NG, Shrader MW, Steinmann SP. Acute triceps ruptures: Case report and retrospective chart review. *J Shoulder Elbow Surg* 2006;15:130-134.
- Balazs GC, Brelin AM, Dworak TC, et al. Outcomes and complications of triceps tendon repair following acute rupture in American military personnel. *Injury* 2016;47:2247-2251.
- Clark J, Obopilwe E, Rizzi A, et al. Distal triceps knotless anatomic footprint repair is superior to transosseous cruciate repair: A biomechanical comparison. *Arthroscopy* 2014;30:1254-1260.
- Dorweiler MA, Van Dyke RO, Siska RC, Boin MA, DiPaola MJ. A comparative biomechanical analysis of 2 double-row, distal triceps tendon repairs. *Orthop J Sports Med* 2017;5. 2325967117708308.
- Paci JM, Clark J, Rizzi A. Distal triceps knotless anatomic footprint repair: A new technique. *Arthrosc Tech* 2014;3:e621-e626.
- van Riet RP, Morrey BF, Ho E, O'Driscoll SW. Surgical treatment of distal triceps ruptures. *J Bone Joint Surg Am* 2003;85-A:1961-1967.
- Yeh PC, Stephens KT, Solovyova O, et al. The distal triceps tendon footprint and a biomechanical analysis of 3 repair techniques. *Am J Sports Med* 2010;38:1025-1033.
- Kose O, Kilicaslan OF, Guler F, Acar B, Yuksel HY. Functional outcomes and complications after surgical repair of triceps tendon rupture. *Eur J Orthop Surg Traumatol* 2015;25:1131-1139.
- Mirzayan R, Acevedo DC, Sodl JF, et al. Operative management of acute triceps tendon ruptures: Review of 184 cases. *Am J Sports Med* 2018;46:1451-1458.
- Horneff JG 3rd, Aleem A, Nicholson T, et al. Functional outcomes of distal triceps tendon repair comparing transosseous bone tunnels with suture anchor constructs. *J Shoulder Elbow Surg* 2017;26:2213-2219.