

Accidental aspiration of head scarf pin in left bronchus piercing the lung parenchyma: A rare case in a child

Yusuf Parvez, Mohammed Ashraf Kandath

Department of Pediatrics, Dubai Hospital, Dubai, United Arab Emirates

ABSTRACT

Foreign body (FB) aspiration is commonly seen in children but less commonly in adolescents. Headscarf pin aspiration is common in Muslim girls, who inappropriately place the pins between their lips while securing the scarf on the head. Bronchoscopy is the treatment modality of choice, and surgery is rarely required. An 11-year-old girl was admitted as a case of accidental aspiration of headscarf pin. X-ray chest showed a radiopaque object in the left bronchus piercing the lung parenchyma. Computed tomography (CT) chest confirmed the diagnosis. The headscarf pin was removed by flexible bronchoscopy as the ear, nose, and throat (ENT) surgeon failed to remove it by rigid bronchoscopy. The FB was removed successfully and the patient was discharged home. Removal of a sharp pin by bronchoscopy is difficult, especially if it pierces the lung parenchyma. In our case, the pin was bent by forceps and then removed by a flexible bronchoscope, which requires a highly skilled professional.

KEY WORDS: Aspiration, bronchoscopy, headscarf pin

Address for correspondence: Dr. Yusuf Parvez, Department of Pediatrics, Dubai Hospital, Dubai - 7272, United Arab Emirates.
E-mail: dryparvez@gmail.com

INTRODUCTION

Foreign body (FB) aspiration is a common problem in young children. Frequently encountered FBs include coins, batteries, and magnets, but there is a distinct group of cases of Muslim children who wear headscarves inappropriately placing the safety pin in their mouth prior to securing the veil, leading to an accidental FB aspiration.^[1-3] We report a classic case to highlight the presentation and management of such a FB.

CASE REPORT

An 11-year-old Muslim girl was admitted to our hospital due to accidental aspiration of a headscarf pin. She aspirated the pin while securing her scarf and holding the pin in the mouth. She was hemodynamically stable, and the systemic examination was unremarkable. Initial chest x-ray showed a sharp radiopaque object in the

left bronchus piercing the lung parenchyma. Computed tomography (CT) chest was performed as requested by the thoracic surgeon for possible thoracotomy in case the bronchoscopy failed to remove the pin. CT chest confirmed the finding of x-ray chest [Figure 1].

An ear, nose, and throat (ENT) surgeon failed to remove the pin by rigid bronchoscopy. A pediatric pulmonologist successfully removed the pin using flexible bronchoscopy, by bending the pin with forceps [Figures 2 and 3]. The repeat x-ray chest after the procedure was absolutely normal. The child did not have any complications after the procedure and was discharged home.

DISCUSSION

FB aspiration remains a common problem among young children. The nature of the FB varies according to region,

Access this article online

Quick Response Code:



Website:

www.lungindia.com

DOI:

10.4103/0970-2113.184914

This is an open access article distributed under the terms of the Creative Commons Attribution-NonCommercial-ShareAlike 3.0 License, which allows others to remix, tweak, and build upon the work non-commercially, as long as the author is credited and the new creations are licensed under the identical terms.

For reprints contact: reprints@medknow.com

How to cite this article: Parvez Y, Kandath MA. Accidental aspiration of head scarf pin in left bronchus piercing the lung parenchyma: A rare case in a child. Lung India 2016;33:424-6.

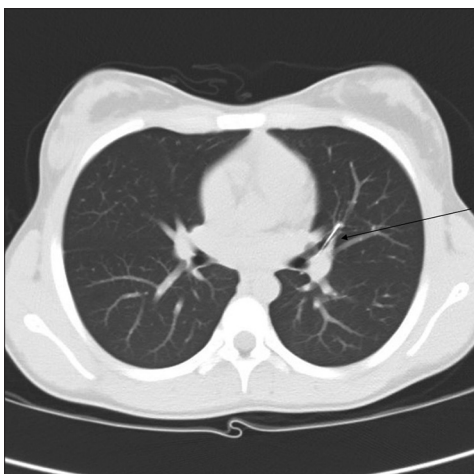


Figure 1: CT chest showing sharp pin in left bronchus piercing the lung parenchyma

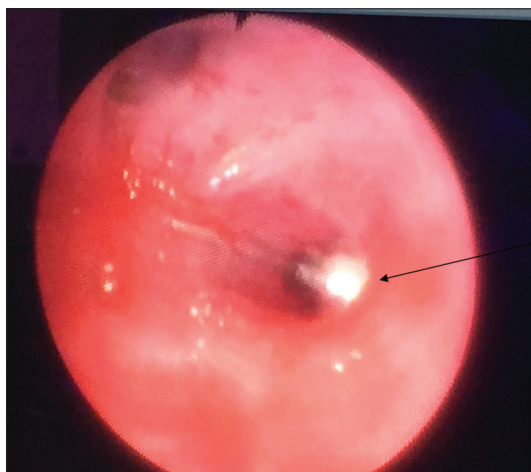


Figure 2: Endoscopic view of sharp pin piercing the lung parenchyma

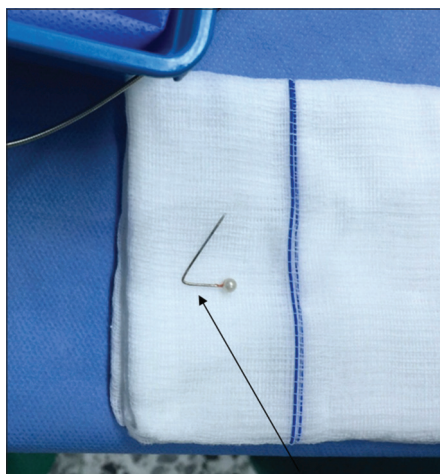

Figure 3: Sharp pin was bent to remove it endoscopically

age, food habits, and even clothing habits, but there is a common classification of organic and inorganic

FB aspiration.^[1,2,4] Organic materials such as nuts and seeds are the most commonly aspirated, while inorganic materials include a wide range of objects such as coins, plastic pieces, and toy parts. The younger age group is more vulnerable because of the lack of adequate dentition and immature swallowing coordination. In addition, among children of this age, introducing objects into their mouths is their way of exploring the world. Muslim girls wearing headscarves because of sociocultural and religious tradition sometimes accidentally aspirate a headscarf pin while holding the pin between their lips in order to secure the veil. Any maneuver then, such as laughter, talking, or coughing, predisposes them to aspiration, especially in the young teenage groups where they lack experience with such maneuvers.^[1-3] This has been reported in the literature as “turban pin syndrome.”^[5,6] In contrast to other forms of FB aspiration, headscarf pin aspirations tend to be easily diagnosed by x-ray chest as all of these inhaled FBs are radiopaque.^[1,4] Complications of intrabronchial FB are obstructive emphysema, recurrent pneumopathy, bronchiectasis, pulmonary abscess, pleural effusion, and even pneumomediastinum.^[7-9] Diagnostic bronchoscopy is rarely needed; rather, a therapeutic intervention is required. Rigid bronchoscopy is not successful, especially if the FB is distally located, hence flexible bronchoscopy is required in such cases. However, rigid bronchoscopy is preferred in children as it allows very efficient airway suctioning in case of massive bleed and is not time-consuming.^[10,11] Cases have been reported where distally located FBs were removed by fluoroscopically guided catheters in a cardiac catheterization lab.^[12] Thoracotomy and bronchotomy are rarely required for the removal of FBs.^[13] The aspiration hazard can be minimized by using adhesive bands or snap fasteners instead of pins when wearing a scarf.

CONCLUSION

Headscarf pin aspiration is common in Muslim girls, and the pins can usually be removed by flexible bronchoscopy. However, when the pin pierces the lung parenchyma, which is rare, it is necessary for a highly skilled pulmonologist to remove it endoscopically.

Financial support and sponsorship

Nil.

Conflicts of interest

There are no conflicts of interest.

REFERENCES

1. Hebbazi A, Afif H, El Khattabi W, Aichane A, Bouayad Z. Scarf pin: A new intrabronchial foreign body. *Rev Mal Respir* 2010;27:724-8.
2. El Koraïchi A, Mokhtari M, El Haddoury M, El Kettani SE. Rigid bronchoscopy for pin extraction in children at the Children’s Hospital in Rabat, Morocco. *Rev Pneumol Clin* 2011;67:309-13.
3. Arsalane A, Zidane A, Atoini F, Traïbi A, Kabiri EH. The surgical extraction of foreign bodies after the inhalation of a scarf pin: Two cases. *Rev Pneumol Clin* 2009;65:293-6.

4. Zaghba N, Benjelloun H, Bakhatar A, Yassine N, Bahlaoui A. Scarf pin: An intrabronchial foreign body who is not unusual. *Rev Pneumol Clin* 2013;69:65-9.
5. Hasdiraz L, Bicer C, Bilgin M, Oguzkaya F. Turban pin aspiration: Non-asphyxiating tracheobronchial foreign body in young Islamic women. *Thorac Cardiovasc Surg* 2006;54:273-5.
6. Kaptanoglu M, Nadir A, Dogan K, Sahin E. The heterodox nature of "Turban Pins" in foreign body aspiration; the central anatolian experience. *Int J Pediatr Otorhinolaryngol* 2007;71:553-8.
7. Caidi M, Kabiri H, Lazrek I, el Maslout A, Ben Osman A. Surgery for intra-bronchial foreign bodies. *Ann Chir* 2002;127:456-60.
8. Mehta A, Sarin D. Subcutaneous emphysema: An unusual presentation of foreign body bronchus. *Med J Armed Forces India* 2007;63:71-2.
9. Aggarwal SK, Keshri A. Subcutaneous emphysema: An unusual presentation of an unsuspected foreign body bronchus in an adult patient. *J Laryngol Voice* 2012;2:38-41.
10. Üskül TB, Türker H, Arslan S, Selvi A, Kant A. Use of Fiberoptic bronchoscopy in endobronchial foreign body removal in adults. *Turk Respir J* 2007;8:39-43.
11. Al-Ali MA, Khassawneh B, Alzoubi F. Utility of fiberoptic bronchoscopy for retrieval of aspirated headscarf pins. *Respiration* 2007;74:309-13.
12. Thatte NM, Guglani L, Turner DR, Forbes TJ, Gowda ST. Retrieval of endobronchial foreign bodies in children: Involving the cardiac catheterization lab. *Pediatrics* 2014;134:e865-9.
13. Murthy PS, Ingle VS, George E, Ramakrishna S, Shah FA. Sharp foreign bodies in the tracheobronchial tree. *Am J Otolaryngol* 2001;22:154-6.