

Contents lists available at [ScienceDirect](http://www.sciencedirect.com)

International Journal of Surgery Case Reports

journal homepage: www.casereports.com

An unusual case of asymptomatic non-urothelial bladder tumour

Daniel Ching^a, Eleni Anastasiadis^b, Sarb Sandhu^{b,*}^a Fiona Stanley Hospital, Western Australia, Australia^b Department of Urology, Kingston Hospital NHS Foundation Trust, United Kingdom

ARTICLE INFO

Article history:

Received 27 March 2016

Received in revised form 9 July 2016

Accepted 10 July 2016

Available online 14 July 2016

Keywords:

Urinary bladder neoplasms

Non-urothelial bladder tumour

Paraganglioma

Extra-adrenal

Cystoscopy and transurethral resection

Case report

ABSTRACT

INTRODUCTION: Non-urothelial tumours are rare and account for less than 5% of all bladder tumours. Bladder paragangliomas also known as extra-adrenal pheochromocytomas are of the non-urothelial subgroup. We present an unusual case of asymptomatic bladder paraganglioma.

CASE REPORT: A 77 year old lady presented with acute abdominal pain was found to have an incidental enhancing nodule in the bladder. During cystoscopy and transurethral resection the patient experienced significant fluctuations in blood pressure that required anaesthetic adjustments. Review of histology confirmed a diagnosis of bladder paraganglioma.

DISCUSSION: Most bladder paraganglioma cases present with sympathomimetic related symptoms and microscopic haematuria but our patient was asymptomatic which resulted in inadequate pre-operative optimisation and high anaesthetic risk. Majority of paragangliomas are benign but there is a 20–40% chance of malignancy. The management options will predominantly depend on whether disease is localised, regional, metastatic or recurrent in nature.

CONCLUSION: Due to the non-specific nature of disease, variability of presentations and rare incidence, bladder paragangliomas are often not part of the urologists' differential diagnoses. In our opinion, establishing guidelines should assist to achieve a balance between anaesthetic risks, cystoscopy and follow up.

© 2016 Published by Elsevier Ltd on behalf of IJS Publishing Group Ltd. This is an open access article under the CC BY-NC-ND license (<http://creativecommons.org/licenses/by-nc-nd/4.0/>).

1. Introduction

Bladder tumours can be subdivided into urothelial and non-urothelial tumours. They usually present as urothelial tumours, with non-urothelial tumours accounting for less than 5% of all bladder tumours. Bladder paragangliomas (also known as extra-adrenal pheochromocytomas) are of the non-urothelial subgroup [1]. We present an unusual case of asymptomatic bladder paraganglioma.

2. Case report

A 77 year old lady presented to the emergency department with acute abdominal pain. A Computed Tomography (CT) abdomen and pelvis with contrast performed demonstrated an incidental enhancing nodule anteriorly in the bladder measuring 2.2 cm (Figs. 1 and 2). The patient was referred to the urology multi-disciplinary team (MDT) which decided further investigation was warranted with cystoscopy and a transurethral resection.

During the resection under general anaesthesia, the patient experienced significant fluctuations in blood pressure (BP) that

required intermittent breaks and pharmacological adjustment. Macroscopically the tumour was a tan brown lesion with normal smooth bladder mucosa.

Review of histology confirmed a diagnosis of a bladder paraganglioma (Figs. 3, 4 and 5). CD56 and chromogranin immunostains are commonly used neuroendocrine markers. The brown staining on both immunostains shows evidence for neuroendocrine cells. As the patient had multiple intra-abdominal surgeries and there was no evidence of metastatic spread on the CT scan, the MDT's decision was for 3 monthly follow-up with surveillance cystoscopies post-resection and depending on clinical features for further biochemical and radiological investigations as needed.

3. Discussion

The incidence of bladder paragangliomas is less than 0.05% of all bladder tumours [2] and less than 1% of all paragangliomas [3]. The mean patient age was 43.3 years (range 11–84) and has an almost equal male to female ratio of 1.07:1 [4].

A systemic review found 106 patients and demonstrated that majority of cases presented with catecholamine secretion leading to sympathomimetic related symptoms. The most common symptoms at presentation in decreasing order are hypertension, headaches, haematuria and syncope/palpitations [3]. They are often triggered during micturition hence termed 'micturition attacks' and

* Corresponding author at: Consultant Urologist, Department of Urology, Kingston Hospital, Galsworthy Road, KT2 7QB, United Kingdom.

E-mail address: Sarbinder.sandhu@kingstonhospital.nhs.uk (S. Sandhu).

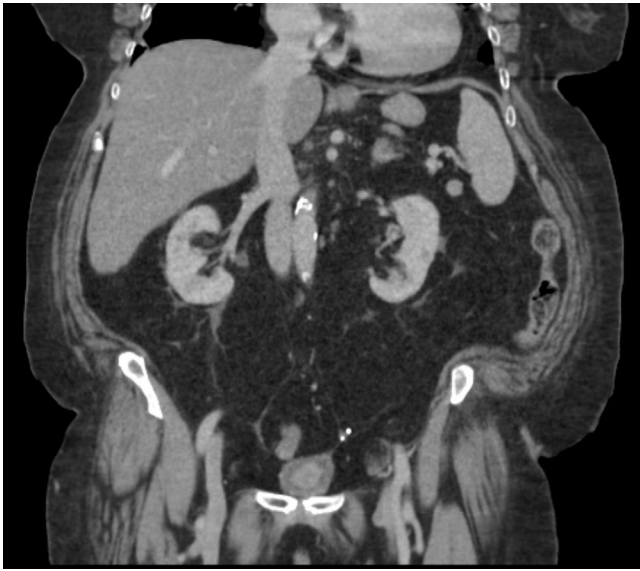

Fig. 1. Coronal view showing bladder enhancing nodule.

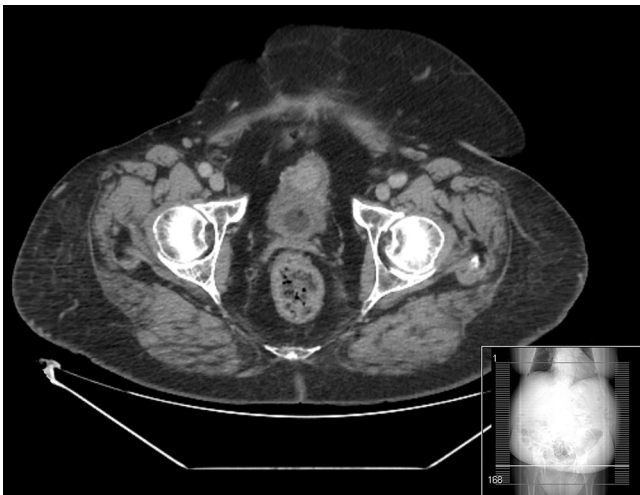

Fig. 2. Axial section demonstrating bladder enhancing nodule.

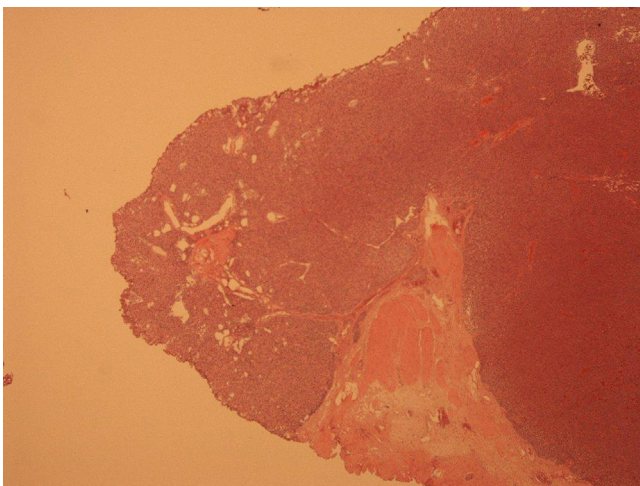


Fig. 3. Low power view with Hematoxylin & Eosin stain demonstrating the solid tumour compressing muscle.

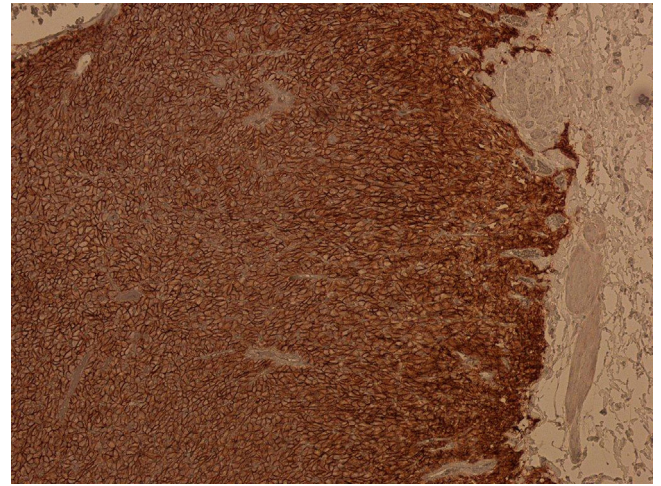


Fig. 4. CD56 stain with brown colour highlighting positive paraganglioma tumour cells. No necrotic areas or mitoses were seen. Antigen Ki-67 is less than 5%.

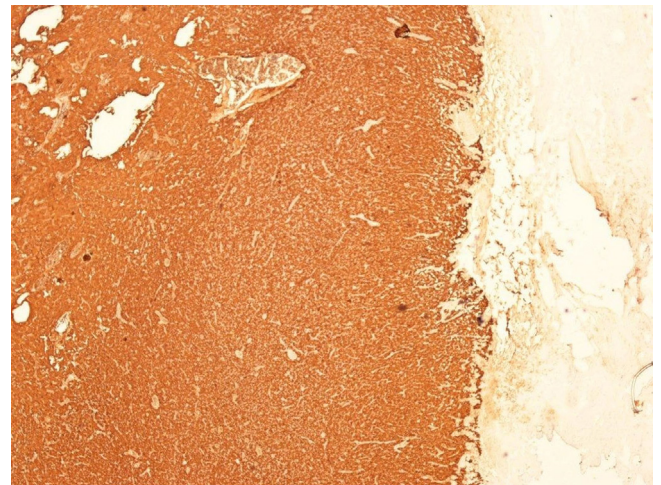


Fig. 5. Chromogranin immunostain with brown colour demonstrating positive neuroendocrine cells.

are reported in 52.8% of patients [3]. Patients were reported to have haematuria in 47–60% of cases and most were of microscopic nature [3,5]. The literature dictates that only 27% of patients had no indication of hormonal activity [6], and 3% of cases were incidental findings [3]. Our patient had moderate hypertension controlled with one anti-hypertensive, did not experience any other symptoms and had a negative urine specimen.

In an asymptomatic incidental bladder lesion it is almost impossible to diagnose bladder paraganglioma without histological diagnosis. Suspicious cases are usually investigated by measuring the level of catecholamine and its metabolites (metanephrine and vanillylmandelic acid secretion) in blood and urine [7,8]. A flexible cystoscopy may be warranted as a form of preliminary investigation especially in symptomatic patients. CT or Magnetic Resonance Imaging can identify the location and extent of the invasion. Advanced methods with the use of nuclear medicine scanning using radioisotope ¹²³I- or ¹³¹I-iodine-metaiodobenzylguanidine and Positron Emission Tomography should be considered, and is the imaging modality of choice for localizing small tumours [9–11].

Prior to any surgical intervention, careful pre-operative management is required. A pre-operative treatment period of 1–3 weeks with alpha-adrenergic blockade is recommended to avoid intra/post-operative complications such as hypertensive crisis, arrhythmias, myocardial infarction and pulmonary oedema. Beta-

adrenergic blockade can be considered pre-operatively, especially in patients with persistent arrhythmias or tachycardia, but must never be initiated before alpha-adrenergic blockade because doing so leads to unopposed alpha-adrenergic vasoconstriction which can lead to a life-threatening crisis [12]. Good symptomatic control and a target low BP for age are features of adequate medical optimisation.

The macroscopic appearance of tan brown lesion seen on cystoscopy is not pathognomic for any form of bladder tumour. According to literature, majority of paragangliomas are benign with a 20–40% of chance of malignancy [13]. There is no single parameter that can predict the malignant potential of paragangliomas. In practice, the only reliable criterion for malignancy is the presence of distant metastases [12]. At present, novel molecular biomarkers are being investigated for their utility in defining malignant tumours.

The management options will predominantly depend on whether disease is localised, regional, metastatic or recurrent in nature. Patients with disease dissemination will require management with a combination of surgery, chemotherapy and/or radiotherapy [14,15]. There is currently no consensus on the management of localised/regional cases. Some studies advocate a partial or complete cystectomy as there is a chance of recurrence from chromaffin cells in the sympathetic plexus of detrusor muscle, and a transurethral resection approach does not adequately excise the lesion. Most however agree that regular follow-up is necessary [13]. Prognostic factors that can be used as a guide include large size (>5 cm diameter), local tumour extension, and the presence of necrotic areas [12,13].

4. Conclusion

Due to the non-specific nature of disease, variability of presentations and rare incidence, bladder paragangliomas are often not part of the urologist's differential diagnoses. This article hopes to add to the limited cases of asymptomatic incidental bladder paragangliomas in the literature and illustrate the importance of suspecting its possibility to reduce operative risk. The involvement of the MDT is essential to ensure patient safety. We support the notion that all cases necessitate long-term follow up which will be dictated by the extent of disease involvement. In our opinion, establishing guidelines should assist to achieve a balance between anaesthetic risks, cystoscopy and follow up. Further research is required to establish best practice in localised bladder paraganglioma management.

Conflicts of interest

All authors declare that there is no conflict of interest.

Funding

This research received no specific grant from any funding agency in the public, commercial, or not - for - profit sectors.

Ethical Approval

Not applicable.

Consent

Written informed consent was obtained from the patient for their anonymised information to be published in this article.

Author contribution

DC and EA researched literature and conceived the study. DC wrote the first draft of the manuscript.

All authors reviewed and edited the manuscript and approved the final version of the manuscript.

Guarantor

SS is the guarantor of the study.

References

- [1] Y. Alderazi, M.W. Yeh, B.G. Robinson, D.E. Benn, M.S. Sywak, D.L. Learoyd, et al., Pheochromocytoma: current concepts, *MJA* 183 (4) (2005) 201–204.
- [2] P. Dahm, J.E. Gschwend, Malignant non-urothelial neoplasms of the urinary bladder: a review, *Eur. Urol.* 44 (6) (2003 Dec) 672–681.
- [3] J.A. Beilan, A. Lawton, J. Hajdenberg, C.J. Rosser, Pheochromocytoma of the urinary bladder: a systematic review of the contemporary literature, *BMC Urol.* 13 (2013 Apr 29) 22.
- [4] J. Beilan, A. Lawton, J. Hajdenberg, C.J. Rosser, Locally advanced paraganglioma of the urinary bladder: a case report, *BMC Res. Notes.* 6 (2013) 156, Apr 18.
- [5] C.C. Tsai, W.J. Wu, K.S. Chueh, W.M. Li, C.H. Huang, C.C. Wu, et al., Paraganglioma of the urinary bladder first presented by bladder bloody tamponade: two case reports and review of the literatures, *Kaohsiung J. Med. Sci.* 27 (3) (2011) 108–113, Epub 2011 February 16.
- [6] W. Li, B. Yang, J.P. Che, Y. Yan, M. Liu, Q.Y. Li, et al., Diagnosis and treatment of extra-adrenal pheochromocytoma of urinary bladder: case report and literature review, *Int. J. Clin. Exp. Med.* 6 (September (9)) (2013) 832–839, eCollection 2013.
- [7] J.W. Lenders, K. Pacak, M.M. Walther, W.M. Linehan, M. Mannelli, P. Friberg, et al., Biochemical diagnosis of pheochromocytoma: which test is best? *JAMA* 287 (11) (2002 Mar) 1427–1434.
- [8] A.M. Sawka, R. Jaeschke, R.J. Singh, W.F. Young Jr., A comparison of biochemical tests for pheochromocytoma: measurement of fractionated plasma metanephrines compared with the combination of 24-hour urinary metanephrines and catecholamines, *J. Clin. Endocrinol. Metab.* 88 (February (2)) (2003) 553–558.
- [9] J.J. Hwang, E.M. Uchio, S.V. Patel, W.M. Linehan, M.M. Walther, K. Pacak, Diagnostic localization of malignant bladder pheochromocytoma using 6–18F fluorodopamine positron emission tomography, *J. Urol.* 169 (January (1)) (2003) 274–275.
- [10] I. Ilias, K. Pacak, Current approaches and recommended algorithm for the diagnostic localization of pheochromocytoma, *J. Clin. Endocrinol. Metab.* 89 (February (2)) (2004) 479–491.
- [11] N. Furuta, H. Kiyota, F. Yoshigoe, N. Hasegawa, Y. Ohishi, Diagnosis of pheochromocytoma using [123I]-compared with [131I]-metaiodobenzylguanidine scintigraphy, *Int. J. Urol.* 6 (March (3)) (1999) 119–124.
- [12] I. Zeitlin, H. Dessau, M. Lorberboym, Y. Beigel, Malignant pheochromocytoma of the urinary bladder: challenges in diagnosis and management, *Isr. Med. Assoc. J.* 13 (5May (5)) (2011) 311–313.
- [13] G. Parenti, B. Zampetti, E. Rapizzi, T. Ercolino, V. Giache, M. Mannelli, Updated and new perspectives on diagnosis, prognosis, and therapy of malignant pheochromocytoma/paraganglioma, *J. Oncol.* 2012 (2012) 872713, Epub 2012 July 17.
- [14] S.D. Averbuch, C.S. Steakley, R.C. Young, E.P. Gelmann, D.S. Goldstein, R. Stull, et al., Malignant pheochromocytoma: effective treatment with a combination of cyclophosphamide, vincristine, and dacarbazine, *Ann. Int. Med.* 109 (August (4)) (1988) 267–273.
- [15] J.R. Buscombe, J.B. Cwikla, M.E. Caplin, A.J. Hilson, Long-term efficacy of low activity meta-[131I]iodobenzylguanidine therapy in patients with disseminated neuroendocrine tumours depends on initial response, *Nucl. Med. Commun.* 26 (November (11)) (2005) 969–976.

Open Access

This article is published Open Access at sciedirect.com. It is distributed under the [IJSCR Supplemental terms and conditions](#), which permits unrestricted non commercial use, distribution, and reproduction in any medium, provided the original authors and source are credited.