

BASIC RESEARCH

Efficacy of vitamin E and selenium for the prevention of intra-abdominal adhesions in rats: uterine horn models

Ali Said Durmus,^I Hamit Yildiz,^{II} Ihsan Yaman,^{III} Halil Simsek^{IV}

^I Department of Surgery, Faculty of Veterinary Medicine, Firat University, Elazig, Turkey. ^{II} Department of Obstetrics and Gynecology, Faculty of Veterinary Medicine, Firat University, Elazig, Turkey. ^{III} Department of Animal Breeding, Sivrice Vocational College, Firat University, Elazig, Turkey. ^{IV} Sanitary Services Vocational School of Higher Education, Bingol University, Bingol, Turkey.

OBJECTIVE: This study compares the efficacies of vitamin E and selenium, both individually and in combination, for the prevention of postoperative intra-abdominal adhesions in rats.

METHODS: Forty-seven female rats were divided into five groups. The sham animals (S group, n = 7) were given only laparotomies and intraperitoneally received 0.9% NaCl (2 ml). In the 40 other rats, abrasions of the left uterine horn were performed, followed by intraperitoneal administration of either 2 ml 0.9% NaCl (C group), 10 mg vitamin E (vitamin E group), 0.2 mg/kg selenium (Se group) or 10 mg vitamin E with 0.2 mg/kg selenium (vitamin E + Se group), with 10 animals in each treatment group.

RESULTS: Adhesion formation was significantly reduced in animals in the Se and vitamin E + Se groups ($p < 0.05$). Tissue catalase and glutathione peroxidase activities did not significantly differ between the groups. However, catalase and glutathione peroxidase activities and reduced glutathione levels were slightly increased in the vitamin E, Se and vitamin E + Se groups. In the vitamin E group, malondialdehyde concentrations were significantly lower than in the C group ($p < 0.05$), but no significant differences were present among the S, C, Se and vitamin E + Se groups. Levels of nitric oxide were significantly higher in the C group than in the other groups ($p < 0.01$).

CONCLUSION: Intraperitoneal administration of selenium or combined vitamin E and selenium appears to be effective in preventing intra-abdominal adhesion formation in rat models through the reduction of lipid peroxidation products.

KEYWORDS: Vitamin E; Selenium; Intra-abdominal adhesion; Histopathology; Rat.

Durmus AS, Yildiz H, Yaman I, Simsek H. Efficacy of vitamin E and selenium for the prevention of intra-abdominal adhesions in rats: uterine horn models. Clinics. 2011;66(7):1247-1251.

Received for publication on February 8, 2011; First review completed on February 25, 2011; Accepted for publication on March 25, 2011

E-mail: asdurmus@firat.edu.tr / alisaidurmus@gmail.com

Tel.: 90 424 237 00 00/3869

INTRODUCTION

The development of intraperitoneal adhesions is a serious postoperative complication of intra-abdominal surgery.¹ A wide variety of therapeutics have been used in attempts to decrease postoperative adhesion formation in animal models.¹⁻⁵

Vitamin E plays a crucial role in the protection of cellular membranes against lipid peroxidation. Vitamin E is a physiologic component of cellular membranes that reacts with peroxyl radicals more quickly than unsaturated fats, protecting membranes from damage caused by reactive oxygen species (ROS). Vitamin E has interesting biological properties and activities that suggest possible applications in preventing intraperitoneal adhesions. In vitro studies have shown that vitamin E has

antioxidant, anti-inflammatory, anticoagulant, and antifibrotic effects and decreases collagen production.^{6,7}

Selenium is an essential trace element that regulates a major component of the antioxidant defense mechanism in all living tissues; it is an essential constituent of glutathione peroxidase (GPx), an enzyme that destroys hydrogen peroxide and organic hydroperoxides using reducing equivalents from glutathione. Selenium is unique in that it acts both as a pro-oxidant and as an antioxidant.⁸ In response to reductions of the intracellular peroxide tone, it also induces anti-inflammatory intracellular metabolic processes.⁹

This study investigated the efficacies of vitamin E and selenium, both individually and in combination, for prevention of intra-abdominal adhesion formation in a rat model.

MATERIAL AND METHODS

Animals and protocol design

The guidelines followed for the care and use of the animals were approved by the local institution. The study

was approved by the committee on Animal Research at University of Firat, Elazig, Turkey. In total, 47 female, 4.5-month-old Sprague-Dawley rats weighing between 200 and 220 g were housed in a climate-controlled (relative humidity of 40-60% and temperature of 21 to 24°C) animal care facility with a 12-hour light/dark cycle. They had free access to water and standard rodent feed.

The rats were randomly divided into four groups, and each rat was anaesthetized with an intramuscular injection of 85 mg/kg ketamine hydrochloride (Parke-Davis, Ketalar, ketamine hydrochloride, 50 mg/ml) and 6 mg/kg xylazine hydrochloride (Bayer, Rompun, xylazine hydrochloride, 23.32 mg/ml). Their abdomens were shaved and prepared with 1% antiseptic povidone-iodine solution (Kim-Pa, Poviiodeks, 10% povidone-iodine), and a 3-cm midline laparotomy was made. The sham group (S, n = 7) underwent only a laparotomy and received 2 ml of 0.9% saline solution intraperitoneally. In the remaining 40 rats, the small bowel was retracted and the uterus exposed. In each of these rats, punctate serosal hemorrhages were generated by scraping with a No. 15 scalpel blade at the abdominal sidewall and the antimesenteric surface of the left uterine horn to create adhesions. A vitamin E solution, prepared by dissolving 2 ml of vitamin E (Evigen Ampul, Aksu Farma, Istanbul, Turkey, 300 mg/2 ml dl-alpha tocopherol acetate) in 58 ml of olive oil, was sterilized in an autoclave and cultured before use. The lesion areas created in the control (C, n = 10), vitamin E-treated (vitamin E group (VE), n = 10), selenium-treated (Se, n = 10) and vitamin E-and-selenium-treated (VE+Se, n = 10) groups were coated and instilled in the peritoneal cavity with either 2 ml of 0.9% saline solution, 10 mg of vitamin E in 2 ml solution, 0.2 mg/kg body weight selenium (sodium selenate, Aldrich, USA) dissolved in 2 ml of distilled water, or 10 mg of vitamin E with 0.2 mg/kg body weight selenium in a 2 ml solution, respectively.

The abdominal incision was then closed. The animals were allowed to resume their diets until 14 days post-operation.

Histopathological examinations

Fourteen days after creation of the lesions, all animals were anaesthetized as previously described, and their abdomens were exposed through U-shaped incisions, providing maximal exposure. All animals were then euthanized by puncture of the vena porta.

The left uterine horn and any adherent material were immediately collected after euthanization for histopathological examination. These tissue samples were fixed in 10% neutral buffered formalin, embedded in paraffin wax, cut into 5 µm sections and stained with hematoxylin and eosin. The severity of the histologic changes (presence of adhesions, edemas, cell infiltration and fibrosis) was evaluated at 5 different locations with a light microscope at 10X magnification. Histological changes were classified as mild (1+), moderate (2+) or severe (3+).

Biochemical examinations

Samples from each tissue were washed twice with cold saline solution, placed in glass bottles and stored at -30°C for a maximum of 10 hours until use. After weighing, the tissue (1 g) was placed on ice, cut into small pieces with scissors and homogenized for 2 minutes at 3000 x g in ice-cold Tris-HCl buffer (50 mM, pH 7.4, 1 : 5, w/v) using a glass-Teflon homogenizer (Caliskan Cam Teknik, Ankara, Turkey). All

procedures were performed at 4°C. Immediately after the addition of butylhydroxytoluol (4 µl per ml), the tissue homogenate levels for nitric oxide (NO), malondialdehyde (MDA), GPx, catalase (CAT) and reduced glutathione (GSH) were assayed.

Lipid peroxidation intensities in the tissue homogenates were measured with a thiobarbituric acid reaction using the method of Yildiz et al.¹⁰ The GSH content of the tissue homogenate was measured at 412 nm using the method of Sedlak and Lindsay.¹¹ The tissue GSH-Px activities were spectrophotometrically measured at 37°C and 412 nm, as described by Lawrence and Burk.¹² The results are expressed as µmol/g of proteins. Tissue protein content was measured using the method of Lowry et al.¹³ with bovine serum albumin as a standard. CAT activity was assayed in the tissue homogenate with the Aebi method,¹⁴ and the results are expressed as katal/g of tissue. NO content was measured using the method of Cortas and Wakid,¹⁵ and the results are expressed as µmol/g of tissue.

Statistical analysis

Adhesion score, fibrosis, edema and mononuclear cell infiltration data were analyzed using the Kruskal-Wallis test, and biochemical data were analyzed using one-way analysis of variance (ANOVA). The Duncan test was performed for multiple comparisons using SPSS 11.0 for Windows. Data are expressed here as mean ± standard error (SEM). The results were considered statistically significant at $p < 0.05$.

RESULTS

The average adhesion scores were 2.90 ± 0.10 , 2.60 ± 0.15 , 2.30 ± 0.16 , and 2.20 ± 0.15 in the C, VE, Se, and VE+Se groups, respectively. The adhesion scores for the Se and VE+Se groups were significantly lower than those of the C group ($p < 0.05$); scores in the VE group were also decreased (Table 1).

No pathological symptoms were observed in microscopic examinations of the uteri of the S group. In the C group, adhesions between uteri and neighboring tissues were visible. Edema, thickness, and capillary vascular proliferations were noted in adhesion regions. Focal microabscesses, fibrosis, and intensive mononuclear cell infiltrations in the muscular layer of the uterus were also observed (Figure 1A). Adhesions, edema, thickness, capillary vascular proliferation, and mononuclear cell infiltrations in the uterine serosa were less severe in the VE group than in the C group (Figure 1B). Similar lesions were found in the Se and VE+Se groups but were less severe than in the other groups (Figure 1C, Figure 1D). The distribution of pathological lesions among the groups is shown in Table 1.

Tissue CAT, GPx, GSH, MDA, and NO levels were measured in all groups; these data are shown in Table 1. CAT and GPx activities did not differ significantly among the groups. However, CAT and GPx activities and GSH levels were slightly increased in the VE, Se, and VE+Se groups. GSH levels were significantly lower in the S group than in the VE, Se, and VE+Se groups ($p < 0.01$). In the VE group, MDA concentrations were significantly lower than in the C group ($p < 0.05$), but those of the S, C, Se, and VE+Se groups did not differ significantly. Levels of NO were significantly higher in the C group than in the other groups ($p < 0.01$).

Table 1 - Incidence of histopathological lesions in uterus sections and mean tissue levels of CAT, GPx, GSH, MDA and NO (values shown as mean \pm SE).

Parameters	Group S (n = 7)	Group C (n = 10)	Group VE (n = 10)	Group Se (n = 10)	Group VE+Se (n = 10)
Histopathology					
Adhesion	Absent	2.90 \pm 0.10*	2.60 \pm 0.15	2.30 \pm 0.16	2.20 \pm 0.15
Edema	Absent	2.70 \pm 0.15	2.20 \pm 0.16	1.10 \pm 0.18 ^a	1.30 \pm 0.15 ^a
Mononuclear cell infiltration	Absent	2.80 \pm 0.20	2.50 \pm 0.16	0.70 \pm 0.15 ^b	1.50 \pm 0.16 ^a
Fibrosis	Absent	2.10 \pm 0.15 ^c	1.60 \pm 0.19 ^d	0.60 \pm 0.16 ^e	1.10 \pm 0.10 ^f
Biochemistry					
CAT (k/gr tissue)	18.15 \pm 1.71	20.40 \pm 1.93	25.47 \pm 4.20	27.18 \pm 5.45	23.06 \pm 2.33
GPx (μ mol/gr protein)	100.07 \pm 3.62	113.15 \pm 10.52	127.58 \pm 23.16	134.91 \pm 26.36	135.80 \pm 21.53
GSH (μ mol/gr protein)	4.59 \pm 0.33 ^g	5.31 \pm 0.41	7.08 \pm 1.34	7.85 \pm 1.49	6.18 \pm 0.22
MDA (μ mol/gr protein)	2.25 \pm 0.10	2.57 \pm 0.25	1.98 \pm 0.12 ⁱ	2.15 \pm 0.22	2.17 \pm 0.38
NO (μ mol/gr tissue)	33.96 \pm 1.25	34.97 \pm 0.08 ^h	33.82 \pm 0.15	33.27 \pm 0.05	33.43 \pm 0.09

(*) Significantly differs from groups Se and VE+Se ($p < 0.05$).

(^a) Significantly differs from groups C and VE ($p < 0.01$).

(^b) Significantly differs from groups C, VE and VE+Se ($p < 0.01$).

(^c) Significantly differs from groups Se and VE+Se ($p < 0.01$).

(^d) Significantly differs from group Se ($p < 0.01$).

(^e) Significantly differs from group VE+Se ($p < 0.01$).

(^f) Significantly differs from group VE ($p < 0.01$).

(^g) Significantly differs from groups VE, Se and VE+Se ($p < 0.01$).

(^h) Significantly differs from the other groups ($p < 0.01$).

(ⁱ) Significantly differs from group C ($p < 0.05$).

DISCUSSION

The formation and reformation of postoperative intra-abdominal adhesions after surgery is a significant cause of morbidity and mortality, resulting in infertility and pain. Peritoneal adhesions develop in 90% of all laparotomies; intestinal obstruction related to peritoneal adhesion has been reported in 1% of all surgical interventions and in 3% of all laparotomies.^{1,2}

There are many experimental models for peritoneal adhesions: the damaged uterine horn model, the ileal transection model, the large bowel anastomosis model, the peritoneal damage model, the bacterial peritonitis model, and the scraping model.¹⁻⁵ The uterine horn model mimics abdominal surgery; thus, we chose this model, scraping and applying it until petechial spots appeared.

It has been postulated that ROS are involved in adhesion development following surgery. After surgery, an increase in free radical activity, such as increases in superoxide anions, xanthine oxidase, and MDA levels, has been detected.^{16,17} A local hypoxic environment occurs in the surgical area and leads to an ischemia/reperfusion process with a resultant decrease in the levels of free radical scavengers.^{7,18} Prevention of adhesion formation after the restoration of free radical scavengers, such as superoxide dismutase, CAT, dimethyl sulfoxide, and allopurinol, has been observed in animal studies. Rats pretreated with these antioxidants have shown significantly reduced severity of adhesions after complete regional intestinal ischemia.⁷

Vitamin E is a natural biological antioxidant that prevents peroxides from accumulating and protects cells from free radical damage. Vitamin E, like other antioxidants, may reduce the effects of oxidative stress in living cells, scavenging the free radicals created locally. Vitamin E provides a cellular defense mechanism that prevents peroxidative processes by sequestering free radicals, CAT, and GPx with its coordinating mineral, selenium, which detoxifies peroxides and protects cells from subsequent deleterious effects.⁷

Selenium is popularly believed to be an antioxidant. However, unlike most other antioxidants, it does not function directly as a free radical scavenger. Selenium is instead an integral part of the enzyme GPx. GPx, when complexed with selenium, catalyzes the oxidation of GSH to glutathione disulfide, which reduces hydrogen peroxides and various lipid hydroperoxides to nontoxic compounds.^{19,20}

Several investigators^{6,7,21} have reported that intraperitoneal administration of vitamin E immediately prior to laparotomy closure has proved to be a safe and efficient means of preventing intraperitoneal adhesions. In the present study, post-surgical adhesion formation was significantly reduced in animals treated with vitamin E, selenium or a combination of the two. The results of this study are in agreement with previous studies.^{6,20} The present study also measured adhesion scores and the levels of tissue CAT, GPx, GSH, MDA, and NO.

As shown in Table 1, the mean adhesion scores were markedly diminished in the Se and VE+Se groups when compared with the C group ($p < 0.05$); no significant difference was present between the VE, Se, and VE+Se groups. In microscopic examinations of the uteri of the Se and VE+Se groups, rates of edema, mononuclear cell infiltration, and fibrosis were significantly lower than in the C group ($p < 0.01$). In this experimental model, intraperitoneal administration of selenium decreased the incidence and extent of intra-abdominal adhesion. Selenium interference with free radical generation may be related to this decline in adhesion formation.

Increases in tissue CAT, GPx, and GSH values following vitamin E, selenium or combined treatments have been attributed to the inhibition of free radicals and lipid peroxidation.^{8,9,22,23} Intraperitoneal administration of vitamin E in rats exhibiting diabetic²³ and nephrotoxic²² effects caused decreases in liver and kidney lipid peroxidation levels, although SOD, CAT, and GPx activities increased. It has been reported that administration of CAT significantly reduces intestinal injury and consequently, the incidence

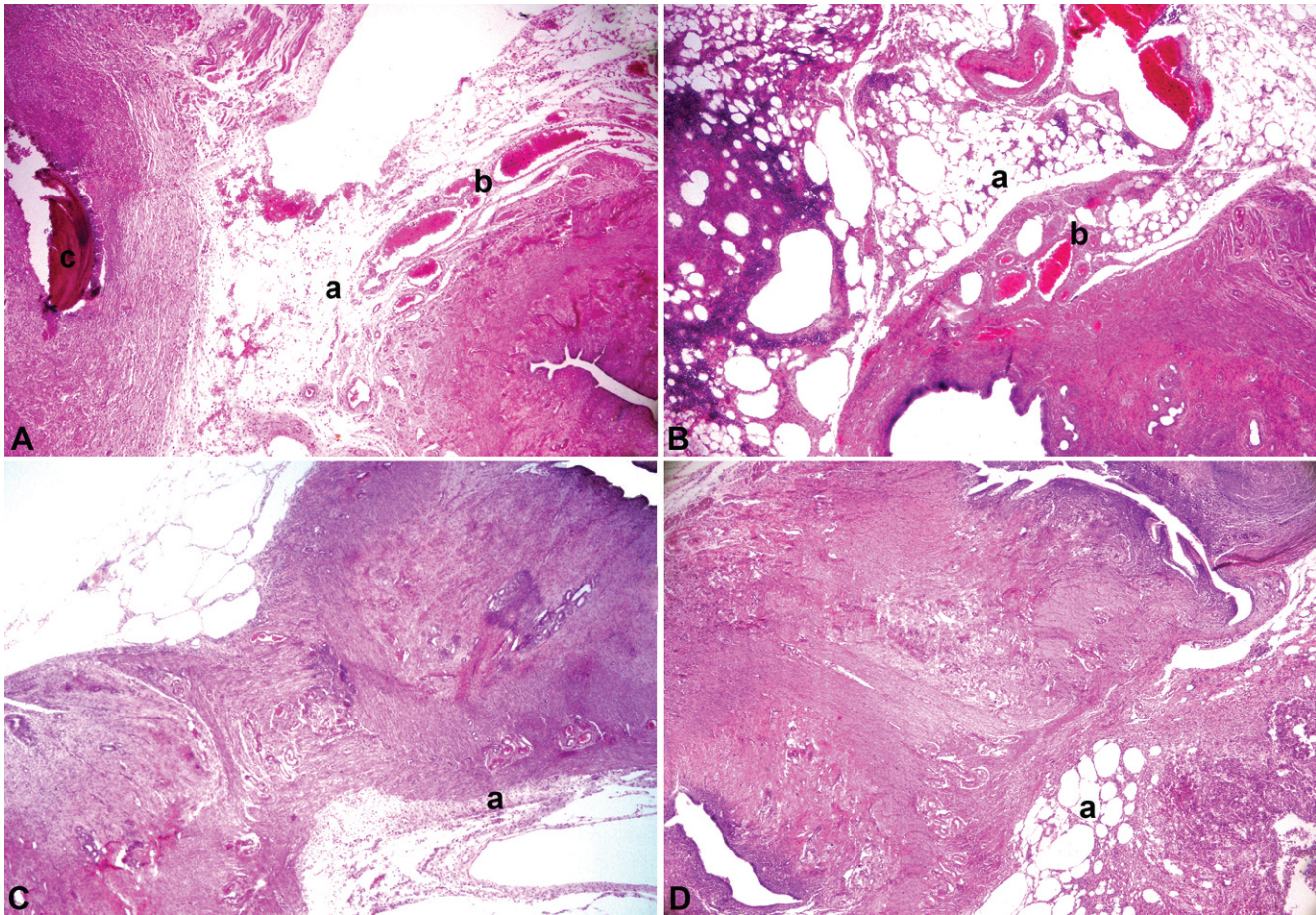


Figure 1 - (A) Histopathological view of uterus section in the control group. a) Edema and thickness in serosa, b) capillary vascular proliferation, c) microabscess (H&E, 100 x). **(B)** Histopathological view of uterus section in the vitamin E-treated group. a) Edema and thickness on serosa, b) capillary vascular proliferation (H&E, 100 x). **(C)** Histopathological view of a uterus section in the selenium-treated group. a) Edema on serosa (H&E, 100 x). **(D)** Histopathological view of uterus section in the animals treated with both vitamin E and selenium. a) Edema and thickness on serosa (H&E, 100 x).

and severity of peritoneal adhesion formation.²⁴ In the current literature, there are no studies reporting the effects of vitamin E and selenium treatments on the prevention of adhesion formation in rats or on the tissue MDA or GSH levels or GPx activities. In the VE, Se and VE+Se groups, tissue GSH content and CAT and GPx activities were elevated. These increases may be due to their depletion or inhibition as a result of the increased production of free radicals. The results of this study are consistent with previous studies²⁴ using CAT to prevent intraperitoneal adhesion formation. These data suggest that ROS may play a role in intra-abdominal adhesion formation.

MDA, a product of lipid peroxidation, is generated as a result of the toxic effects of active oxygen radicals that destroy unsaturated fatty acids in membranes.^{23,25} Locally generated free radicals, such as superoxides, peroxides and hydroxyl radicals, are potential oxidizers of polyunsaturated fatty acids and are therefore postulated to induce peritoneal adhesions through damage to cellular membranes.⁷ In this study, levels of MDA in the vitamin E group were significantly lower than in the control group. It has been demonstrated that tissue MDA levels are decreased by vitamin E. This may be related to the antioxidative and free radical-scavenging effects of vitamin E.

This study showed that selenium is a potent inhibitor of adhesion formation and suggests that its action is due to its anti-inflammatory and antioxidant effects, as shown by the lower observed tissue concentration of MDA, higher activities of CAT and GPx and high tissue GSH content in the VE, Se and VE+Se groups. These data indicate that the administration of vitamin E and selenium can prevent adhesion formation in rat uteri by modifying tissue antioxidant enzyme activities.

NO is a free radical gas molecule that is produced from L-arginine by the enzyme nitric oxide synthase (NOS). Depending on its redox state and cellular source, NO may be toxic or protective.²⁶ Increased NO, especially associated with oxidative stress, is harmful to tissue.¹⁶ Gurel et al.²⁷ reported that acute administration of vitamin E decreased NO concentrations in both ipsilateral and contralateral renal tissues compared to an ischemia-reperfusion group. Gorgun et al.²⁸ showed that vitamin E was effective in reducing NOS activity in streptozotocin-induced diabetic rats, suggesting that α -tocopherol acts as a beneficial antioxidant. Vitamin E may also increase NO efficiency by scavenging oxygen radicals in diabetic animals. Vitamin E supplementation is beneficial in reducing nitric oxidation mechanisms. Studies on the role of NO in adhesion formation are limited.

Intraperitoneal administration of melatonin,²⁹ aminoguanidine,³⁰ and resveratrol³¹ has been reported to decrease the incidence and extent of peritoneal adhesions and cause a decrease in NO levels. In this study, levels of NO were significantly higher in the C group than in other groups ($p < 0.01$). Tissue NO levels were decreased by vitamin E and selenium. These results show that NO may play an important role in adhesion formation, and the decrease in adhesion formation from vitamin E and selenium treatment may be related to their antioxidant and free radical scavenging effects. The observed lower levels of tissue NO in the VE, Se, and VE+Se groups may be evidence of these antioxidative effects.

Selenium was shown to be effective in reducing intra-abdominal adhesion formation. However, the efficacy of vitamin E used together with selenium was not superior to that of selenium alone.

CONCLUSION

The results of this study suggest that postoperative intra-abdominal adhesion formation in female rats resulted in increased oxidative stress, but that vitamin E and selenium supplementation may reduce the imbalance between uncontrolled free radical generation and scavenging enzyme activity. Intraperitoneal administration of vitamin E, selenium, and a combination of the two may be effective in preventing intra-abdominal adhesion formation in rat models. The antioxidative effects of selenium may have helped to prevent intraperitoneal adhesions between serosal surfaces.

REFERENCES

- Durmus AS, Han MC. Comparison of the effects of different concentrations of sodium carboxymethylcellulose on prevention of intraabdominal adhesions in rats. *Rev Med Vet Toulouse*. 2006;157:535-8.
- Durmus AS, Han MC. Effect of bovine amniotic fluid on intraabdominal adhesions. *Indian Vet J*. 2006;83:621-3.
- Emre A, Akin M, Isikgonul I, Yuksel O, Anadol AZ, Cifter C. Comparison of intraperitoneal honey and sodium hyaluronate - carboxymethylcellulose (SerafilmTM) for the prevention of postoperative intra-abdominal adhesions. *Clinics*. 2009;64:363-8, doi: 10.1590/S1807-59322009000400016.
- Irkorucu O, Ferahköşe Z, Memiş L, Ekinçi Ö, Akin M. Reduction of postsurgical adhesions in a rat model: a comparative study. *Clinics*. 2009;64:143-8.
- Aksakal O, Yilmaz B, Gungor T, Sirvan L, Sut N, Inan I, et al. A randomised controlled trial on melatonin and rosiglitazone for prevention of adhesion formation in a rat uterine horn model. *Arch Gynecol Obstet*. 2010;282:55-61, doi: 10.1007/s00404-009-1240-8.
- De La Portilla F, Ynfante I, Bejarano D, Conde J, Fernandez A, Ortega JM, et al. Prevention of peritoneal adhesions by intraperitoneal administration of vitamin E: an experimental study. *Dis Colon Rectum*. 2005;47:2157-61, doi: 10.1007/s10350-004-0741-6.
- Yildiz H, Durmus AS, Simsek H. Surgery-induced changes in red blood cell and plasma lipid peroxidation, enzymatic and non-enzymatic antioxidants, and blood hematology of female rats: protective role of methylene blue and vitamin E. *Eur J Obstet Gynecol Reprod Biol*. 2011;155:89-93, doi: 10.1016/j.ejogrb.2010.11.003.
- Forceville X. Seleno-enzymes and seleno-compounds: the two faces of selenium. *Crit Care*. 2006;10:180, doi: 10.1186/cc5109.
- Forceville X. Effects of high doses of selenium, as sodium selenite, in septic shock patients: a placebo-controlled, randomized, double-blind, multi-center phase II study: Selenium and sepsis. *J Trace Elem Med Bio*. 2007;21:62-5, doi: 10.1016/j.jtemb.2007.09.021.
- Yildiz H, Durmus AS, Simsek H, Yaman M. Protective effect of sildenafil citrate on contralateral testis injury after unilateral testicular torsion/detorsion. *Clinics*, 2011;66:137-42.
- Sedlak J, Lindsay RHC. Estimation of total, protein bound and non-protein sulfhydryl groups in tissue with Ellmann's reagent. *Anal Biochem*. 1968;25:192-205, doi: 10.1016/0003-2697(68)90092-4.
- Lawrence RA, Burk RF. Glutathione peroxidase activity in selenium-deficient rat liver. *Biochem Biophys Res Co*. 1976;71:952-8, doi: 10.1016/0006-291X(76)90747-6.
- Lowry OH, Rosebrough NJ, Farr AL, Randall RJ. Protein measurement with the Folin-Phenol reagent. *J Biol Chem*. 1951;193:265-75.
- Aebi H. Catalase in vitro. *Method Enzymol*. 1984;105:121-6, doi: 10.1016/S0076-6879(84)05016-3.
- Cortas NK, Wakid NM. Determination of inorganic nitrate in serum and urine by a kinetic cadmium-reduction method. *Clin Chem*. 1990;36:1440-3.
- Alpay Z, Saed GM, Diamond MP. Female infertility and free radicals: Potential role in adhesions and endometriosis. *J Soc Gynecol Investig*. 2006;13:390-8, doi: 10.1016/j.jsg.2006.05.002.
- Bentes De Souza AM, Rogers MS, Wang CC, Yuen PM, Pui SN. Comparison of peritoneal oxidative stress during laparoscopy and laparotomy. *J Am Assoc Gynecol Laparosc*. 2003;10:65-74, doi: 10.1016/S1074-3804(05)60237-X.
- Andraus W, Souza GFP, Oliveira MG, Haddad LBP, Coelho AMM, Galvão FH, et al. S-Nitroso-n-acetylcysteine ameliorates ischemia-reperfusion injury in the steatotic liver. *Clinics*. 2010;65:715-21, doi: 10.1590/S1807-59322010000700011.
- Bright MWR, Beate T, Peter ET, Martin AV, David HS. Effect of pancreatic enzyme preparations on erythrocyte glutathione peroxidase activities and plasma selenium concentrations in cystic fibrosis. *Free Radical Bio Med*. 1998;25:242-9, doi: 10.1016/S0891-5849(98)00061-6.
- Sarada SKS, Sairam M, Dipti P, Anju B, Pauline T, Kain AK, et al. Role of selenium in reducing hypoxia-induced oxidative stress: an in vivo study. *Biomed Pharmacother*. 2002;56:173-8, doi: 10.1016/S0753-3322(02)00173-7.
- Corrales F, Corrales M, Schirmer CC. Preventing intraperitoneal adhesions with vitamin E and sodium hyaluronate/carboxymethylcellulose. A comparative study in rats. *Acta Cir Bras*. 2008;23:36-41.
- Armagan A, Kutluhan S, Yilmaz M, Yilmaz N, Bulbul M, Vural H, et al. Topiramate and vitamin E modulate antioxidant enzyme activities, nitric oxide and lipid peroxidation levels in pentylentetrazol-induced nephrotoxicity in rats. *Basic Clin Pharmacol Toxicol*. 2008;103:166-70, doi: 10.1111/j.1742-7843.2008.00271.x.
- Kinalski M, Śledziewski A, Telejko B, Zarzycki W, Kinalska I. Lipid peroxidation and scavenging enzyme activity in streptozotocin-induced diabeto. *Acta Diabetol*. 2000;37:179-83, doi: 10.1007/s005920070002.
- Yuzbasioglu MF, Ezberci F, Imrek E, Bulbuloglu E. The effect of intraperitoneal catalase on prevention of peritoneal adhesion formation in rats. *J Invest Surg*. 2008;21:65-9, doi: 10.1080/08941930701883616.
- Budin SB, Othman F, Louis SR, Bakar MA, Das S, Mohamed J. The effects of palm oil tocotrienol-rich fraction supplementation on biochemical parameters, oxidative stress and the vascular wall of streptozotocin-induced diabetic rats. *Clinics*. 2009;64:235-44, doi: 10.1590/S1807-59322009000300015.
- Lipton SA, Choi YB, Pan ZH, Lei SZ, Chen HSV, Sucher NJ, et al. A redox-based mechanism for the neuroprotective and neurodestructive effects of nitric oxide and related nitroso-compounds. *Nature*. 1993;364:626-32, doi: 10.1038/364626a0.
- Gurel A, Armutcu F, Sahin S, Sogut S, Ozyurt H, Gulec M, et al. Protective role of alpha-tocopherol and caffeic acid phenethyl ester on ischemia-reperfusion injury via nitric oxide and myeloperoxidase in rat kidneys. *Clin Chim Acta*. 2004;339:33-41, doi: 10.1016/j.cccn.2003.09.013.
- Gorgun FM, Gumustas MK, Altug T, Kokoglu E. Vitamin E supplementation in streptozotocin-treated rats alters cerebellar and plasma nitric oxide metabolism. *J Toxicol Env Heal A*. 2002;65:631-7, doi: 10.1080/152873902317349772.
- Ara CT, Kirimlioglu H, Bay Karabulut A, Coban S, Hascalik S, Celik O, et al. Effect of melatonin against oxidative stress on adhesion formation in the rat rectum and uterine horn model. *Life Sci*. 2005;77:1341-50, doi: 10.1016/j.lfs.2005.01.024.
- Ara C, Bay Karabulut A, Kirimlioglu H, Yilmaz M, Kirimlioglu V, Yilmaz S. Protective effect of aminoguanidine against oxidative stress in an experimental peritoneal adhesion model in rats. *Cell Biochem Funct*. 2006;24:443-8, doi: 10.1002/cbf.1245.
- Gogutlu G, Bay Karabulut A, Ara C, Cinpolat O, Isik B, Piskin T, et al. The effect of resveratrol on surgery-induced peritoneal adhesions in an experimental model. *Cell Biochem Funct*. 2007;25:217-20, doi: 10.1002/cbf.1324.