

Submitted: 24/11/2014

Accepted: 15/03/2015

Published: 10/04/2015

## Clinical management of dietary induced urolithiasis associated with balanoposthitis in a Boer goat

Y. Abba<sup>1</sup>, F.F.J. Abdullah<sup>2,3</sup>, N.H. Bin Abu Daud<sup>4</sup>, R. Bin Shaari<sup>4\*</sup>, A. Tijjani<sup>1</sup>, M.A. Sadiq<sup>2</sup>, K. Mohammed<sup>2</sup>, L. Adamu<sup>2</sup> and A.M.L. Mohd<sup>1</sup>

<sup>1</sup>Department of Veterinary Pathology and Microbiology, Faculty of Veterinary Medicine, Universiti Putra Malaysia, 43400 UPM Serdang, Selangor, Malaysia

<sup>2</sup>Department of Veterinary Clinical Studies, Faculty of Veterinary Medicine, Universiti Putra Malaysia, 43400 UPM Serdang, Selangor, Malaysia

<sup>3</sup>Research Centre for Ruminant Disease, Faculty of Veterinary Medicine, Universiti Putra Malaysia, 43400 UPM Serdang, Selangor, Malaysia

<sup>4</sup>Faculty of Veterinary Medicine, Universiti Malaysia Kelantan, Locked Bag 36, Pengkalan Chepa, 16100 Kota Bharu, Kelantan, Malaysia

### Abstract

A Boer-Kajang cross male goat was presented to the Veterinary Hospital, University Malaysia Kelantan with a history of dysuria, hematuria and restlessness. The goat was intensively managed (confined to the pen) and fed with only palm kernel cake for the last three months. Physical examination revealed that the goat was dull, depressed, having an inflamed penis and prepuce with blood stained urine dripping from the penis. The differential diagnoses were obstructive urolithiasis, urinary tract infection and balanoposthitis. Based on the history, clinical signs, physical examination, urinalysis, ultrasonography and feed analysis, the goat was diagnosed with obstructive urolithiasis and balanoposthitis. Treatment was instituted by amputation of the urethral process and retrograde urohydropulsion to relieve the blockade. Sulfadiazine-trimethoprim (Norodine<sup>®</sup>24) 15mg/kg, I.M; flunixin meglumine 2.2mg/kg, I.M; vitamin B complex 1ml/10kg, I.M and ammonium chloride 300mg/kg orally were administered. The goat responded well to treatment and was recovering well during a follow up visit.

**Keywords:** Balanoposthitis, Boer goat, Obstructive urolithiasis, Palm kernel cake

### Introduction

Urolithiasis is a condition associated with the formation of urinary calculi in the urinary system. Thus, obstructive urolithiasis is usually associated with the obstruction of the urethra by one or more uroliths which results in blockage of urine outflow (Radostits *et al.*, 2007; Ewoldt *et al.*, 2008). Nutritional disease is considered the primary factor for ruminant urolithiasis, while sex and hormonal changes are also considered as predisposing factors (Kahn *et al.*, 2005). Animals affected with obstructive urolithiasis usually show signs of abdominal pain, restlessness, groaning and grunting while straining to urinate but passing only a few drops of blood stained urine. However, these conditions usually go unnoticed in many food animals. Balanoposthitis which is an inflammation of the penis and prepuce can be found in male animals with urethral obstruction (Radostits *et al.*, 2007). This can be due to self-inflicted trauma or caused by *Corynebacterium renale* which is capable of hydrolyzing urea. Animals affected will show signs of swelling around the prepuce (Kahn *et al.*, 2005). Balanoposthitis can be a secondary lesion due to obstructive urolithiasis.

Dietary imbalances resulting from disproportionate calcium-phosphorus ratios (Ca:P ratios) have been

incriminated in formation of uroliths and crystals in the urine (Makhdoomi and Ghazi, 2013). Palm kernel cake (PKC) is an important oil palm by-product used as animal feed (Kum and Zahari, 2011). However, PKC contains an imbalance of calcium-phosphorus ratio and excess quantities in the feed may lead to the formation of uroliths (Wan Zahari and Alimon, 2012). The optimum level of PKC to be fed to goats is 30% (MPOB, 2002). This clinical case reports the management of dietary induced obstructive urolithiasis associated with balanoposthitis in a Boer goat.

### Case History

A 2 year-old Kajang cross male goat weighing about 30kg with a body condition score of 3/5 was presented to the Veterinary Hospital, University Malaysia Kelantan with a history of dysuria, hematuria and restlessness lasting for five days. Vaccination and deworming statuses were not up to date. The goat was intensively managed and fed with a commercially bought palm kernel cake for the past three months.

### Clinical examination

On clinical evaluation, the goat was found to be dull, depressed and recumbent. There was pyrexia and

\*Corresponding author: Rumaizi Bin Shaari. Faculty of Veterinary Medicine, Universiti Malaysia Kelantan, Locked Bag 36, PengkalanChepa, 16100 Kota Bharu, Kelantan, Malaysia. E-mail: [rumaizi@umk.edu.my](mailto:rumaizi@umk.edu.my)

tachypnoea. The mucous membrane was pale pink with capillary refill time and skin recoil of 3 seconds. The prepuce and penis were inflamed, hemorrhagic and necrotic (Fig. 1). Upon abdominal palpation, the urinary bladder was turgid and enlarged. Palpation of the inguinal region revealed pain at the point of sigmoid flexure.

#### **Diagnostic Work-up and results**

Urinalysis, radiography, ultrasonography and feed mineral analysis were done for the diagnostic work-ups. The urinalysis results showed the presence of leucocytes (+1), nitrite, proteins (+3), and red blood cells (+4). Urinary sediments were also observed under the microscope where calcium phosphate crystals (Fig. 2) and struvite crystals (Fig. 3) were seen.

Radiography of the right lateral view showed an absence of the urinary bladder line and a ground glass appearance of the abdomen, which was interpreted as ruminal distention. The glans penis and the prepuce were observed to be radiopaque (Fig. 4).

Ultrasonographic examination showed collection of hyperechoic sediments at the dorsal part of the enlarged

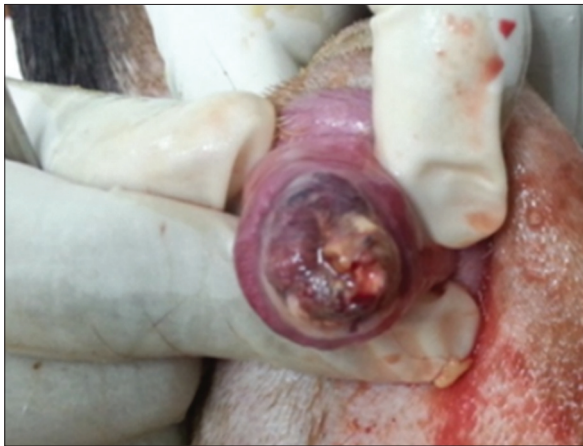and turgid bladder which measured approximately 10cm in diameter (Fig. 5).

Feed analysis of the palm kernel cake showed that calcium and phosphorus level in feed were 0.25% and 0.59%, respectively.

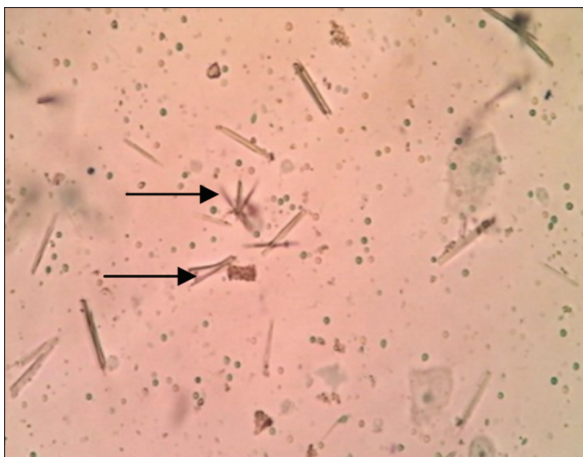Based on the history, clinical signs, physical examination and urinalysis, the definitive diagnosis for this case were obstructive urolithiasis associated with balanoposthitis.

#### **Management**

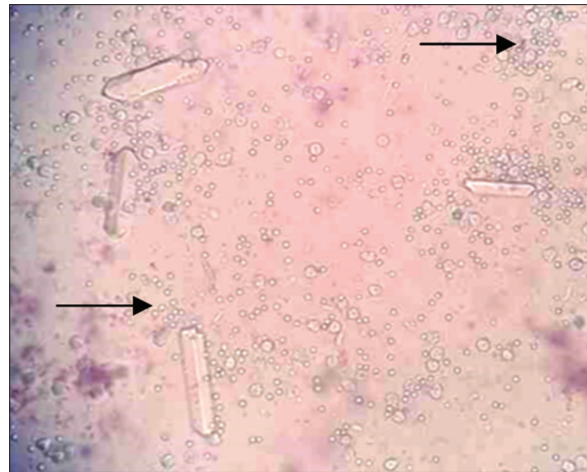
Management of obstructive urolithiasis generally involves establishing a patent urethra (Ewoldt *et al.*, 2008). Thus, urethral process amputation and retrograde urohydropulsion were indicated in this case. The penis was grossly inflamed with presence of multifocal necrotic patches on the preputial surface. The goat was placed in a squatting position and the hair around the prepuce area was shaved and disinfected



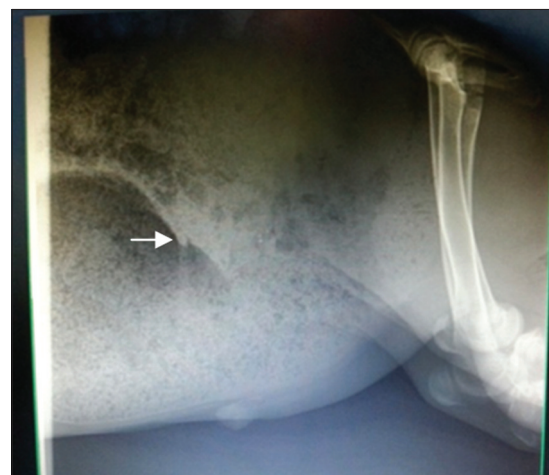**Fig. 1.** Inflamed and necrotic penis and prepuce.



**Fig. 2.** Calcium phosphate crystals from urine smear (arrows).



**Fig. 3.** Struvite crystals; colorless, 3-dimensional, prism-like crystals from urine smear (arrows).



**Fig. 4.** Radiograph showing right lateral view of the abdomen. Note opaque distended urethra due to obstruction (arrow).

using chlorhexidine, alcohol and povidone-iodine. The glans penis and urethral process were extruded out by pushing back the prepuce (Fig. 6). A 2 % lidocaine hydrochloride injection (3ml) was injected into the glands penis and the urethral process was transected with a scissors, while the surrounding necrotic penile tissue was debrided. The incised urethral process was examined for presence of uroliths and crystals. In order to initiate retrograde urohydropulsion, a urethral catheter was inserted into the urethra up to the level of the sigmoid flexure and the urinary bladder was manually expressed to evacuate the urine until the bladder was empty.

Sulfadiazine-trimethoprim (Norodine® 24) 15mg/kg, I.M, SID, for 10 days as broad spectrum antibiotic, Flunixin meglumine 2.2mg/kg, I.M, SID, for 10 days as analgesic and anti-inflammatory, ammonium

chloride 300mg/kg, P.O, SID, for 1 month as urine acidifier and Vitamin B complex 1ml/10 kg, SID, I.M for 3 days were administered.

### Discussion

The prevalence of urolithiasis is high in ruminants fed with high grain diet. These animals are at increased risk of developing struvite uroliths due to the high phosphorus level in the feed (Kahn *et al.*, 2005). The formation of calculi and the development of urolithiasis occurs in phases; from the formation of nidus, concentration of urine and lastly precipitation of various minerals such as phosphorus from which struvite crystals are formed (Makhdoomi and Ghazi, 2013). The distal aspect of sigmoid flexure and urethral process of sheep and goats are the most common sites for formation of uroliths due to the narrow lumen (Parrah *et al.*, 2010). The goat in this case was fed solely with PKC for a few months, which predisposed it to struvite uroliths formation resulting from the imbalance of calcium-phosphorus ratio in the feed. Another predisposition is the sex of the goat, thus making the uroliths to be easily lodged at the sigmoid flexure and the urethral process. On the other hand, the presence of inflammation around the penis and prepuce, which was presumed to be secondary to the urolith formation, might have contributed to obstruction of the urethral process. Complete obstruction around the urethral process will usually lead to perforation and inflammation around the prepuce and glans penis (Kahn *et al.*, 2005).

According to Kahn *et al.* (2005), the Ca: P ratio in the diet should be 2:1. Thus, any feeding program incorporating concentrate feeding must include appropriate calcium supplements in the diet. Ammonium chloride supplementation at 2.25% has been shown to maintain urinary pH of goats at 6.5 for up to 24 hrs (Mavangira *et al.*, 2010). Since maintenance of urinary pH at 5.5-6.5 is paramount in preventing the formation of uroliths, incorporation of ammonium chloride in goat feed is essential. A high P:Ca ratio has been shown to predispose to osteopenia and fibrous osteodystrophy in confined goats fed with high phosphate diet (Bandarra *et al.*, 2011). High dietary phosphate and magnesium has also been shown to increase urinary excretion of phosphate and predisposes to the formation of struvite crystals and phosphate calculi (Makhdoomi and Ghazi, 2013). In an experimental study using cotton seed feed and magnesium oxide for induction of urolithiasis in goats, Wang *et al.* (2008) and Sun *et al.* (2010) reported that the most important component for the formation of a urolith was magnesium, which contributed to the development of struvite calculi. The authors also observed that crystals formed were made up of magnesium ammonium phosphate (MAP) before stone formation and potassium magnesium phosphate (MKP) after stone formation. In Malaysia, most concentrates

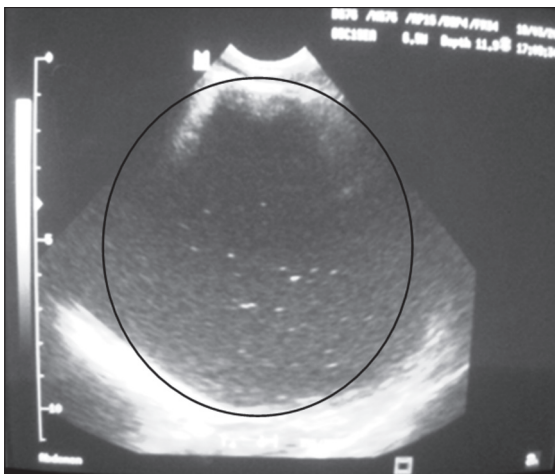


Fig. 5. Ultrasonograph of the distended bladder (10cm) showing opaque bodies. Note the uniformly distributed echoes resulting from cystitis. Transducer was placed on the ventral abdomen in the standing position.

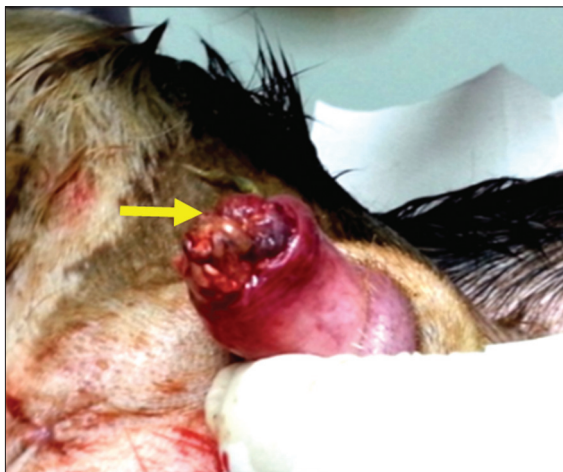

Fig. 6. Urethral process amputation (arrow).

are oil palm based, where PKC is used as animal feed. The Ca:P ratio in PKC is 1:2; hence the phosphorus level is two times higher than calcium level (MPOB, 2002). As a result, feeding high quantities of PKC predisposes the animals to uroliths and crystal formation in the urine just as we observed in this report.

Surgical intervention through tube cystotomy and chemical dissolution is the most widely practiced management procedure, especially when the stones are located proximal to the sigmoid flexure and urethral catheter insertion fails (Dubey *et al.*, 2006). In our case, insertion of a urethral catheter coupled with normograde retro-hydropulsion was able to restore urine flow to normal because the urolith was small and the obstruction was distal to the sigmoid flexure. On the other hand, large uroliths that are proximal and which are impossible to dislodge through this procedure will require a perineal urethrostomy and cystotomy as previously described by other researchers (Ewoldt *et al.*, 2008). Although currently the most effective approach is tube cystotomy, future approach is aimed at using laser lithotripsy to break down stones within the bladder. Since dietary cation differences have been identified as the most important factor in its development, preventive measures such as controlled salt level in diet, use of urine acidifiers and reduced concentrate coupled with increased roughage intake is recommended to reduce incidence of this condition in farmanimals (Jones *et al.*, 2009; Makhdoomi *et al.*, 2013).

#### Conclusion

It is important to limit feeding of concentrate to goats and other livestock due to imbalance in the Ca:P ratio. The best feeding regime is 70% roughage and 30% concentrate feed based on dry matter. It is also crucial to educate farmers on the clinical signs associated with obstructive urolithiasis in order to ensure institution of early treatment for better prognosis.

#### Acknowledgement

The authors wish to acknowledge the staff of Veterinary Hospital, Faculty of Veterinary Medicine, University Malaysia Kelantan for their technical help and support.

#### References

Bandarra, P.M., Pavarini, S.P., Santos, A.S., Antoniassi, N.A.B., Cruz, C.E. and Driemeier, D. 2011. Nutritional fibrous osteodystrophy in goats. *Pesquisa Vet. Brasil.* 31(10), 875-878.

- Dubey, A., Pratap, K., Amarpal, Aithal, H.P., Kinjavdekar, P., Singh, T.I. and Sharma, M.C. 2006. Tube cystotomy and chemical dissolution of urethral calculi in goats. *Indian J. Vet. Surg.* 27(2), 98-103.
- Ewoldt, J.M., Jones, M.L. and Miesner, M.D. 2008. Surgery of obstructive urolithiasis in ruminants. *Vet. Clin. North Am. Food Anim. Pract.* 24(3), 455-465.
- Jones, M.L., Streeter, R.N. and Goad, C.L. 2009. Use of dietary cation difference for control of urolithiasis risk factors in goats. *Am. J. Vet. Res.* 70, 147-155.
- Kahn, C.M. and Line, S. 2005. *The Merck Veterinary Manual* 9<sup>th</sup> Edition. USA: Merial.
- Kum, W.H. and Zahari, M.W. 2011. Utilisation of oil palm by-product as ruminant feed in Malaysia. *J. Oil Palm Res.* 23, 1029-1035.
- Makhdoomi, D.M. and Ghazi, M.A. 2013. Obstructive urolithiasis in ruminants- A review. *Vet. World* 6(4), 233-238.
- Malaysia Palm Oil Board, MPOB. 2002. Palm kernel cake as animal feed.
- Mavangira, V., Cornish, J.M. and Angelos, J.A. 2010. Effect of ammonium chloride supplementation on urine pH and urinary fractional excretion of electrolytes in goats. *J. Am. Vet. Med. Assoc.* 237(11), 1299-1304.
- Parrah, J.D., Hussain, S.S., Moulvi, B.A., Singh, M. and Athar, H. 2010. Bovine uroliths analysis: A review of 30 cases. *Isr. J. Vet. Med.* 65(3), 103-107.
- Radostits, O.M., Gay, C.C., Hinchcliff, K.W. and Constable, P.D. 2007. *A textbook of the diseases of cattle, horses, sheep, pigs and goats.* Veterinary Medicine, 10<sup>th</sup> ed. London: Saunders. pp:1548-1551.
- Sun, W.D., Wang, J.Y., Zhang, K.C. and Wang, X.L. 2010. Study on precipitation of struvite and struvite-K crystal in goats during onset of urolithiasis. *Res. Vet. Sci.* 88(3), 461-466.
- Wang, J.Y., Sun, W.D. and Wang, X.L. 2009. Comparison of effect of high intake of magnesium with high intake of phosphorus and potassium on urolithiasis in goats fed with cottonseed meal diet. *Res. Vet. Sci.* 87(1), 79-84.
- Wan Zahari, M. and Alimon, A.R. 2012. Recent advances in the utilization of oil palm by-products as animal feed. In: *International Conference on Livestock Production and Veterinary Technology (ICARD)*, Ciawi, Bogor, Indonesia.