

Research

Open Access

Three stage axillary lymphatic massage optimizes sentinel lymph node localisation using blue dye

Robert M Kirby, Abdul Basit*, Quang T Nguyen, Anthony Jaipersad and Rebecca Billingham

Address: Breast Unit, University Hospital of North Staffordshire, Keele University, Stoke-on-Trent, UK

Email: Robert M Kirby - robert.kirby@uhns.nhs.uk; Abdul Basit* - drabdulbasit@aol.com; Quang T Nguyen - quang.nguyen@uhns.nhs.uk; Anthony Jaipersad - anthony.jaipersad@uhns.nhs.uk; Rebecca Billingham - rebecca.billingham@uhns.nhs.uk

* Corresponding author

Published: 22 December 2007

Received: 20 November 2007

International Seminars in Surgical Oncology 2007, 4:30 doi:10.1186/1477-7800-4-30

Accepted: 22 December 2007

This article is available from: <http://www.issoonline.com/content/4/1/30>

© 2007 Kirby et al; licensee BioMed Central Ltd.

This is an Open Access article distributed under the terms of the Creative Commons Attribution License (<http://creativecommons.org/licenses/by/2.0>), which permits unrestricted use, distribution, and reproduction in any medium, provided the original work is properly cited.

Abstract

Aims: This paper describes a simple technique of axillary and breast massage which improves the successful identification of blue sentinel nodes using patent blue dye alone.

Methods: Patent blue dye was injected in the subdermal part of the retroareolar area in 167 patients having surgical treatment for invasive breast cancer. Three stage axillary lymphatic massage was performed prior to making the axillary incision for sentinel lymph node biopsy. All patients had completion axillary sampling or clearance.

Results: A blue lymphatic duct leading to lymph nodes of the first drainage was identified in 163 (97%) of the patients. Results are compared with 168 patients who had sentinel lymph node biopsy using blue dye without axillary massage. Allergic reactions were observed in four patients (1.2%).

Conclusion: Three stage axillary lymphatic massage improves the successful identification of a blue sentinel lymph node in breast cancer patients.

Introduction

Lymphatic mapping using blue dye, radiolabelled colloid or both to identify the sentinel lymph node in breast cancer surgery is becoming the standard of care. In the validation phase of the ALMANAC trial surgeons achieving a localization rate of = 90% using a combined technique of blue dye and radioisotope proceeded to the randomization phase in which the success rate for localization of the sentinel lymph node was 98% [1]. A number of studies (Table 1) have reported a localization rate in the range of 85–98% using the combined technique, [2-4] However Adwani and Giuliano have reported a 90–95% success rate of localization of the sentinel node using the blue dye alone without and with a breast massage respectively

[5,6]. Although both radiocolloid and blue dye are used together by most surgeons, and training should be in both techniques, some experienced surgeons use one or the other almost exclusively. [6,7]

We report a technique using a three stage axillary and breast massage after subcutaneous injection of 2 ml of patent blue dye alone. This massage technique applies the principle of manual lymphatic drainage and is based on the physiology of lymphatic flow described originally by Winiwarter (1892) and Vodder (1982). It improves the localisation of a blue lymphatic duct in the axilla and almost always leads to successful identification of the blue sentinel lymph node. [8]

Table 1:

Author	Number of Patients	Technique	Number of SLN*	SLN Identification rate (%)
Giuliano 1997	107	Blue Dye Only	1.8	93
Veronesi 2003	649	Radiocolloid only	2.7	98.7
Krag 1998	443	Radiocolloid only	2.5	93
ALMANAC Mansel 2006	1031	Combined Blue Dye and Radiocolloid	2.4	98
Hadjiminas 2005	234	Combined Blue Dye and Radiocolloid	1.38	94.5
Kuehn 2004	1124	Combined Blue Dye and Radiocolloid	2	85

* Average number

Methods

We injected 2 ml of 2.5 per cent undiluted patent blue V sodium dye subdermally in the retroareolar area at the upper outer quadrant of the breast. The lymphatic massage was performed in three stages. In the first stage the axilla was massaged to empty axillary lymph nodes (Fig. 1). The lymph node massage was performed with the tips of two or three fingers. These were placed over the nodes, and pressure was applied like a gentle "scoop" in the direction of further flow from them. The fingers did not move over the skin; rather, they applied pressure during the "scoop" and released it [8]. In the second stage a retrograde massage was undertaken from the axilla towards the injection site. This was performed using the palm of the hand and fingers using light stroking movements over the skin. The final step was to massage from the injected area towards the axilla (Antegrade massage) to drain the blue dye into lymphatics and axillary lymph nodes (Fig. 2). The three stage massage takes about one minute to complete. It uses light-pressured strokes in a specific direction to stimulate the lymph vessels just below the surface of the skin without increasing blood circulation or reaching the depth of muscle tissue. It was thought necessary to

allow about seven minutes before making the axillary incision to provide the blue dye enough time to reach the axillary glands. All patients had completion axillary sampling or clearance.

Results

In 167 patients with three stage axillary lymphatic massage a blue sentinel lymph node was identified in 163 patients thereby achieving a localisation rate of 97%. We compared the results with our previous technique of simple massage from the injection site towards the axilla (Antegrade massage). A blue sentinel lymph node had been identified in 144 of 168 patients with simple antegrade massage alone, a localisation rate of only 85%.

Four patients (1.2%) developed allergic reaction to patent blue dye which manifested in the form of blisters or wheal and blue hives with bluish discoloration of the skin. One of these patients became hypotensive. All reactions occurred within 45 minutes of the injection and were

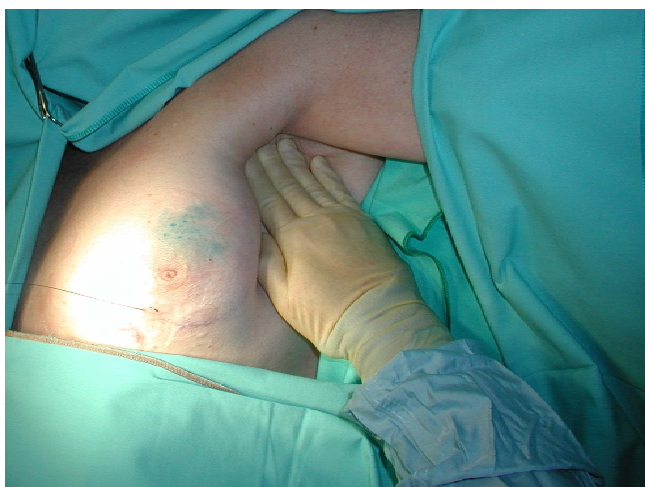

Figure 1
First stage of axillary lymphatic massage.

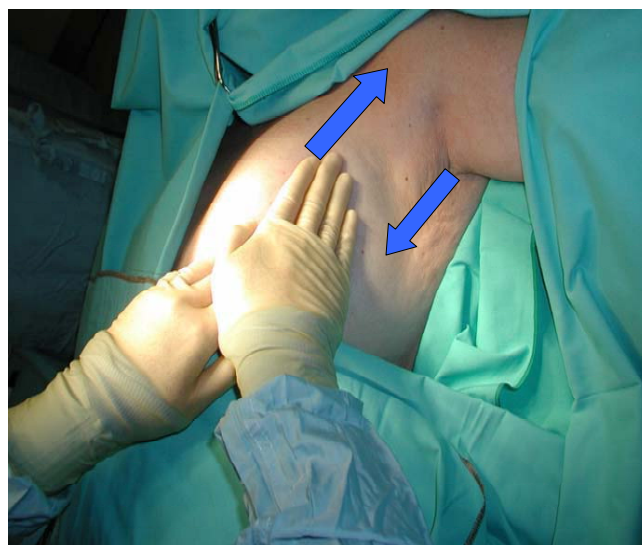


Figure 2
Stage 2 retrograde and stage 3 antegrade massage.

treated by a single intravenous injection of 200 mg of Prednisolone.

The false negative rate was 6% in the antegrade massage group and zero per cent in the three stage axillary lymphatic massage group. The new technique also improved the sensitivity and specificity from 70 and 88 per cent with simple antegrade massage to 84% and 100% with a three stage massage.

Discussion

Axillary sentinel lymph node biopsy allows a minimal invasion of the axillary area in order to obtain a limited number of axillary lymph nodes to identify patients who do not have nodal metastases. This avoids a more extensive axillary dissection with its associated complications. It is important that techniques used to localise the axillary sentinel lymph node in breast cancer are optimized to achieve a high identification rate. A combined technique using Tc-99 isotope and patent blue dye has been shown to achieve a localisation rate of up to 98% [1,9,10].

Of the various dyes used for sentinel node localization patent blue dye is currently recommended for sentinel node biopsy in breast cancer patients in the United Kingdom. When injected subdermally in any area of the breast it binds to proteins and is absorbed by the lymphatics and highlights the lymphatic drainage and the sentinel lymph node in the axilla [11]. Three stage lymphatic massage works by first emptying the "reservoir" in the lymph nodes creating an empty space into which lymphatics containing the blue dye can be emptied easily [8].

A localisation rate of over 90% is currently recommended to assure quality in breast cancer surgery [7,12,13]. We report in this study that a localisation rate of 97% is achievable by using blue dye alone with axillary lymphatic massage in three stages. This technique can be useful for breast surgeons working in breast units where facilities for nuclear medicine are not readily available [14]. A blue dye assisted four node sampling can be performed making it a targeted axillary sampling [15]. A comparison of Methylene blue dye and combined dye and radioactive technique has shown that the blue dye technique with breast massage can be as accurate as the combined isotope dye technique [16].

Acknowledgements

We thank all patients who have taken part in this study. Written informed consent was obtained from the patient for publication of images in this paper. A copy of the written consent is available for review by the Editor-in-Chief of this journal.

References

1. Mansel RE, Fallowfield L, Kissin M, Goyal A, Newcombe RG, Dixon JM, Yiangou C, Horgan K, Bundred N, Monypenny I, England D, Siburbering M, Abdulla TI, Barr L, Chetty U, Sinnett DH, Fleissig A, Clarke

2. D, Ell PJ: **Randomized multicenter trial of Sentinel node biopsy versus standard axillary treatment in operable breast cancer: The ALMANAC trial.** *J Natl Cancer Inst* 2006, **98(9)**:599-609.
2. Agarwal T, Kakkos SK, Cunningham DA, Darzi A, Lee D, Rajen P, Hadjiminias DJ: **Sentinel node biopsy can replace four-node-sampling in staging early breast cancer.** *Eur J Surg Oncol* 2005, **31(2)**:122-7.
3. Kuehn T, Vogl FD, Helms G, Pueckler SV, Schirrmmeister H, Strueber R, Koretz K, Kreienberg R: **Sentinel-node biopsy for axillary staging in breast cancer: results from a large prospective German multi-institutional trial.** *Eur J Surg Oncol* 2004, **30(3)**:252-9.
4. Veronesi U, Paganelli G, Viale G, Luini A, Zurrada S, Galimberti V, Intra M, Veronesi P, Robertson C, Maisonneuve P, Renne G, De Cicco C, De Lucia F, Gennari R: **A randomized comparison of sentinel-node biopsy with routine axillary dissection in breast cancer.** *N Engl J Med* 2003, **349(6)**:546-53.
5. Adwani A, Ebbs S, Burton S, Lowe S: **Sentinel lymph node biopsy should be supplemented by axillary sampling in patients with small breast cancers.** *Int Semin Surg Oncol* 2005, **2(1)**:27.
6. Giuliano AE, Jones RC, Brennan M, Statman R: **Sentinel lymphadenectomy in breast cancer.** *J Clin Oncol* 1997, **15(6)**:2345-50.
7. Schwartz GF: **Clinical practice guidelines for the use of axillary sentinel lymph node biopsy in carcinoma of the breast: current update.** *Breast J* 2004, **10(2)**:85-8.
8. Casley-Smith JR, Boris M, Weindorf S, Lasinski B: **Treatment of lymphedema of the arm-The Casley-Smith method.** *Cancer* 1998, **83**:2843-60.
9. Albertini JJ, Lyman GH, Cox C, Yeatman T, Balducci L, Ku N, Shivers S, Berman C, Wells K, Rapaport D, Shons A, Horton J, Greenberg H, Nicosia S, Clark R, Cantor A, Reintgen DS: **Lymphatic mapping and sentinel node biopsy in the patient with breast cancer.** *JAMA* 1996, **276(22)**:1818-22.
10. Derossis AM, Fey J, Yeung H, Yeh SD, Heerd AS, Petrek J, VanZee KJ, Montgomery LL, Borgen PL, Cody HS 3rd: **A trend analysis of the relative value of blue dye and isotope localization in 2,000 consecutive cases of sentinel node biopsy for breast cancer.** *J Am Col Surg* 2001, **193(5)**:473-78.
11. Masannat Y, Shenoy H, Speirs V, Hanby A, Horgan K: **Properties and characteristics of the dyes injected to assist axillary sentinel node localization in breast surgery.** *Eur J Surg Oncol* 2006, **32(4)**:381-4.
12. Rutgers EJTh: **Guidelines to assure quality in breast cancer surgery.** *Eur J Surg Oncol* 2005, **31(6)**:568-76.
13. Schwartz GF, Giuliano AE, Veronesi U: **Consensus Conference Committee. Proceedings of the consensus conference on the role of sentinel lymph node biopsy in carcinoma of the breast, April 19 - 22, Philadelphia, Pennsylvania.** *Cancer* 2001, **94(10)**:2542-51.
14. Purushotham AD, Macmillan RD, Wishart GC: **Advances in axillary surgery for breast cancer - time for a tailored approach.** *Eur J Surg Oncol* 2005, **31(9)**:929-931.
15. Macmillan RD, Barbera D, Hadjiminias DJ, Rampaul RS, Lee AH, Pinder SE, Ellis IO, Blamey RW, Geraghty JG: **Sentinel node biopsy for breast cancer may have little to offer four-node-samplers. results of a prospective comparison study.** *Eur J Cancer* 2001, **37(9)**:1076-80.
16. Varghese P, Mostafa A, Abdel-Rahman A, Akberali S, Gattuso J, Canzales A, Wells C, Carpenter R: **Methylene blue dye versus combined dye-radioactive tracer technique for sentinel lymph node localisation in early breast cancer.** *Eur J Surg Oncol* 2001, **33(2)**:147-152.