



Case report- acute pre-operative gall bladder perforation (Type-1) with generalized biliary peritonitis in younger age group without any comorbid illness

Anil Khetarpal^{*}, Ayush Khetarpal

Department- General Surgery, Institution – Khetarpal Hospital, India

ARTICLE INFO

Keywords:

Common bile duct
Gall bladder perforation (GBP)
Laparoscopic cholecystectomy
Cholecystitis

ABSTRACT

Gall bladder related disease is now one of the commonest indications for elective and emergency surgery and laparoscopic cholecystectomy is the mainstay treatment in patients with gall bladder stones, however some patient delay their surgical intervention for some period of time which might lead to life threatening complications in later stages such as GBP which is rare but when it occurs along with other predisposing risk factors (hypoalbuminemia and SIRS) might increase the morbidity and mortality rate. Here we report a case of pre-operative Type-I GBP with generalized biliary peritonitis with sepsis with hypoalbuminemia in younger age group. Acute cholecystitis patient of younger age group without any comorbid illness, needs prompt surgical intervention (cholecystectomy).

1. Introduction

Gall bladder perforation (GBP) is a rare but life threatening event of severe acute cholecystitis with mortality rate of 12–16% in recent publications [1]. In acute cholecystitis, progressive gall bladder distension and inflammation is followed by vascular compromise, gangrene, necrosis and ultimately perforation [2] however fundus is the most frequent site of perforation due to relatively poor blood supply in area and if the perforation site is at fundus, it is more likely to end up with a Type-I perforation. The incidence of GBP in acute cholecystitis is 10% [3]. We routinely practice laparoscopic cholecystectomy in patients with gall bladder stones, however some patient delay their surgical intervention for some period of time which might lead to life threatening complications in later stages such as GBP which is rare but when it occurs along with other predisposing risk factors (hypoalbuminemia and SIRS) might increase the morbidity and mortality rate. Here, we report a case of a Type-I GBP with generalized biliary peritonitis with sepsis with hypoalbuminemia.

2. Case report

A 22-years-old Indian male was apparently normal, one and half month ago when he developed abdominal pain more at right upper

quadrant for which he visited nearest healthcare centre, where sonography whole abdomen was done, found to have echogenic calculus of 16mm in GB neck region and dilated CBD (16mm) with multiple echogenic calculi (4.5mm–8.9mm). Following it, patient underwent ERCP with biliary stenting in another health care centre and get discharged in stable condition with supportive medications as oral antibiotics, PPI's and analgesics.

Few days later, his complaints became intensified and was walked in emergency department of private practice setting with sharp shooting right upper quadrant pain which was radiating towards back. He also had recurrent episodes of non-projectile and non-bilious vomiting. He could not even tolerate any fluids, or solid food and began to vomit, with no associated fever. Also, there was no history of any medical illness or previous abdominal surgery except ERCP + Biliary stenting, 13 days back.

On physical examination, he was alert, afebrile and hemodynamically stable, with no signs of dehydration. On per-abdominal examination, found to have distended abdomen with tenderness over right upper quadrant along with rigidity and guarding with positive murphy's sign. Bowel sounds were found to be sluggish.

Routine blood investigations were carried out which revealed leucocytosis (16.50thou/ul) with neutrophilia and hepatic dysfunction. Contrast enhanced CT abdomen showed features of acute cholecystitis

^{*} Corresponding author. F-95, Bali Nagar, New Delhi, 110015, India.

E-mail address: khetarpalhospital@gmail.com (A. Khetarpal).

<https://doi.org/10.1016/j.amsu.2021.102253>

Received 26 February 2021; Received in revised form 19 March 2021; Accepted 22 March 2021

Available online 27 March 2021

2049-0801/© 2021 The Authors. Published by Elsevier Ltd on behalf of IJS Publishing Group Ltd. This is an open access article under the CC BY-NC-ND license

(<http://creativecommons.org/licenses/by-nc-nd/4.0/>).

with diffuse GB wall edema, pericholecystic fluid collection extending into the subhepatic space, right paracolic region with surrounding right subhepatic and omental fat plane stranding, inflammation also noted in the right paracolic gutter-S/O Acute cholecystitis with biliary stent in-situ.

Patient was kept nil per oral and supportive therapy was started intravenously as antibiotics (broad spectrum carbapenem group of antibiotic, nitroimidazole group of antibiotic) thrice daily, proton pump inhibitors twice daily, with insertion of nasogastric tube and urinary catheter. On further review, found to have hypoalbuminemia with hypokalaemia and treatment imparted accordingly.

As, presenting complaints of GBP patients are abdominal pain associated with fever, and vomiting. however these features are commonly shared by different abdominal conditions (cholecystitis, pancreatitis, cholangitis, GBP, etc.); so it is difficult to diagnose this condition at once, but in view of CECT of whole abdomen findings of diffuse GB wall edema, pericholecystic fluid collection which was extending into the subhepatic space and right paracolic region an emergency decision was taken up for laparoscopic cholecystectomy.

After getting consent, patient was taken up for laparoscopic cholecystectomy and intra-operatively GB was not visualized as there was a presence of omental caking all over the GB (Fig. 1), and with great difficulty, adhesiolysis achieved followed by difficult dissection of Calot's triangle. GB was found to be perforated at the level of fundus and body with peritonitis (Figs. 2 and 3) as extensive amount of bile present in paracolic gutter and pelvis). Cholecystectomy was performed and thorough peritoneal toileting was done. Biopsy (excised tissue) was sent for HPE.

Patient sustained the procedure well and post-operatively, was managed with bowel rest, appropriate fluid, optimum analgesia and antibiotics. No worsening effects were seen post-operatively. Patient had an excellent recovery and was discharged in stable condition on 4th post-operative day.

Post-operatively, followed up after 5 days with no complaints. His biopsy specimen (open distorted specimen of Gall bladder, measuring 10 × 4cm) showed partial erosion of mucosa (ulcerated and brownish in appearance), moderate infiltrate of neutrophils, lymphocytes and plasma cells in the wall along with fibrosis, haemorrhage, granulation tissue and irregular thickening (wall thickness varies from 0.2 to 1.2cm) along with multiple calculi and ductal end was identified (measuring 0.2cm) –S/O Acute on chronic cholecystitis.

Patient was then followed up after 1 month and was doing well with no complaints.

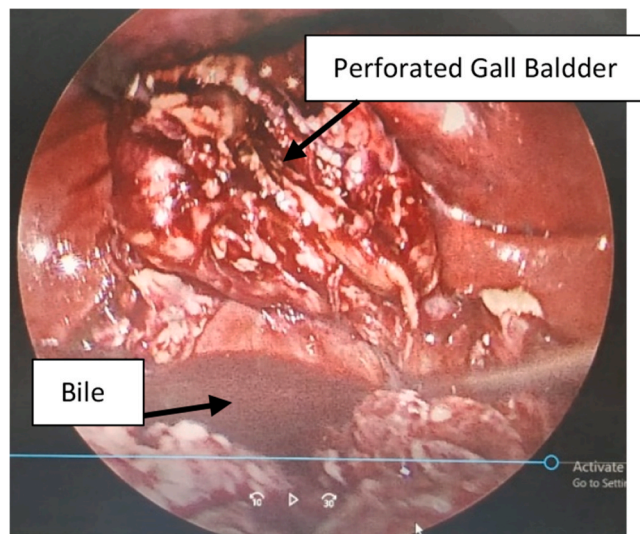


Fig. 2. Perforated GB with bile in peritoneum.

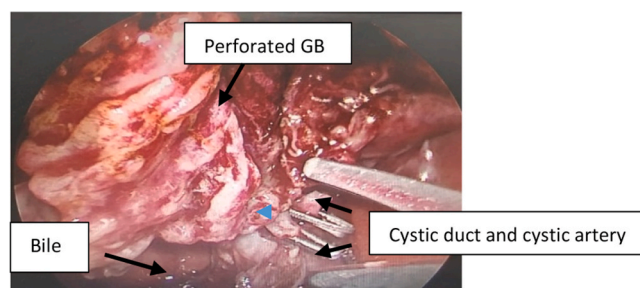


Fig. 3. Intra-operative findings of GBP with Peritonitis.

3. Discussion

GBP usually starts with the impaction of a bile stone in the cystic duct, followed by gall bladder distension, vascular impairment, and ischemia of the gall bladder wall, usually at the fundus, which is most distal part and therefore poorly vascularized and then ischemic part necrotizes and eventually ruptures, sometimes precipitated by infection. GBP should be considered with acute cholecystitis when the clinical condition deteriorated rapidly [4].

As per literature review, the risk factors of gall bladder perforation is

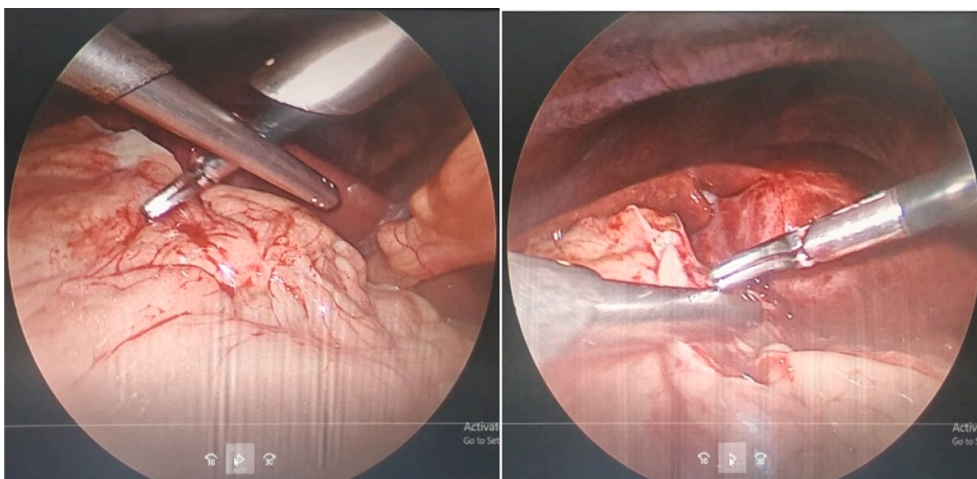


Fig. 1. GB not visualized due to omental caking.

age over 60 years with severe systemic disorders such as diabetes and atherosclerotic heart disease (as these patients already had compromised blood supply), however there was a second group of younger patients who were also at a risk for acute perforation and most of the younger patients were found to be immunosuppressed, was believed that the inability to combat infection played an important role in the GBP [5]. In our case, patient was not an immunosuppressed and moreover the histopathology findings were suggestive of acute on chronic calculus cholecystitis. Larmi et al. [6], Addison et al. [7], reported the risk of perforation to be between 3 and 12% in patients treated conservatively for acute cholecystitis. Thus, in our case the chronic calculus cholecystitis might be the reason of GBP.

The patients of GBP presented commonly with abdominal pain associated with fever, and vomiting, and however these features are commonly shared by different abdominal conditions (cholecystitis, pancreatitis, cholangitis, GBP, etc.); hence, it is difficult to diagnose this condition at once.

Mohamed M et al. [8]. reported that CT whole abdomen and MSCT findings are most specific and sensitive for the detection Of GBP and its complication. In our case, pre-operative diagnosis was made in view of contrast enhanced CT whole abdomen findings.

In this case, intraoperative findings were suggestive of Type-I GBP at the level of fundus and body with generalized peritonitis (as per revised Niemeir's classification, which classified GBP into three subtypes).

Any kind of delay in surgical intervention (Cholecystectomy) even in younger age group patients without any comorbid illness might result in life threatening complications such as GBP, which leads to biliary peritonitis. In response to biliary peritonitis, process of SIRS initiated through an immune system trigger (which is basically a response to a variety of quite different immune challenges) by releasing cytokines, which promotes repair and recruitment of phagocytes directed at pathogen.

However, as per SIRS classification by Bone et al. [9], stage I and stage II SIRS is progressive and reversible with timely intervention and stage III SIRS is detrimental, which carries increased mortality, and there are few guidelines of treatment which include medical and surgical care along with maintenance of nutrition and prevention for complications.

The most common complication associated with SIRS are related to progression of the disease to sepsis, septic shock and multi organ dysfunction syndrome and the prognosis depends upon timely intervention and control of pro-inflammatory state.

As in our case, patient had GBP with hypoalbuminemia and SIRS for which immediate surgical intervention (cholecystectomy) along with supplemented nutritional support with appropriate antibiotic and post-operative resuscitation is the mainstay treatment. So, change of management approach is doubtful in these cases. However pre-operatively, decision of laparoscopic cholecystectomy or open cholecystectomy is to be taken on the basis of patient clinical condition but sometimes, intra-operatively decision of conversion from laparoscopic to open surgery has to be done on the basis of difficulties (such as presence of adhesions, difficult callots dissection) during laparoscopic cholecystectomy.

4. Conclusion

- Acute cholecystitis patient of younger age group without any comorbid illness, also needs prompt surgical intervention (cholecystectomy).

- GBP should be considered with acute cholecystitis, when the clinical condition is deteriorating rapidly.
- In GBP having associated pre-operative risk factors (such as hypoalbuminemia and SIRS) needs prompt surgical intervention, as these factors might increase the morbidity and mortality in this rarest life threatening complication of acute cholecystitis.

Sources of funding

No funding sources.

Ethical approval

Not required.

Consent

A written informed consent was obtained from the patient for publication of this case report and accompanying images.

Author contribution

Drafting of manuscript, proofreading. All authors read and approved the final manuscript.

Provenance and peer review

Not-commissioned, externally peer-reviewed.

Guarantor

Dr. AniL Khetarpal & Dr. Ayush Khetarpal.

Declaration of competing interest

All authors declared no conflict of interest.

Appendix A. Supplementary data

Supplementary data to this article can be found online at <https://doi.org/10.1016/j.amsu.2021.102253>.

References

- [1] R.S. Date, S.G. Thrumurthy, S. Whiteside, M.A. Umer, K.G. Pursnani, J.B. Ward, et al., Gall bladder perforation : case series and systematic review, *Int. J. Surg.* 10 (2012) 63–68.
- [2] L. Genevieve, M.D. Bebbett, Cholelithiasis, cholecystitis, choledocholithiasis and hyperplastic cholecystoses, in: *Textbook of Gastrointestinal Radiology*, third ed., 2008.
- [3] A.A. Indar, I.J. Beckingham, Acute cholecystitis, *BMJ* 325 (7365) (2002) 639–643.
- [4] Mohamed M. Harraz, Ahmed H. Abouissa, Role of MSCT in the diagnosis of perforated gall bladder (A retrospective study) 51 (2020) 4.
- [5] J.J. Roslyn, J.E. Thompson Jr., H. Darvi, L. Den Besten, Risk factors for gall bladder perforation 82 (7) (1987) 636–640.
- [6] T.K. Larmi, M.I. Kairaluoma, J. Junila, S. Laitineu, M. Stahlberg, H.G. Fock, Perforation of the gall bladder. A retrospective comparative study of cases from 1946-1956 and 1969-1980, *Acta Chir. Scand.* 150 (1984) 557–560.
- [7] N.V. Addison, P.J. Finan, Urgent and early cholecystectomy for acute gall bladder disease, *Br. J. Surg.* 75 (1988) 141–143.
- [8] M. Mohamed, Ahmed H. Harraz, Abouissa. " Role of MSCT in the diagnosis of perforated gall bladder (A retrospective study) 51 (2020) 4.
- [9] R.C. Bone, R.A. Balk, F.B. Cera, et al., Definitions for sepsis and organ failure and guidelines for the use of innovative therapies in sepsis, *Chest* 101 (1992) 1644–1655.