

The Performance of Multiple Transgastric Procedures Using the Natural Orifice Transluminal Endoscopic Surgery Technique: Is Pure NOTES Satisfactory?

Tae Jun Song*, Dong Wan Seo†, Su Hui Kim‡, Do Hyun Park†, Sang Soo Lee†, Sung Koo Lee†, and Myung-Hwan Kim†

*Department of Internal Medicine, Inje University Ilsan Paik Hospital, Goyang, †Department of Internal Medicine and ‡Asan Institute for Life Science, Asan Medical Center, University of Ulsan College of Medicine, Seoul, Korea

Background/Aims: Although several groups have demonstrated the usefulness of natural orifice transluminal endoscopic surgery (NOTES), there is still concern about frequent serious adverse events. We performed this study to determine the technical feasibility and safety of pure NOTES with a transgastric approach in a porcine model from the endoscopist's point of view. **Methods:** Diagnostic peritoneoscopy, liver biopsy, salpingo-oophorectomy, and Fallopian tube ligation with a transgastric approach using a two-channel therapeutic endoscope were performed in 10 healthy female minipigs. These procedures were performed in two acute models and eight survival models in consecutive order. **Results:** The technical success rate was 100% for peritoneoscopy (10/10), liver biopsy (5/5), salpingo-oophorectomy (10/10), and Fallopian tube ligation (10/10). Eight cases of adverse events occurred, including one case of splenic injury, one case of bleeding after liver biopsy, two cases of small bowel adhesion after salpingo-oophorectomy, two cases of hematoma at the salpingo-oophorectomy site, and two cases of partial dehiscence at the gastric closure site. The gastric puncture site was closed with seven to eight hemoclips in four cases and two hemoclips and an endoloop in four cases. **Conclusions:** The use of pure NOTES for peritoneoscopy, liver biopsy, salpingo-oophorectomy, and Fallopian tube ligation may be technically feasible, but considerable adverse events can occur during or after the procedure. Further studies utilizing specialized techniques overcome several limitations of pure NOTES are therefore necessary. (*Gut Liver* 2012;6:457-463)

Key Words: Natural orifice endoscopic surgery; Endoscopy; Swine

INTRODUCTION

Natural orifice transluminal endoscopic surgery (NOTES) is a minimally invasive surgery technique that was recently devised and whose application areas are gradually expanding.¹⁻³ An incision is made in the esophagus, stomach, colon, or vagina instead of skin, and an endoscope is inserted through the incision site into the thoracic cavity or peritoneal cavity.⁴ According to the literature, Kalloo *et al.*¹ in 2004 first inserted an endoscope into the peritoneal cavity of a pig to observe organs in the peritoneal cavity. Since then, various studies on NOTES in animal models have been conducted, and its applications are gradually expanding. Recently in the USA, Europe, and South America, there have been sporadic reports on the applications of NOTES, mainly combined with laparoscopic technique, in performing diagnostic peritoneoscopy, cholecystectomy, appendectomy, and nephrectomy in human.^{3,5-8}

NOTES is mainly divided into two types: pure NOTES, which only uses an endoscope, and hybrid NOTES, which uses both an endoscope and a laparoscope.⁹ The use of a laparoscope is advantageous in that it facilitates acquisition of an additional view and intraoperative traction of organs, and the laparoscopic techniques, with many accumulated experiences, can be used to cope with various potential adverse events during the procedure.¹⁰ However, pure NOTES is meaningful for scarless advantage and minimal invasiveness, which are important advantages of NOTES.^{11,12}

According to preceding studies, endoscopists who are skilled in handling endoscopes seem to prefer a transgastric approach, whereas surgeons who are not experienced in handling endoscopes seem to prefer a transcolonic or transvaginal approach.

Correspondence to: Dong Wan Seo

Department of Internal Medicine, Asan Medical Center, University of Ulsan College of Medicine, 88 Olympic-ro 43-gil, Songpa-gu, Seoul 138-736, Korea

Tel: +82-2-3010-3190, Fax: +82-2-485-5782, E-mail: dwseoamc@amc.seoul.kr

Received on December 18, 2011. Revised on March 7, 2012. Accepted on March 16, 2012.

pISSN 1976-2283 eISSN 2005-1212 <http://dx.doi.org/10.5009/gnl.2012.6.4.457>

© This is an Open Access article distributed under the terms of the Creative Commons Attribution Non-Commercial License (<http://creativecommons.org/licenses/by-nc/3.0>) which permits unrestricted non-commercial use, distribution, and reproduction in any medium, provided the original work is properly cited.

The authors of the present paper conducted diagnostic peritoneoscopy, liver biopsy, salpingo-oophorectomy, and fallopian tube ligation with a transgastric approach in 10 pigs using pure NOTES technique with existing accessories from the standpoint of endoscopists, and investigated technical feasibility and adverse events of this technique before application in human.

MATERIALS AND METHODS

1. Subjects

For this experiment, 10 minipigs weighing about 40 kg each were used. The anesthesia was performed by one veterinarian, and the procedures were performed by three endoscopists and two nurses. Permission for this study was obtained from the Animal Experiment Review Board of Asan Medical Center.

2. Experiment methods

1) Pretreatment

The animals were fed a soft liquid diet beginning 48 hours before procedure and then abstained from food, except for only a small quantity of water, beginning 24 hours before procedure. They were anesthetized with a combination of anesthetic agents including tiletamine hydrochloride and zolazepam hydrochloride (Zoletil[®]; Virbac do Brasil Ltd., São Paulo, Brazil) and xylazine (Rompun[®]; Bayer Korea Co., Ltd., Seoul, Korea) before procedure, and general anesthesia was maintained with 1.5% isoflurane (Forane[®]; Choongwae Pharma Co., Ltd., Seoul, Korea). Pre-medication was performed 30 minutes before anesthesia using an intramuscular injection of Atropine sulfate (Bayer Korea Co., Ltd.). Even after abstinence from food, the remnant food material inside the stomach was washed several times with normal saline and removed by using endoscope before the procedure.

2) Procedure

(1) Gastric puncture and intraperitoneal access

A multibending two-channel endoscope (2TQ260[®]; Olympus Optical Co., Ltd., Tokyo, Japan) was used for the procedures. The minipigs were put in a supine position, and the endoscope was inserted into the stomach. The epigastric region under the xyphoid process was pressed from the outside to confirm the an-

terior wall of the body of the stomach, and the gastric wall was punctured with a needle knife (Micro knife[®]; Boston Scientific, Natick, MA, USA). After the puncture, a 0.035 inch guidewire (Jagwire[®]; Boston Scientific) was inserted into the peritoneal cavity through the needle knife, and then the needle knife was removed. A dilating balloon with a diameter of 20 mm (CRE[®]; Boston Scientific) was inserted along the guidewire, and the puncture site was dilated twice for 1 minute each. After dilation, the dilating balloon was pushed inside the peritoneal cavity together with the endoscope while being deflated. After entering into the peritoneal cavity, the guidewire and inflating balloon were removed from the scope.

(2) Peritoneoscopy

After intraperitoneal ingress, a peritoneoscopy was performed on the intraperitoneal organs, using the endoscope in the same manner as in esophagogastroduodenoscopy. Air was insufflated into the peritoneal cavity through the endoscope to secure a clear view during the peritoneoscopy. During the procedure, the electrocardiography and oxygen saturation of the minipigs were carefully monitored, and the volume of insufflated air was adjusted appropriately.

(3) Liver biopsy

The liver was macroscopically observed with retroflexed position of endoscope. Only macroscopic observation was performed in initial five pigs, and a random biopsy of the liver surface was performed in the other five pigs, using a biopsy forceps designed for endoscope. After biopsy, any possible adverse events were carefully observed.

(4) Salpingo-oophorectomy

With the endoscope positioned at the left or right lower abdomen, we found the fallopian tubes and ovaries of the minipigs while dragging the small bowel with forceps. After finding the ovary, an endoloop (Loop MAJ-254[®]; Olympus Co., Ltd.) was inserted through the other accessory channel on the opposite side of the endoscope. The endoloop was opened and the forceps passed through it. The ovary was caught using the forceps that was passed through the opened endoloop and dragged through the endoloop, and the ovary was ligated using the endoloop. Then, they were ligated one more time via the same method. A snare (Captivator Polypectomy Snare[®]; Boston Scientific) was

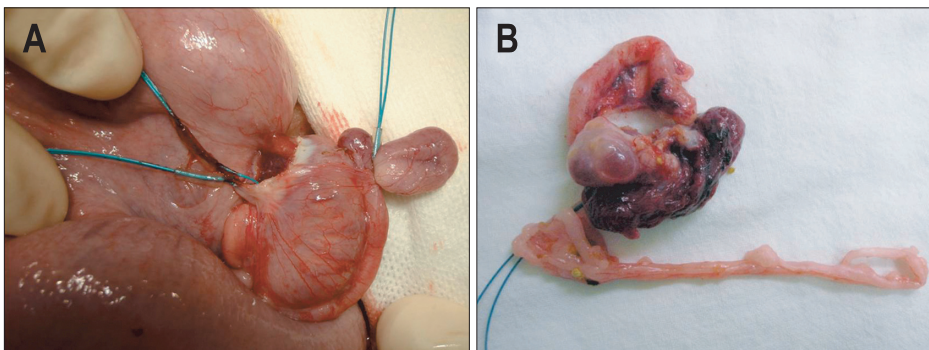


Fig. 1. (A) A post-mortem image showing the salpingo-oophorectomy and Fallopian tube ligation sites. The first two pigs were euthanized immediately after the procedure, and an autopsy was then conducted. (B) The digital image showed a resected ovary.

inserted instead of an endoloop, and the ovary was excised (Fig. 1). The excised ovary was removed through the oral cavity together with the endoscope, using a forcep or a retrieval basket (Roth Net®; US Endoscopy Group Inc., Mentor, OH, USA).

(5) Fallopian tube ligation

In the same manner as the salpingo-oophorectomy, the small bowel was dragged with a forceps and the fallopian tube was found. The fallopian tube was ligated twice using two endoloops.

(6) Closure of the gastric puncture site

After the procedure was completed, all the residual intraperitoneal air was aspirated and the endoscope was retracted into the stomach. The puncture site was then closed with seven or eight standard-sized hemoclips (EZ-clip; Olympus Co., Ltd.) or two hemoclips and an endoloop (Fig. 2). When only the hemoclips were used, clipping was performed from the margins of the incision site on both sides toward the center. When both the hemoclips and an endoloop were used, the margins of the incision site on both sides were clipped using the two hemoclips and the center of the incision site was raised with the forcep and closed using one endoloop.

3) Postoperative care

The first two pigs were operated on to investigate the feasibility of peritoneoscopy, liver biopsy, salpingo-oophorectomy, and fallopian tube ligation. In these cases, the gastric puncture site was not closed, and the pigs were euthanized immediately after the procedure, and then an autopsy was conducted. Gastric closure was performed for the other eight pigs. They survived for 7 days before they were euthanized, and then autopsies were conducted. For the pigs that survived for 7 days after the procedure, third-generation cephalosporin and analgesics were administered intravenously after procedure, and a liquid diet was fed starting after 24 hours. The health conditions and abnormal reactions of the animals, for example whether they ate well, were active, and thrive, were monitored for 7 days. After 7 days, the

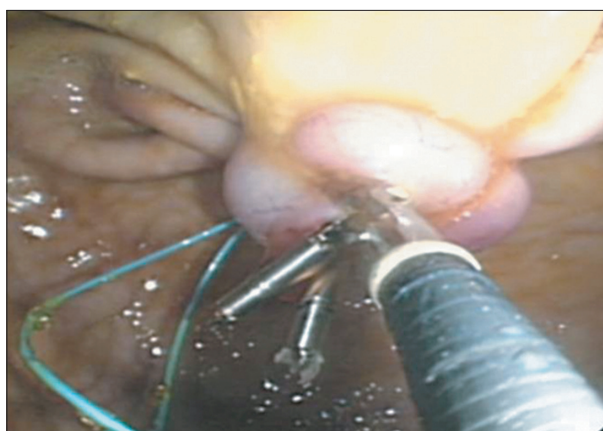


Fig. 2. An endoscopic view showing the gastric closure site with two hemoclips and an endoloop.

animals were euthanized and the sites of gastric closure, liver biopsy, salpingo-oophorectomy and the fallopian tube ligation were observed.

RESULTS

Multiple procedures including peritoneoscopy, liver biopsy, salpingo-oophorectomy, and fallopian tube ligation were performed in two acute models which were euthanized immediately after the procedure and eight survival models which were survived for 7 days in consecutive order. Among eight survival models, seven animals ate well, were active, and thrive without fever, vomiting, or diarrhea for 7 days. One animal suffered from anorexia, but other abnormal responses such as fever, vomiting, or diarrhea did not occur.

The summarized results of each procedure are shown in Table 1.

1. Gastric puncture and intraperitoneal access

Gastric puncture and intraperitoneal ingression were successful in all 10 pigs. There was no major difficulty in intraperitoneal ingression of the endoscope. When the endoscope was pushed inside the peritoneal cavity after the puncture site was inflated, the endoscope could be ingressed into the peritoneal cavity relatively easily by using the dragging force of the balloon into the peritoneal cavity as the balloon was slowly contracted. A spleen injury caused by the needle knife occurred during the gastric puncture in one case, but no special management was necessary. There were no other adverse events.

Table 1. The Summarized Results of Each Procedure

	No.
Technical success rates of each procedure	
Gastric puncture and intraperitoneal access	10/10
Peritoneoscopy	10/10
Liver biopsy	5/5
Salpingo-oophorectomy	10/10
Follopian tube ligation	10/10
Closure of the gastric puncture site	8/8
Methods of gastric closure	
Hemoclips	4
Hemoclips and an endoloop	4
Adverse events	
Adhesion of the small bowel	2
Hematoma at the salpingo-oophorectomy site	2
Partial dehiscence at the gastric closure site	2
Spleen injury during gastric puncture	1
Bleeding during liver biopsy	1

2. Peritoneoscopy

Peritoneoscopy was successful in all 10 pigs. The intraperitoneal organs were observed sequentially using the general endoscopy technique. The abdominal walls, small and large bowels, mesentery, and urinary bladder could be observed in a straight position of endoscope. When the endoscope was retroflexed, the liver, gallbladder, spleen, and stomach could be observed. There were no special adverse events during the peritoneoscopy.

3. Liver biopsy

The endoscope was retroflexed inside the peritoneal cavity and a random biopsy was performed on the liver surface using a biopsy forceps designed for endoscopy. Biopsies were performed in five pigs, and all the procedures were successful. There were no special technical difficulties, but bleeding occurred after biopsy in one case.

4. Salpingo-oophorectomy

Salpingo-oophorectomy was performed in 10 pigs, and all the procedures were successful. During the procedure, no special adverse events occurred. During the autopsies after one week, however, hematomas near the incision site were found in two pigs, and an adhesion of the small bowel near the incision site was found in two pigs (Fig. 3).

5. Fallopian tube ligation

Fallopian tube ligation was conducted in 10 pigs, and all

the procedures were successful. There were no special adverse events during or after the procedures.

6. Closure of the gastric puncture site

The closure of the puncture site on the gastric wall was conducted in eight pigs. The puncture site was closed using seven or eight hemoclips in four pigs (Fig. 4), and using two hemoclips and one endoloop in the other four pigs. The autopsies found no special adverse events in the four pigs for which only hemoclips were used for closure; in two pigs, healing occurred as the omentum adhered to the closure site. In two of the four pigs that used hemoclips and an endoloop, dehiscence was observed at the closure site. But due to adhesion of omentum on the serosal side of stomach, no leakage of gastric contents into the peritoneal cavity was observed. No other adverse events were observed.

DISCUSSION

In this study, the authors performed peritoneoscopy, liver biopsy, salpingo-oophorectomy, and fallopian tube ligation in 10 pigs, using a transgastric approach that implemented only the currently used endoscope and accessories according to the pure NOTES technique. After euthanasia, autopsies were performed on the eight pigs that survived for 7 days to confirm the existence of adverse events. This study demonstrated that pure NOTES technique can be used for various procedures on intra-

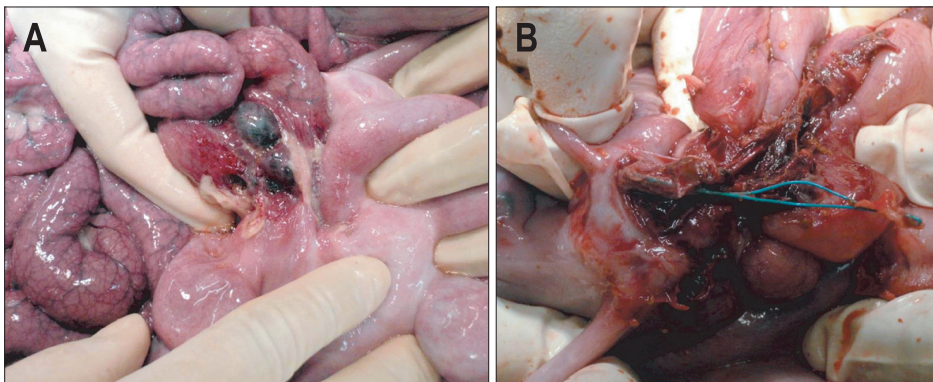


Fig. 3. Adverse events after salpingo-oophorectomy. (A) The autopsy showed a small bowel adhesion near the incision site after salpingo-oophorectomy. (B) The autopsy showed hematoma formation at the salpingo-oophorectomy site.

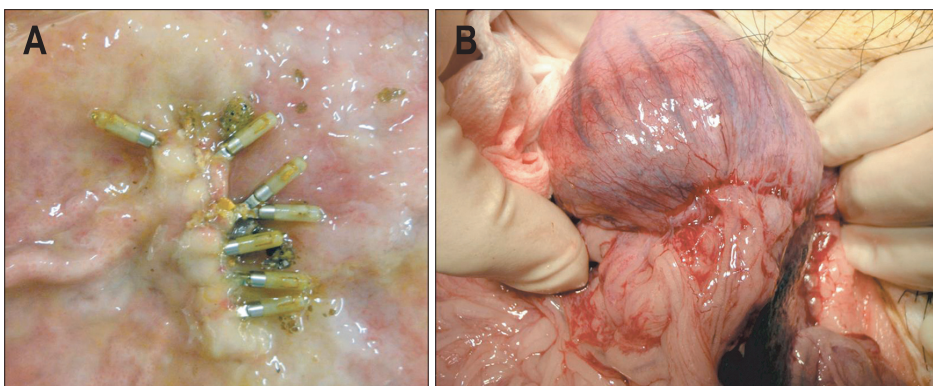


Fig. 4. Autopsy of the gastric closure site. (A) The gastric closure site with multiple hemoclips. (B) The autopsy showed the serosal side of the gastric closure. The omentum adhered to the puncture site.

peritoneal organs with transgastric approach. However, there were several technical difficulties and risks of adverse events due to limited view during the procedure and lack of instruments for NOTES.

Unlike hybrid NOTES, which is conducted together with a laparoscope, the pure NOTES technique only uses an endoscope, with no assistance from a laparoscope. Since pure NOTES does not need any skin incision, it is truly a no-scar surgery.^{11,12} However, as no laparoscope was used for additional view and traction, the intraoperative view in pure NOTES technique was limited. In other words, because the working channels through which the accessories come out and the camera of endoscope is positioned are on the same line, it is difficult to secure a view during the procedure. Moreover, the procedures were difficult because the formation of triangulation of the camera, accessory for traction, and other accessory for operation such as needle knife or snare was difficult.

In this study, the room air that is generally used for endoscopy was insufflated inside the peritoneal cavity to form pneumoperitoneum. During the laparoscopic surgery, the intraperitoneal pressure is continuously monitored and the pressure of the insufflated gas was controlled according to it. However, the intraperitoneal pressure was not directly measured in this study. Instead, changes in the cardiopulmonary functions were checked by continuously measuring oxygen saturation and electrocardiography. In our study, adverse events related to the overinflation of the abdominal cavity did not occur. As overinflation of the abdominal cavity, however, may cause adverse events including decreased venous return, impaired ventilation, risk of gas embolism, and subcutaneous emphysema, it is very important to adjust the volume of insufflated gas by measuring the intraperitoneal pressure during the procedure. Because pure NOTES only uses an endoscope without assistance of laparoscope, a probe which measures the intraperitoneal pressure must be inserted through the accessory channel of the endoscope, but continuous monitoring of intraperitoneal pressure is impossible if another accessory must be used through the accessory channel. Thus, a new NOTES-exclusive scope or platform should include a device for measuring intraperitoneal pressure inside the scope.

The gastric puncture could be conducted relatively safely at the anterior wall of the body of the stomach with the conventional technique that is used in percutaneous endoscopic gastrostomy procedure. However, as it is a blind puncture, there is concern for injuring surrounding blood vessels during the puncture. In this study, there was one case of spleen injury caused by the needle knife during the gastric puncture. Although the probability of spleen injury during the gastric puncture can be higher in pigs than in human due to the different anatomy of pigs, safe gastric puncture is an important issue in the NOTES procedure. Submucosal tunnel technique has been reported as another puncture technique.^{13,14} This technique is advantageous

for closing the incision site after procedure, but it also carries a risk of injury to surrounding blood vessels or organs, as a blind puncture must be performed in the last step of entry into the peritoneal cavity. Using endoscopic ultrasound (EUS) as a method to reduce this risk of gastric puncture would make for safer procedures, since adverse events could be reduced by selecting the puncture site that can best prevent injury to surrounding blood vessels and organs using EUS with color Doppler.^{4,15} A study on drainage of pancreatic pseudocysts also reported that conducting a puncture with EUS significantly reduced the percentage of adverse events related to the procedure, such as bleeding, compared to blind puncture.¹⁶ Thus, more studies will be necessary to compare the results of EUS-guided puncture and blind puncture in the transgastric approach.

The intraperitoneal procedures in the present study used the usual techniques of endoscopy. However, handling the endoscope was difficult inside the peritoneal cavity because there was no supporting part for the endoscope, unlike inside the stomach or duodenum. In this study, we used a multibending scope with two bending points, which allowed different angle adjustments. However, the endoscope had to be handled in free space with no supporting part, and it was not easy to fix the endoscope during the procedure. As far as we know, as various scopes that allow easy tip angle adjustment and easy use of accessories are under development now, they can overcome these limitations in the near future.¹⁷ Moreover, as there are no instruments designed for NOTES procedures yet, the existing accessories for endoscopy had to be used. In particular, instruments for hemostasis were insufficient. Hybrid NOTES can cope with complications through experiences from laparoscopic surgeries and assistance of various laparoscopic instruments. However, experiences are insufficient, and various limitations in the intraoperative view and traction exist with pure NOTES compared to hybrid NOTES. Therefore, instruments to control various adverse events that can occur during the procedures must be developed to secure safe NOTES procedures.

In this study, hemoclips that are mainly used for conventional endoscopy were used for closure of gastric puncture site. Instead of incising the gastric wall, a needle knife was used to puncture the gastric wall, and a dilating balloon was used to dilate the puncture site, through which the endoscope was inserted into the peritoneal cavity. Thus, as the incision site of the gastric wall was small after procedure, it could be relatively easily closed with hemoclips. Hemoclips have the shortcoming of a full thickness suture not being possible.¹⁸ In this study, however, the autopsies conducted after 7 days found that two of the four cases that were closed with seven or eight hemoclips healed as the omentum covered the incision site from the serosal side, even without full thickness suture. As all four of the cases healed without special adverse events, we think that the closure technique using hemoclips may be used safely even without full thickness closure.

In four cases, the edges at both sides of the puncture site were closed using two hemoclips, then the center of the incision site was raised with a forceps and a full thickness closure was performed using an endoloop. Previous studies that conducted closure of the incision site using endoloops used three endoloops.^{19,20} In our study, full thickness closure was possible even with one endoloop because balloon dilatation was used without incising the gastric wall and the incision site was small. Furthermore, either side of the incision site was closed with one hemoclip, so the gastric walls at both sides of the incision were gathered to the center, which facilitated closure with an endoloop. The endoloop technique has the advantage of full thickness closure, but dehiscence can occur at the closure site if the tension of the endoloop is too high. In this study, partial dehiscence occurred in two cases at the endoloop closure site. In these cases there was no leakage of gastric contents or peritonitis, as the omentum adhered to the serosal side of the stomach. However, special care must be taken to prevent too much tension when using endoloops. As various prototypes of closure devices are currently being developed, it is expected that more studies on closure will be conducted in the future.^{18,21-23}

In conclusion, the peritoneoscopy, liver biopsy, salpingo-oophorectomy, and fallopian tube ligation that were conducted using the pure NOTES technique with transgastric approach in this study were technically feasible, but there were several limitations to be improved and various adverse events could occur. From the standpoint of endoscopists, pure NOTES is a new technique that has various attractive advantages, but limitations still exist, as there are few devices specific to NOTES. As safety must be secured first for successful procedure using pure NOTES in human, additional studies focusing on safe procedures are required.

CONFLICTS OF INTEREST

No potential conflict of interest relevant to this article was reported.

ACKNOWLEDGEMENTS

This study was supported by a grant (grant no. w11-201) from the Asan Institute for Life Sciences, Seoul, Korea.

REFERENCES

1. Kalloo AN, Singh VK, Jagannath SB, et al. Flexible transgastric peritoneoscopy: a novel approach to diagnostic and therapeutic interventions in the peritoneal cavity. *Gastrointest Endosc* 2004;60:114-117.
2. Giday SA, Kantsevoy SV, Kalloo AN. Current status of natural orifice transluminal surgery. *Gastrointest Endosc Clin N Am* 2007;17:595-604.
3. ASGE Technology Committee, Kantsevoy SV, Adler DG, et al. Natural orifice transluminal endoscopic surgery. *Gastrointest Endosc* 2008;68:617-620.
4. Abbas Fehmi SM, Kochman ML. Natural orifice transluminal endoscopic surgery 2009: what is the future for the gastroenterologist? *Curr Opin Gastroenterol* 2009;25:399-404.
5. Lehmann KS, Ritz JP, Wibmer A, et al. The German registry for natural orifice transluminal endoscopic surgery: report of the first 551 patients. *Ann Surg* 2010;252:263-270.
6. Shin EJ, Jeong GA, Jung JC, et al. Transvaginal endoscopic appendectomy. *J Korean Soc Coloproctol* 2010;26:429-432.
7. Kaouk JH, White WM, Goel RK, et al. NOTES transvaginal nephrectomy: first human experience. *Urology* 2009;74:5-8.
8. Zornig C, Mofid H, Siemssen L, et al. Transvaginal NOTES hybrid cholecystectomy: feasibility results in 68 cases with mid-term follow-up. *Endoscopy* 2009;41:391-394.
9. von Delius S, Meining A. Natural orifice transluminal endoscopic surgery (NOTES). *Endoscopy* 2010;42:73-76.
10. Mori H, Kobara H, Kobayashi M, et al. Establishment of pure NOTES procedure using a conventional flexible endoscope: review of six cases of gastric gastrointestinal stromal tumors. *Endoscopy* 2011;43:631-634.
11. McGee MF, Rosen MJ, Marks J, et al. A primer on natural orifice transluminal endoscopic surgery: building a new paradigm. *Surg Innov* 2006;13:86-93.
12. Pearl JP, Ponsky JL. Natural orifice transluminal endoscopic surgery: a critical review. *J Gastrointest Surg* 2008;12:1293-1300.
13. Lee CK, Lee SH, Chung IK, et al. Human diagnostic transgastric peritoneoscopy with the submucosal tunnel technique performed with the patient under conscious sedation (with video). *Gastrointest Endosc* 2010;72:889-891.
14. Sumiyama K, Gostout CJ, Rajan E, Bakken TA, Knipschild MA, Marler RJ. Submucosal endoscopy with mucosal flap safety valve. *Gastrointest Endosc* 2007;65:688-694.
15. Elmunzer BJ, Schomisch SJ, Trunzo JA, et al. EUS in localizing safe alternate access sites for natural orifice transluminal endoscopic surgery: initial experience in a porcine model. *Gastrointest Endosc* 2009;69:108-114.
16. Park DH, Lee SS, Moon SH, et al. Endoscopic ultrasound-guided versus conventional transmural drainage for pancreatic pseudocysts: a prospective randomized trial. *Endoscopy* 2009;41:842-848.
17. Moyer MT, Haluck RS, Gopal J, Pauli EM, Mathew A. Transgastric organ resection solely with the prototype R-scope and the self-approximating transluminal access technique. *Gastrointest Endosc* 2010;72:170-176.
18. Lee SS, Oelschlager BK, Wright AS, et al. Assessment of a simple, novel endoluminal method for gastrotomy closure in NOTES. *Surg Endosc* 2011;25:3448-3452.
19. Katsarelias D, Polydorou A, Tsaroucha A, et al. Endoloop application as an alternative method for gastrotomy closure in experimental transgastric surgery. *Surg Endosc* 2007;21:1862-1865.

20. Hucl T, Benes M, Kocik M, et al. A novel double-endoloop technique for natural orifice transluminal endoscopic surgery gastric access site closure. *Gastrointest Endosc* 2010;71:806-811.
21. Chiu PW, Lau JY, Ng EK, et al. Closure of a gastrotomy after transgastric tubal ligation by using the Eagle Claw VII: a survival experiment in a porcine model (with video). *Gastrointest Endosc* 2008;68:554-559.
22. Hookey LC, Bielawska B, Samis A, et al. A reliable and safe gastrotomy closure technique assessed in a porcine survival model pilot study: success of the Queen's closure. *Endoscopy* 2009;41:493-497.
23. Meireles OR, Kantsevov SV, Assumpcao LR, et al. Reliable gastric closure after natural orifice transluminal endoscopic surgery (NOTES) using a novel automated flexible stapling device. *Surg Endosc* 2008;22:1609-1613.