

# Computer-assisted Patient-specific Prototype Template for Thoracolumbar Cortical Bone Trajectory Screw Placement: A Cadaveric Study

Sang Bum Kim, MD, PhD,\* John M. Rhee, MD,† Gi Soo Lee, MD,‡  
Hee Young Lee, MD,§ Taehyung Kim, MD,|| and Yougun Won, MD\*

**Summary:** The cortical bone trajectory (CBT) screw technique yields effective mechanical and clinical results, improving the holding screw strength with a less invasive exposure. Accurate and safe screw placement is crucial. A patient-specific drill template with a preplanned trajectory was considered a promising solution; however, it is critical to assess the efficacy and safety of this technique. This study aims to evaluate the accuracy of patient-specific computed tomography (CT)-based rapid prototype drill guide templates for the CBT technique. CT scanning was performed in 7 cadaveric thoracolumbar spines, and a 3-dimensional reconstruction model was generated. By using computer software, we constructed drill templates that fit onto the posterior surface of thoracolumbar vertebrae with drill guides to match the CBT. In total, 80 guide templates from T11 to L5 were created from the computer models by using rapid prototyping. The drill templates were used to guide the drilling of CBT screws without any fluoroscopic control, and CT images were obtained after fixation. The entry point and direction of the planned and inserted screws were measured and compared. In total, 80 screws were inserted from T11 to L5. No misplacement or bony perforation was observed on postoperative CT scan. The patient-specific prototype template system showed the advantage of safe and accurate cortical screw placement in the thoracolumbar spine. This method showed its ability to customize the patient-specific trajectory of the spine, based on the unique morphology of the spine. The potential use of drill templates to place CBT screws is promising.

**Key Words:** drill template—cortical bone screw—computer-assisted template—rapid prototyping.

(*Tech Orthop* 2018;33: 246–250)

A patient-specific drill template (PSDT) with a preplanned trajectory has been considered a promising solution that may reduce the rate of spinal screw malposition without additional intraoperative radiation exposure. However, it is critical to assess the efficacy and safety profile of this technique. Previously, several studies reported the favorable performance of patient-specific guide template made by rapid prototyping and designed using a 3-dimensional (3D) method.<sup>1–7</sup> These studies involved cervical laminar and pedicle screws, as well as thoracic pedicle screws.

From the \*College of Medicine, Konyang University, Daejeon; §Changwon Fatima Hospital, Changwon; ||College of Medicine, Yonsei University, Seoul; ‡Department of Orthopedic Surgery, Chungnam National University, School of Medicine, Daejeon, South Korea; and †Department of Orthopaedic Surgery, Emory University, Atlanta, GA.

Supported in part by Konyang University Myunggok Research Fund 2015.

The authors declare that they have nothing to disclose.

**For reprint requests, or additional information and guidance on the techniques described in the article, please contact Yougun Won, MD, at yougunwon@gmail.com; ywon1@partners.org or by mail at Department of Orthopaedic Surgery, Konyang University College of Medicine. You may inquire whether the author(s) will agree to phone conferences and/or visits regarding these techniques.**

Copyright © 2018 Wolters Kluwer Health, Inc. All rights reserved.

For improving the holding screw strength with a less invasive exposure, a cortical bone trajectory (CBT) screw was introduced.<sup>8</sup> The CBT screw has a different trajectory, passing through denser bone than the traditional pedicle screw trajectory. The trajectory is a caudocephalad path sagittally and a divergent path in the transverse plane. Both the cortical bone of the vertebral posterior laminar surface and that of the upper-end plate of the vertebral body can be engaged. The CBT technique has been shown to produce better screw pullout strength, enough mechanical strength and clinical results.<sup>8–12</sup> To date, however, there is no research on CBT screw templates with a computer-assisted patient-specific prototype. The goal of this study was to evaluate the accuracy of patient-specific computed tomography (CT)-based rapid prototype drill guide templates for the thoracolumbar CBT technique.

## MATERIALS AND METHODS

Seven formalin-fixed cadaveric thoracolumbar spines were obtained from T11 to L5. The mean age of cadavers was  $78.1 \pm 12.8$  years. There were 6 male cadavers and 1 female cadaver. The total number of screws inserted was 80, with a mean number of screws per specimen of  $11.4 \pm 2.2$  (Table 1). Pre-operative spiral 3D CT scan (Light Speed VCT; GE) was performed on the thoracolumbar spine with 0.625 mm slice thickness and 0.35 mm in-plane resolution. The images were stored in DICOM format and transferred to a workstation running MIM-ICS 17.0 software, 3-Matic 9.0 (Materialise Company, Belgium), to generate a 3D reconstruction template for the desired thoracolumbar vertebra (Fig. 1A, B). The accurate trajectory and screw diameter and length were calculated with UG Imageware 12.1 (EDS Co.) (Fig. 2). The drill guide template was produced by using the reverse mirror image technique with a Connex 2 to 3D multimaterial 3D printer (Stratasys Co.). The biomodel of the navigational template was produced in acrylic resin (Somos 14120; DSM Desotech Inc., Elgin, IL). By using computer software, we constructed the drill templates that fit onto the posterior surface of the thoracolumbar vertebrae with drill guides to match the CBT (Fig. 1). In total, 80 guide templates from T11 to L5 were created from the computer models by using the 3D printer (Fig. 1A-C). The drill templates were used to guide the drilling of the trajectory of the cortical bone screw, without any fluoroscopic control. Fitting the template in the adequate site was useful because the laminar surface was adequately mirror imaged. The hold of the template was fairly secure on the lamina as there was not any movement of the template on slight digital pressure. Fluoroscopy was required only once after the insertion of the entire CBT screws.

After all CBT screws had been inserted, we performed a CT scan to evaluate the position of the screws. By using the Imageware program, the postoperative CT scan data were compared with the preplanned trajectory for the assessment of

**TABLE 1.** Demographic Data of Cadavers

Case	Age (y)	Sex	Screw Location	No. Screws
1	86	M	L1,3,4,5	8
2	80	M	T12,L1,2,3,4,5	12
3	99	F	L1,2,3,4,5	10
4	58	M	T11,12,L1,2,3,4,5	14
5	71	M	T12,L1,2,3,4,5	12
6	72	M	T11,12,L1,2,3,4,5	14
7	80	M	L1,2,3,4,5	10

F indicates female; M, male.

safety and accuracy. We stacked pre-CT and post-CT slices of axial and sagittal planes and measured the distance between the preplanned trajectory and the fixed screws (Fig. 3).

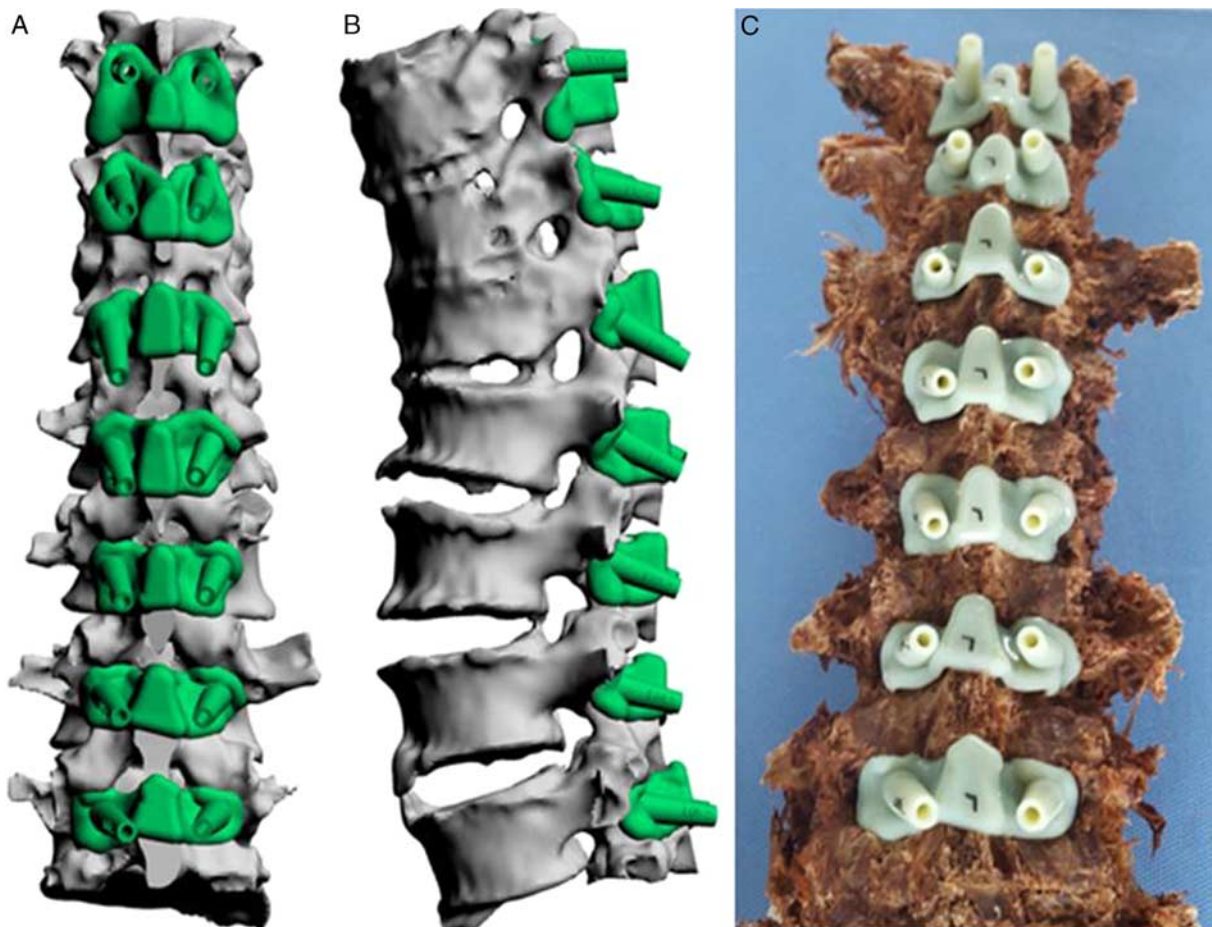
## RESULTS

In total, 80 screws were inserted from T11 to L5. Four vertebral bodies were excluded due to osteoporotic compression fracture. A >30% decrease in vertebral body height was exclusion criteria of osteoporotic deformation or osteoporotic compression fracture. To evaluate the accuracy of screw fixation, the following criteria were used—class 1 (accurate):

the screw axis deviates by <2 mm from the planned trajectory; class 2 (inaccurate): the screw axis deviates by  $\geq 2$  but <4 mm; class 3 (deviated): the screw axis deviates by  $\geq 4$  mm.<sup>13</sup> No screws deviated from the preplanned trajectory. Four screws were inaccurate by <4 mm (class 2) and the others were placed accurately (class 1) (Table 2). The mean deviations of class 1 screws were  $0.94 \pm 0.42$  mm, and those of class 2 screws were  $2.75 \pm 0.64$  mm. It took 1 to 2 minutes to fit the template to the lamina and to fix the CBT screws.

## DISCUSSION

The complications associated with the use of spine screw fixation, including screw misplacement, nerve root injury, dural injury, and infection, must be considered.<sup>14–16</sup> To reduce these complications, 3D template guide techniques have been introduced, with good results reported.<sup>1,3,5,6,17,18</sup> For the pedicle screw in the lumbar and thoracic spine, Lamartina et al<sup>18</sup> described 43 of 54 pedicle screws (91%) were placed accurately. Furthermore, these techniques are also expected to reduce hazardous radiation exposure and to shorten the operation time. Intraoperative fluoroscopic confirmation with hazardous radiation is still important in the use of an image-guided navigational system or minimally invasive techniques.<sup>19</sup> In this study, fluoroscopy was required only once after the insertion of



**FIGURE 1.** A, B, The data (in DICOM format) of 3D computed tomography scan performed on the thoracolumbar spine were transferred to generate a 3D reconstruction of the template. C, The drill guide template was produced by using the reverse mirror image technique with a Connex 2 to 3D multimaterial 3D printer in acrylate resin and applied to a cadaveric model. 3D indicates 3-dimensional. full color online

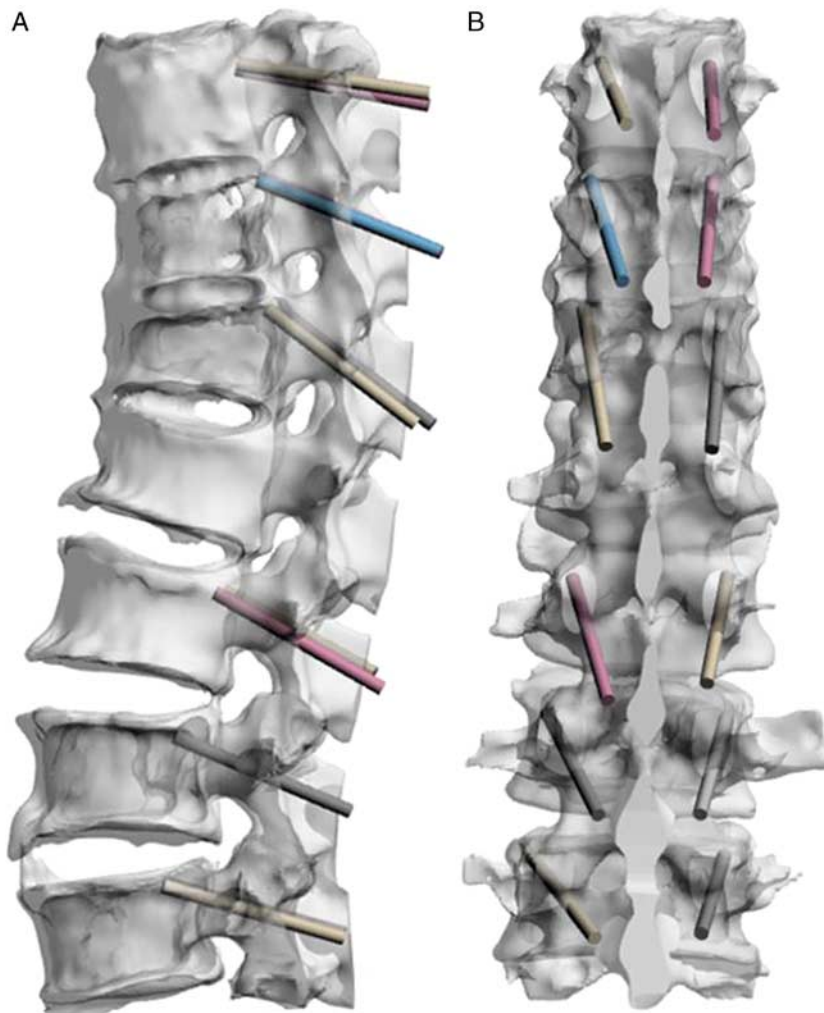


FIGURE 2. A, B, The accurate trajectory and screw diameter and length were calculated with UG Imageware 12.1. [full color online](#)

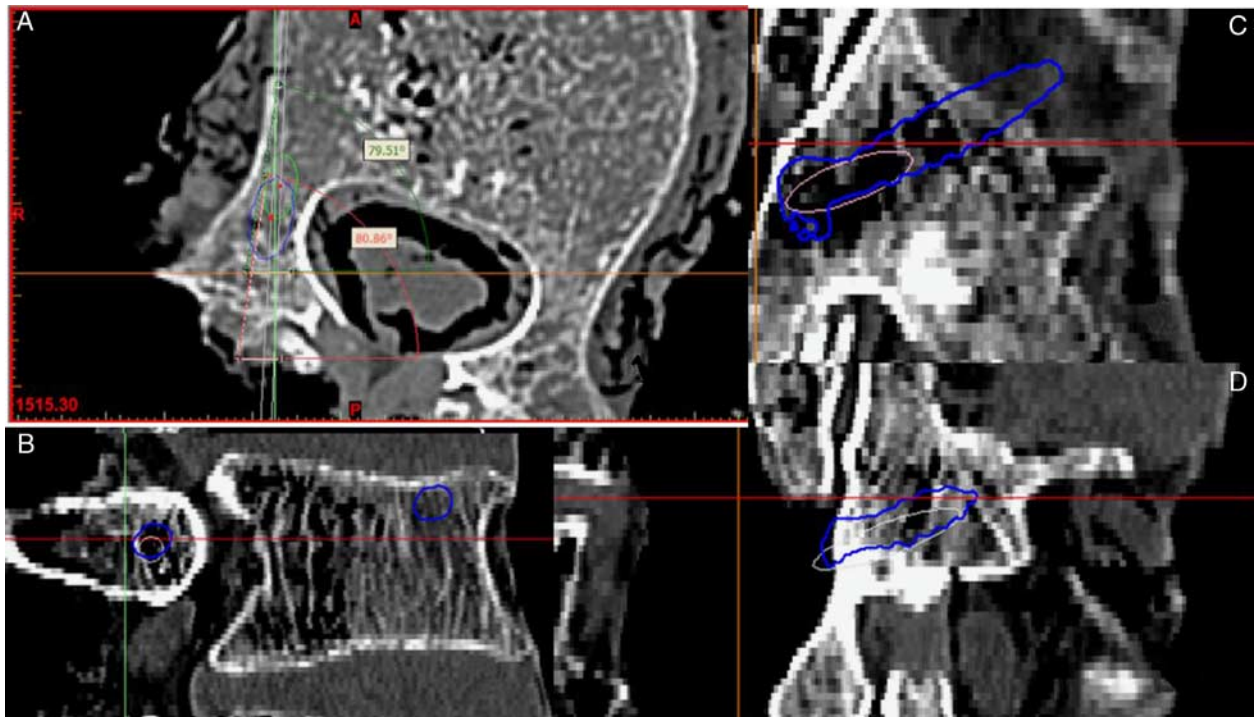
the screws. Thereby reducing the duration of radiation exposure to the surgical team. The PSDT has the ability to customize both the placement and the size of each screw, based on the unique morphology of each patient's vertebral lamina, and to preoperatively prepare the surgical plan. Verifying the accuracy of this simple template guide may help alleviate procedural anxiety, especially among less experienced spine surgeons. A suitable position of the template was easily found, because of the specific fit of the postural lamina surface with the template, by pressing gently with the surgeon's finger. Vibration during drilling or the gap between the lamina and the PSDT can cause errors. In this regard, clean preparation of the lamina surface is essential. Although the PSDT has many advantages over previous fluoroscopy-guided screw-insertion techniques, including less hazardous radiation exposure and less screw misplacement rate,<sup>3,7,12</sup> the analysis and progress of this technique will require further study. However, such efforts will ensure safety and accuracy of using these techniques. By using this novel, custom-fit navigational template, the operation time can be considerably reduced.<sup>5,13</sup>

The cortical trajectory followed a caudocephalad path sagittally and a laterally directed path in the transverse plane, engaging only the cortical bone in the pedicle without the involvement of the vertebral body trabecular space.<sup>9</sup> CBT

screws are shorter and smaller but potentially more powerful. Theoretically, the advantage associated with this technique is increased cortical bone contact, providing enhanced screw grip and interface strength independent of trabecular bone mineral density.<sup>20</sup> Mechanical studies support this theoretical advantage. CBT has been shown to increase the resistance to pullout by 30% compared with the pedicle screw.<sup>8,9</sup> Clinically, Takenaka and colleagues reported CBT has less blood loss, less intraoperative muscle injury, and less perioperative pain which led early recovery. However, as it is newly developed and unfamiliar, proper positioning is difficult with CBT. The positioning of CBT screws after decompressive procedures such as a partial or total laminectomy during spinal surgery might be difficult because the landmark of the starting point of the CBT screw is on the posterior surface of a lamina bone, which would be removed during the decompression. PSDT may be especially useful for surgeons who are not familiar with CBT.

Compared with the PSDT, robot-based systems and associated navigational systems require more space for the instruments, and their increased operative time can contribute to infection risk.<sup>21</sup> Moreover, such systems may require more time, greater personnel, and higher expense. These demands allow the use of robot systems in only a few hospitals that have sufficient human and financial resources.<sup>22,23</sup> With the





**FIGURE 3.** Postoperative computed tomography scan data were compared with the preplanned trajectory safety and accuracy. Blue in the image indicates the screw and white indicate the preplanned trajectory. Each axial (A) slice and sagittal slice (B–D) was measured. [full color online](#)

technique presented in this study, a single programmer, handled the software, and the material was inexpensive. The average cost of material in this study was \$10 for each template, and known cost for patient-specific drill template is \$8 to \$50.<sup>7</sup> The time required for manufacturing the PSDT including designing and printing was <1 day. Although we need 1 day for preparation, it will be worth it because it can decrease intraoperative time.<sup>7</sup> Our 3D printing machine is over \$200,000 and is a multipurpose, multimaterial, high-quality machine. An entry-level 3D printer suitable for printing drill guides may be obtained for only a few thousand US dollars with similar or lower average cost of material.<sup>7,24</sup> The reliability and print speeds may differ, and further research is needed to determine best practices for 3D printing templates. Nevertheless, we believe the PSDT is cost-effective, convenient, and demonstrates clear advantage of safe and accurate cortical screw placement in the thoracolumbar spine.

**Limitation**

Currently, we do not have the standard methods for measuring the accuracy and safety using statistical methods. We need standard methods for evaluating the accuracy of mirror-imaged template to confirm the adequate placement onto the laminar

surface. Our design of the template did not aim the soft tissue preservation, which is the advantage of the cortical screw in a clinical situation. Some drill guide templates are composed of 2 units for 1 spine level for the left side and right side. Such design provides the preservation of more soft tissues including posterior ligament complex.<sup>7</sup> Further clinical study of the efficacy and optimal design of template will be beneficial. This study is not a comparative clinical trial, and a further study is comparing with the robot and the navigational system would be more informative to decide optimal guide-aided surgery methods.

**CONCLUSIONS**

The PSDT customizes patient-specific trajectory for CBT screw placement in the thoracolumbar spine, based on the unique morphology of the individual. The use of drill templates in placing thoracolumbar CBT screws is promising due to its accuracy, low cost, and ease of use.

**REFERENCES**

1. Lu S, Xu YQ, Zhang YZ, et al. A novel computer-assisted drill guide template for placement of C2 laminar screws. *Eur Spine J.* 2009;18:1379–1385.
2. Kaneyama S, Sugawara T, Sumi M. Safe and accurate midcervical pedicle screw insertion procedure with the patient-specific screw guide template system. *Spine (Phila Pa 1976).* 2015;40:E341–E348.
3. Lu S, Zhang YZ, Wang Z, et al. Accuracy and efficacy of thoracic pedicle screws in scoliosis with patient-specific drill template. *Med Biol Eng Comput.* 2012;50:751–758.
4. Sugawara T, Higashiyama N, Kaneyama S, et al. Multistep pedicle screw insertion procedure with patient-specific lamina fit-and-lock templates for the thoracic spine: clinical article. *J Neurosurg Spine.* 2013;19:185–190.

**TABLE 2.** Results

Class (Accuracy)*	No. Screws	Mean Deviation ± SD (mm)
1	76	0.94 ± 0.42
2	4	2.75 ± 0.64
3	0	NA

\*Class 1 (accurate): the axis deviates by <2 mm from the planned trajectory. Class 2 (inaccurate): the screw axis deviates by ≥ 2 but <4 mm. Class 3 (deviated): the screw axis deviates by ≥ 4 mm. NA indicates not applicable.

5. Lu S, Xu YQ, Zhang YZ, et al. A novel computer-assisted drill guide template for lumbar pedicle screw placement: a cadaveric and clinical study. *Int J Med Robot*. 2009;5:184–191.
6. Ma T, Xu YQ, Cheng YB, et al. A novel computer-assisted drill guide template for thoracic pedicle screw placement: a cadaveric study. *Arch Orthop Trauma Surg*. 2012;132:65–72.
7. Kim SB, Won Y, Yoo HJ, et al. Unilateral spinous process non-covering hook type patient-specific drill template for thoracic pedicle screw fixation: a pilot clinical trial and template classification. *Spine (Phila Pa 1976)*. 2017;42:E1050–E1057.
8. Santoni BG, Hynes RA, McGilvray KC, et al. Cortical bone trajectory for lumbar pedicle screws. *Spine J*. 2009;9:366–373.
9. Perez-Orribo L, Kalb S, Reyes PM, et al. Biomechanics of lumbar cortical screw-rod fixation versus pedicle screw-rod fixation with and without interbody support. *Spine (Phila Pa 1976)*. 2013;38:635–641.
10. Takenaka S, Mukai Y, Tateishi K, et al. Clinical outcomes after posterior lumbar interbody fusion: comparison of cortical bone trajectory and conventional pedicle screw insertion. *Clin Spine Surg*. 2017;30:E1411–E1418.
11. Oshino H, Sakakibara T, Inaba T, et al. A biomechanical comparison between cortical bone trajectory fixation and pedicle screw fixation. *J Orthop Surg Res*. 2015;10:125.
12. Sakaura H, Miwa T, Yamashita T, et al. Posterior lumbar interbody fusion with cortical bone trajectory screw fixation versus posterior lumbar interbody fusion using traditional pedicle screw fixation for degenerative lumbar spondylolisthesis: a comparative study. *J Neurosurg Spine*. 2016;25:591–595.
13. Kaneyama S, Sugawara T, Sumi M, et al. A novel screw guiding method with a screw guide template system for posterior C-2 fixation: clinical article. *J Neurosurg Spine*. 2014;21:231–238.
14. Davne SH, Myers DL. Complications of lumbar spinal fusion with transpedicular instrumentation. *Spine*. 1992;17:S184–S189.
15. Uribe JS, Deukmedjian AR, Mummaneni PV, et al. Complications in adult spinal deformity surgery: an analysis of minimally invasive, hybrid, and open surgical techniques. *Neurosurg Focus*. 2014;36:E15.
16. Perez-Cruet MJ, Fessler RG, Perin NI. Review: complications of minimally invasive spinal surgery. *Neurosurgery*. 2002;51(suppl): S26–S36.
17. Hu Y, Yuan ZS, Spiker WR, et al. Deviation analysis of C2 translaminar screw placement assisted by a novel rapid prototyping drill template: a cadaveric study. *Eur Spine J*. 2013;22:2770–2776.
18. Lamartina C, Cecchinato R, Fekete Z, et al. Pedicle screw placement accuracy in thoracic and lumbar spinal surgery with a patient-matched targeting guide: a cadaveric study. *Eur Spine J*. 2015;24(suppl 7): 937–941.
19. Shin BJ, James AR, Njoku IU, et al. Pedicle screw navigation: a systematic review and meta-analysis of perforation risk for computer-navigated versus freehand insertion. *J Neurosurg Spine*. 2012;17:113–122.
20. Mizuno M, Kuraishi K, Umeda Y, et al. Midline lumbar fusion with cortical bone trajectory screw. *Neurol Med Chir (Tokyo)*. 2014;54: 716–721.
21. Hughes SP, Anderson FM. Infection in the operating room. *J Bone Joint Surg Br*. 1999;81:754–755.
22. Lim MR, Girardi FP, Yoon SC, et al. Accuracy of computerized frameless stereotactic image-guided pedicle screw placement into previously fused lumbar spines. *Spine (Phila Pa 1976)*. 2005;30:1793–1798.
23. Sagi HC, Manos R, Benz R, et al. Electromagnetic field-based image-guided spine surgery part one: results of a cadaveric study evaluating lumbar pedicle screw placement. *Spine (Phila Pa 1976)*. 2003;28: 2013–2018.
24. Balestrini C, Campo-Celaya T. With the advent of domestic 3-dimensional (3D) printers and their associated reduced cost, is it now time for every medical school to have their own 3D printer? *Med Teach*. 2016;38:312–313.