

# Concomitant herpes simplex virus colitis and hepatitis in a man with ulcerative colitis

## Case report and review of the literature

Varun K. Phadke, MD<sup>a,\*</sup>, Rachel J. Friedman-Moraco, MD<sup>a</sup>, Brian C. Quigley, MD<sup>b</sup>, Alton B. Farris, MD<sup>b</sup>, J. P. Norvell, MD<sup>c,d</sup>

### Abstract

**Background:** Herpesvirus infections often complicate the clinical course of patients with inflammatory bowel disease; however, invasive disease due to herpes simplex virus is distinctly uncommon.

**Methods:** We present a case of herpes simplex virus colitis and hepatitis, review all the previously published cases of herpes simplex virus colitis, and discuss common clinical features and outcomes. We also discuss the epidemiology, clinical manifestations, diagnosis, and management of herpes simplex virus infections, focusing specifically on patients with inflammatory bowel disease.

**Results:** A 43-year-old man with ulcerative colitis, previously controlled with an oral 5-aminosalicylic agent, developed symptoms of a colitis flare that did not respond to treatment with systemic corticosteroid therapy. One week later he developed orolabial ulcers and progressive hepatic dysfunction, with markedly elevated transaminases and coagulopathy. He underwent emergent total colectomy when imaging suggested bowel micro-perforation. Pathology from both the colon and liver was consistent with herpes simplex virus infection, and a viral culture of his orolabial lesions and a serum polymerase chain reaction assay also identified herpes simplex virus. He was treated with systemic antiviral therapy and made a complete recovery.

**Conclusions:** Disseminated herpes simplex virus infection with concomitant involvement of the colon and liver has been reported only 3 times in the published literature, and to our knowledge this is the first such case in a patient with inflammatory bowel disease. The risk of invasive herpes simplex virus infections increases with some, but not all immunomodulatory therapies. Optimal management of herpes simplex virus in patients with inflammatory bowel disease includes targeted prophylactic therapy for patients with evidence of latent infection, and timely initiation of antiviral therapy for those patients suspected to have invasive disease.

**Abbreviations:** ALT = alanine transaminase, AST = aspartate transaminase, CMV = cytomegalovirus, CT = computed tomography, ECCO = European Crohn's and Colitis Organisation, FDA = Food and Drug Administration, HIV/AIDS = human immunodeficiency virus/acquired immunodeficiency syndrome, HSV = herpes simplex virus, IBD = inflammatory bowel disease, IHC = immunohistochemistry, IL = interleukin, PCR = polymerase chain reaction, TNF = tumor necrosis factor, UC = ulcerative colitis.

**Keywords:** case report, Crohn's disease, herpes simplex virus, immunomodulatory therapy, inflammatory bowel disease, ulcerative colitis

## 1. Introduction

Herpesvirus infections frequently complicate the clinical course of patients with inflammatory bowel disease (IBD).<sup>[1,2]</sup> Immunosuppressive therapy increases the risk of herpesvirus reactivation and predisposes to more severe infections.<sup>[2]</sup> Whereas cytomegalovirus

(CMV) is a well-recognized cause of tissue-invasive disease in this population,<sup>[1]</sup> herpes simplex virus (HSV) has only rarely been implicated.<sup>[3-7]</sup> When HSV infections do occur they are usually limited to sites of local reactivation, for example, mucosal surfaces

Editor: Min Lu.

*Declaration:* The content of this review is solely the responsibility of the authors and does not necessarily represent the official views of the National Institute of Allergy and Infectious Diseases or the National Institutes of Health.

*Funding:* Varun K. Phadke is supported by the Emory Vaccinology Training Program under award number T32AI074492 from the National Institute of Allergy and Infectious Diseases.

*Authorship:* VKP wrote the initial draft and performed the review of the literature. VKP and RJF were the infectious diseases clinicians caring for this patient. BCQ and ABF provided images of the biopsy and operative specimens and were also the attending pathologists for this case. JPN was the attending hepatology clinician caring for this patient. All authors reviewed and edited the manuscript for important intellectual content.

The authors have no conflicts of interest to disclose.

<sup>a</sup> Division of Infectious Diseases, Emory University School of Medicine, <sup>b</sup> Department of Pathology and Laboratory Medicine, Emory University School of Medicine, Emory University Hospital, <sup>c</sup> Division of Digestive Diseases, Emory University School of Medicine, <sup>d</sup> Emory Transplant Center, Atlanta, GA.

\* Correspondence: Varun K. Phadke, 49 Jesse Hill Jr. Drive, Atlanta 30303, GA (e-mail: vphadke@emory.edu).

Copyright © 2016 the Author(s). Published by Wolters Kluwer Health, Inc. All rights reserved.

This is an open access article distributed under the terms of the Creative Commons Attribution-Non Commercial-No Derivatives License 4.0 (CCBY-NC-ND), where it is permissible to download and share the work provided it is properly cited. The work cannot be changed in any way or used commercially without permission from the journal.

Medicine (2016) 95:42(e5082)

Received: 2 June 2016 / Received in final form: 2 July 2016 / Accepted: 15 September 2016

<http://dx.doi.org/10.1097/MD.0000000000005082>

(such as the oropharynx, anogenital area, and eyes) and skin sites. Here we report the first case, to our knowledge, of a patient with IBD who developed disseminated HSV infection with concomitant colonic and hepatic involvement. We also review all of the previously reported cases of HSV colitis and hepatitis, as well as the published literature of HSV infections, in patients with IBD.

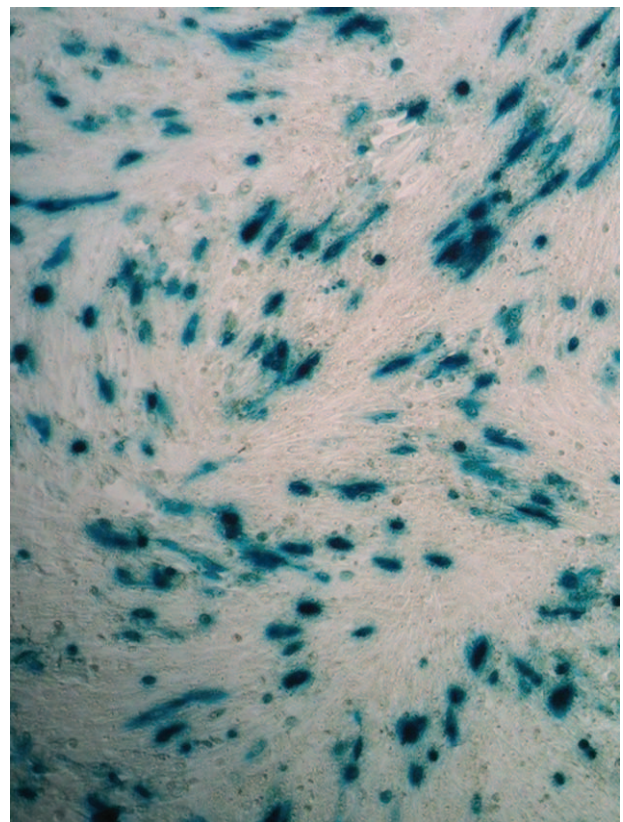
The patient provided informed consent for the use of clinical information and images for this case report.

## 2. Case report

A 43-year-old man with ulcerative colitis (UC) was transferred to our hospital for evaluation and management of refractory colitis symptoms and abnormal liver function tests. One year earlier he had been diagnosed with UC and started on maintenance therapy with oral balsalazide. He continued to have intermittent flares of his colitis which were well-controlled with short courses of systemic corticosteroids. After his last flare 6 months earlier, he was prescribed a trial of azathioprine, which he discontinued after a few weeks due to intolerance, followed by mesalamine suppositories. One month prior to admission he was asymptomatic.

Approximately 3 weeks prior to transfer he developed fatigue, decreased oral intake, diffuse crampy abdominal discomfort, and loose bloody stools, consistent with his prior UC flares. He was prescribed prednisone 40 mg daily, but his symptoms did not improve after 1 week of this therapy. He was admitted to his local hospital. Laboratory testing was unremarkable (Table 1) and stool evaluation for bacterial and parasitic pathogens was unrevealing. A flexible sigmoidoscopy demonstrated “severe ulcerative colitis” without pseudomembranes; biopsies were not performed. He was treated with intravenous methylprednisolone and discharged with prednisone 60 mg daily and a course of metronidazole—however, he was readmitted 1 week later for persistent symptoms. Laboratory testing on readmission was notable for: aspartate aminotransferase (AST), 98 U/L; alanine aminotransferase (ALT), 136 U/L; total bilirubin 1.6 mg/dL, and a prothrombin time of 15.7 seconds (international normalized ratio, INR, of 1.25). Computed tomography (CT) of the abdomen and pelvis demonstrated pan-colitis. He was started on intravenous corticosteroids and empiric broad-spectrum antibiotics. For persistent colitis symptoms, he also received a dose of golimumab 48 hours after admission.

Over the next 96 hours, his serum aminotransferase levels and prothrombin time continued to increase (Table 1). A serologic evaluation for viral causes of acute hepatitis was notable for a



**Figure 1.** Representative positive herpes simplex viral culture using the Enzyme Linked Virus Inducible System (ELVIS). A swab of the case patient’s oral ulcers grew herpes simplex virus (Photo courtesy of Dr. Lori Racsa (Department of Pathology, Emory University)).

positive CMV IgG and HSV-1 IgM; tests for hepatitis A and B and HSV-2 were negative. He subsequently underwent percutaneous liver biopsy, and then was transferred to our hospital for further management.

On arrival to our hospital, he was febrile to 39.6°C and in distributive shock. On physical examination, he had multiple small shallow ulcerations of the hard palate as well as diffuse abdominal tenderness to palpation. Laboratory testing was notable for pancytopenia and markedly elevated serum transaminases, with AST, 3072 U/L, and ALT, 3392 U/L (other results in Table 1). Blood cultures were obtained, swabs of his oral ulcers

**Table 1**

**Progression of laboratory values of case patient.**

Variable	Reference range, adults*	3 weeks before transfer	11 days before transfer	4 days before transfer	2 days before transfer	On transfer	Hospital day 2	Hospital day 10	4 months after discharge
White-cell count, per mm <sup>3</sup>	4200–9100	16,300	21,200	7300	10,600	3400	21,200	5600	6300
Hemoglobin, g/dL	12.9–16.1	14.3	12.9	12.9	9.2	6.6	7.5	7.0	14.9
Platelet count, per mm <sup>3</sup>	150,000–400,000	340,000	324,000	300,000	197,000	127,000	104,000	140,000	207,000
Creatinine, mg/dL	0.7–1.2	1.0	0.8	1.1	0.9	1.18	0.81	0.38	1.00
Aspartate aminotransferase, U/L	15–41	18	13	98	316	3072	3726	55	20
Alanine aminotransferase, U/L	<44	16	16	136	438	3392	2312	173	22
Alkaline phosphatase, U/L	32–91	73	50	62	57	77	122	156	63
Total bilirubin, mg/dL	0.3–1.2	1.0	0.8	1.6	0.8	0.9	1.7	1.6	1.1
Prothrombin time, seconds	9.4–12.5	—	—	15.7	—	16	19.5	12.8	10.6
International normalized ratio	—	—	—	1.25	—	1.52	1.85	1.22	1.01

g/dL = grams/deciliter, mg/dL = milligrams/deciliter, mm<sup>3</sup> = cubic millimeter, U/L = units/liter.  
Reference ranges used at Emory University Hospital.

were sent for viral culture, and serum polymerase chain reaction (PCR) assays for CMV and HSV were performed. A repeat CT of the abdomen and pelvis revealed diffuse colonic wall thickening and a micro-perforation in the distal sigmoid colon.

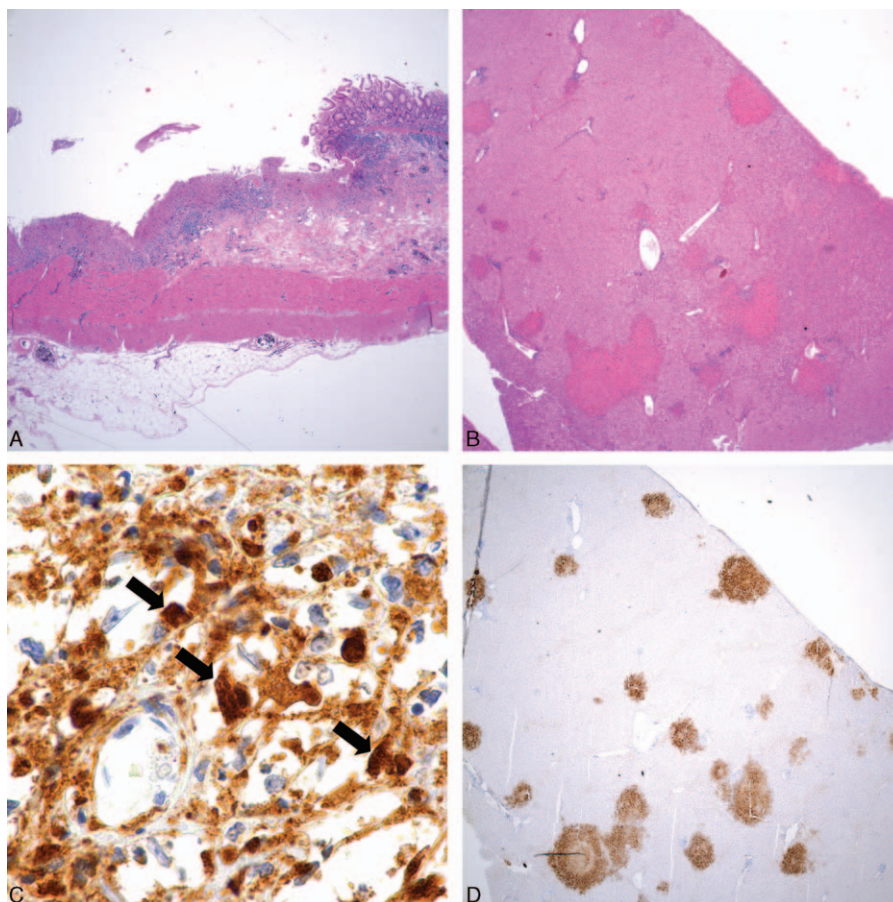
The patient received intravenous fluid boluses, transfusions of packed red cells, and empiric antimicrobial therapy with vancomycin, piperacillin/tazobactam, and intravenous ganciclovir. He underwent emergent total abdominal colectomy with end ileostomy as well as intraoperative liver biopsy. Blood cultures obtained on admission grew *Escherichia coli* and *Citrobacter amalonaticus*—his anti-bacterial therapy was changed to intravenous ertapenem. Viral culture of his oral ulcers grew herpes simplex virus (Fig. 1). A serum PCR assay was positive for HSV (cycle threshold value of 18.5, cutoff for positivity <39), but negative for CMV. Pathology slides sent from the referring hospital and intraoperative specimens from our hospital were reviewed. The colon had “chronic active colitis with ulceration” (Fig. 2A) and the liver had “patchy foci of nonzonal hepatocellular necrosis” (Fig. 2B). Histopathology and immunohistochemistry (IHC) of both the liver and colon were consistent with HSV infection (Fig. 2A–D); IHC stains for CMV and adenovirus were negative.

His antiviral therapy was changed to intravenous acyclovir for disseminated HSV infection. His steroids were tapered over a period of 1 month. At the time of discharge, 10 days after admission, his serum AST and ALT levels had decreased to 173 U/L and 55 U/L, respectively. He was discharged with oral valacyclovir 1000 mg 3 times daily to take for an additional 4 weeks, to be followed by indefinite suppressive therapy. Four months after discharge his serum transaminase levels had returned to normal. In the 1 year following discharge, he has remained clinically well with no evidence of relapse.

### 3. Discussion

#### 3.1. Epidemiology of HSV infections in IBD

Herpes simplex virus 1 and 2 infections are common, with an estimated seroprevalence of 50% and 15% respectively in the general US population.<sup>[8]</sup> Importantly, rates of infection vary between certain age, race, and socioeconomic groups<sup>[8]</sup>—since no seroepidemiologic studies of latent HSV infection have been conducted specifically in patients with IBD, the prevalence in this particular population is unknown. Nevertheless, data from single



**Figure 2.** (A) Herpes simplex colitis, colectomy specimen. Deep ulceration in the colon (left) with adjacent nonulcerated mucosa (right). Hematoxylin and eosin stain, 20× overall magnification. (B) Herpes simplex virus hepatitis, intraoperative liver biopsy 1 day after initiation of antiviral therapy. Patches of nonzonal hepatocyte necrosis with minimal inflammation. Hematoxylin and eosin stain, 20× overall magnification. (C) Herpes simplex virus colitis. An immunohistochemical stain for herpes simplex virus (types 1 and 2, combined stain) darkly stains these inclusion-like structures (some denoted with arrows). Despite the apparently high background staining, note absence of staining within macrophage nuclei. No staining whatsoever was observed in the nonulcerated colonic mucosa. Immunohistochemical stain for herpes simplex virus, 1000× overall magnification. (D) Herpes simplex virus hepatitis. The patches of hepatocyte necrosis are highlighted strongly with an immunohistochemical stain for herpes simplex virus (types 1 and 2, combined stain). 20× overall magnification. Photo courtesy of Dr. Brian Quigley (Department of Pathology and Laboratory Medicine, Emory University).

center analyses and meta-analyses of multicenter trials indicate that HSV infections are fairly common among patients with IBD,<sup>[9–12]</sup> mirroring trends in the general population. In fact, the actual incidence is likely to be underestimated by these studies due to underreporting and inadequate duration of follow-up.

Use of immunomodulatory agents, particularly systemic corticosteroids and antimetabolites (e.g., azathioprine, 6-mercaptopurine, and methotrexate), has been associated with an elevated risk of localized mucocutaneous HSV reactivation,<sup>[9,10]</sup> similar to herpes zoster.<sup>[2]</sup> Invasive HSV infections have also been reported in patients taking azathioprine<sup>[5–7,13]</sup> and methotrexate<sup>[14]</sup> for IBD. Post-marketing surveillance studies of IBD patients receiving newer immunomodulatory therapies (e.g., biologic therapies) less frequently evaluate the specific risk of HSV infections, as compared to herpes zoster, mycobacterial, and fungal infections.<sup>[11,15]</sup> As a result, the effect of biologic agents, such as tumor necrosis factor (TNF)-alpha antagonists, anti-integrin antibodies, or interleukin (IL)-12/23 receptor antagonists, on the incidence of HSV infections—both localized and invasive—among IBD patients is less clear. However, given the paucity of reported cases, the risk is likely lower than with antimetabolite therapy (Table 4).<sup>[11,15]</sup> Indeed, although there have been small case series of tissue-invasive HSV infections in patients receiving TNF-alpha antagonists and anti-integrin antibodies,<sup>[16,17]</sup> none have included patients with IBD.

Patient-specific immunologic factors can also influence the course of infections due to herpes simplex viruses. These may include individual-level variations in pathogen recognition receptors, major histocompatibility complex proteins, naturally occurring anti-viral peptides, and effector cell function.<sup>[18–21]</sup> Although IBD has been associated with a variety of genetic polymorphisms linked to a dysregulated immune response to enteric microbes, none of these genetic factors have been investigated specifically for their role in immunity to herpes simplex viruses.

### 3.2. Clinical manifestations of HSV infections in IBD

The most common clinical manifestations of HSV in IBD are similar to those in otherwise healthy individuals. Overall, mucocutaneous (i.e., oropharynx and anogenital areas) disease predominates and is generally benign; however, progression to more invasive disease or widespread cutaneous dissemination has occasionally been described.<sup>[13,22,23]</sup> Importantly, oropharyngeal and anogenital lesions due to HSV can mimic those seen with Crohn's disease<sup>[24]</sup>; thus, it is important to exclude active HSV infection before initiating or escalating immunomodulatory therapy.<sup>[25]</sup> Herpes simplex viruses can also occasionally cause disseminated disease with end-organ involvement; however, there have been only a few reports of visceral HSV disease among patients with IBD. The gastrointestinal tract is a frequent site of HSV involvement in immunocompromised patients,<sup>[26]</sup> with the esophagus and rectum being the most frequently affected organs, followed by isolated reports of stomach and small bowel disease. Interestingly, the vast majority of these cases have been in patients with HIV/AIDS or among solid organ and bone marrow transplant recipients, and not those with IBD—we found only 1 report of HSV duodenitis in a patient with Crohn's disease.<sup>[27]</sup> Involvement of other organs in IBD patients is even less common—to date only 2 cases of HSV meningoencephalitis<sup>[6,7]</sup> and a single case of HSV pneumonia/pneumonitis<sup>[5]</sup> have been reported, all in the setting of corticosteroid or anti-metabolite therapy.

Colitis due to HSV was first described in 1982<sup>[28]</sup> and since then only 16 cases have been reported in the literature.<sup>[4,28–42]</sup> Almost all of the cases occurred in immunocompromised hosts, nearly a third (n=5) of whom were receiving corticosteroid therapy for IBD (Table 2).<sup>[4,33,39,41,42]</sup> In contrast, CMV is routinely implicated as an intestinal pathogen in patients with IBD. Indeed, among patients with IBD presenting with acute colitis, reported prevalence rates of CMV infection have ranged from 21% to 34%, and in those with steroid-refractory disease it can be as high 36%.<sup>[1]</sup> As is the case for CMV, HSV colitis in this population often mimics the underlying disease, presenting as fever, abdominal pain and diarrhea, rectal bleeding,<sup>[4,39,42]</sup> or even paralytic ileus,<sup>[41]</sup> generally in the absence of suggestive mucocutaneous involvement. Endoscopic findings may be nonspecific and can include edema, erythema sometimes with petechiae, and well-demarcated ulcers of variable size and depth with or without purulent exudate, often separated by normal-appearing mucosa.<sup>[41,42]</sup>

The relative paucity of cases of HSV colitis as compared to CMV colitis (not only in the context of IBD) suggests a fundamental difference in the pathophysiology of end-organ involvement due to these viruses. Differences in the site of viral latency (e.g. neural ganglion cells for HSV vs leukocytes and endothelial cells for CMV) may account for the relative infrequency of colonic involvement due to HSV as compared to CMV. Alternatively, these viruses may differ in their tropism for colonic tissue. In studies that have exploited the oncolytic properties of herpes simplex viruses, investigators have shown diminished binding of HSV-1 to normal colonic tissue as compared to cancerous lesions.<sup>[43]</sup> Similarly, although HSV-1 has been used successfully in an ex vivo colonic explant model of virally induced immune activation in Crohn's disease,<sup>[44]</sup> it is rarely detected in the large intestines of patients with IBD.<sup>[45]</sup>

Hepatitis due to HSV is also uncommon and almost exclusively occurs in the context of impaired cell-mediated immunity.<sup>[46]</sup> We found only 8 previous cases of HSV hepatitis in patients with IBD, all of whom were receiving systemic corticosteroids with or without anti-metabolite therapy (Table 3).<sup>[3,47–53]</sup> Similar to other patient populations, HSV hepatitis in patients with IBD tends to progress rapidly and is associated with a high case fatality rate, particularly if the diagnosis is not considered early enough in the disease course to allow for timely initiation of appropriate antiviral therapy.<sup>[51]</sup>

We identified only 3 prior reports<sup>[31,37,38]</sup> describing simultaneous colonic and hepatic involvement of disseminated herpes simplex virus infection (one of which did not report pathologic confirmation of hepatic involvement),<sup>[37]</sup> none of which involved a patient with IBD (Table 2). One of the cases was a neonate presumably with perinatal acquisition of HSV,<sup>[37]</sup> the second case was a patient who had received re-induction chemotherapy for acute lymphoblastic leukemia and developed reactivation HSV infection (prior history of herpes labialis) with multiorgan involvement,<sup>[38]</sup> and the third case was a liver transplant recipient who developed disseminated HSV with liver, colon, lung, and laryngeal involvement.<sup>[31]</sup>

### 3.3. Diagnosis of HSV infections in IBD

The gold-standard diagnostic test for tissue-invasive HSV disease, including colitis and hepatitis, is histopathologic evidence of herpes simplex virus infection, which can include characteristic eosinophilic intracytoplasmic inclusions (Fig. 2A and B) as well as positive immunohistochemical staining using labeled HSV-1- and

**Table 2****Published cases of herpes simplex virus (HSV) colitis in the English-language literature. Patients with inflammatory bowel disease (n = 4) in bold.**

Reference/year	Age/sex	Risk factor	HSV-1/ HSV-2	Other organ involvement	Diagnostic test	Treatment	Outcome
Boulton et al (1982)	57/F	Chemotherapy for Hodgkin's disease	HSV-2	None	Autopsy (histopathology, IHC) serology	Supportive	Died
Guttman et al (1983)	36/M	Homosexual	NS	Perianal ulcers	Histopathology, viral culture (from rectum and perianal ulcer)	Supportive	Survived
Adler et al (1987)	53/M	Kidney transplant recipient	HSV-1	Perineal ulcers	Histopathology, viral culture (throat), viral antigen (stool), serology	Acyclovir	Survived
Singh et al (1988)	NS	Liver transplant recipient	NS	Liver, lungs, larynx	Autopsy (otherwise NS)	NS	Died
Colemont et al (1990)	78/F	Surgical therapy for colon cancer	HSV-1	None	IHC, viral culture (colon biopsy), serology	Acyclovir	Survived
Rathgaber et al (1993)	47/M	Kidney transplant recipient	HSV-1	Oral ulcers	Histopathology, viral culture (colon biopsy and urine)	Acyclovir	Survived
el-Serag et al (1996)	35/F	CD, steroid therapy	NS	None	Histopathology, IHC	Ileocelectomy	Survived
Naik et al (1996)	45/M	Allogenic HSCT recipient for relapsed lymphoma	HSV-2	Penile ulcer	Viral culture (cecal biopsy and penile ulcer)	Acyclovir	Died
Delis et al (2001)	2/M	Small bowel transplant recipient	HSV-2	None	Viral culture (colon biopsy)	Acyclovir	Survived
Daley et al (2002)	4 days/F	Possible perinatal transmission	HSV-1	Scalp lesion, liver, possible lung and colon	Histopathology, PCR (colon biopsy), viral culture (scalp lesion and nasopharyngeal aspirate)	Acyclovir, sigmoid colectomy	Survived
Herget et al (2005)	22/F	Chemotherapy for acute leukemia	HSV-1	Skin, liver, lung, esophagus, small bowel, colon	Autopsy (histopathology, IHC) PCR (skin, lung, and colon)	Acyclovir	Died
Blaszkyk et al (2006)	31/F	UC, steroid therapy	NS	None	IHC, EM	Proctocolectomy	Survived
Dray et al (2006)	69/F	CVID	HSV-1	None	Viral culture (colon biopsy), serology	Valacyclovir	Survived
Schunter et al (2007)	35/F	UC, steroid therapy, tacrolimus, and azathioprine	HSV-2	None	Histopathology, IHC, PCR (colon), serology	Acyclovir, subtotal colectomy	Survived
Smith et al (2010)	50/M	CD, steroid therapy, also on interferon therapy for HDV	HSV-2	None	IHC, viral culture (colon)	Antiviral therapy NS	Died

CD = Crohn's disease, EM = electron microscopy, F = female, IHC = immunohistochemistry, M = male, NS = not specified, PCR = polymerase chain reaction, UC = ulcerative colitis.

HSV-2-specific monoclonal antibodies (Fig. 2C and D). In practice, particularly given the challenges of obtaining pathologic specimens from critically ill patients, a combination of noninvasive diagnostic tests is often used to support a clinical diagnosis of

HSV end-organ disease and the decision to begin antiviral therapy.

A variety of noninvasive tests are available to aid in the diagnosis of tissue-invasive HSV infections.<sup>[54]</sup> Typically the most

**Table 3****Published cases of herpes simplex virus (HSV) hepatitis in patients with inflammatory bowel disease (IBD) in the English-language literature.**

Reference/year	Age/sex	Form of IBD	Immunosuppressive regimen	HSV-1 or HSV-2	Other organ involvement	Diagnostic test	Treatment	Outcome
Shlien (1988)	16/F	UC	Steroids	HSV-1	No	Autopsy (IHC, EM)	NS	Died
Wolfsen et al (1993)	23/F	CD	Steroids	HSV-2	Yes (oral "aphthous" ulcers, genital ulcers)	Autopsy (histopathology, IHC)	NS	Died
Seksik et al (1999)	37/M	UC	Steroids	HSV-1	No	Autopsy (histopathology, IHC), tissue and blood viral culture, serology	Acyclovir and foscarnet	Died
Bissig et al (2003)	22/M	CD*	Steroids, tacrolimus, azathioprine	HSV-1	Yes (skin, oral, genital lesions)	Liver biopsy (histopathology, IHC), viral culture (lesions), serology	Acyclovir	Survived
Norvell et al (2007)	29/F	UC	Steroids	NS	No	Liver biopsy	Acyclovir	Survived
Levitsky et al (2008)	28/F	UC	Steroids	HSV-1	No	Autopsy (histopathology)	Acyclovir	Died
Haag et al (2015)	19/F	CD	Steroids, azathioprine, adalimumab	HSV-1	Yes (skin lesions)	Liver biopsy (IHC), viral PCR (lesions and blood)	Acyclovir	Survived

CD = Crohn's disease, EM = electron microscopy, F = female, IHC = immunohistochemistry, M = male, NS = not specified, UC = ulcerative colitis.

\* This patient had also received a liver transplant.

**Table 4****Immunomodulatory therapies for inflammatory bowel disease (IBD) and risk for infections, including invasive herpes simplex virus (HSV) disease.**

Drug class	Examples	Characteristic infectious complication (s)	Reported invasive infections due to HSV
5-Aminosalicylates	Sulfasalazine, mesalamine, balsalazide, olsalazine	None	No
Topical (nonsystemic) glucocorticoids	Budesonide	Oropharyngeal candidiasis	No
Systemic glucocorticoids	Prednisone, methylprednisolone	Viral (herpesviruses, hepatitis B, etc.), bacterial and fungal infections	Yes
Antimetabolites	Azathioprine, 6-mercaptopurine, methotrexate	Viral (herpesviruses, hepatitis B) and bacterial infections	Yes
Calcineurin inhibitors	Cyclosporine, tacrolimus	Viral (herpesviruses), bacterial and fungal infections	Yes
Tumor necrosis factor- $\alpha$ antagonists	Etanercept, infliximab, adalimumab, certolizumab pegol, golimumab	Mycobacterial and fungal infections	Yes*
Anti-integrin antibodies	Natalizumab, vedolizumab	Progressive multifocal leukoencephalopathy (JC virus infection)	Yes <sup>17†</sup>
Interleukin-12/23 receptor antagonist	Ustekinumab	Upper respiratory infections (nasopharyngitis), herpes zoster	No

HSV = herpes simplex virus, IBD = inflammatory bowel disease.

\* Only with concomitant receipt of systemic glucocorticoids and/or antimetabolite therapy.

† Data not from patients with IBD.

readily available is HSV type-specific serology; however, given high background seroprevalence rates, a positive result is typically not useful for the diagnosis of suspected active disease,<sup>[55]</sup> and a negative result does not exclude the possibility of a primary infection. As in our case, assays that detect IgM antibodies may suggest the diagnosis of early primary infection, especially if IgG antibodies are absent. Unfortunately, the sensitivity and specificity of these assays are limited by the fact that HSV IgM antibodies are not always detected, they can persist for months after primary infection, and they often reappear in the setting of reactivation.<sup>[54]</sup>

Direct detection of HSV in non-invasively obtained specimens (e.g., scrapings of mucocutaneous lesions, respiratory or gastrointestinal tract secretions, etc.) using culture, direct immunofluorescence, or PCR-based assays can also support the diagnosis of end-organ involvement in the appropriate clinical setting. For instance, the appearance of characteristic herpetic mucocutaneous lesions in the context of mildly abnormal serum liver enzyme levels—transaminases and lactate dehydrogenase in particular—may herald impending fulminant HSV hepatitis and should prompt the initiation of timely antiviral therapy.<sup>[50]</sup> However, concomitant skin findings are present in fewer than one-third of patients with HSV hepatitis,<sup>[46,51,53]</sup> including those with IBD. Similarly, less than half ( $n=6$ ) of all the previously reported cases of HSV colitis had suggestive mucocutaneous lesions at the time of presentation. More importantly, recovery of virus in the absence of lesions should be interpreted with caution since HSV reactivation and shedding is not uncommon in the context of critical illness and may or may not be indicative of active tissue-invasive HSV disease.<sup>[56]</sup>

As illustrated by our case, visceral or disseminated HSV infections (particularly those with hepatic involvement) are frequently accompanied by some degree of HSV viremia,<sup>[52,57]</sup> which can be detected using PCR assays of whole blood using HSV specific primers. Notably, in the United States none of these assays is currently approved by the Food and Drug Administration (FDA) for this application.<sup>[54,58]</sup> Concomitant viremia was described in only one of the previously reported cases of HSV hepatitis in patients with IBD,<sup>[53]</sup> and none of the cases of HSV colitis; however, HSV viremia has been used to predict hepatic involvement in other patient populations.<sup>[52,57–60]</sup> Importantly,

even the presence of HSV viremia is generally not sufficient to make a definitive diagnosis of visceral HSV disease because it too can be frequently detected in patients with non-HSV-related critical illness.<sup>[56,61]</sup> Although quantification of viremia may be useful for differentiating between inconsequential reactivation and end-organ disease in this setting,<sup>[57]</sup> this has not been studied in a prospective fashion.

### 3.4. Treatment and prevention of invasive HSV infections in IBD

There have been no prospective comparative studies of antiviral therapy for visceral or disseminated HSV infection. Acyclovir is the drug of choice for HSV infections and earlier treatment has been associated with improved outcomes for both HSV hepatitis and encephalitis.<sup>[51,62,63]</sup> Primary mucocutaneous infections (i.e., occurring in a patient known to be HSV seronegative) in patients on immunomodulatory therapy for IBD should be treated promptly with antiviral therapy as this may prevent secondary complications.<sup>[25]</sup> For tissue-invasive HSV infections (e.g., colitis, hepatitis, meningoencephalitis, pneumonia, etc.), most experts would recommend a minimum of 2 to 3 weeks of parenteral antiviral therapy. In the case of HSV hepatitis, a highly morbid disease with a high case fatality rate and no well-validated marker of disease activity, the duration may be significantly longer depending on the patient's clinical course. After completion of a course of systemic antiviral therapy some experts advocate indefinite suppressive therapy with prophylactic doses of oral antiviral agents, particularly if further immunosuppressive therapy is anticipated in the future (i.e., post-transplantation), although this may lead to the subsequent emergence of acyclovir resistance.<sup>[64]</sup> Our patient received a total of 6 weeks of antiviral therapy (intravenous acyclovir followed by oral valacyclovir) with a plan to continue lifelong suppressive therapy to prevent potential recurrence. Interestingly, four of the previously reported cases of HSV colitis were cured without specific antiviral therapy, though most of those patients did not have significant immunologic defects and ultimately required surgical resection of the diseased tissue before achieving symptom resolution.

In addition to initiating antiviral therapy, most experts as well as consensus guidelines from the European Crohn's and Colitis Organization (ECCO) also recommend interruption of immunomodulatory therapy for IBD in the context of severe HSV infections.<sup>[25,65]</sup> For more typical mucocutaneous infections immunomodulatory therapy may be continued, though there is a small risk for widespread dissemination and invasive disease.<sup>[13,22,23]</sup> Patients with suspected hepatic involvement—particularly those with high-risk features, such as age >40 years, immunocompromised status, or evidence of fulminant hepatic failure (encephalopathy, coagulopathy, or thrombocytopenia)—should also be referred promptly for consideration for liver transplantation, as this may be life-saving.<sup>[51]</sup>

Current guidelines make no formal recommendations regarding baseline serologic testing of patients with IBD for HSV or for routine antiviral prophylaxis, even when initiating immunomodulatory therapy.<sup>[25,66]</sup> Given the observed increased rates of reactivation HSV disease—albeit mild—in patients receiving certain classes of immunomodulatory drugs, it has been suggested that patients with a previous history of frequent HSV outbreaks who are being prescribed immunomodulatory medications also receive suppressive antiviral therapy,<sup>[65,67,68]</sup> though there are limited clinical data to support that recommendation. The likelihood of developing disseminated infection due to specific immunomodulatory agents has not been prospectively evaluated; however, based on post-licensure studies in other populations commonly prescribed similar therapies, the risk is likely to be greater with certain drug classes (Table 4). Consequently, it may be reasonable to offer secondary prophylaxis to HSV seropositive individuals or those with a history of recurrent localized mucocutaneous HSV infections who are going to receive prolonged courses of systemic corticosteroids, anti-metabolite therapy, or a calcineurin inhibitor. Patients with a previous history of disseminated or tissue-invasive HSV disease may be offered lifelong suppressive therapy/secondary prophylaxis, similar to the case patient, especially if any underlying or iatrogenic immunologic defect(s) cannot be reversed. However, the true risk of recurrence for tissue-invasive HSV disease has not been well established, secondary antiviral prophylaxis has variable efficacy depending on the site of disease, and ongoing antiviral therapy may lead to the development of drug resistance in immunocompromised patients.<sup>[69]</sup>

#### 4. Conclusion

Herpes simplex virus infections are common in patients with inflammatory bowel disease, but systemic dissemination and end-organ involvement have been infrequently reported. Patients with IBD are often at a higher risk for reactivation of HSV and tissue-invasive disease due to immunomodulatory therapy. Colitis and hepatitis due to HSV are particularly rare in this population, but HSV colitis should be considered in the differential diagnosis of refractory colitis symptoms, particularly if CMV disease has already been excluded. Treatment of suspected disseminated HSV infections should include prompt initiation of systemic antiviral therapy, with routine involvement of organ-specific and infectious disease specialists. Strategies for prevention of these infections include symptom-based and serologic screening of patients that are going to receive immunomodulatory therapy, especially with systemic corticosteroids or antimetabolites, with consideration of prophylactic antiviral therapy in those with a history of recurrent or complicated HSV infections.

#### References

- [1] Kandiel A, Lashner B. Cytomegalovirus colitis complicating inflammatory bowel disease. *Am J Gastroenterol* 2006;101:2857–65.
- [2] Long MD, Martin C, Sandler RS, et al. Increased risk of herpes zoster among 108 604 patients with inflammatory bowel disease. *Alimentary Pharmacol Ther* 2013;37:420–9.
- [3] Shlien RD, Meyers S, Lee JA, et al. Fulminant herpes simplex hepatitis in a patient with ulcerative colitis. *Gut* 1988;29:257–61.
- [4] el-Serag HB, Zwas FR, Cirillo NW, et al. Fulminant herpes colitis in a patient with Crohn's disease. *J Clin Gastroenterol* 1996;22:220–3.
- [5] Francois-Dufresne A, Garbino J, Ricou B, et al. ARDS caused by herpes simplex virus pneumonia in a patient with Crohn's disease: a case report. *Intensive Care Med* 1997;23:345–7.
- [6] Alimohamadi SM, Malekzadeh R, Mirmadjless SH, et al. Herpes simplex virus encephalitis during immunosuppressive treatment of ulcerative colitis. *MedGenMed* 2004;6:7.
- [7] Robineau O, Enrico J, Lemaire X, et al. Herpes simplex virus meningoencephalitis in a patient with Crohn's disease on azathioprine therapy. *Am J Gastroenterol* 2010;105:240–1.
- [8] Bradley H, Markowitz LE, Gibson T, et al. Seroprevalence of herpes simplex virus types 1 and 2—United States, 1999–2010. *J Infect Dis* 2014;209:325–33.
- [9] Toruner M, Loftus EV Jr, Harmsen WS, et al. Risk factors for opportunistic infections in patients with inflammatory bowel disease. *Gastroenterology* 2008;134:929–36.
- [10] Seksik P, Cosnes J, Sokol H, et al. Incidence of benign upper respiratory tract infections, HSV and HPV cutaneous infections in inflammatory bowel disease patients treated with azathioprine. *Aliment Pharmacol Ther* 2009;29:1106–13.
- [11] Marebian J, Arrighi HM, Hass S, et al. Adverse events associated with common therapy regimens for moderate-to-severe Crohn's disease. *Am J Gastroenterol* 2009;104:2524–33.
- [12] Naganuma M, Kunisaki R, Yoshimura N, et al. A prospective analysis of the incidence of and risk factors for opportunistic infections in patients with inflammatory bowel disease. *J Gastroenterol* 2013;48:595–600.
- [13] Santos-Antunes J, Abreu C, Magro F, et al. Disseminated cutaneous herpes simplex infection in a patient with Crohn's disease under azathioprine and steroids: first case report and literature review. *J Crohn's Colitis* 2014;8:326–30.
- [14] Desalermos AP, Frank S, Farraye FA. Recurrent Bell's palsy in a patient with Crohn's disease on methotrexate. *J Clin Gastroenterol* 2014;48:651–2.
- [15] Ford AC, Peyrin-Biroulet L. Opportunistic infections with anti-tumor necrosis factor-alpha therapy in inflammatory bowel disease: meta-analysis of randomized controlled trials. *Am J Gastroenterol* 2013;108:1268–76.
- [16] Bradford RD, Pettit AC, Wright PW, et al. Herpes simplex encephalitis during treatment with tumor necrosis factor-alpha inhibitors. *Clin Infect Dis* 2009;49:924–7.
- [17] Fine AJ, Sorbello A, Kortepeter C, et al. Central nervous system herpes simplex and varicella zoster virus infections in natalizumab-treated patients. *Clinical Infect Dis* 2013;57:849–52.
- [18] Yang CA, Raftery MJ, Hamann L, et al. Association of TLR3-hyporesponsiveness and functional TLR3 L412F polymorphism with recurrent herpes labialis. *Hum Immunol* 2012;73:844–51.
- [19] Moraru M, Cisneros E, Gomez-Lozano N, et al. Host genetic factors in susceptibility to herpes simplex type 1 virus infection: contribution of polymorphic genes at the interface of innate and adaptive immunity. *J Immunol* 2012;188:4412–20.
- [20] Griffiths SJ, Koegl M, Boutell C, et al. A systematic analysis of host factors reveals a Med23-interferon-lambda regulatory axis against herpes simplex virus type 1 replication. *PLoS Pathog* 2013;9:e1003514.
- [21] Moraru M, Black LE, Muntasell A, et al. NK cell and Ig interplay in defense against herpes simplex virus type 1: epistatic interaction of CD16A and IgG1 allotypes of variable affinities modulates antibody-dependent cellular cytotoxicity and susceptibility to clinical reactivation. *J Immunol* 2015;195:1676–84.
- [22] Sykora J, Varvarovska J, Stozicky F, et al. Adolescent herpes simplex viral infection related Ludwig's angina in ulcerative colitis. *J Pediatr Gastroenterol Nutr* 2004;38:221–3.
- [23] Sciaudone G, Pellino G, Guadagni I, et al. Education and imaging: gastrointestinal: herpes simplex virus-associated erythema multiforme (HAEM) during infliximab treatment for ulcerative colitis. *J Gastroenterol Hepatol* 2011;26:610.
- [24] Hoentjen F, Rubin DT. Infectious proctitis: when to suspect it is not inflammatory bowel disease. *Dig Dis Sci* 2012;57:269–73.

- [25] Rahier JF, Magro F, Abreu C, et al. Second European evidence-based consensus on the prevention, diagnosis and management of opportunistic infections in inflammatory bowel disease. *J Crohn's Colitis* 2014;8:443–68.
- [26] Buss DH, Scharj M. Herpesvirus infection of the esophagus and other visceral organs in adults. Incidence and clinical significance. *Am J Med* 1979;66:457–62.
- [27] Lee BH, Um WH, Jeon SR, et al. Herpes simplex virus duodenitis accompanying Crohn's disease. *Kor J Gastroenterol* 2013;62:292–5.
- [28] Boulton AJ, Slater DN, Hancock BW. Herpesvirus colitis: a new cause of diarrhoea in a patient with Hodgkin's disease. *Gut* 1982;23:247–9.
- [29] Guttman D, Raymond A, Gelb A, et al. Virus-associated colitis in homosexual men: two case reports. *Am J Gastroenterol* 1983;78:167–9.
- [30] Adler M, Goldman M, Liesnard C, et al. Diffuse herpes simplex virus colitis in a kidney transplant recipient successfully treated with acyclovir. *Transplantation* 1987;43:919–21.
- [31] Singh N, Dummer JS, Kusne S, et al. Impact of OKT3 therapy on cytomegalovirus and herpes simplex virus infections after liver transplantation. *Transplant Proc* 1988;20(1 suppl 1):661–3.
- [32] Colemont LJ, Pen JH, Pelckmans PA, et al. Herpes simplex virus type 1 colitis: an unusual cause of diarrhea. *Am J Gastroenterol* 1990;85:1182–5.
- [33] Ruther U, Nunnensiek C, Muller HA, et al. Herpes simplex-associated exacerbation of Crohn's disease. Successful treatment with acyclovir. *Deutsche Medizinische Wochenschrift* 1992;117:46–50.
- [34] Rathgaber SW, Rex DK. Colonoscopy and endoscopic therapy of hemorrhage from viral colitis. *Gastrointest Endosc* 1993;39:737–8.
- [35] Naik HR, Chandrasekar PH. Herpes simplex virus (HSV) colitis in a bone marrow transplant recipient. *Bone marrow Transplant* 1996;17:285–6.
- [36] Delis S, Kato T, Ruiz P, et al. Herpes simplex colitis in a child with combined liver and small bowel transplant. *Pediatr Transplant* 2001;5:374–7.
- [37] Daley AJ, Craven P, Holland AJ, et al. Herpes simplex virus colitis in a neonate. *Pediatr Infect Dis J* 2002;21:887–8.
- [38] Herget GW, Riede UN, Schmitt-Graff A, et al. Generalized herpes simplex virus infection in an immunocompromised patient—report of a case and review of the literature. *Pathol Res Pract* 2005;201:123–9.
- [39] Blaszyk H, Hyman NH, Cooper K. Herpes simplex virus colitis in ulcerative colitis, simulating malignancy. *Histopathology* 2006;49:316–8.
- [40] Dray X, Treton X, Mazon MC, et al. Herpes simplex virus type 1 colitis in a patient with common variable immunodeficiency syndrome. *Eur J Gastroenterol Hepatol* 2006;18:541–4.
- [41] Schunter MO, Walles T, Fritz P, et al. Herpes simplex virus colitis complicating ulcerative colitis: a case report and brief review on superinfections. *J Crohn's Colitis* 2007;1:41–6.
- [42] Smith JO, Sterling RK, Mills AS, et al. Herpes simplex virus colitis in a patient with Crohn's disease and hepatitis B and D cirrhosis. *Gastroenterol Hepatol* 2010;6:120–2.
- [43] Kolodkin-Gal D, Zamir G, Edden Y, et al. Herpes simplex virus type 1 preferentially targets human colon carcinoma: role of extracellular matrix. *J Virol* 2008;82:999–1010.
- [44] Silva MA, Menezes J, Dionne S, et al. Herpes simplex virus-1 infection of colonic explants as a model of viral-induced activation of Crohn's disease. *J Crohn's Colitis* 2012;6:454–63.
- [45] Wakefield AJ, Fox JD, Sawyerr AM, et al. Detection of herpesvirus DNA in the large intestine of patients with ulcerative colitis and Crohn's disease using the nested polymerase chain reaction. *J Med Virol* 1992;38:183–90.
- [46] Kaufman B, Gandhi SA, Louie E, et al. Herpes simplex virus hepatitis: case report and review. *Clin Infect Dis* 1997;24:334–8.
- [47] Wolfsen HC, Bolen JW, Bowen JL, et al. Fulminant herpes hepatitis mimicking hepatic abscesses. *J Clin Gastroenterol* 1993;16:61–4.
- [48] Seksik P, Gozlan J, Guitton C, et al. Fatal herpetic hepatitis in adult following short corticotherapy: a case report. *Intensive Care Med* 1999;25:415–7.
- [49] Rigau V, Comperat E, Bouillout JL, et al. Fulminant herpes hepatitis in a young adult with hemorrhagic colitis. *Gastroenterologie Clinique et Biologique* 2003;27:350–1.
- [50] Bissig KD, Zimmermann A, Bernasch D, et al. Herpes simplex virus hepatitis 4 years after liver transplantation. *J Gastroenterol* 2003;38:1005–8.
- [51] Norvell JP, Blei AT, Jovanovic BD, et al. Herpes simplex virus hepatitis: an analysis of the published literature and institutional cases. *Liver Transpl* 2007;13:1428–34.
- [52] Levitsky J, Duddempudi AT, Lakeman FD, et al. Detection and diagnosis of herpes simplex virus infection in adults with acute liver failure. *Liver Transpl* 2008;14:1498–504.
- [53] Haag LM, Hofmann J, Kredel LI, et al. Herpes simplex virus sepsis in a young woman with Crohn's disease. *J Crohn's Colitis* 2015;9:1169–73.
- [54] Anderson NW, Buchan BW, Ledebner NA. Light microscopy, culture, molecular, and serologic methods for detection of herpes simplex virus. *J Clin Microbiol* 2014;52:2–8.
- [55] Pinna AD, Rakela J, Demetris AJ, et al. Five cases of fulminant hepatitis due to herpes simplex virus in adults. *Dig Dis Sci* 2002;47:750–4.
- [56] Lepiller Q, Sueur C, Solis M, et al. Clinical relevance of herpes simplex virus viremia in Intensive Care Unit patients. *J Infect* 2015;71:93–100.
- [57] Beersma MF, Verjans GM, Metselaar HJ, et al. Quantification of viral DNA and liver enzymes in plasma improves early diagnosis and management of herpes simplex virus hepatitis. *J Viral Hepat* 2011;18:e160–166.
- [58] Berrington WR, Jerome KR, Cook L, et al. Clinical correlates of herpes simplex virus viremia among hospitalized adults. *Clin Infect Dis* 2009;49:1295–301.
- [59] Nienaber JH, McNamara DR, Banerjee R, et al. Fulminant gestational hepatitis due to primary herpes simplex type 2 infection: use of serum HSV polymerase chain reaction for noninvasive diagnosis. *Diagn Microbiol Infect Dis* 2012;72:181–4.
- [60] Ambrosioni J, Kaiser L, Giostra E, et al. Herpes simplex virus load to monitor antiviral treatment after liver transplantation for acute herpetic hepatitis. *Antiviral Ther* 2012;17:401–4.
- [61] Walton AH, Muenzer JT, Rasche D, et al. Reactivation of multiple viruses in patients with sepsis. *PLoS One* 2014;9:e98819.
- [62] Whitley RJ, Alford CA, Hirsch MS, et al. Vidarabine versus acyclovir therapy in herpes simplex encephalitis. *N Engl J Med* 1986;314:144–9.
- [63] Raschilas F, Wolff M, Delatour F, et al. Outcome of and prognostic factors for herpes simplex encephalitis in adult patients: results of a multicenter study. *Clin Infect Dis* 2002;35:254–60.
- [64] Longerich T, Eisenbach C, Penzel R, et al. Recurrent herpes simplex virus hepatitis after liver retransplantation despite acyclovir therapy. *Liver Transpl* 2005;11:1289–94.
- [65] Viget N, Vernier-Massouille G, Salmon-Ceron D, et al. Opportunistic infections in patients with inflammatory bowel disease: prevention and diagnosis. *Gut* 2008;57:549–58.
- [66] D'Haens GR, Panaccione R, Higgins PD, et al. The London Position Statement of the World Congress of Gastroenterology on Biological Therapy for IBD with the European Crohn's and Colitis Organization: when to start, when to stop, which drug to choose, and how to predict response? *Am J Gastroenterol* 2011;106:199–212. quiz 213.
- [67] Checchin D, Buda A, Sgarabotto D, et al. RDI Successful prophylaxis with valaciclovir for relapsing HSV-1 in a girl treated with infliximab for moderate Crohn's disease. *Eur J Gastroenterol Hepatol* 2009;21:1095–6.
- [68] Kittai A, Ali MA, Borum M. Herpes simplex virus blepharitis in a patient with Crohn's colitis. *Am J Med* 2014;127:e1–2.
- [69] Englund JA, Zimmerman ME, Swierkosz EM, et al. Herpes simplex virus resistant to acyclovir. A study in a tertiary care center. *Ann Int Med* 1990;112:416–22.