

Received: 2016.06.24  
Accepted: 2016.09.04  
Published: 2017.04.10

# Relationship Between Femur and Femoral Arteries for Identifying Risk Factors for Vascular Injury

Authors' Contribution:  
Study Design A  
Data Collection B  
Statistical Analysis C  
Data Interpretation D  
Manuscript Preparation E  
Literature Search F  
Funds Collection G

ABCDE **Qi Sun\***  
BCDF **GuoXin Fan\***  
BCDE **XiFan Li\***  
BCE **JinPeng Gong**  
CEF **Wei Ge**  
ADFG **Ming Cai**

Department of Orthopaedics, Shanghai Tenth People's Hospital, Tongji University, School of Medicine, Shanghai, P.R. China

**Corresponding Author:**  
**Source of support:**

\* These authors contributed equally to this work  
Ming Cai, e-mail: 13816147208@163.com  
Departmental sources

**Background:** This study aimed to identify risk factors for vascular injury in proximal femoral fracture through identifying frequency and distances between femur and femoral arteries with computed tomography angiography and 3-dimensional reconstruction.





**Material/Methods:** In a series of 400 participants, based on measurement results regarding the distribution of femoral arteries in the medial femur, the femoral portion covering that part was divided into levels A–E. The center region, margin region, and risky area in the medial femur were defined. The frequency of femoral arteries and interested shortest distance between the outer femur and superficial, deep, and perforating femoral arteries (SFAs, DFAs, and PFAs) in the center region, margin region, and risky area at each level were recorded.

**Results:** There were 173 males and 227 females (average age: 63.61±19.18 years) in this study. The starting point and end point for femoral arteries in the medial femur were from 22.55±4.23% to 54.56±8.39% of the whole femur. The femoral arteries in the medial femur mainly were distributed at levels B (88.2%), C (65.9%), and D (40.6%). The femoral arteries in center regions in the risky area, most of which were DFAs and PFAs, were mainly concentrated at levels B (26.93%) and C (11.81%).

**Conclusions:** The mid-shaft level was the most risky level, and the DFAs and PFAs were easier to injure than the SFAs when performing internal fixation of proximal femoral fracture. We recommended that great attention be paid to drill and screw insertion around the mid-shaft level for prevention of iatrogenic vascular injury.

**MeSH Keywords:** **Bone Screws • Femoral Artery • Femoral Fractures • Vascular System Injuries**

**Full-text PDF:** <http://www.medscimonit.com/abstract/index/idArt/900252>

 2306  4  3  24



## Background

The incidence of proximal femoral fracture (PFF) has dramatically increased due to poor bone stock and increasing life expectancy [1–3], and PFF management requires great attention from orthopedic surgeons because of a high rate of complications and mortality [4,5]. The vascular injury of femoral arteries in PFF internal fixation is rare but potentially life- or limb-threatening [6]. Although achieving early diagnosis and prompt accurate treatment are necessary, there is no optimal diagnostic or therapeutic modality for vascular injury [7]. Hence, further management or prevention of vascular injury may need clinical attention. There are infrequent reports demonstrating that the over-penetration of drill bit or distal screws may induce vascular injury of femoral arteries [8–12]. The current common PFF fixation modes are almost outside-to-in screw insertion, which is more dangerous for femoral arteries when travelling in the medial aspect of the femur. Recognition of the relationship between screw insertion and femoral arteries in the medial aspect of the femur is a practical approach to reduce iatrogenic vascular injury.

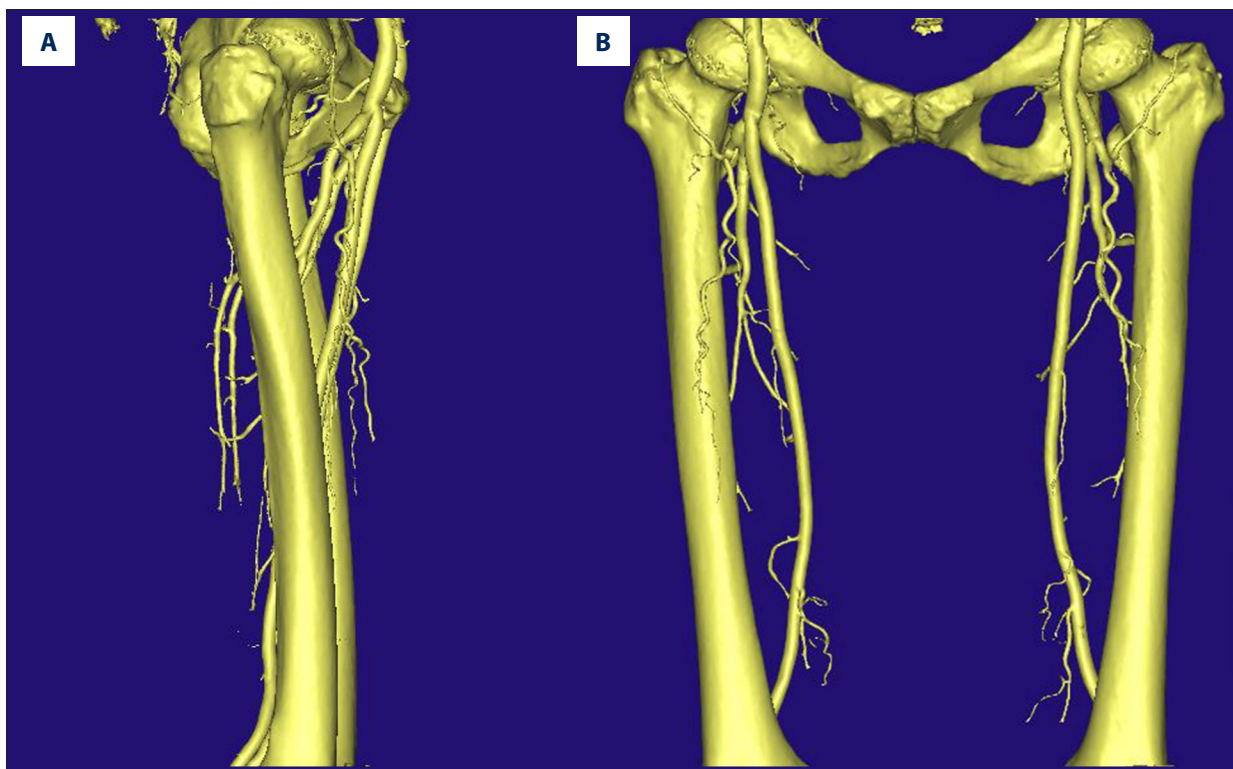
Therefore, we aimed to identify risk factors for vascular injury through identifying the relationship between screw insertion and femoral arteries in the medial aspect of the femur with computed tomography (CT) angiography and 3-dimensional (3D) reconstruction.

## Material and Methods

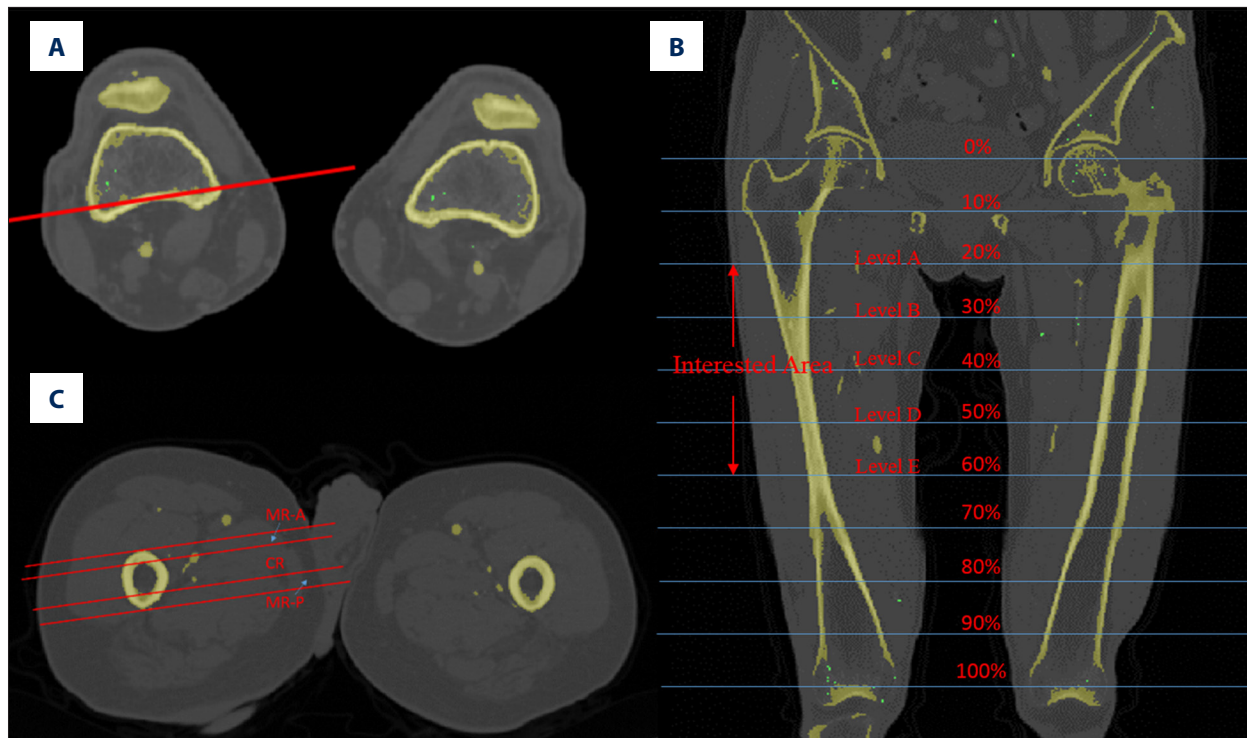
From August 2013 to December 2015, a total of 400 participants (173 males and 227 females, average age:  $63.61 \pm 19.18$  years) who underwent CT angiography of paired lower extremities were recorded. Inclusion criteria were age more than 18 years old and intact paired lower extremities without injury. Those with lower extremity deformity, femoral fracture history, severe femoral artery disease, height shorter than 150 cm, or age less than 18 years old were excluded. The study was approved by local institutional review boards, and required written informed consent was provided.

CT angiography was performed by a 64-slice CT scanner (GE Medical Systems/LightSpeed VCT, Siemens, New York, New York, USA) with the same scanning parameters: voltage 120 Kv, electricity 264 mA, image resolution 0.4 mm/pixel, and reconstruction interval 0.625 mm. The imaging data were transmitted to a personal graphics workstation. Mask A was obtained after mimics were set with a threshold value of 226 – maximum HU. Then, Region Growing was applied with Mask A to obtain Mask B, based on which a 3D reconstructed model (Figure 1) was obtained.

The reference line drawn in the study was the connection line of the medial and lateral epicondyle of the femur, which passed through the center of the femur (Figure 2A). The medial region



**Figure 1.** The 3D reconstruction model of femur and femoral arteries. (A) Lateral view. (B) Anteroposterior view.



**Figure 2.** (A) The reference on the CT angiography sectional view. (B) Schematic diagram of interested area (from level A to level E). (C) The center region (CR), margin region A (MR-A), and margin region P (MR-P) on the CT angiography sectional view.

of the femur between two tangent lines of the femur that paralleled the reference line defined the medial femur. The starting point and end point of the femoral arteries including superficial femoral artery (SFA), deep femoral artery (DFA), and perforating femoral artery (PFA) in the medial femur were measured.

The whole length of the femur was defined as the distance between the greater femoral tuberosity apex and the midpoint of the connection line of the medial and lateral epicondyle of the femur. According to measurement results, the femoral length covering the portion of femoral arteries in the medial femur was divided into five levels equally by percentage of the whole femur: namely, levels A (20%), B (30%), C (40%), D (50%), and E (60%) (Figure 2B). Based on the 3D reconstruction model and CT angiography sectional view, the center region was defined as the region between two tangent lines of the medullary cavity in the medial femur, which was paralleled with the reference line. The margin region was defined as the region between the ipsilateral tangent lines of the medullary cavity and the femur; the anterior part was named margin region A and the posterior part was named margin region P (Figure 2C). The region within 10 mm of the femur in the medial femur was defined as the risky area. The shortest distance was the length of the connection line between the outer femur and femoral arteries, which was paralleled with the reference line. The frequency of femoral arteries and the interested shortest distance in the medial femur and in the risky area at each level were recorded.

An experienced radiologist and an orthopedic surgeon reviewed CT angiography images and 3D reconstruction models twice at an interval of 10 days in random order. All information about participants was blinded, and the assessment results were also blinded to each other. The clinical results without participants' information were analyzed by the same author.

### Statistical analysis

All statistical analyses were performed using SPSS 19.0 (IBM Corp., Armonk, New York, USA). All data are summarized as mean  $\pm$  standard deviations for continuous variables and frequency (percentages) for categorical variables. One-way ANOVA and Student's t test were applied for statistical analysis. A significant difference was defined as  $p < 0.05$ .

### Results

The starting point and end point in the medial femur were different among SFAs, DFAs, and PFAs (from  $31.45 \pm 9.64\%$  to  $54.56 \pm 8.39\%$  for SFAs, from  $22.55 \pm 4.23\%$  to  $42.75 \pm 7.12\%$  for DFAs, and from  $24.45 \pm 4.57\%$  to  $34.30 \pm 6.17\%$  for PFAs with respect to the whole femur). The starting point and end point for femoral arteries in the medial femur was from  $22.55 \pm 4.23\%$  to  $54.56 \pm 8.39\%$  of the whole femur. There were 173 males and 227 females (average age:  $63.61 \pm 19.18$  years) in this study.

**Table 1.** The femoral arteries distribution in different regions at each level.

| Level | Regions         | SFA | DFA | PFA | Total        |
|-------|-----------------|-----|-----|-----|--------------|
| A     | Margin Region A | 19  | 142 | 79  | 240 (15.0%)  |
|       | Center Region   | /   | 41  | 17  | 58 (3.6%)    |
|       | Margin Region P | /   | /   | /   | /            |
|       | Total           | 19  | 183 | 96  | 298 (18.6%)  |
| B     | Margin Region A | 397 | 162 | /   | 559 (34.9%)  |
|       | Center Region   | 4   | 551 | 212 | 767 (47.9%)  |
|       | Margin Region P | /   | 12  | 73  | 85 (5.3%)    |
|       | Total           | 401 | 725 | 285 | 1411 (88.2%) |
| C     | Margin Region A | 203 | 19  | /   | 222 (13.9%)  |
|       | Center Region   | 614 | 173 | /   | 787 (49.2%)  |
|       | Margin Region P | /   | 11  | 35  | 46 (2.9%)    |
|       | Total           | 817 | 203 | 35  | 1055 (65.9%) |
| D     | Margin Region A | 9   | /   | /   | 9 (0.6%)     |
|       | Center Region   | 190 | 0   | /   | 190 (11.9%)  |
|       | Margin Region P | 418 | 31  | /   | 449 (28.1%)  |
|       | Total           | 617 | 31  | /   | 648 (40.6%)  |
| E     | Margin Region A | /   | /   | /   | /            |
|       | Center Region   | /   | /   | /   | /            |
|       | Margin Region P | 189 | /   | /   | 189 (11.8%)  |
|       | Total           | 189 | /   | /   | 189 (11.8%)  |

Satisfactory agreement was demonstrated by an intraclass correlation of 0.915–0.996 for intraobserver reliability and 0.897–0.993 for interobserver reliability in the study.

The femoral arteries in the medial femur were mainly distributed at levels B (88.2%), C (65.9%), and D (40.6%). As for distribution in the center region in the medial femur, the femoral arteries were mainly concentrated at levels B (47.9%) and C (49.2%) (Table 1). Besides, PFAs and DFAs were much closer to the femur than SFAs at each level, and the difference was significant ( $p < 0.05$ ). The PFAs were closest to the femur in the center region at levels A, B, and C, and the DFAs had the least distance to the femur in the center region at level D. Moreover, the femoral arteries in the center region at level B were much closer to the femur than at other levels (Table 2). The femoral arteries in the center regions in the risky area, most of which were DFAs and PFAs, were mainly concentrated at levels B (26.93%) and C (11.81%). No femoral arteries existed in the center region in the risky area at level E (Table 3). There was no significant difference between left and right sides, or between male and female subjects (except at level B), in the

distance between femoral arteries and the femur in the center region (Table 4).

### Discussion

The increasing incidence of PFF draws more attention to treatment and relevant complications [1,13,14], of which iatrogenic vascular injury is a severe complication and is difficult to diagnose early [15,16]. Identifying the relationship between femoral arteries and femur in the medial aspect of the femur is critical for prevention of iatrogenic vascular injury in internal fixation of PFF. We found that the femoral arteries were mainly distributed in the medial part of the femur at levels B, C, and D. The least mean distance between femoral arteries and femur in the center region was at level B ( $12.80 \pm 2.38$  mm). With respect to distribution in the center region in the risky area, the femoral arteries were concentrated at levels B and C. Moreover, the PFAs and DFAs were much closer to the femur than the SFAs.

**Table 2.** The distance between femur and SFA, DFA and PFA at each level.

| Level | Regions         | SFA        | DFA        | PFA        | Total      | p     |
|-------|-----------------|------------|------------|------------|------------|-------|
| A     | Margin Region A | 39.51±5.26 | 24.63±3.64 | 17.12±2.87 | 23.34±3.57 | 0.01< |
|       | Center Region   | /          | 24.16±3.29 | 12.86±2.86 | 22.26±3.18 | 0.033 |
|       | Margin Region P | /          | /          | /          | /          | /     |
| B     | Margin Region A | 33.59±5.01 | 17.67±2.18 | /          | 28.98±4.33 | 0.035 |
|       | Center Region   | 28.17±2.95 | 14.54±1.97 | 7.99±3.05  | 12.80±2.38 | 0.01< |
|       | Margin Region P | /          | 13.09±2.41 | 10.75±2.73 | 11.08±2.54 | 0.694 |
| C     | Margin Region A | 40.39±5.62 | 13.93±2.85 | /          | 38.13±5.39 | 0.021 |
|       | Center Region   | 27.69±2.89 | 12.33±3.27 | /          | 24.31±2.98 | 0.037 |
|       | Margin Region P | 0          | 11.63±3.11 | 4.23±3.49  | 5.99±3.32  | 0.019 |
| D     | Margin Region A | 25.06±3.17 | /          | /          | 25.06±3.17 | /     |
|       | Center Region   | 31.91±3.94 | /          | /          | 31.91±3.94 | /     |
|       | Margin Region P | 32.14±4.21 | 5.54±2.99  | /          | 30.30±4.14 | <0.01 |
| E     | Margin Region A | /          | /          | /          | /          | /     |
|       | Center Region   | /          | /          | /          | /          | /     |
|       | Margin Region P | 34.34±4.38 | /          | /          | 34.34±4.38 | /     |

p< was regarded as significant difference. Unit – mm.

**Table 3.** The femoral arteries distribution in center region and risky area at each level.

| Level | SFA | DFA | PFA | Total        |
|-------|-----|-----|-----|--------------|
| A     | /   | /   | 29  | 29 (1.81%)   |
| B     | /   | 237 | 194 | 431 (26.93%) |
| C     | 31  | 158 | /   | 189 (11.81%) |
| D     | 15  | /   | /   | 15 (0.94%)   |
| E     | /   | /   | /   | /            |

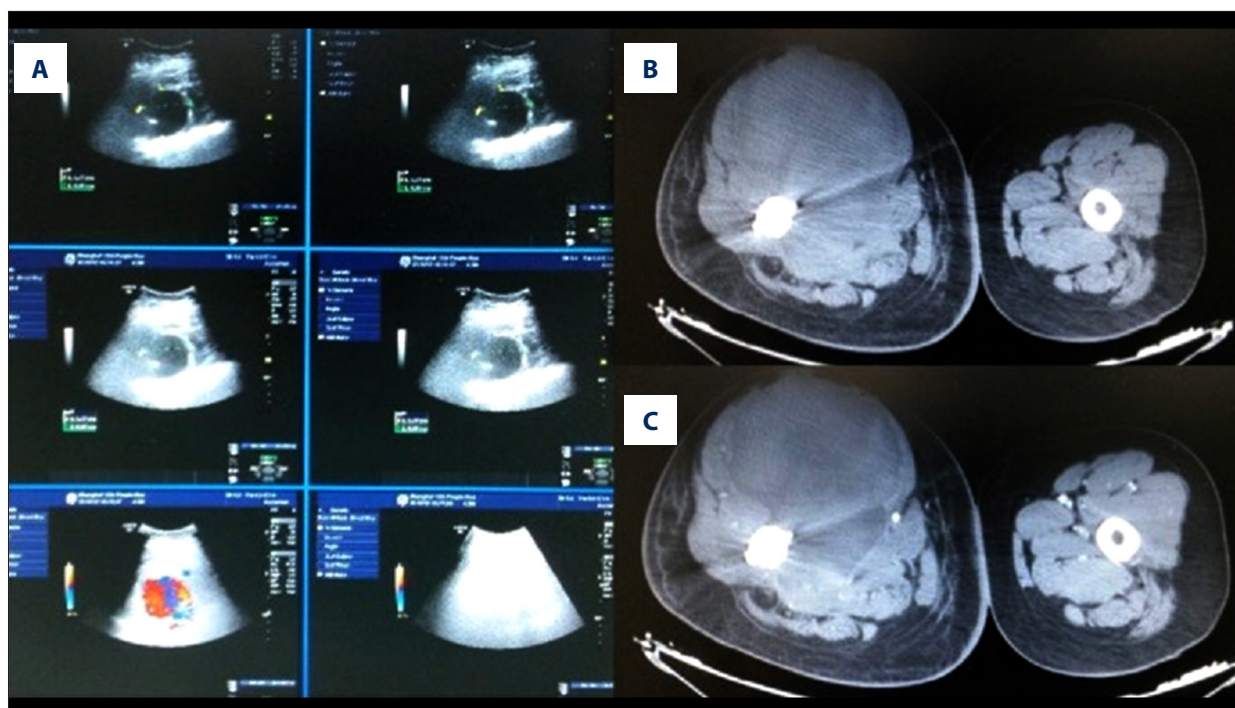
**Table 4.** The difference in distance between femoral arteries and femur with sex and sides.

| Level | Left side  | Right side | p     | Male       | Female     | p     |
|-------|------------|------------|-------|------------|------------|-------|
| 20%   | 23.07±3.42 | 23.54±3.17 | 0.874 | 25.91±3.28 | 22.34±3.07 | 0.174 |
| 30%   | 11.92±2.07 | 13.29±3.11 | 0.542 | 13.95±3.42 | 10.87±2.04 | 0.047 |
| 40%   | 25.17±2.83 | 23.94±3.13 | 0.685 | 26.94±3.59 | 22.76±2.71 | 0.219 |
| 50%   | 31.44±4.02 | 29.94±4.43 | 0.429 | 32.47±4.68 | 29.26±3.83 | 0.276 |
| 60%   | 33.29±4.89 | 34.86±4.01 | 0.597 | 34.99±4.74 | 33.16±4.25 | 0.542 |

P<0.05 was regarded as significant difference. Unit – mm.

The thigh anatomy demonstrated that the femoral arteries run anterior to the femur, separate into SFAs, DFAs, and PFAs, and then run posteromedial or posterior to the femur from the medial

aspect [7]. According to previous studies, [7,9,17], the common screw insertion methods for PFF were completely or almost outside-to-in. The femoral arteries in the medial aspect of the



**Figure 3.** (A) Ultrasonography of DFA pseudoaneurysms. (B) CT of DFA pseudoaneurysms. (C) CT angiography of DFA pseudoaneurysms.

femur were in jeopardy from screw insertion or over-shot drill bit, which should never be underestimated. Therefore, the course of the femoral arteries in the medial aspect of the femur was in danger during screw insertion. In our study, we found that the femoral arteries in the medial aspect of the femur covered from  $22.55 \pm 4.23\%$  to  $54.56 \pm 8.39\%$  of the whole femur. Orthopedic surgeons must pay close attention when screws are inserted around those levels. In the light of our results, the femur from 20% to 60% was divided into five levels: namely, levels A, B, C, D, and E. The percentage rather than the length of the femur was selected for level division mainly because the percentage was not influenced by height of subjects; therefore, it was more practicable for further clinical application. The femoral arteries in the medial aspect of the femur were mainly distributed at levels B (88.2%), C (65.9%), and D (40.6%); that is to say, the femoral arteries around levels B to D were at higher risk for iatrogenic vascular injury than those around levels A and E due to intense distribution of femoral arteries. Moreover, Yang et al. [18] found that internal rotation and adduction would lessen the distance between SFAs and the femur. Grimaldi et al. [19] reported an SFA laceration caused by insertion of screws, and they recommended that neutral position and less limb traction could reduce the risk of injury to SFAs. Thus, neutral position with less limb traction would be a better choice in screw insertion for prevention of iatrogenic vascular injury. Diminished traction and adduction before screwing plates or cephalomedullary nails could reduce vascular injury because it would not lessen the distance between the medial femur and nearby vessels.

According to the degree of risk for iatrogenic vascular injury [9], the medial aspect of the femur was divided into three regions (center region and margin regions), and the femoral arteries in the center region were easily injured during screw insertion. The vascular injury usually occurred where femoral arteries were close to the femur in the direction of screw insertion [18]. The risky area was analyzed especially because of higher risk for vascular injury. With regard to center regions in the risky area, the femoral arteries, mainly DFAs and PFAs, were mostly concentrated at levels B (26.93%) and C (11.81%). That could explain the higher incidence of vascular injury in DFAs and PFAs compared with SFAs. Injuries to PFAs were usually reported in the fixation of intertrochanteric fracture [9,20]. In addition, level B and level C were the most risky levels for iatrogenic vascular injury compared with other levels. Laohapoonrungrsee et al. [10] believed that a short drill bit and accurate screw length were helpful in prevention of pseudoaneurysms. A case of DFA pseudoaneurysm was observed in our trauma center 4 weeks postoperatively (Figure 3). Considering the distribution of femoral arteries in the left limb, the short distance to the femur and distribution in the center region might be the main causes for the DFA pseudoaneurysm.

There were no significant differences in distance of femur and femoral arteries between the left and right limbs, which was partially consistent with the result of Han et al. [17]. No significant differences between male and female subjects were observed, except for distance at level B. Mean distance in

male subjects was greater than that in female subjects, which might be related to differences in heights and weights between male and female subjects. Therefore, iatrogenic vascular injuries might be more common in female subjects, which indicates the need for more caution on the part of orthopedic surgeons, especially when the screw insertion is around level B.

CT angiography and 3D reconstruction were combined to obtain more accurate and rapid measurement results with satisfactory quality control. The 3D reconstructed model could show anatomical structures in detail and the spatial relationship between femur and femoral arteries, and was more easily and accurately used for image review [21]. Yang et al. [18] applied color-flow duplex scanning for distance measurement in three hip positions. However, color-flow duplex scanning was not as accurate and distinct as CT angiography, and only distance between the femur and SFAs was measured, without the other arteries. Han et al. [17] introduced angle measurement to identify the relationship between femoral arteries and imaginary distal locking screws. Nevertheless, the study sample was not large enough, and PFAs were not well studied [22,23]. Besides, the outside-to-in screw insertion was not well considered, and the area of the femur associated with high risk of iatrogenic vascular injury was not analyzed. Kim et al. [24] calculated the number of femoral arteries and average distance by regions from six levels, aiming to select a safe zone for minimally invasive medial plate fixation in the distal femur. The risky area was also not analyzed in particular in that study. Compared with this method, in our study we analyzed the femoral arteries, assisted by 3D reconstructions, as well

as differences in distance between males and females and between the right and left sides.

Several limitations existed in the design of this study. Firstly, only images of CT angiography in the supine position were obtained for measurement, because it was not practical for participants to undergo CT angiography in different positions. The report [18] about internal rotation and adduction lessening distance between the femur and interested arteries could resolve the problem partially. Secondly, the PFA distribution in the medial aspect of the femur was regarded as the course from starting point to ending point. In addition, there was no anatomical measurement for comparison to validate the accuracy of the results in this study, because it was not practical to perform anatomical measurement. Lastly, large-scale prospective studies need to be performed for validation.

## Conclusions

The mid-shaft level was the most risky level, and the DFAs and PFAs were easier to injure than the SFAs during internal fixation of proximal femoral fracture. We recommended that great attention be paid to drill and screw insertion around the mid-shaft level for prevention of iatrogenic vascular injury.

## Conflicts of interest

None declared.

## References:

1. Muller F, Galler M, Zellner M et al: The fate of proximal femoral fractures in the 10<sup>th</sup> decade of life: An analysis of 117 consecutive patients. *Injury*, 2015; 46(10): 1983–87
2. Sahin E K, Imerci A, Kinik H et al: Comparison of proximal femoral nail antirotation (PFNA) with AO dynamic condylar screws (DCS) for the treatment of unstable peritrochanteric femoral fractures. *Eur J Orthop Surg Traumatol*, 2014; 24(3): 347–52
3. Ozkan K, Turkmen I, Sahin A et al: A biomechanical comparison of proximal femoral nails and locking proximal anatomic femoral plates in femoral fracture fixation: A study on synthetic bones. *Indian J Orthop*, 2015; 49(3): 347–51
4. Okcu G, Ozkayin N, Erkan S et al: Should full threaded compression screws be used in adult femoral neck fractures? *Injury*, 2015; 46(Suppl. 2) S24–28
5. Haubro M, Stougaard C, Torfing T, Overgaard S: Sensitivity and specificity of CT- and MRI-scanning in evaluation of occult fracture of the proximal femur. *Injury*, 2015; 46(8): 1557–61
6. Bartonicek J: [Injuries to femoral vessels in fractures of the hip]. *Rozhl Chir*, 2009; 88(4): 203–5 [in Czech]
7. Barquet A, Gelink A, Giannoudis PV: Proximal femoral fractures and vascular injuries in adults: Incidence, aetiology and outcomes. *Injury*, 2015; 46(12): 2297–313
8. Yang KH, Park HW, Park SJ: Pseudoaneurysm of the superficial femoral artery after closed hip nailing with a Gamma nail: Report of a case. *J Orthop Trauma*, 2002; 16(2): 124–27
9. Rajaesparan K, Amin A, Arora S, Walton NP: Pseudoaneurysm of a branch of the profunda femoris artery following distal locking of an intramedullary hip nail: an unusual anatomical location. *Hip Int*, 2008; 18(3): 231–35
10. Laohapoonrungrsee A, Sirirungruangsarn Y, Arpornchayanon O: Pseudoaneurysm of profunda femoris artery following internal fixation of intertrochanteric fracture: two cases report. *J Med Assoc Thai*, 2005; 88(11): 1703–6
11. Kickuth R, Anderson S, Kocovic L et al: Endovascular treatment of arterial injury as an uncommon complication after orthopedic surgery. *J Vasc Interv Radiol*, 2006; 17(5): 791–99
12. Bassett FH, Houck WS: False aneurysm of the profunda femoris artery after subtrochanteric osteotomy and nail-plate fixation. *J Bone Joint Surg Am*, 1964; 46: 583–85
13. Ma KL, Wang X, Luan FJ et al: Proximal femoral nails antirotation, Gamma nails, and dynamic hip screws for fixation of intertrochanteric fractures of femur: A meta-analysis. *Orthop Traumatol Surg Res*, 2014; 100(8): 859–66
14. Haidukewych GJ, Berry DJ: Salvage of failed treatment of hip fractures. *J Am Acad Orthop Surg*, 2005; 13(2): 101–9
15. Lazarov M, Van der Bracht H, Victor J, Stuyts B: Missed diagnosis of false aneurysm of the superficial femoral artery after closed complex fracture of the distal femur. *Orthop Traumatol Surg Res*, 2014; 100(6): 695–97
16. Handolin L, Pajarinen J, Tuulikoura I: Injury to the deep femoral artery during proximal locking of a distal femoral nail – a report of 2 cases. *Acta Orthop Scand*, 2003; 74(1): 111–13
17. Han CD, Lee YH, Yang KH et al: Relationship between distal screws and femoral arteries in closed hip nailing on computed tomography angiography. *Arch Orthop Trauma Surg*, 2013; 133(3): 361–66
18. Yang KH, Yoon CS, Park HW et al: Position of the superficial femoral artery in closed hip nailing. *Arch Orthop Trauma Surg*, 2004; 124(3): 169–72

19. Grimaldi M, Courvoisier A, Tonetti J et al: Superficial femoral artery injury resulting from intertrochanteric hip fracture fixation by a locked intramedullary nail. *Orthop Traumatol Surg Res*, 2009; 95(5): 380–82
20. Patelis N, Koutsoumpelis A, Papoutsis K: Iatrogenic injury of profunda femoris artery branches after intertrochanteric hip screw fixation for intertrochanteric femoral fracture: A case report and literature review, 2014; 2014: 694235
21. Wei XF, Zhang XY, Yuan WU, Li YS: Accuracy of computer-aided geometric three-dimensional reconstruction of the human petrous bone based on serial unstained celloidin sections. *Exp Ther Med*, 2015; 9(4): 1113–18
22. Canbaz S, Acipayam M, Gurbuz H, Duran E: False aneurysm of perforating branch of the profunda femoris artery after external fixation for a complicated femur fracture. *J Cardiovasc Surg (Torino)*, 2002; 43(4): 519–21
23. Naouli H, Jiber H, Bouarhroum A: False aneurysm of perforating branch of the deep femoral artery – report of two cases. *Int J Surg Case Rep*, 2015; 14: 36–39
24. Kim JJ, Oh HK, Bae JY, Kim JW: Radiological assessment of the safe zone for medial minimally invasive plate osteosynthesis in the distal femur with computed tomography angiography. *Injury*, 2014; 45(12): 1964–69