



Contents lists available at ScienceDirect

International Journal of Surgery Case Reports

journal homepage: www.casereports.com

An unusual presentation of congenital intestinal malrotation in a nonagenarian

Fernandez-Moure Joseph S.^{a,b,*}, Maya L. Moses^c, Andres Garcia^c, Reader Michael M.^a^a Houston Methodist Hospital, Department of Surgery, 6565 Fannin St., Houston, TX 77030, United States^b Houston Methodist Research Institute, Department of Regenerative and Biomimetic Medicine, Surgical Advanced Technologies Lab, 6670 Bertner Ave., Houston, TX, 77030, United States^c University of Texas Health Science Center at Houston, 7000 Fannin St., Houston, TX, 77030, United States

ARTICLE INFO

Article history:

Received 11 April 2016

Accepted 28 June 2016

Available online 1 July 2016

Keywords:

Intestinal malrotation

Appendicitis

Elderly

Peritonitis

ABSTRACT

INTRODUCTION: Appendicitis is a common surgical pathology with many clinical presentations. Diagnosis can be challenging if there is an alteration to the normal position of anatomical structures and their relationships.

CASE PRESENTATION: In this case, we report an unusual presentation of congenital intestinal malrotation in a nonagenarian presenting with generalized abdominal pain and lactic acidosis found to have perforated appendicitis. The patient was admitted to the Hospitalist service for abdominal pain and misdiagnosed with bowel obstruction secondary to previous “operation”. After further review of imaging malrotation with internal hernia was suggested. The patient was taken emergently to the operating room and found to have perforated and gangrenous appendix in the midabdomen. An appendectomy was performed and patient was ultimately discharged home in good condition on postoperative day four.

DISCUSSION: Malrotation of the intestines is a developmental variant that occurs when normal fetal rotation of the intestines around the superior mesenteric artery and their peritoneal fixation fails to occur. Presentation typically occurs during infancy and diagnosis in an elderly patient is exceedingly rare. Operative intervention is often required as it is commonly associated with lactic acidosis or peritonitis.

CONCLUSIONS: Malrotation can go undiagnosed well into elderly life and can present with unusual signs and symptoms. CT is very helpful in aiding the diagnosis but itself can be misleading.

© 2016 The Authors. Published by Elsevier Ltd on behalf of IJS Publishing Group Ltd. This is an open access article under the CC BY-NC-ND license (<http://creativecommons.org/licenses/by-nc-nd/4.0/>).

1. Introduction

Malrotation of the intestines is a relatively uncommon anomaly with an incidence of 1 in 500 births and with symptomatic cases only appearing in 1 out of every 6000 births [1,2]. A large portion (40%) of affected patients are diagnosed within the first week of life with the vast majority (75–85%) following within the first year [3]. Very few cases in children remain quiescent, therefore incidence rates in adults become increasingly small and one estimate shows an occurrence of 0.16% within the adult population [4]. Intestinal malrotation occurs when the colon and small intestine fail to properly rotate into their normal anatomic positions when the intestines

return into the abdominal cavity in utero. As a result: the patient's small intestine is found predominantly on the right side of the body; the cecum and right colon are misplaced into the midepigastrium; the ligament of Treitz is displaced inferiorly and rightward; fibrous connective tissue (Ladd's bands) forms from the cecum and right colon, obstructing the duodenum; and the superior mesenteric artery (SMA) has a narrow base predisposing it to volvulus [5,6]. The typical history reported by the patient includes bilious emesis and physical exam may reveal abdominal distention [6]. The diagnosis is confirmed with an upper GI X-ray series with small bowel follow through where the abnormal position of the ligament of Treitz and cecum can be appreciated. An unexplained lactic acidosis may be an important indicator of intestinal ischemia in the setting of obstruction and may even prompt surgical intervention. In this report, we present a case of a 92 year old man with undiagnosed malrotation who presented with generalized abdominal pain thought to be due to obstruction and was later found to have perforated appendicitis. To our knowledge, this is the oldest reported age for an initial diagnosis of congenital intestinal malrotation.

Abbreviations: CT, Computed Tomography; BUN, Blood Urea Nitrogen; GI, Gastrointestinal; PO, per oral; SMA, Superior Mesenteric Artery.

* Corresponding author at: Houston Methodist Hospital, Department of Surgery, Suite 1661, 6565 Fannin St., Houston, Texas 77030, United States.

E-mail addresses: jfernandez-moure@houstonmethodist.org (J.S. Fernandez-Moure), Maya.L.Moses@uth.tmc.edu (M.L. Moses), Andres.Garcia@uth.tmc.edu (A. Garcia), mmreader@houstonmethodist.org (M.M. Reader).

<http://dx.doi.org/10.1016/j.ijscr.2016.06.053>

2210-2612/© 2016 The Authors. Published by Elsevier Ltd on behalf of IJS Publishing Group Ltd. This is an open access article under the CC BY-NC-ND license (<http://creativecommons.org/licenses/by-nc-nd/4.0/>).

2. Case presentation

Patient is a 92-year old Caucasian gentleman with a past medical history significant for diet controlled diabetes, coronary artery disease status post angioplasty and stent placement, gastroesophageal reflux disease, hyperlipidemia, dementia, and hypertension. Surgical history consisted of a right-sided total hip arthroplasty and a coronary artery bypass graft. He was admitted to the emergency department in stable condition for evaluation and management of lower abdominal pain and generalized weakness. The patient reported symptoms of two days duration with the most recent bowel movement occurring 3 days prior to presentation to the Emergency Department (ED). The patient was initially admitted to a hospitalist from the ED and intravenous normal saline was started. He endorsed nausea and vomiting for two days and an absence of flatulence. Abdominal pain had been present in bilateral lower quadrants but had migrated towards the upper abdominal quadrants with exacerbation of pain on exertion. Labs drawn from the patient revealed a basic metabolic panel showing moderate hyperglycemia (glucose of 242), a lactic acid of 5.2, creatinine of 1.5, BUN of 36, and an anion gap of 20. A complete blood count was within normal limits. Results from an abdominal CT showed diffuse small bowel dilation with focal areas of wall thickening and an assumption by the radiologist of past right-sided hemicolectomy surgery based on anatomical presentation of both the large and small bowel. Calcified gallstones and free air were also appreciated on the read. In addition, free fluid was noted adjacent to the dilated loops of small bowel that was greater in the mid and right abdomen than the left suggesting an infectious or inflammatory process. Once the imaging was performed, a surgical consultation was placed to evaluate the patient for possible small bowel obstruction secondary to adhesive disease as a result of his previous abdominal operation. Physical exam shows an agitated and confused patient with persistent tachycardia, normal blood pressure, and low-grade fever (38.1 °C). Abdominal exam demonstrated a distended, tympanic abdomen with diffuse tenderness to palpation worse in the midepigastrium and no surgical scars. The patient did not endorse ever having had an abdominal operation and family confirmed this. Upon further interrogation of the CT scan it was noted that the majority of bowel was on the right side of the abdomen (Fig. 1). Additionally, the right colon was noted to be in the midepigastrium, the duodenum do not cross the midline, and a fecolith in the bowel (Fig. 2a and b). The diagnosis of malrotation with a possible obstruction secondary to internal hernia or Ladd's bands was then suspected.

Given the patient's presentation of peritonitis with lactic acidosis in the setting of potential malrotation, he was taken urgently to the operating room for exploratory laparotomy. Prior to surgery the patient received resuscitation with lactated ringers solution, placement of a nasogastric tube for decompression, and placement of an arterial line for hemodynamic monitoring intraoperatively. The abdomen was entered through a midline laparotomy incision. This revealed a moderate amount of turbid purulent fluid that was suctioned and sent for culture. He was noted to have numerous interloop small-bowel adhesions that were taken down bluntly as well as fibrinous exudates and interloop abscesses throughout the abdomen. It was clear the patient did, in fact, have malrotation with the cecum and appendix position being in the middle of the abdomen (Fig. 3a). He was noted to have a small-bowel obstruction secondary to inflammation and scarring from the infectious process. While Ladd's bands were clearly seen this was not the source of obstruction precipitating the patient's hospitalization as they did not course over the duodenum (Fig. 3b). The obstruction was manually reduced and the small bowel was examined throughout its entirety and no perforations or bowel ischemia was identified. The cecum was again identified in the middle of the abdomen and was

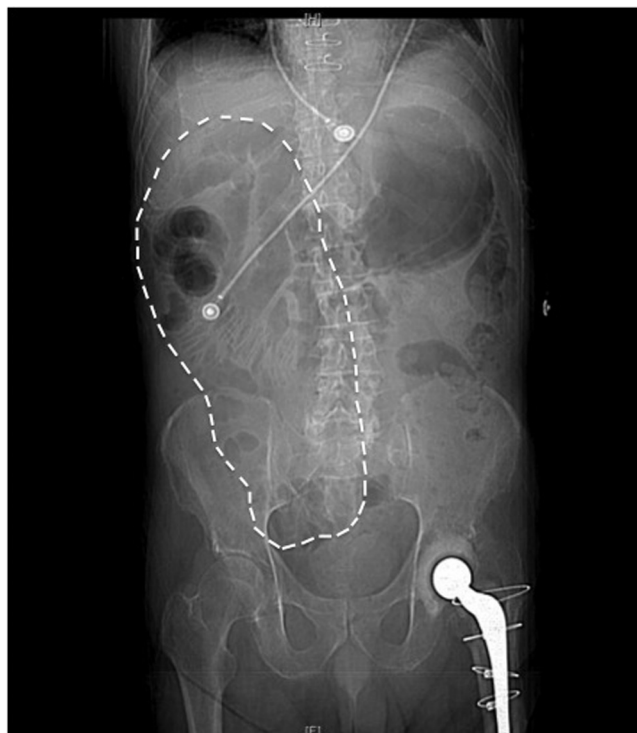

Fig. 1. Abdominal X-ray demonstrates dilated loops of small bowel. A paucity of colonic gas is noted on the right side with a predominance of small bowel in right upper quadrant.

noted to have a gangrenous appendix with several perforations as well as a large fecolith (Fig. 4). Further mobilization identified a large intraabdominal abscess that was opened and drained. These findings confirmed the diagnosis of appendicitis and not an obstruction from internal hernia associated with malrotation. The appendix and mesoappendix were ligated and an open appendectomy performed in a standard fashion. Hemostasis was attained and the abdomen irrigated with bacitracin infused saline prior to closure. Once the irrigant was clear the patient's fascia and skin were closed and the patient transferred to the post operative care unit in stable condition. The patient did not suffer an intraoperative instability and did not require any vasopressor support during the operation. The patient postoperative course was uncomplicated and he was discharged home on post-operative day 4 following return of bowel function and resumption of a heart healthy diet.

3. Discussion

Malrotation is commonly diagnosed in infancy with a 55% incidence of a clinical emergency related to malrotation in the first week of life and an 80% incidence within the first month of life [1]. In order to understand how malrotation classically presents, a basic understanding of how the alimentary tract develops is essential. The alimentary tract is divided into foregut, midgut, and hindgut defined by the blood supply it receives. Intestinal rotation primarily involves the midgut and begins during the fifth gestational week and proceeds through the twelfth gestational week. Rotation of the midgut has classically been divided into three stages. In stage one, the midgut loop undergoes a 90° counterclockwise rotation around the SMA. This occurs during the 8th week of gestation and failure of this first stage results in an omphalocele. During the early phase of the second stage, the midgut has returned to the peritoneal cavity and development of the bowel continues. If development proceeds normally, a 270° counterclockwise rotation of the midgut occurs resulting in the normal anatomical position of the C-loop of the

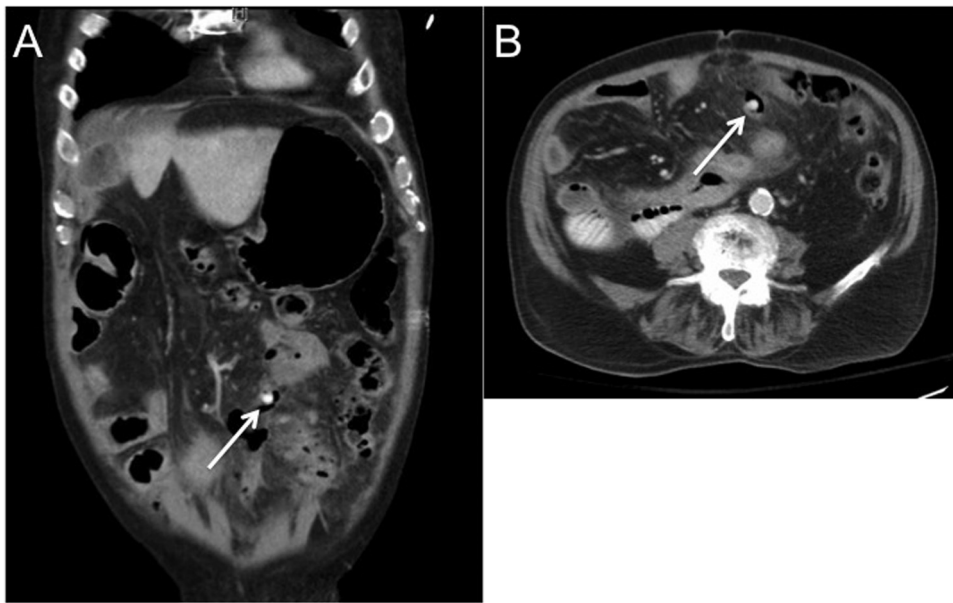


Fig. 2. Abdominal Computed Tomography (CT). Abdominal CT shows thickened loops of bowel in the midabdomen with a prominent fecolith (white arrow). The right colon is absent from its normal anatomic position.

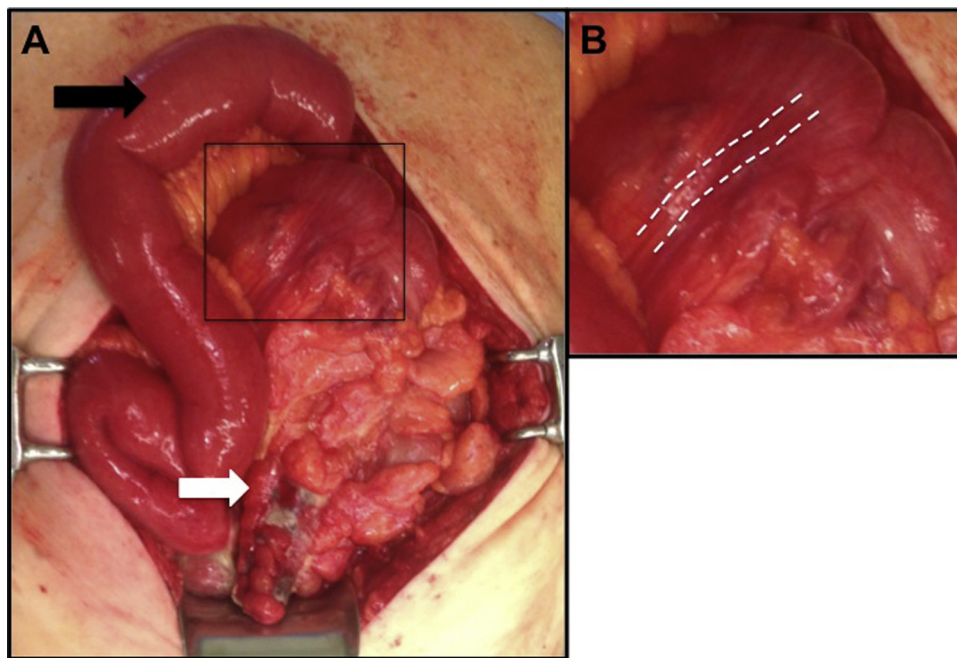


Fig. 3. Intraoperative pictures demonstrate a midabdominal appendix. The appendix was perforated with a large fecolith (white arrow). The proximal jejunum (black arrow) is seen coursing the patient's right side and not crossing midline along the normal anatomic course (3a). Ladd's bands (white dotted lines) are seen originated from the cecum and right colon (3b).

duodenum behind the SMA and the transverse colon lying anteriorly to the SMA [7]. If the 270° counterclockwise rotation does not occur than a non-rotation results. Any deviation from the 270° rotation results in a malrotation. In non-rotation the duodenum descends in a linear fashion to the right of the SMA and no ligament of Treitz is formed. The final step involves fixation of the intestine and fusion of the mesentery. Fixation of the bowel keeps the ascending and descending colon anchored into the right and left abdominal gutters, respectively. Presentation of generalized abdominal pain in the elderly population hardly narrows potential diagnoses from a physician's differential. Due to the innervation

of visceral tissue within the gut, pain is usually generalized for most affected structures other than normal anatomic appendicitis and diverticulitis, which have well known localization to the right, lower quadrant and left lower quadrant, respectively. Patients are usually unaware of the origin of their visceral pain until the adjacent peritoneum becomes inflamed from locally irritated tissue, and their pain becomes somatic in nature.

Determining the incidence of malrotation in the adult population has proven considerably difficult due its rare appearance [8]. Studies have shown an incidence of between 0.0001% and 0.19% in the adult population [6,9,10]. Of those cases that remain

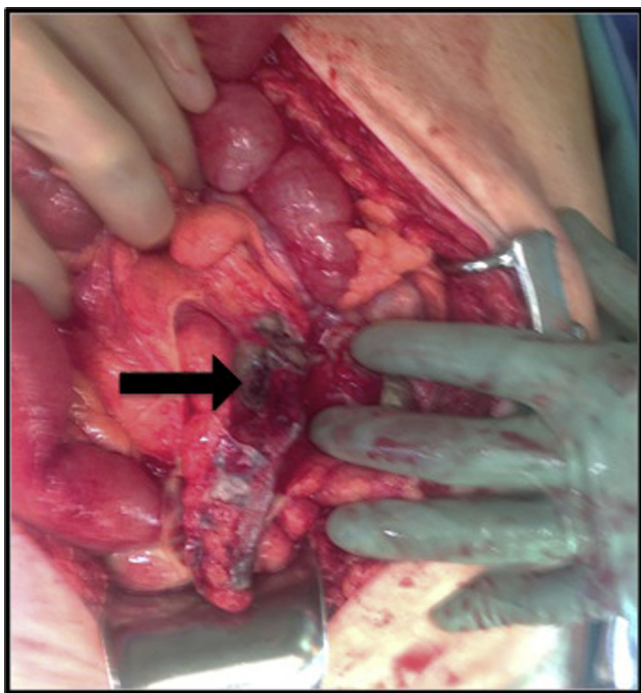


Fig. 4. Appendiceal perforation. The appendix (black arrow) was found to be gangrenous and perforated at its base.

undiagnosed through infancy and adolescence, few will present in their adulthood with abdominal bloating, vomiting, and intermittent symptoms of volvulus. Adult malrotation cases that were previously undiagnosed but presented with signs and symptoms of small bowel obstruction are usually discovered when clinical protocols call for abdominal imaging or surgical intervention. Diagnosis of pathologies such as appendicitis are difficult to detect in patient's with malrotation and represent a clinical dilemma [11]. Of the imaging modalities, conventional X-rays yield low utility with positive cases usually showing abnormal fluid and air levels with abnormal jejunal loops and an absent colon on the right side of the abdomen [4]. CT imaging currently stands as the gold standard imaging modality available for diagnosing malrotation and if possible, with PO contrast [12]. Some cases may be diagnosed based off of abnormal positioning of the superior mesenteric artery in relation to the superior mesenteric vein as well as the classic “whirlpool sign” that was originally characterized by Fisher [13]. However, abnormal or normal anatomic positioning of the SMA and SMV does not rule in or rule out malrotation. While the majority of patients with malrotation will likely present with obstruction, other causes of abdominal pain must also be dually considered.

In retrospect, an antibiotic regimen should have been started at an earlier time due to the suspicion of ischemia and perforation. Clinical signs of peritonitis and an elevated lactic acidosis were the factors that pushed the medical team into surgical intervention where the undiagnosed malrotation in addition to appendicitis was discovered. At the time of this writing, we were unable to find any reports with a similar presentation with a patient age greater than 90. Thus, we believe this to be oldest confirmed age of a patient with undiagnosed intestinal malrotation. Strikingly, while diagnosis was delayed due to the congenital condition, his hospitalization was not a result of a complication of malrotation but rather the most common of surgical conditions.

4. Conclusion

Malrotation is a rare pathologic entity most often diagnosed in infancy. Diagnosis in the elderly is rare [8]. While presentation with obstruction is most common, these patients are susceptible to common surgical diseases such as appendicitis. Because of altered anatomy, patients will present with midabdominal or generalized abdominal pain and thus common pathology of the colon and appendix should be considered. CT imaging and awareness of radiographic findings of malrotation aid in the diagnosis but can be misleading because the already altered anatomy can be further distorted by the ongoing pathology.

Conflict of interest

None.

Funding source

None.

Ethics approval

Not applicable.

Consent

Written informed consent was obtained from the patient for publication of this case report and accompanying images. A copy of the written consent is available for review by the Editor-in-Chief of this journal on request.

Authors contributions

JJFM, MLM, and AG were equally responsible for drafting the manuscript, revising the manuscript, and creating the figures. All authors reviewed and approved the final version of the manuscript for submission. MMR, as the senior attending, was involved in all aspects of the manuscript preparation. JJFM assumes full responsibility for all aspects of the work.

Guarantor

Joseph Fernandez-Moure accepts responsibility.

Acknowledgement

We would like to thank Kimberly Jones for her hard work and dedication to the excellence of patient care and resident education.

References

- [1] A.M. Torres, M.M. Ziegler, Malrotation of the intestine, *World J. Surg.* 17 (1993) 326–331.
- [2] C. Berse, Disorders of the intestine and pancreas, in: *Avery's Diseases of the Newborn*, 7th ed., WB Saunders, Philadelphia, 1998, pp. 923.
- [3] M.R. McVay, E.R. Kokoska, R.J. Jackson, S.D. Smith, Jack Barney award. The changing spectrum of intestinal malrotation: diagnosis and management, *Am. J. Surg.* 194 (2007) 712–717, discussion 8–9.
- [4] J.A. Garcelan-Trigo, M. Tello-Moreno, M.J. Rabaza-Espigares, I. Talavera-Martinez, Barber pole sign in CT angiography, adult presentation of midgut malrotation: a case report, *Iran. J. Radiol.* 12 (2015) e17853.
- [5] Ladd W.E. Surgical diseases of the alimentary tract in infants. 1936.
- [6] O.F. Emanuwa, A.A. Ayantunde, T.W. Davies, Midgut malrotation first presenting as acute bowel obstruction in adulthood: a case report and literature review, *World J. Emerg. Surg.* 6 (2011) 22.
- [7] M. von Flue, U. Herzog, C. Ackermann, P. Tondelli, F. Harder, Acute and chronic presentation of intestinal nonrotation in adults, *Dis. Colon Rectum* 37 (1994) 192–198.

- [8] L. Amaral, R. Quintanilha, L. Bernardo, T. Eloi, F. Bento, V. Santos, Intestinal malrotation in the elderly, *Am. Surg.* 75 (2009) 631–633.
- [9] M. von Flüe, U. Herzog, C. Ackermann, P. Tondelli, F. Harder, Acute and chronic presentation of intestinal nonrotation in adults, *Dis. Colon Rectum* 37 (1994) 192–198.
- [10] C.A. Wang, C.E. Welch, Anomalies of intestinal rotation in adolescents and adults, *Surgery* 54 (1963) 839–855.
- [11] R. Badea, N. Al Hajjar, V. Andreica, B. Procopet, C. Caraiani, A. Tamas-Szora, Appendicitis associated with intestinal malrotation: imaging diagnosis features. Case report, *Med. Ultrason.* 14 (2012) 164–167.
- [12] M.B. Forrester, R.D. Merz, Epidemiology of intestinal malrotation, Hawaii, 1986–99, *Paediatr. Perinat. Epidemiol.* 17 (2003) 195–200.
- [13] J.K. Fisher, Computed tomographic diagnosis of volvulus in intestinal malrotation, *Radiology* 140 (1981) 145–146.

Open Access

This article is published Open Access at [sciencedirect.com](https://www.sciencedirect.com). It is distributed under the [IJSCR Supplemental terms and conditions](#), which permits unrestricted non commercial use, distribution, and reproduction in any medium, provided the original authors and source are credited.