



Case Letter

Ketoconazole shampoo-induced hair discoloration[☆]Shelby L. Kubicki, MD^a, Shadi Damanpour, MD^{b,c,*}, Ranon Mann, MD^{b,c}^a Mount Sinai Beth Israel, Department of Medicine, New York, NY, United States^b Albert Einstein College of Medicine, Department of Medicine, Division of Dermatology, Bronx, NY, United States^c Montefiore Medical Center, Bronx, NY, United States

Dear Editors,

Ketoconazole is a synthetic azole compound with topical and systemic antifungal properties. Ketoconazole shampoo is approved by the U.S. Food and Drug Administration for the treatment of tinea versicolor and is commonly used off-label for other conditions (Nizoral, 2017). It has an excellent safety profile, with mild adverse events occurring in only 1% to 7% of patients. The most common side effects are pruritus, dryness of the scalp and hair, and application site reaction (Nizoral, 2017). We present the case of a patient with ketoconazole shampoo-induced pink hair discoloration, a previously unreported adverse event.

A 61-year-old African American woman, who presented with nonscarring hair loss secondary to androgenic alopecia versus telogen effluvium, developed pink hair discoloration 3 weeks after initiating therapy with ketoconazole 2% shampoo. The patient had been applying the shampoo once weekly and rinsing thoroughly after 5 minutes. The pink color persisted despite the use of multiple conditioning treatments. She reported prior chemical hair treatments but had not received one in several years. Upon examination, the patient's previously silver-white strands of hair were visibly pink (Fig. 1A). Light microscopic analysis of a hair sample showed red to pink particles adherent to the hair shaft (Fig. 1B). The patient confirmed that she was not using any other red-colored hair products, and she was instructed to discontinue use of ketoconazole shampoo.

Ketoconazole shampoo-induced hair discoloration has been reported in postmarketing pharmaceutical studies but, to our knowledge, has not been described in the literature (Nizoral, 2017). Ketoconazole shampoo is a red/orange liquid intended for topical application (Nizoral, 2017). It contains FD&C Red No. 40, a synthetic azo dye that has been approved by the U.S. Food and Drug Administration for use in food, cosmetics, and medications (Doell et al., 2016). FD&C Red No. 40 is the only colored ingredient in ketoconazole shampoo and the most likely cause of this patient's hair discoloration.

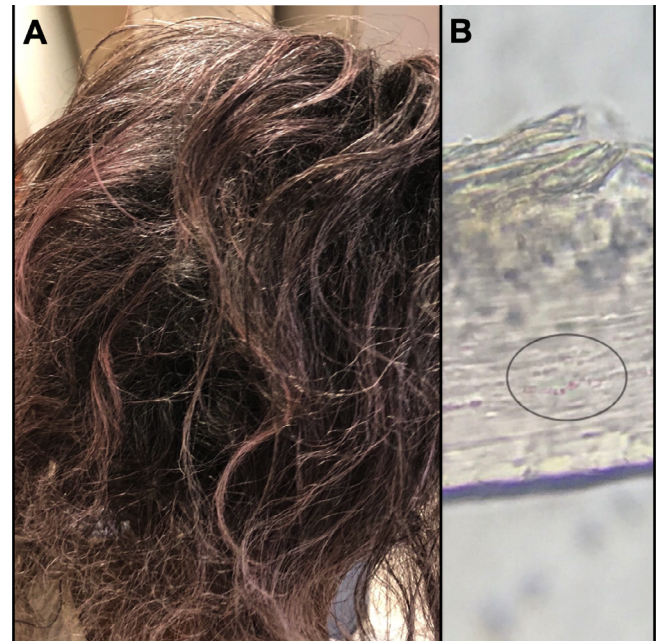


Fig. 1. (A) Pink hair discoloration 3 weeks after initiating ketoconazole shampoo therapy. (B) Microscopic hair analysis showing red particles adherent to the hair shaft.

We hypothesize that our patient had a specific environmental exposure, such as contaminated water, with which FD&C Red No. 40 reacted. Current research is focused on extracting synthetic azo dyes from food products and contaminated water sources (Rovina et al., 2016). In the process, researchers have identified a number of compounds that bind FD&C Red No. 40. In theory, if our patient was exposed to a compound known to bind red dye, this could cause pigment deposition in the hair. Shampoos and topical creams that contain selenium sulfide, tar, and minoxidil are also known to cause hair discoloration (Crowley and Cohen, 2016). These medications primarily cause yellow or green hair discoloration. Similar to synthetic dye and henna, the pigment may bind to keratin in the hair shaft (Trüeb, 2006).

[☆] No human subjects were included in this study. No animals were used in this study.

* Corresponding author at: Albert Einstein College of Medicine, Department of Medicine, Division of Dermatology, 3411 Wayne Avenue, 2nd floor, Bronx, NY 10467, United States.

E-mail address: sdamanpo@montefiore.org (S. Damanpour).

In this patient, the white hairs were more involved, possibly due to the porous nature of dry and aging hair. However, the reason why this patient was affected remains unclear, because many people with light-colored hair use ketoconazole shampoo without developing similar findings. It is important to understand the potential adverse events associated with commonly prescribed topical medications such as ketoconazole to properly counsel patients and, in this case, identify rare causes of hair discoloration. More investigation is needed to determine predisposing risk factors that lead to pigment deposition on the hair cuticle.

Conflict of Interest

None.

Funding

None.

Study Approval

NA.

References

- Crowley CS, Cohen PR. Yellow hair following sequential application of bacitracin zinc and selenium sulfide: report of acquired xanthotrichosis and review of yellow hair discoloration. *Dermatol Online J* 2016;22(6).
- Doell DL, Folmer DE, Lee HS, Butts KM, Carberry SE. Exposure estimate for FD&C colour additives for the U.S. population. *Food Addit Contam Part A Chem Anal Control Expo Risk Assess* 2016;33(5):782–97.
- Nizoral. Ketoconazole shampoo prescribing information. Titusville, NJ: Janssen; December 2017.
- Rovina K, Siddiquee S, Shaarani SM. Extraction, analytical and advanced methods for detection of allura red AC (E129) in food and beverage products. *Front Microbiol* 2016;7:798.
- Trüeb RM. Pharmacologic interventions in aging hair. *Clin Interv Aging* 2006;1(2):121–9.