

## Surgical Treatment of a Tuberculous Abscess of the Chest Wall

Dong-Yoon Keum, M.D., Jae-Bum Kim, M.D., Chang-Kwon Park, M.D.

**Background:** Tuberculous abscess of the chest wall is a very rare disease. Few articles have reported on it and those that have enrolled few patients. To determine the characteristics of this disease and to suggest an optimal treatment strategy, we reviewed patients treated by surgical management. **Materials and Methods:** Between October 1981 and December 2009, 68 patients treated by surgical management for a tuberculous abscess of the chest wall were reviewed retrospectively. **Results:** Of 33 men and 35 women, 31 patients had a current or previous history of tuberculosis. The main complaints were chest pain, a palpable mass, pus discharge, and coughing. A preoperative bacteriologic diagnosis was performed in 12 patients. Abscess excision was performed in 54 cases, abscess cavity excision and partial rib resection in 13, and abscess excision and partial sternum and clavicle excision in 1 case. Postoperative wound infection was noted in 16 patients and a secondary operation was performed in 1 patient. Recurrence occurred in 5 patients (7.35%). Reoperation with abscess excision and partial rib resection was performed in all of the 5 cases. **Conclusion:** Complete excision of the abscess and primary closure of the wound with obliteration of space would decrease postoperative complications. Anti-tuberculosis medication may reduce the chance of recurrence.

Key words: 1. Tuberculosis  
2. Abscess  
3. Chest wall

### INTRODUCTION

The incidence of tuberculosis is decreasing with proper medication and the improved economic and environmental status of the Republic of Korea. Skeletal tuberculosis is not frequent and chest wall tuberculosis is very rare [1]. The incidence of extrathoracic tuberculosis is about 15% to 20% of all tuberculosis, and in bone and joint involvement, below 2%. Chest wall tuberculosis has been reported to be 1% to 10% of skeletal tuberculosis cases. Most patients with a tuberculous abscess of the chest wall do not complain of specific signs or symptoms, and it is difficult to diagnose and

often misdiagnosed as another benign or malignant disease of the thoracic cage [2]. Also, given that this type of abscess often fails to respond to anti-tuberculosis medication, a proper combination of medical and surgical management is very important to handle it. However, few reports have been published regarding tuberculous abscesses of the chest wall, and most reports that provide a clinical presentation and optimal treatment strategy for this disease have enrolled only a small number of patients [3-5]. The purpose of this study was to evaluate the characteristics of this disease and determine the role of surgery in the management of tuberculous abscesses of the chest wall. We reviewed 68 patients who underwent

Department of Thoracic and Cardiovascular Surgery, Keimyung University Dongsan Medical Center, Keimyung University School of Medicine  
Received: January 26, 2012, Revised: February 15, 2012, Accepted: February 28, 2012

Corresponding author: Dong-Yoon Keum, Department of Thoracic and Cardiovascular Surgery, Keimyung University Dongsan Medical Center, Keimyung University School of Medicine, 56 Dalseong-ro, Jung-gu, Daegu 700-712, Korea  
(Tel) 82-53-250-7450 (Fax) 82-53-250-7307 (E-mail) [kdy@dsmc.or.kr](mailto:kdy@dsmc.or.kr)

© The Korean Society for Thoracic and Cardiovascular Surgery. 2012. All right reserved.

© This is an open access article distributed under the terms of the Creative Commons Attribution Non-Commercial License (<http://creativecommons.org/licenses/by-nc/3.0>) which permits unrestricted non-commercial use, distribution, and reproduction in any medium, provided the original work is properly cited.

surgical treatment of tuberculous abscess of the chest wall and analyzed the characteristics of the patients, method of surgery, results, operative complications, and postoperative treatment.

## MATERIALS AND METHODS

From October 1981 to December 2009, 68 patients with tuberculous abscess of the chest wall were surgically treated in our institution. Retrospective analysis focusing on their clinical features, diagnostic methods, operative methods, and postoperative management was performed. Preoperative diagnosis of the disease was made upon the history taking, physical examination, laboratory examination, and radiologic findings including computed tomography (CT) of the chest and a fistulogram in selected patients. Preoperative bacteriologic studies using acid fast bacilli staining, polymerase chain reaction, or culture were not performed routinely. Confirmation of diagnosis was made by a pathologic examination showing caseous granulomatous necrosis, Langhan's giant cells, or tuberculous bacilli on the operative specimens. Patient with empyema necessitatis were excluded from this study. The study protocol was approved by our institutional review board, and all data were collected through patient records.

## RESULTS

The study included 33 men and 35 women, with ages ranging from 17 to 74 years (mean, 39.98±4.09). Thirty-one patients (45.6%) had a past or current history of tuberculosis. Among these patients, 10 had a past history of tuberculous pleurisy, 1 of renal tuberculosis, 1 of meningeal tuberculosis, and 3 of spinal tuberculosis. One patient had a history of tuberculous abscess of the chest wall 20 years earlier; at that time, excision of the cavity and partial rib resection was performed at another institution. The chief complaints of the patients were pain or tenderness at the lesion site in 40, a palpable mass in 24 patients, pus discharge in 3, and coughing with blood-tinged sputum in 1. The lesion site was the right chest wall in 40 (58.8%), the left in 26 (38.3%), and the median in 2 (2.9%). In 64 patients, the lesion was single, and multiple lesions (triple in 1 patient and double in 3) were

**Table 1.** Clinical features of patients with tuberculous abscess of the chest wall

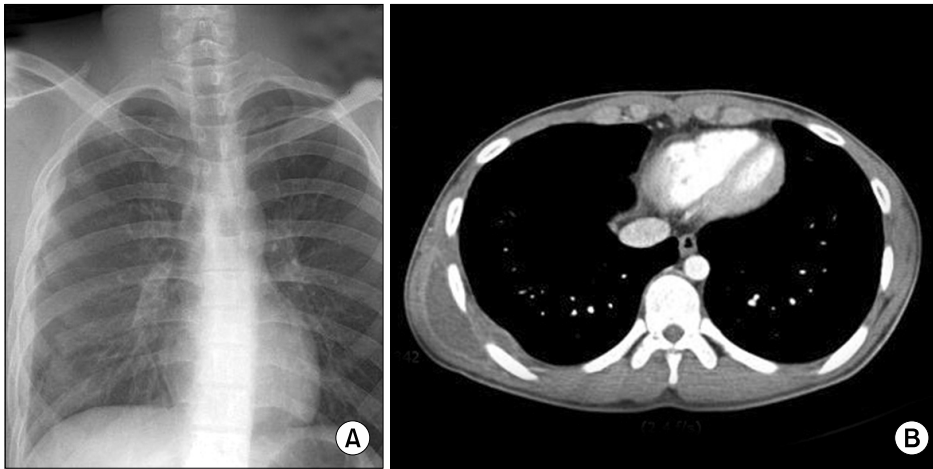
Profile	No. of patients
Age	17–74 (mean, 39.98±4.09)
Sex (male:female)	33:35
Preoperative symptoms	
Pain and tenderness	40
Palpable mass	24
Pus discharge	3
Cough, blood tinged sputum	1
Lesion site	
Right	40 (58.8)
Left	26 (38.3)
Median	2 (2.9)
No. of lesions	
Single	64 (94.1)
Multiple	4 (5.9)
History of tuberculosis	31 (45.6)
Preoperative medication	31 (45.6)

Values are presented as number or number (%).

found in 4 patients (Table 1).

Preoperative chest CT was performed for 53 patients and a preoperative fistulogram was performed for 4 patients (Fig. 1). Preoperative bacteriologic diagnosis was performed in 12 patients using acid fast bacilli fluorochrome staining, polymerase chain reaction, or a culture of pus for tuberculosis bacilli. In 31 patients, preoperative anti-tuberculous medication was performed, with the medication period ranging from 2 to 32 weeks. When the patients had no history of anti-tuberculous medication for tuberculosis and a tuberculous abscess was highly suspected, anti-tuberculosis medication was administered for 2 weeks. In cases of a rupture or impending rupture of the cavity, the operation was done without medication.

The main goal of the surgery was complete excision of the abscess cavity and surrounding tissue. We performed segmental rib or cartilage resection in case of any of the following. 1) Involvement of the periosteum or perichondrium such as bony destruction or periosteal granulation tissue formation was suspected. 2) The abscess cavity in the chest wall made a fistulous track to the pleural cavity forming a loculated pleural abscess. 3) The subpleural abscess cavity was large, thus requiring the complete obliteration of the pleural space.



**Fig. 1.** Chest posteroanterior (PA) view and computed tomography (CT) section in patient with a tuberculous abscess of the chest wall. (A) A 21-year-old male with a slowly growing mass reveals pleural thickening and a pleural mass-like lesion on chest PA film. (B) A CT scan shows a low attenuating density lesion in the latissimus dorsi muscle communicating with the pleural space.

**Table 2.** Surgical methods for tuberculous abscess of the chest wall

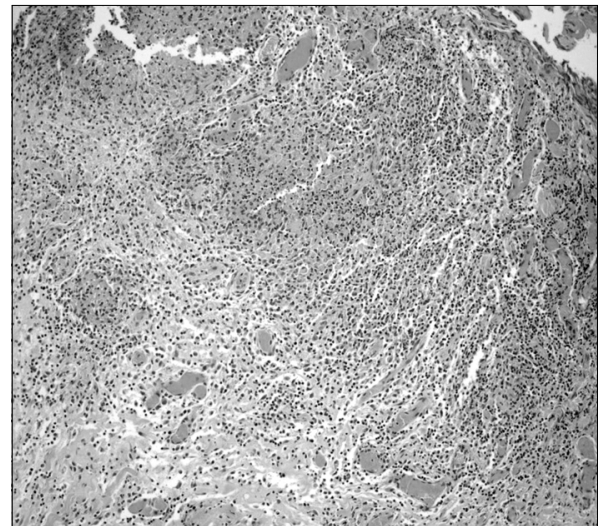
Methods of surgery	No. of patients
AE	54 (79.4)
AE+RR	12 (17.6)
AE+RR+pulmonary resection	1 (1.5)
AE+sternum, clavicle partial resection	1 (1.5)

Values are presented as number (%).

AE, abscess excision; RR, rib resection.

In total, 14 rib segments were obtained from 13 patients. In 1 patient, partial resection of the sternum and clavicle was performed. After excision of the abscess, massive irrigation of the wound and meticulous obliteration of dead space using adjacent muscle mobilization or a pedicled flap was performed in every operation. Primary closure of the wound was performed in every case, and the chest wound was closed with a Penrose drain in the chest wall or a chest tube drain in the pleural cavity. The surgical methods were as follows: Abscess cavity excision in 54 (79%), abscess cavity excision with concomitant partial rib resection in 12 (17.6%), wedge resection of the lung parenchyme with abscess excision and rib resection in 1 (1.5%), and clavicular and sternal partial resection with abscess cavity excision in 1 (1.5%). No musculoskeletal reconstruction was performed (Table 2).

There was no operative mortality. Postoperative wound infection was noted in 16 patients (11.24%) and managed with conservative dressing and delayed wound closure. However, in 1 patient, after abscess cavity excision only, after 3



**Fig. 2.** Microscopic findings of cold abscess showing hemorrhage and necrosis with surrounding inflammation. Multinucleated giant cells are seen (H&E, ×100).

months of conservative management, reoperation for fistulectomy and partial rib excision was done. Respiratory complications such as pneumonia or atelectasis were noted in 4 patients.

The pathologic examination confirmed the disease in all cases. Typical microscopic features with epithelioid histiocytes and caseous granulomatous necrosis were found (Fig. 2).

In all patients, postoperative anti-tuberculosis medication was given for 6 to 19 months including the preoperative medication periods. The regimen was based on triple (isoniazid, ri-

**Table 3.** Characteristics of patients who recurred after the first operation

Patient	1st OP	Lesion (1st OP)	Recur period (mo)	Preop medication	Rib involve	Wound infection	Treatment	Outcome
1	AE	Single	34	(-)	(-)	(+)	AE+RR	Cure
2	AE	Single	6	(-)	(-)	(+)	AE+RR	Cure
3	AE	Single	38	(-)	(-)	(+)	AE+RR	Cure
4	AE	Single	19	7 mo	(-)	(-)	AE+RR	Cure
5	AE+RR	Multiple	6	5 mo	(-)	(-)	AE+RR	Cure

OP, operation; AE, abscess excision; RR, rib resection.

fampin, ethambutol) or quadruple (triple + pyrazinamide) therapy.

The disease recurred in 5 patients (7.35%) between 6 months and 38 months postoperatively, and all these 5 patients underwent a second operation. The surgical method of the second operation in all of the recurred patients was abscess cavity excision and partial rib resection. Four patients had single site recurrence and 1 had recurrence at 2 sites. In 4 patients, the abscess cavity excision was performed at the first operation, while concomitant rib resection was performed in 1 patient at the first operation. In 3 patients, a post-operative wound problem occurred at the first operation, but in all of the patients the abscess recurred in a location other than the previous site. Only in the 1 patient with multiple lesions at the first operation did one abscess recur at a previous site and one at a newly formed site (Table 3).

## DISCUSSION

Tuberculous abscesses of the chest wall are not frequently encountered and constitute less than 10% of skeletal tuberculosis. The presentation of this disease is a progressively enlarging mass with or without pain. Sometimes abscesses make a fistulous tract to the pleural cavity and destroy underlying bone or cartilage.

There are three mechanisms in the pathogenesis of a tuberculous abscess of the chest wall [6]: 1) direct extension from the underlying pleural or pulmonary tuberculosis, 2) direct extension from lymphadenitis of the chest wall, and 3) hematogenous dissemination from dormant tuberculous lesions. In the second case, mycobacterium tuberculosis in the pulmonary parenchyma or visceral pleura invades the pleural space

forming pleuritis. Lymphatics in the pleural space develop by inflammation and finally communicate to the lymphatics of the chest wall, forming caseous necrosis or a fistulous tract. The third case can result from iatrogenic spread of tuberculosis to the chest wall during aspiration or drainage of tuberculous pleurisy or empyema. In our study, 22 (32.4%) patients had a history of tuberculosis or current tuberculosis. In general, retrospective studies based on medical records have the limitation that it is difficult to determine the exact mechanism of the tuberculous abscess of the chest wall.

These lesions are generally solitary, but in some patients multiple lesions were found in two or more sites. Faure et al. [6] reported 16 single-lesion patients of 18 patients. In our study, 60 of 64 patients had a single location.

The diagnosis of tuberculous abscess of the chest wall is difficult and often diagnosed by postoperative pathologic examination. Preoperatively, it can be confirmed by detecting acid-fast bacilli, polymerase chain reaction, or culture of pus in the abscess. Many authors recommend needle aspiration or incisional biopsy to confirm the tuberculous disease or to exclude other inflammatory disease [2,4-6]. Faure et al. [6] reported a diagnostic rate of only 36.3% by needle aspiration. Sakuraba et al. [5] reported that 9 (62.29%) of 13 patients had positive acid-fast bacilli tests, 4 (28.57%) had positive polymerase chain reaction, and 6 (42.86%) had positive cultures from preoperative specimens. However, needle aspiration diagnosis of tuberculosis is not as reliable and some authors recommend surgical biopsy. Kim et al. [7] reported that only 3 of 80 patients had a preoperative bacteriologic diagnosis, and a tuberculous cold abscess was confirmed by postoperative pathologic examination in all cases. With this result, they recommended that the diagnosis can be made without a

preoperative bacteriologic examination in geographic areas where the prevalence of tuberculosis remains high; instead, it can be clinically diagnosed by the clinical features of the chest wall abscess, history of pulmonary tuberculosis, and typical CT findings. Cho et al. [8] recommended needle aspiration or biopsy preoperatively when the patient has no past history of tuberculosis and no concomitant active pulmonary lesions, when CT findings show poorly demarcated mass lesions. In this study, only 12 patients were diagnosed preoperatively with acid-fast bacilli staining, polymerase chain reaction, or culture of bacilli, and the other cases were diagnosed with clinical information and CT findings, and confirmed with postoperative pathologic examination.

A chest CT should be performed for every patient to evaluate the extent of abscess cavities and the status of the ribs, sternum, cartilage, and pleural space. The CT also provides information on the functional state of the lung parenchyma and thoracic cavities, and concomitant diseases, and excludes other inflammatory or tumor lesions [9]. Brown [10] noted that tuberculous abscess of chest wall can be easily diagnosed in endemic geographic areas in cases with a chest wall abscess with rib destruction and an extrapleural soft tissue mass lesion on chest CT. Cho et al. [8] classified the CT findings of tuberculous abscess of the chest wall as follows: 1) a lesion confined to the chest wall, 2) a lesion confined to the inner chest wall beneath the ribs and also protruding into the pleural space, 3) a lesion involving most of the chest wall and also protruding into the pleural space. With this classification, they found that more a superficial location of the abscess did not exclude the risk of rib involvement. In our study, chest CT films before the mid-1990s' were not available due to storage problems, and radiologic reports of chest CT were not sufficient to classify the type of the disease. A fistulogram with contrast media was taken in some patients, but was no longer done once the CT scan became popular in evaluating these patients.

Anti-tuberculosis medication may be very important. A few studies have reported successful treatment with anti-tuberculosis chemotherapy alone [2,3,11], but many authors have reported frequent recurrence after medication only [5,6]. Hence, medical treatment alone is not suitable for this disease; many authors recommend a combination of medical and

surgical management to reduce the recurrence. On the other hand, Faure et al. [6] strongly suggested chemotherapy when a tuberculous infection is confirmed or highly suspected, but fails to improve with 1 to 3 months medication, and when it worsens, surgical intervention is indicated. In our study, 31 patients were treated with anti-tuberculosis medication preoperatively with a medication period ranging from 2 to 32 weeks, but no patients were treated with medication only. Among 5 recurred patients, 2 were preoperatively medicated, and 3 were not medicated.

The methods of surgical treatment are controversial. Weissberg [12] mentioned in his commentary that this disease is best treated with antimicrobials and drainage, with debridement and excision reserved for the most extensive cases. The optimal surgical approach consists of excising the abscess and primary closure of the wounds, but the extent of resection is not defined. However, complete excision of the abscess including the abscess wall, fistulous tract, enlarged lymph node, and adjacent bony structure avoiding unnecessary extensive chest wall resection would be important to reduce complications and recurrence [13-15]. If there is any bony destruction or suspicious periosteal granulation tissue exists, if a fistulous tract overlays the rib or sternum, or for complete removal of underlying pleural abscess, the rib should be partially removed. Curettage of the infected pleural peel should be performed. After extensive debridement of the lesion, the space should be obliterated meticulously. If any dead space remains, a postoperative wound infection or chronic sinus formation can occur. In our study, we noticed a high incidence of postoperative wound infection (11.24%), which may be due to inadequate control of dead space. In 1 patient, reoperation including fistulectomy and partial rib resection was performed after 3 months of conservative management. Adequate muscle mobilization or a flap and small indwelling catheter would decrease the incidence of wound infection. Three other patients recurred among 16 postoperative wound infection patients, but at new sites.

Kim et al. [7] classified patients into a debridement and drainage group and a complete resection group, and they found a higher recurrence rate in the debridement and drainage group (40%) than the complete resection group (9.2%). Paik et al. [13] reported a 16% recurrence rate in abscess ex-

cision patients, but only a 1.6% recurrence rate in the rib resection group. These means a wide and complete resection would decrease recurrence.

Postoperative medical treatment is mandatory for an acceptable cure rate. The duration of anti-tuberculosis therapy is controversial, but, a minimum of 6 to 9 months of isoniazide- and rifampin-based therapy would be needed [14,15]. Paik et al. [13] suggested medication for a minimum of 12 months especially in endemic geographical areas.

## CONCLUSION

We recommend preoperative medication and complete excision of tuberculous abscess of the chest wall. If periosteal involvement of the abscess is suspected, excision of the skeletal structure should be performed. To decrease postoperative morbidity, complete removal of the abscess and obliteration of any dead space is mandatory. Adequate postoperative medication may reduce the chance of recurrence.

## REFERENCES

1. Enarson DA, Ashley MJ, Grzybowski S, Ostapkowicz E, Dorken E. *Non-respiratory tuberculosis in Canada. Epidemiologic and bacteriologic features.* Am J Epidemiol 1980; 112:341-51.
2. Hsu HS, Wang LS, Wu YC, Fahn HJ, Huang MH. *Management of primary chest wall tuberculosis.* Scand J Thorac Cardiovasc Surg 1995;29:119-23.
3. Chen CH, Shih JF, Wang LS, Perng RP. *Tuberculous subcutaneous abscess: an analysis of seven cases.* Tuber Lung Dis 1996;77:184-7.
4. Kuzucu A, Soysal O, Gunen H. *The role of surgery in chest wall tuberculosis.* Interact Cardiovasc Thorac Surg 2004;3: 99-103.
5. Sakuraba M, Sagara Y, Komatsu H. *Surgical treatment of tuberculous abscess in the chest wall.* Ann Thorac Surg 2005;79:964-7.
6. Faure E, Souilamas R, Riquet M, et al. *Cold abscess of the chest wall: a surgical entity?* Ann Thorac Surg 1998;66: 1174-8.
7. Kim YT, Han KN, Kang CH, Sung SW, Kim JH. *Complete resection is mandatory for tubercular cold abscess of the chest wall.* Ann Thorac Surg 2008;85:273-7.
8. Cho KD, Cho DG, Jo MS, Ahn MI, Park CB. *Current surgical therapy for patients with tuberculous abscess of the chest wall.* Ann Thorac Surg 2006;81:1220-6.
9. Lee G, Im JG, Kim JS, Kang HS, Han MC. *Tuberculosis of the ribs: CT appearance.* J Comput Assist Tomogr 1993;17: 363-6.
10. Brown TS. *Tuberculosis of the ribs.* Clin Radiol 1980;31: 681-4.
11. Blunt SB, Harries MG. *Discrete pleural masses without effusion in a young man: an unusual presentation of tuberculosis.* Thorax 1989;44:436-7.
12. Weissberg D. *Invited commentary: Cold abscess of the chest wall: a surgical entity?* Ann Thorac Surg 1998;66:1178.
13. Paik HC, Chung KY, Kang JH, Maeng DH. *Surgical treatment of tuberculous cold abscess of the chest wall.* Yonsei Med J 2002;43:309-14.
14. Cho S, Lee EB. *Surgical resection of chest wall tuberculosis.* Thorac Cardiovasc Surg 2009;57:480-3.
15. Tanaka S, Aoki M, Nakanishi T, et al. *Retrospective case series analysing the clinical data and treatment options of patients with a tubercular abscess of the chest wall.* Interact Cardiovasc Thorac Surg 2012;14:249-52.