



Breast reconstruction with donor tissue from the back—an evolution towards customized reconstructive solutions guided by innovative surgery and patient wishes

Gudjon L. Gunnarsson^{1^}, Caroline Lilja^{2^}, Jørn Bo Thomsen^{2^}

¹Plastic Surgical Section, Sørlandet Sykehus Arendal, Arendal, Norway; ²Research Unit of Plastic Surgery, Department of Plastic Surgery, Odense University Hospital & Clinical Institute, University of Southern Denmark, Odense, Denmark

Correspondence to: Jørn Bo Thomsen, MD, PhD. Associate Professor, Research Unit of Plastic Surgery, Department of Plastic Surgery, Odense University Hospital & Clinical Institute, University of Southern Denmark, Sdr. Boulevard 29, 5000 Odense, Denmark.

Email: Joern.Bo.Thomsen@rsyd.dk.

Comment on: Kim H, Eo P, Ryu JY, *et al.* Boomerang latissimus dorsi flap in immediate or delayed breast reconstruction. *Gland Surg* 2023;12:894-904.

Keywords: Breast reconstruction; latissimus dorsi; thoracodorsal artery perforator (TDAP) flap; innovation

Submitted Aug 07, 2023. Accepted for publication Aug 30, 2023. Published online Sep 13, 2023.

doi: 10.21037/gs-23-325

View this article at: <https://dx.doi.org/10.21037/gs-23-325>

The boomerang latissimus dorsi (bLD) flap is the most recent addition to a growing armamentarium of LD flap designs for breast reconstruction (1). Now joining the previously introduced LD flap techniques based on the difference in skin island design; the traditional horizontal, vertical, and extended LD (eLD) utilized for breast reconstruction (2). Baumholtz *et al.* first introduced the boomerang design in the literature in 2002; they extended the traditional horizontal skin island in which the medial part of the flap was elongated vertically in the medial part of the back in close proximity to and along with the vertebra (3). Kim *et al.* apply a boomerang design similarly in order to harvest as much volume from the back as possible, however the design is altered as the horizontal and vertical skin islands is placed in the mid-axillary line along the anterior border of the LD muscle instead of its lumbar portion (1). This may turn out to be an advantage as the skin in the lateral part of the thorax around the mid-axillary line is thinner and more pliable than the thick skin closer to the vertebra. The vascularity is probably more reliable along the anterior muscle border including the descending branch of the thoracodorsal artery along with its

perforators. However, a recent cadaver study by Elzawawy *et al.* showed that the vascularity of the LD muscle is much more variable than anticipated (4). It seems that the typical type 5 vascular pattern is only present in 20% of cases. Thus, maybe this should be taken into consideration in the preoperative planning of flap design including the boomerang design to avoid vascular problems. A design based on the vascular branching pattern of the thoracodorsal vessels and perforators targeted by preoperative color Doppler ultrasonography (5,6). The boomerang design includes areas where excess skin can be found by pinch test; the usual location is often horizontally below the scapula and vertically and posteriorly to the mid-axillary line. The design proposed by Kim *et al.* is therefore sensible if you want to harvest as much tissue as possible, with the least tension for subsequent closure (1).

A major drawback for the traditional musculocutaneous LD flap in breast reconstruction is the limited upper pole fullness. It is therefore not a clear first choice for total autologous breast reconstruction unless combined with fat transplantation or an implant to fill up the breast volume with the additional burden of more operative corrective

[^] ORCID: Gudjon L. Gunnarsson, 0000-0001-7388-9451; Caroline Lilja, 0000-0003-3933-5580; Jørn Bo Thomsen, 0000-0002-7368-6133.

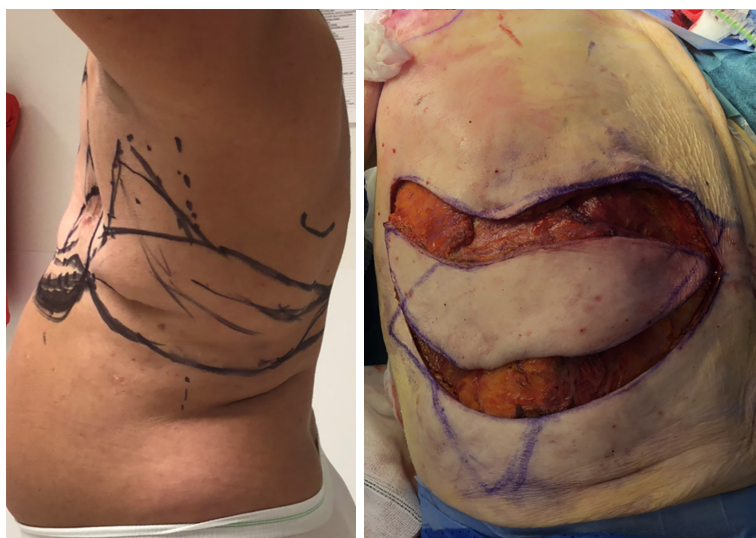

Figure 1 Muscle sparing latissimus dorsi flap with cranial boomerang shape designed to reduce lateral bulk.

procedures. Fat transplantation frequently requires repeated procedures in order to obtain or maintain sufficient volume (7). Implants can be used for augmentation, however, one has as much control over an implant as a housecat and they are equally as reliable, with plans on their own. The boomerang design enables the surgeon to fold the flap in the shape of an implant to create projection and fill both the upper and lower pole as opposed to the traditional flap, which mainly covers the inferior, and lateral half of the breast most often leaving the upper pole empty. The boomerang design may potentially provide patients with an alternative for autologous breast reconstruction without the addition of an implant, which is often necessary to obtain sufficient volume for reconstruction, when using the traditional LD techniques.

We mentioned that the vascularity of the tissue along the anterior border of the LD muscle is more reliable than the posterior part that crosses over to the lumbar and paraspinous angiosomes, which probably makes the addition of a vertical portion more attractive. Iginio Tansini, who pioneered the use of the LD flap, revised his original horizontal design to a vertical design of the LD flap for reconstruction of the breast (8). The scar on the other hand is rather visible and does not hide anatomically at all. Experience gained from body contouring procedures using lateral mid axillary incision have been largely dissatisfying due to the vulnerable anatomy of cutaneous nerves running laterally causing painful scarring.

A drawback to the use of any type of LD flap, including

the bLD flap is donor site morbidity, when the entire LD muscle is included in the design. Involvement of larger portions of the muscle seem to increase the risk of donor site morbidity (9-11). Our studies amongst others have shown the eLD to be associated with more donor site morbidity of the shoulder and arm and more seroma formation, compared to the other types of LD flaps; classic LD flaps, and muscle sparing LD (MS-LD) flaps, not to mention the propeller thoracodorsal artery perforator (TDAP) flaps and the classic TDAP flap (12). In our practice, we have taken the benefits of the vascularity and available tissue to evolve a reliable propeller flap and a MS-LD flap that has a boomerang shape along the anterior border of the LD muscle upwards towards the axilla. This allows for an easy dissection and reduces the lateral bulk formation, as the superior portion of the flap is included in the lateral part of the reconstruction, *Figure 1*. The paper by Kim *et al.* seems to be a natural evolution of the LD flap in experienced hands, we agree with the authors conclusions so far and commend their efforts (1). The question that remains, whether the donor site morbidity measures up to the possible benefits/morbidity associated with the other reconstructive options? This remains to be tested over time with larger studies and longer follow-up. Until more is known about the bLD, patients need to be well informed about the possible benefits and potential limitations. However, multilobed designs of LD-flaps is gaining popularity for customized reconstruction of defects as shown in another recent study by Zhang *et al.* (13).

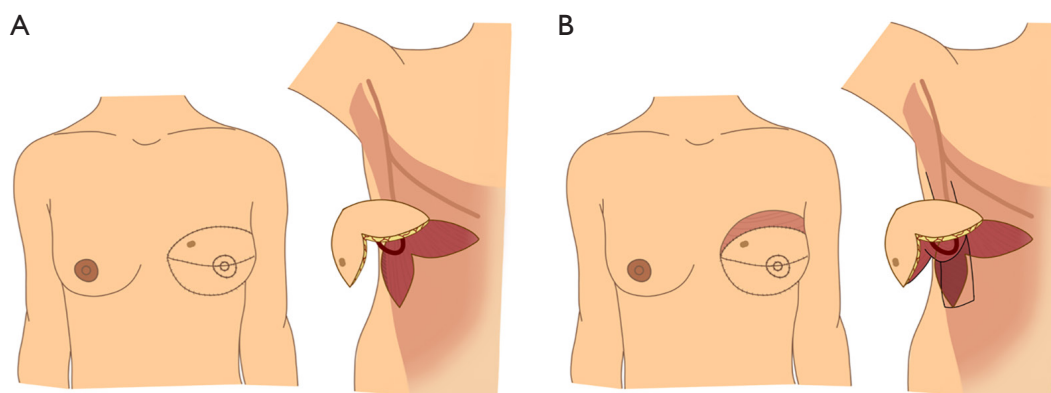


Figure 2 Illustration of suggestions for design of: (A) boomerang thoracodorsal artery perforator flap and (B) boomerang muscle sparing latissimus dorsi flap.

However, we must be aware, that the donor site scar does matter to patients as shown in a study by Rha *et al.*, and it seems patient with a vertical scar is more satisfied than patients with other types of scars (14).

Overall, new innovative techniques are inspiring and at the same time, it also reminds us, that we have to consider all options prior to reconstruction of our patients. First and foremost, we have to ask the patients, what they want and what they expect regarding the reconstruction and the possible donor site(s) (14). In doing so we have to consider and examine the vascularity of the planned donor site and in doing so, evaluate the possible reconstructive options (4). Reconstructive options which seem to evolve towards more customized solutions (13).

We congratulate the authors on their innovative approach utilizing a maximum of the available donor tissue from the back to achieve a satisfying one-stage autologous breast reconstruction. It is an intriguing thought to examine in future studies whether a boomerang design can be raised without the entire LD muscle, as a muscle-sparing variant or even as a perforator-based boomerang TDAP, propeller or classic? It is almost bound to follow, *Figure 2*.

Acknowledgments

Funding: None.

Footnote

Provenance and Peer Review: This article was commissioned by the editorial office, *Gland Surgery*. The article did not undergo external peer review.

Conflicts of Interest: All authors have completed the ICMJE uniform disclosure form (available at <https://gs.amegroups.com/article/view/10.21037/gS-23-325/coif>). JBT serves as an unpaid Honorary Editor-in-Chief of *Gland Surgery* from November 2022 to October 2024. The other authors have no conflicts of interest to declare.

Ethical Statement: The authors are accountable for all aspects of the work in ensuring that questions related to the accuracy or integrity of any part of the work are appropriately investigated or resolved.

Open Access Statement: This is an Open Access article distributed in accordance with the Creative Commons Attribution-NonCommercial-NoDerivs 4.0 International License (CC BY-NC-ND 4.0), which permits the non-commercial replication and distribution of the article with the strict proviso that no changes or edits are made and the original work is properly cited (including links to both the formal publication through the relevant DOI and the license). See: <https://creativecommons.org/licenses/by-nc-nd/4.0/>.

References

1. Kim H, Eo P, Ryu JY, et al. Boomerang latissimus dorsi flap in immediate or delayed breast reconstruction. *Gland Surg* 2023;12:894-904.
2. Thomsen JB, Gunnarsson GL. The evolving breast reconstruction: from latissimus dorsi musculocutaneous flap to a propeller thoracodorsal fasciocutaneous flap. *Gland Surg* 2014;3:151-4.
3. Baumholtz MA, Al-Shunnar BM, Dabb RW. Boomerang

- flap reconstruction for the breast. *Ann Plast Surg* 2002;49:44-8; discussion 48-9.
4. Elzawawy EM, Kelada MN, Al Karmouty AF. Design of Mini Latissimus Dorsi Flap Based on Thoracodorsal Vascular Patterns. *Ann Plast Surg* 2018;80:607-15.
 5. Ibrahim RM, Gunnarsson GL, Akram J, et al. Color Doppler ultrasonography targeted reconstruction using pedicled perforator flaps—a systematic review and meta-analysis. *Eur J Plast Surg* 2018;41:495-504.
 6. Gunnarsson GL, Tei T, Thomsen JB. Color Doppler Ultrasonography-Targeted Perforator Mapping and Angiosome-Based Flap Reconstruction. *Ann Plast Surg* 2016;77:464-8.
 7. Kristensen RN, Gunnarsson GL, Børsen-Koch M, et al. Fast and simple fat grafting of the breast. *Gland Surg* 2015;4:572-6.
 8. Maxwell GP. Iginio Tansini and the origin of the latissimus dorsi musculocutaneous flap. *Plast Reconstr Surg* 1980;65:686-92.
 9. Rindom MB, Gunnarsson GL, Lautrup MD, et al. Shoulder-related donor site morbidity and patient-reported satisfaction after delayed breast reconstruction with pedicled flaps from the back: A comparative analysis. *J Plast Reconstr Aesthet Surg* 2018;71:1108-15.
 10. Rindom MB, Gunnarsson GL, Lautrup MD, et al. Shoulder-related donor site morbidity after delayed breast reconstruction with pedicled flaps from the back: An open label randomized controlled clinical trial. *J Plast Reconstr Aesthet Surg* 2019;72:1942-9.
 11. Rindom MB, Gunnarsson GL, Lautrup MD, et al. Good health-related quality-of-life and high patient-reported satisfaction after delayed breast reconstruction with pedicled flaps from the back. *J Plast Reconstr Aesthet Surg* 2021;74:1752-7.
 12. Thomsen JB, Rindom MB, Rancati A, et al. Thoracodorsal artery flaps for breast reconstruction—the variants and its approach. *Arch Plast Surg* 2021;48:15-25.
 13. Zhang YX, Messmer C, Pang FK, et al. A novel design of the multilobed latissimus dorsi myocutaneous flap to achieve primary donor-site closure in the reconstruction of large defects. *Plast Reconstr Surg* 2013;131:752e-8e.
 14. Rha EY, Jeon HH, Park SH, et al. Defect-Oriented Versus Back Scar-Oriented Flap Design in Breast Reconstruction with Latissimus Dorsi Musculocutaneous Flap: A Patient-Reported Satisfaction Outcome Comparison Using BREAST-Q. *Aesthetic Plast Surg* 2023. [Epub ahead of print]. doi: 10.1007/s00266-023-03385-0.

Cite this article as: Gunnarsson GL, Lilja C, Thomsen JB. Breast reconstruction with donor tissue from the back—an evolution towards customized reconstructive solutions guided by innovative surgery and patient wishes. *Gland Surg* 2023;12(9):1137-1140. doi: 10.21037/gS-23-325