

THE USE OF REFORMATTED CONE BEAM CT IMAGES IN ASSESSING MID-FACE TRAUMA, WITH A FOCUS ON THE ORBITAL FLOOR FRACTURES

RALUCA ROMAN¹, MIHAELA HEDEȘIU¹, FLOAREA FILDAN¹,
ROBERT ILEȘAN¹, DIANA MITEA¹, CRISTIAN DINU¹, MIHAELA BĂCIUȚ²

¹Department of Cranio-Maxillofacial Surgery and Radiology, Faculty of Dentistry, University of Medicine and Pharmacy Iuliu Hațieganu, Cluj-Napoca, Romania

²Department of Maxillofacial Surgery and Implantology, Faculty of Dentistry, Iuliu Hațieganu University of Medicine and Pharmacy, Cluj-Napoca, Romania

Abstract

Background and aim. This study aims at evaluating the reliability on specific multi-planar cone beam computer tomography (CBCT) reconstruction in the orbital floor fractures.

Methods. CBCT examination of the mid-face fractures area involving the floor of the orbit was performed in a number of 93 trauma patients by two independent radiologists. Both radiologists assessed the axial, coronal and sagittal sections and also the oblique coronal and sagittal extracted sections evaluating the location of the orbital fractures, its size and displacement, the involvement of the infra-orbital foramen, herniation of fat or muscle within the maxillary sinus, the overall type of the fracture and the implication of lateral or medial orbital wall. We also registered the section that provided better confidence of both examiners in visualizing the fracture of the orbit floor and the presence of herniated soft tissue, on different reformatted sectioning.

Results. The presence of pure fracture of the orbital floor was detected in 11% of patients. The association of the orbital fractures with the zygomatic fractures was identified in the majority of the patients. In 86% of patients the displacement of the floor of the orbit was visualized, and in almost 30% of cases more than 50% of the orbital floor was involved in the fracture. Regarding the confidence between examiners, they were more confident using the oblique sagittal CBCT reformatted images for fracture detection and bone displacement evaluation, as for the soft tissue herniation the oblique coronal sections provided the highest level of confidence.

Conclusion. Mid-face trauma involves the orbital floor in the majority of situations. CBCT allows to obtain oblique images extracted from the three dimensional (3D) data that provide high confidence level in assessing pure orbital floor fractures.

Keywords: CBCT, multi-planar extracted images, mid-face trauma, orbital fracture

Background and aims

The maxillofacial trauma involves, in the majority of the cases, a mid facial fracture. According to several studies in the literature the zygomatic complex fractures

are the most encountered ones, followed by the fractures of the orbital floor, that can cause severe complications [1-3].

Correct evaluation of the site of the orbital fracture, the pure involvement of the orbital floor obtaining a detailed measurement of the bone displacement and a throughout appreciation of the possibly herniated tissue makes consist in

Manuscript received: 15.10.2015

Accepted: 24.11.2015

Address for correspondence: mhedesiu@gmail.com

an important factor in deciding the best treatment approach. The use of surgical approach is decided based on several clinical ocular factors and the imaging data regarding the location, size, walls involved and the presence and type of tissue herniation within the sinus [4].

Sagittal section plane on computer tomography (CT) was stated by several studies as the main plane to be able to appreciate correctly the orbital floor fractures. Direct sagittal examination was discussed as being closer to the need of the examiners than the reconstructed one from the axial images. The study of Manchio et al. used five different observers to assess orbital floor fractures in different planes possibly to be obtained with computer tomography and the conclusion was that supplementary views were needed for the surgeon to thoroughly appreciate the fracture area and its characteristics [5]. Still, the sagittal or coronal plane of the orbit itself cannot be provided by the computer tomography, even if the equipment is a high resolution one, due to the fact that the multi-planar reconstruction images from the axial images are in the coronal and sagittal plane of the head.

Brisco et al. in their study compared CT with CBCT, as a volume data acquisition, in orbital trauma with regard to image quality and radiation dose, and found similar percentages in detectability of overall orbital fractures in favor of CBCT. They did not make the difference between the walls of the orbit that were involved. The radiation dosage measured to the eye was lowered to a half in CBCT then in CT, thus making this imaging tool a good choice in fine diagnosing orbital fractures that are not complicated with the back of the eye hematoma [6].

The advantages offered by CBCT were investigated also by Tsao et al. and Hatcher et al. and the results were also in its favor in evaluating the treatment approach for uncomplicated cases if it is used a customized protocol. The precision of the measurement seems to be higher on volumetric CT than the classic one, facts that in case of the infra-orbital fractures with bone displacement are very important in planning the treatment protocol [7,8].

The aim of this study was to assess, by using the Cone Beam CT multi-planar extracted images and oblique in axis approach, the presence of orbital floor fractures in different mid-face fracture association and to determine the confidence of different planes of examination in depicting preoperatively the site of fracture, dimension of bone displacement and the presence of soft tissue herniation in the maxillary sinus, elements that could improve the surgical planning.

Material and methods

For this study, a number of 93 patients with orbital floor fracture were selected from the maxillo-facial trauma patients examined with CBCT at the Maxillo-facial and Radiology department of the Dental Faculty.

The CBCT imaging was performed with a NewTom 3G scanner (Quantitative Radiology, Verona, Italy, pixel size: 0.180 mm). Independent evaluation was conducted by two maxillo-facial radiologists, using the default NNT viewer. The protocol of viewing the images consisted in two steps. First one was to evaluate the axial, coronal and sagittal extracted planes in the multiplanar (MPR) three classic axis of the skull (figure 1, figure 2).

The next step was to investigate the site of the orbital fracture in oblique coronal and sagittal planes, all extracted by designing the sections set using the axis of the orbit (figures 3,4). Additional inclination in the curve could be added to the designed extracted set of sections, in order to appreciate thoroughly possibly associated fracture sites, as seen in figure 5 and figure 6.

The elements evaluated were: the overall type of the fracture, the location of the orbital fractures and implication of lateral or medial orbital wall, the defect position on the floor of the orbit and its size and displacement, the involvement of the infra-orbital foramen and also the presence or absence of fat or muscle herniation within the maxillary sinus and its degree. Examples of the displacement evaluation and herniation measurement are seen in figure 7 and figure 8.

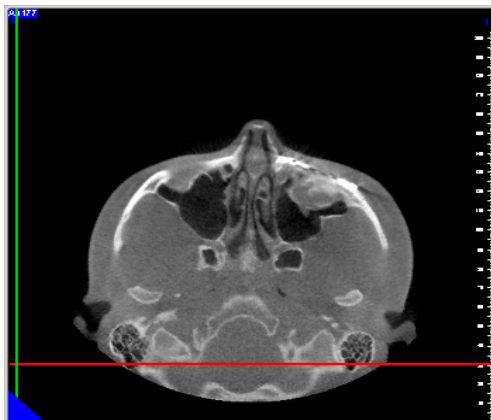

Figure 1. CBCT axial view from the raw data.

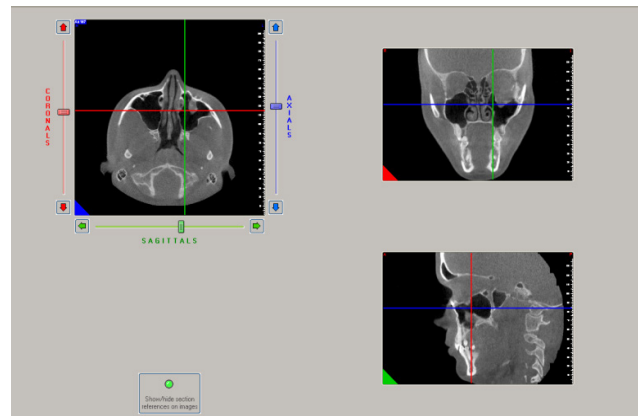


Figure 2. CBCT. MPR representation in the three planes of the head.

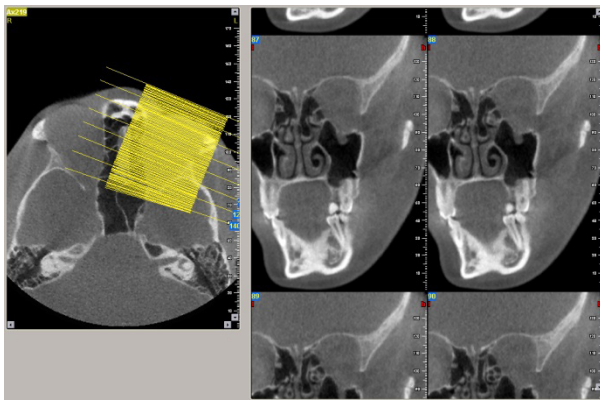


Figure 3. CBCT oblique coronal extracted sections.

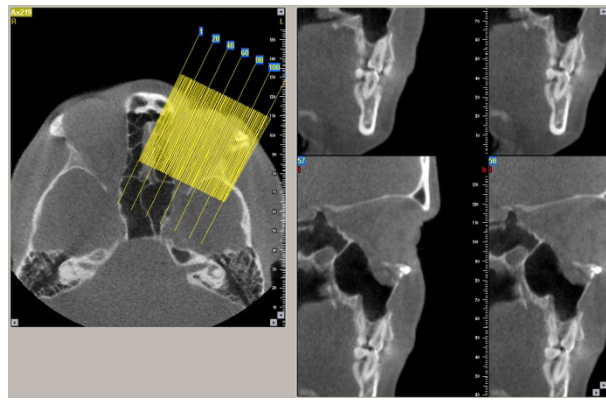


Figure 4. CBCT oblique sagittal extracted sections.

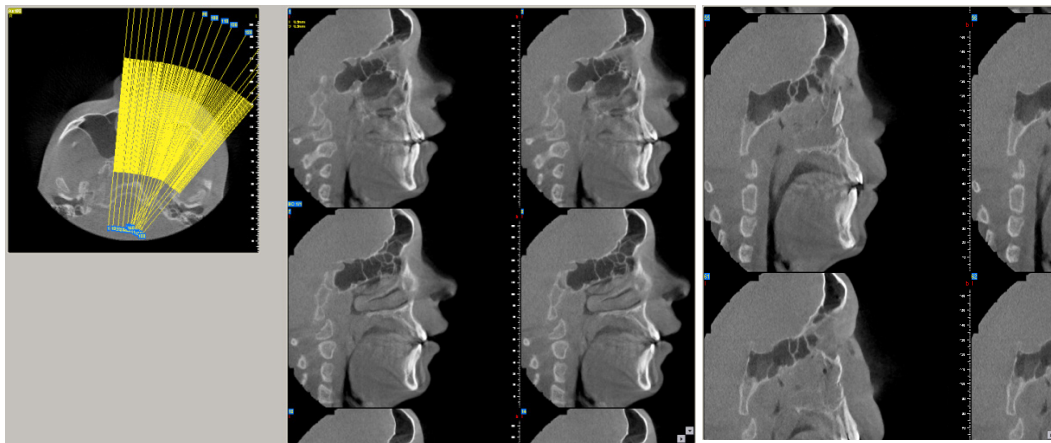


Figure 5. CBCT. Additional inclination of the designed curve for sagittal sections.

Figure 6. CBCT. Sagittal section in an oblique extraction. Associated maxillary bone fracture

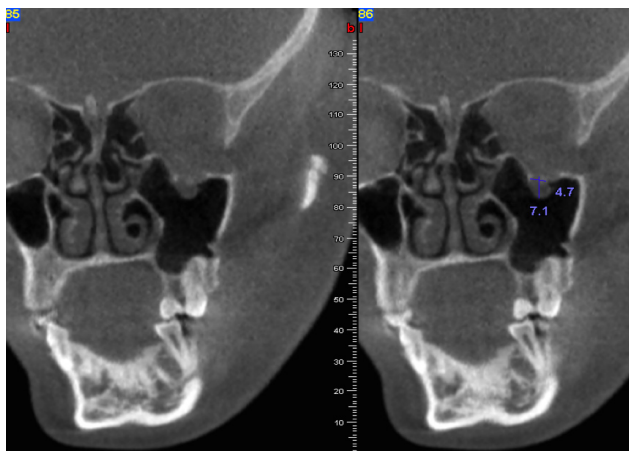


Figure 7. CBCT. Oblique coronal sections. Measurement of the herniated orbital soft tissue within the left maxillary sinus.

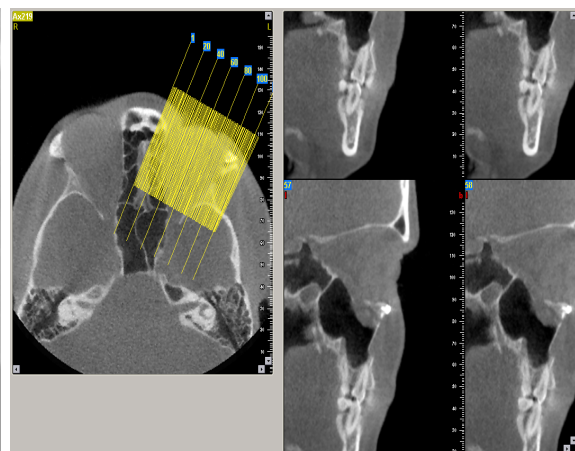


Figure 8. CBCT. Oblique sagittal section evaluation of the displacement and soft tissue down placement within the maxillary sinus

Both examiner's confidence in different type of sectioning was registered for being able to provide: a good detection and evaluation of the orbital floor fracture, of the presence or absence of herniated soft tissue within the maxillary sinus and the capacity to measure correctly the displacement on different reformatted sectioning. Across

the inter-examiners agreement was determined based on the results Cohen kappa-coefficient. The data were interpreted using statistical parameters, Confidence Intervals (CI) and Odds ratio, considering the determined $p < 0.05$ as being statistically significant.

Results

A number of 93 CBCT images were evaluated on 14 females and 79 males.

The presence of pure fracture of the orbital floor was detected in 11% of patients. Orbital floor was involved in different types of fractures, the respective data are presented in table I.

In 86% of subjects the displacement of the orbital floor was present, and from those cases in 21.5% of cases more than half of the orbital floor was affected by the fracture. Infra-orbital foramen was involved in the floor of the orbit fractures in 56.9%, with an OR= 1.32. This collective data are presented in Table II.

Regarding the confidence between examiners as to CBCT in evaluating these cases, the results are presented in table III, with percentages of the cases appreciated with confidence on using the oblique coronal or oblique sagittal CBCT reconstruction images for each type of modification. The results were calculated for orbital floor fracture detection and displacement and regarding the extent confident evaluation and confident appreciation of the migrated soft tissue.

The bone displacement of the orbital floor evaluated

in the reformatted coronal section was confidently seen in 53.25% of the cases by the first examiner and in 57.14% of the cases by the second examiner. The sagittal oblique reformatted sections provided confident evaluation of the extent of the bone displacement after examining section by section in 96% of the cases for the first examiner and in 90% of the cases for the second one. The inter-examiners agreement resulted in a Cohen kappa value of 0.96.

The soft tissue migration inferiorly within the maxillary sinus was appreciated as being confident on the oblique coronal sections in 74% by the first examiner and 76% by the second one. The oblique sagittal reconstruction allowed the first examiner to be confident in 59.1% and the second in 65.5%.

The presence or absence of muscle migration was confidently evaluated by the first examiner on the coronal sections in 69% of the cases and on the coronal ones in 54.8% on the sagittal one, 15% of the cases offered confident detection on both reformatted sections. The second examiner appreciated confidently the same aspect in 68% of the cases using the coronal oblique set of sections and in 59.14% using the sagittal sections, with a k=0.87 at kappa Cohen test.

Table I. Type of fractures that involved the orbital floor.

| Type of fracture | number of cases | percentage from the group | 95% CI |
|----------------------------------|-----------------|---------------------------|---------------|
| zygomatic disjunction | 52 | 56% | [0.457-0.655] |
| blow-out | 10 | 10% | [0.059-0.186] |
| blow-in | 8 | 8% | [0.044-0.160] |
| anterior wall of maxillary sinus | 11 | 10% | [0.067-0.199] |
| Le Fort 3 | 8 | 8% | [0.044-0.160] |
| Le Fort 2 | 12 | 11% | [0.075-0.212] |

Table II. Data regarding the involved structures in orbital floor fractures.

| Structure | percentage from the group | 95% CI | Odds ratio |
|--------------------------|---------------------------|---------------|------------|
| orbit floor displacement | 86% | [0.775-0.916] | 6.15 |
| infra-orbital foramen | 56.9% | [0.468-0.665] | 1.32 |
| bone displacement >50% | 21.5 % | [0.143-0.309] | 0.27 |
| fat herniation | 34.4% | [0.255-0.445] | 0.52 |
| muscle herniation | 15.05% | [0.091-0.237] | 0.17 |

Table III. The confidence of different sections in evaluating orbital floor fracture.

| Confidence on | oblique section | First examiner | Second examiner | Odds Ratio | Relative Risk | 95% CI |
|--------------------------|-----------------|----------------|-----------------|------------|---------------|---------------|
| orbit floor displacement | coronal | 53.25% | 57.14% | 1.17 | 1.07 | [0.807-1.427] |
| | sagittal | 96% | 90% | 0.4 | 0.94 | [0.870-1.028] |
| soft tissue herniation | coronal | 74% | 76% | 0.99 | 0.98 | [0.829-1.170] |
| | sagittal | 59.1% | 65.5% | 1.31 | 1.1 | [0.886-1.387] |

Measurements were made both on the three classical planes, available also when medical CT is used and in the oblique reconstructed images available only on CBCT. The soft tissue herniation measurements were considered after all planes were evaluated on the CBCT oblique reconstructed images. In the pure coronal view similar to CT, displacement and migration was measurable in 42% of the cases, whereas in the reformatted oblique coronal view it was achieved in 97% of the cases with high confidence, p value <0.0001 . The combination of the both oblique reformatted sagittal and coronal set of sections offered confidence of appreciation for all cases.

The cross agreement between examiners for each type of reformatted set of sections evaluated resulted in Cohen kappa values that ranged between 0.82-1.

Discussion

In examining the mid-facial fracture with a focus on the orbital fractures, the CBCT sections offered good quality images comparable with the bone window sections on medical CT. Orbital floor fractures was involved in more than half of the cases in the zygomatic disjunction, and in less than 15% in other types of fractures. The infra-orbital foramen was affected in more than 50% of the cases, and orbital floor displacement appeared in almost 90% of the cases. Even though it was present in so large number, the displacement of more than half of the orbital floor was detected in less than a third of the cases.

Our study is in agreement with Brisco et al. reported results when considering the detectability on CBCT of this type of fractures, comparing it with CT sections. Both studies show a higher detectability and evaluation confidence when using reformatted CBCT sectioning. In Brisco et al. [6] study the focus was not on a specific wall of the orbit, all the walls being taken in consideration together, while our study had focused especially on the floor of the orbit.

The use of the axial plane to detect fractures was below the needed confidence and did not offer the possibility to correctly appreciate the migration of the soft tissue within the maxillary sinus cavity. Moreover, the measurements of the soft tissue herniation were considered to be superior on CBCT oblique reconstructed images. In the pure coronal view similar to CT, displacement and migration was measurable in less the half of the patients of the cases, whereas in the reformatted oblique coronal view it was achieved in almost all cases with high confidence with a significant p value. The combination of the both oblique reformatted sagittal and coronal set of sections offered confidence of appreciation for all cases.

On classic CT, imaging correctly this displacement is difficult, and even harder with regard to the measurement of the defect because it is done on the 3D MIP reconstruction, both in coronal and sagittal plane, from the previous axial slices. This reconstruction depends on the

equipment with the possibility of volume average defects, and cannot provide oblique slices. The CBCT offers the possibility to extract, from the direct volume acquired during the exposure, slices in any inclination needed, to better analyze any bone displacement and fat pad or muscle herniation within the sinus. Our study is in agreement with Hatcher et al. [8] results on their imaging study of the orbit regarding the use of multi-planar approach, especially in the uncomplicated situation, when there is no hematoma in the back of the eye.

We obtained results similar to those of Tsao et al. [7] in the appreciation of the soft tissue migration. They included in the study only four patients, that were examined with CBCT after surgical treatment for orbital fractures. Our study differs by having a considerable larger group of patients with orbital fractures and having the CBCT examination performed before treatment. The data offered by CBCT were more superior than CT ones, as a low dose radiation tool in evaluating the surgical approach for uncomplicated cases.

The precision of the measurement seems to be higher on volumetric CT than the classic one, facts that in case of the infra-orbital fractures with bone displacement are very important in planning the treatment protocol. Schouman et al. [4] obtained good results on CT regarding these multi-planar oblique sectioning in the axis of the orbit by using additionally a special extra software accessible on some types of computer, but these takes a large amount of time consuming over the use of CBCT directly. The benefits though would be the possibility to access the retro-orbital hematoma.

Considering the confidence between examiners regarding CBCT in evaluating these cases, the results showed more confidence in using the oblique coronal and sagittal CBCT reconstruction images for fracture detection. For the bone displacement detection and extent evaluation the oblique sagittal reformatted set of sections provided the higher confidence in agreement on both examiners. For the soft tissue migration inferiorly within the maxillary sinus, and especially regarding the inferior rectus muscle entrapment, the confidence was appreciated to be better on the oblique coronal sections, in agreement with Drage et al. [9] results, or both section combined with a higher level of confidence over the sagittal ones alone. The difference between muscle and fat herniation, stated by Drage et al. to be a limit on CBCT, as the examination is in bone windowing, can be obtain better with the new and improved types of CBCT equipment, that provide possibility to measure even the number of Hounsfield units, in order to make a difference between structure absorption. This further possibility would even improve the detection on CBCT of the retro-orbital hematoma. The results on the confidence across examiners were extremely significant statistically according to the Cohen test kappa results, regarding every type of section investigated, both

in detection, displacement of the bone and soft tissue entrapment evaluation.

The main limitation of the present study consists in the incapacity of a true comparison between CBCT and CT on the same population, due to a non-ethical double exposure to a supplementary dose of radiation. This limitation was overcome by using the multi-planar extracted axial, coronal and sagittal planes offered by the CBCT equipment, sections that are similar with the ones provided by CT equipment.

The studies that use CBCT as imaging tool in evaluating the floor of the orbit fractures are few and with small number of cases, and this study comes to clarify the important position of the oblique coronal and sagittal extracted set of sections in evaluating these fractures and establishing the preoperative protocol.

Conclusions

The majority of mid-face trauma involve the orbital floor in the area of the fracture. CBCT offers, due to the set of 3D data obtained during examination, individual high resolution sagittal and coronal extracted plane, oblique sagittal and coronal plane, dedicated to the orbit itself, in its axis. The sagittal extracted sections in the axis of the orbit are the most confident in detecting bone displacement and the coronal in the orbit axis sections are the most confident in evaluating soft tissue entrapment.

The oblique cone-beam CT sectioning provides, with high confidence across examiners, the fine high resolution imaging information needed in the surgical planning for the

non-complicated orbital floor fractures, with less radiation exposure.

References

1. Salentjin E., Van Den Berg B. Forouzanfar T. A ten-year analysis of midfacial fractures. *J Craniomaxillofac Surg.* 2014;42(8):1717-1722.
2. Burm JS, Chung CH, OH SJ. Pure orbital blowout fractures: new concept and importance of medial blow-out fractures. *Plast Reconstr Surg.* 1999;103(7):1839-1849.
3. Shin JW, Lim JS, Yoo G, Byeon JH. An analysis of pure blowout fractures and associated ocular symptoms. *J Craniofac Surg.* 2013;24(3):703-707.
4. Schouman T, Courvoisier D, Imholz B. Computational area measurement of orbital floor fractures: Reliability, accuracy and rapidity. *Eur J Radiol.* 2012;81(9):2251-2254.
5. Manchio JV, Sati S, Rosman DA, Bryan DJ, Lee GM, Weinzweig J. Role of sagittal reformatted computed tomographic images in the evaluation of orbital floor fractures. *J Craniofac Surg.* 2010;21(4):1153-1157.
6. Brisco J, Fuller K, Lee N, Andrew D. Cone beam computed tomography for imaging orbital trauma--image quality and radiation dose compared with conventional multislice computed tomography. *Br J Oral Maxillofac Surg.* 2014;52(1):76-80.
7. Tsao K, Cheng A, Goss A, Donovan D. The use of cone beam computed tomography in the postoperative assessment of orbital wall fracture reconstruction. *J Craniofac Surg.* 2014;25(4):1150-1154.
8. Hatcher DC. CT & CBCT imaging: assessment of the orbits. *Oral Maxillofac Surg Clin North Am.* 2012;24(4):537-543.
9. Drage NA, Sivarajasingam V. The use of cone beam computed tomography in the management of isolated orbital floor fractures. *Br J Oral Maxillofac Surg.* 2009;47(1):65-66.