

Partial Epididymal Rupture and Spermatic Cord Haematoma with an Associated Secondary Testicular Torsion due to Blunt Scrotal Injury, in a 12-Year-Old Boy

Kleanthis Anastasiadis, Dimitrios Godosis, Chrysostomos Kepertis, Vasileios Mouravas, Vassilis Lampropoulos, Charikleia Demiri, Maria Tsopozidi, Ioannis Spyridakis

2nd Department of Pediatric Surgery, Aristotle University of Thessaloniki Greece, General Hospital 'Papageorgiou', Thessaloniki, Greece

Abstract

Scrotal injuries are not very common in children and are mostly due to blunt trauma from direct injury, sports injuries or motor vehicle accidents. Traumatic testicular torsion in children has been also infrequently reported in the literature. To ensure testicular salvage, an urgent and specialised diagnosis and management are necessary. We present a case of a partial epididymal rupture and spermatic cord haematoma with an associated secondary testicular torsion due to blunt scrotal injury, in a 12-year-old boy.

Keywords: Boy, epididymis, torsion

INTRODUCTION

Testicular injuries in children are relatively rare because the testicles are quite mobile inside the scrotum, covered and protected by the fibrous sheath and the overlying skin is quite loose.^[1] The injuries are divided into (a) blunt, after injury in sports activities and falling from a bicycle or motorcycle and (b) open, that are not common in children.^[1] The usual mechanism of testicular or spermatic cord and epididymal injury is the pressure on the symphysis pubis or on the surface of the inner thigh.

Secondary testicular torsion due to blunt scrotal trauma has an incidence of 4%–8% of testicular torsion in most series^[2] with the highest reported incidence being 12%.^[3] The scrotal symptoms and signs of trauma-induced spermatic cord torsion may be wrongfully attributed to the trauma itself.

Ultrasound is the first-line diagnostic method while the clinical examination is usually difficult due to swelling and severe pain on palpation. The examination includes first the simple ultrasound and then the power Doppler ultrasound. The size, echogenicity, integrity and perfusion of the testicle, the condition of the surrounding structures and the wall of the

scrotum are investigated, but always in comparison with the unilateral part of the scrotum.

A case of a partial epididymal rupture and spermatic cord haematoma with an associated secondary testicular torsion due to blunt scrotal injury in a 12-year-old boy is presented.

CASE REPORT

A 12-year-old boy presented to Pediatric Surgery Emergency Department with a painful and swollen right hemi-scrotum after falling from a motorcycle in which he was a co-driver. An ultrasound was performed immediately which showed the presence of a large haematoma on the upper pole of the testis and a heterogeneous and thickened epididymis representing traumatic rupture. A homogeneous intact testicle was also noted [Figure 1]. The testicular perfusion was

Address for correspondence: Dr. Kleanthis Anastasiadis, 2nd Department of Pediatric Surgery, Aristotle University, Papageorgiou General Hospital, Ring Road Nea Efkarpia Region, 56403 Thessaloniki, Greece.
E-mail: kaanastasiadis1@gmail.com

Received: 01-03-2021 Revised: 13-08-2021 Accepted: 20-10-2021 Available Online: 23-06-2022

Access this article online

Quick Response Code:



Website:
www.afjpaedsurg.org

DOI:
10.4103/ajps.AJPS_29_21

This is an open access journal, and articles are distributed under the terms of the Creative Commons Attribution-NonCommercial-ShareAlike 4.0 License, which allows others to remix, tweak, and build upon the work non-commercially, as long as appropriate credit is given and the new creations are licensed under the identical terms.

For reprints contact: WKHLRPMedknow_reprints@wolterskluwer.com

How to cite this article: Anastasiadis K, Godosis D, Kepertis C, Mouravas V, Lampropoulos V, Demiri C, *et al.* Partial epididymal rupture and spermatic cord haematoma with an associated secondary testicular torsion due to blunt scrotal injury, in a 12-year-old boy. Afr J Paediatr Surg 2022;19:183-5.

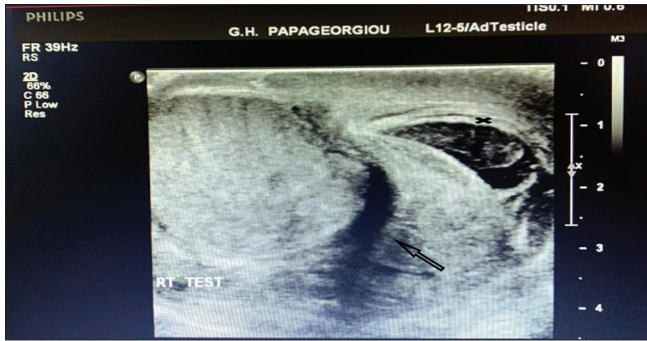

Figure 1: Large haematoma on the upper pole of the testis (arrow) and heterogeneous and thickened epididymis representing traumatic rupture (x). An intact testicle is also noted

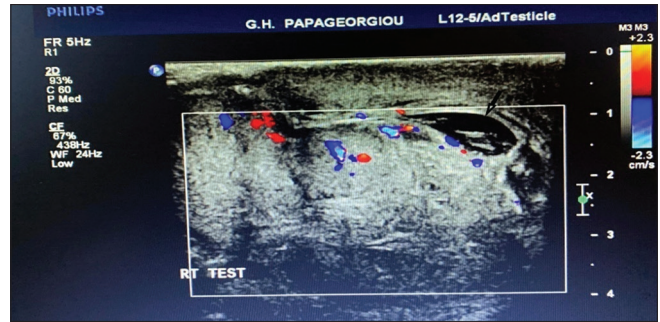


Figure 2: Doppler ultrasound demonstrating a preserved perfusion of the testicle. An associated haematocoele is also noted (arrow)

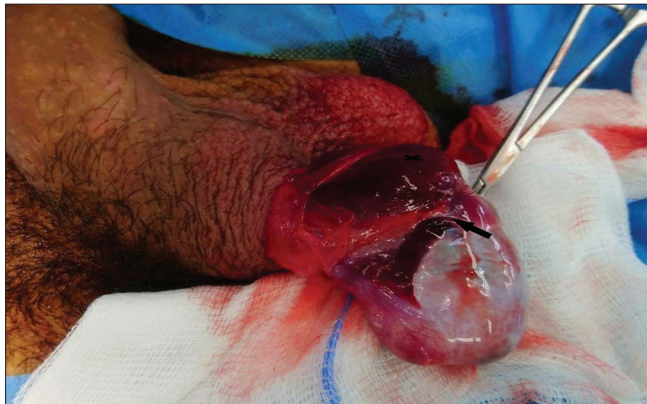


Figure 3: Large haematoma of the spermatic cord (x). Haematoma and minor bleeding of the epididymis (arrow) (due to urgent exploration, the photograph was taken few seconds after the anti-clockwise rotation of the twisted spermatic cord)

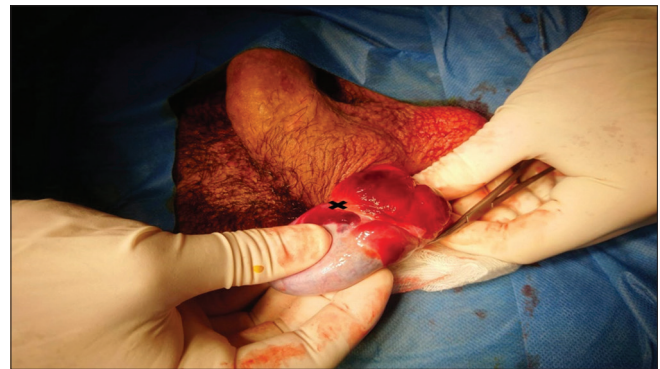

Figure 4: Spermatic cord's perfusion has been improved after the moist warm swabs. The haematoma of the epididymis is also noted (x)

intact [Figure 2]. The child was admitted to the Pediatric Surgery Department for follow-up where he was given analgesic and antibiotic treatment. After 6 h of his admission to the clinic, the swelling and the pain worsened and the repeated ultrasound examination confirmed the increase in the diameter of the haematoma. During the ultrasound examination, the radiologist raised the suspicion of possible twisting of the spermatic cord without being absolutely sure because of the existing oedema. The child was taken to the operating room for urgent exploration. A large haematoma of the upper pole of the testis was found and the spermatic cord to be 'strained' due to 180° clockwise rotation and the associated oedema. The testicle was intact without signs of injury or ischaemia [Figure 3]. The swollen spermatic cord was placed in the appropriate direction and wrapped in moist warm swabs and its colour observed intermittently. Five minutes later, its perfusion had been improved and after careful inspection of the area, a haematoma of the spermatic cord and minor bleeding due to partial epididymal rupture were observed [Figure 4]. Haemostasis was achieved by placement on the bleeding epididymal surface a piece of fibrillar surgical. Subsequently, a 'window' orchidopexy of this testicle was performed. Post-operative period was

smooth. An ultrasound examination on the 4th post-operative day revealed a good testicular perfusion and a decrease of the scrotal swelling. The boy was discharged on the 5th post-operative day with the recommendation to continue oral antibiotic and anti-inflammatory therapy. Follow-up ultrasound examination in the 3rd and 6th months after injury did not reveal any pathological findings.

DISCUSSION

Extratesticular haematomas are formed either in the scrotal wall by intraluminal haemorrhage or in the scrotal sac by haemorrhage of the para-testicular structures (spermatic cord and epididymis) or the testicle itself. The usual mechanism of testicular injury is the pressure on the symphysis pubis or on the surface of the inner thigh. Extratesticular haematocoeles within the tunica vaginalis are common finding in the scrotum after blunt injury in paediatric population.^[4] Haematomas of the scrotum are depicted as thickening or fluid collections in the wall.^[5] The volume of the haematocoele and the size of intrascrotal haematoma are criteria for urgent surgery. Persisting large haematocoele or large intrascrotal haematoma can lead to prolonged pain, inflammation, may mimic testicular torsion or partial torsion and even testicular atrophy.^[6] Haematomas with a diameter up to 5 cm require immediate intervention. If the diameter is smaller or does not increase during the ultrasound controls, a conservative management is suggested.^[7]

The most common predisposing factor for testicular torsion is so-called bell clapper deformity.^[8] In bell clapper deformity, an abnormal insertion of the tunica vaginalis allows the testis wide mobility. Trauma may induce a sudden forceful contraction of the cremasteric muscle, which encloses the spermatic cord in a spiral fashion and rotates the testicle as a result of its contraction.^[3] Traumatic testicular torsion has been infrequently reported in the literature, and the history of trauma may result in delay in making the correct diagnosis. According to the published literature, 5%–8% of cases of torsion of the spermatic cord are thought to be induced by trauma.^[3,9] The testicular salvage rate reported after traumatic testicular torsion varies between 0%, 33%, 80% and 100%.^[3] The presence of a haematoma from the twisted spermatic cord and the mild degree of pain often lead the doctors to ascribe the signs and symptoms to the traumatic episode, leading to a delayed diagnosis. That is why the strategy followed by our clinic is always the close clinical inpatient monitoring, which provides the opportunity of immediate intervention in case of a worsening clinical status of the patient. Hence, in our case, the patient underwent an immediate scrotal exploration, due to a sudden intense pain and the deteriorating ultrasound findings, during his 6 h stay after his admission into the Pediatric Surgery Department.

Epididymal injuries are usually seen in association with testicular injuries.^[6] The most commonly observed epididymal injury at ultrasound examination is traumatic epididymitis. Usually, epididymal injuries do not require surgical therapy and are managed conservatively.^[1] Epididymal rupture is a rare entity and even more rarely observed at ultrasound.^[5] In our case, however, the accurate pre-operative ultrasound diagnosis of the epididymal rupture was confirmed during the scrotal exploration. Few cases of ruptured epididymis have been reported in the literature and even fewer with associated torsion have been described before.^[10]

CONCLUSION

We would say that although serious injuries to the testicles and extratesticular structures are not so common in childhood, they

should always have a close paediatric surgery and radiological monitoring for the possibility of complications from the injury. Our strategy is always to recommend the admission of these patients to a Pediatric Surgery Department.

Declaration of patient consent

The authors certify that they have obtained all appropriate patient consent forms. In the form, the patient has given his consent for his images and other clinical information to be reported in the journal. The patient understands that name and initials will not be published and due efforts will be made to conceal identity, but anonymity cannot be guaranteed.

Financial support and sponsorship

Nil.

Conflicts of interest

There are no conflicts of interest.

REFERENCES

1. Dogra VS, Gottlieb RH, Oka M, Rubens DJ. Sonography of the scrotum. *Radiology* 2003;227:18-36.
2. Anderson JB, Williamson RC. Testicular torsion in Bristol: A 25-year review. *Br J Surg* 1988;75:988-92.
3. Seng YJ, Moissinac K. Trauma induced testicular torsion: A reminder for the unwary. *J Accid Emerg Med* 2000;17:381-2.
4. Koumanidou C, Manopoulou E, Pantazis J, Dermentzoglou V, Georgoulis P, Vakaki M, *et al.* Scrotal hematocele as an unusual presentation of blunt abdominal trauma in three male infants. *J Clin Ultrasound* 2000;28:190-3.
5. Deurdulian C, Mittelstaedt CA, Chong WK, Fielding JR. US of acute scrotal trauma: Optical technique, imaging findings, and management. *Radiographics* 2007;27:357-69.
6. Guichard G, El Ammari J, Del Coro C, Cellarier D, Loock PY, Chabannes E, *et al.* Accuracy of ultrasonography in diagnosis of testicular rupture after blunt scrotal trauma. *Urology* 2008;71:52-6.
7. Kim SH, Park S, Choi SH, Jeong WK, Choi JH. Significant predictors for determination of testicular rupture on sonography: A prospective study. *J Ultrasound Med* 2007;26:1649-55.
8. Dogra V, Bhatt S. Acute painful scrotum. *Radiol Clin North Am* 2004;42:349-63.
9. Lrhorfi H, Manunta A, Rodriguez A, Lobel B. Trauma induced testicular torsion. *J Urol* 2002;168:2548.
10. Kwong Y, Nathan T, McDonald J. A case of traumatic testicular torsion associated with a ruptured epididymis. *Int J Urol* 2004;11:349-51.