

Displacement of occluder as a rare complication of transcatheter closure of ventricular septal defect

A case report

Renwei Chen, MD^{a,*}, Jinwen Luo, MD^b, Xicheng Deng, MD^b, Peng Huang, MD^b

Abstract

Rationale: Ventricular septal defects are the most common congenital heart defect in children. As this method avoids sternotomy, the post-procedural morbidity is lower. However, transcatheter closure of perimembranous ventricular septal defects are still associated with complications such as arrhythmia (particularly, Atrioventricular Block), device embolization, atrioventricular valve and/or aortic valves regurgitation, residual shunts. Some complications can be life threatening and require urgent surgical intervention.

Patient concerns: An 32-months-old boy was admitted for a significant precordial systolic murmur. The patient underwent transcatheter perimembranous ventricular septal defects closure. 12 months later, Transthoracic echocardiography revealed the device displaced, 4 mm shunt across the ventricular septum and moderate tricuspid regurgitation detected.

Diagnosis: According to the echocardiography result, the patient was diagnosed with displacement of the ventricular septal defect occluder and tricuspid regurgitation.

Interventions: After the diagnosis, the patient underwent removal of the ventricular septal defect occluder and closure of the perimembranous ventricular septal defect.

Outcomes: The post-operative recovery was uneventful. One year post-procedural follow-up transthoracic echocardiography showed there was no residual shunt and no tricuspid regurgitation.

Lessons: Transcatheter closure of Ventricular septal defects is an attractive alternative to surgery in simple perimembranous ventricular septal defects. Proper follow-up should be emphasized to the patient.

Abbreviations: CPB = cardiopulmonary bypass, pmVSDs = perimembranous ventricular septal defects, TEE = transesophageal echocardiography, TR = tricuspid regurgitation, TTE = transthoracic echocardiography, VSDs = ventricular septal defects.

Keywords: cardiac surgery, complication, ventricular septal defect occluder

1. Introduction

Interventional techniques in cardiac catheterization have advanced by leaps and bounds in recent years. Ventricular septal defects (VSDs) are the most common congenital cardiac defect. Treatment options include surgical repair and, more recently, percutaneous device closure.^[1] Transcatheter closure of VSDs is

increasingly being used for simple perimembranous VSDs (pmVSDs). It avoids sternotomy and cardiopulmonary bypass (CPB). The morbidity is lower and hospital stay shorter. But complications of the procedure, which can occur in the early few days or weeks after the initial procedure, often require urgent surgical intervention.^[2] We describe a rare case requiring surgical removal of a pmVSD occluder and closure of the pmVSD a year after percutaneous closure.

Editor: N/A.

The author(s) received no financial support for the research and/or authorship of this article.

The authors have no conflicts of interest to disclose.

^a Department of Cardiothoracic Surgery, Maternal and Child Health Hospital of Hainan Province (Hainan Children's Hospital), Haikou, Hainan. ^b Department of Cardiothoracic Surgery, Hunan Children's Hospital, Changsha, Hunan, China.

* Correspondence: Renwei Chen, Department of Cardiothoracic Surgery, Maternal and Child Health Hospital of Hainan Province (Hainan Children's Hospital), No. 75 Longkun South Road, Haikou, Hainan Province 570206, China (e-mail: chenrw@qq.com).

Copyright © 2018 the Author(s). Published by Wolters Kluwer Health, Inc. This is an open access article distributed under the terms of the Creative Commons Attribution-Non Commercial-No Derivatives License 4.0 (CCBY-NC-ND), where it is permissible to download and share the work provided it is properly cited. The work cannot be changed in any way or used commercially without permission from the journal.

Medicine (2018) 97:27(e11327)

Received: 28 February 2018 / Accepted: 4 June 2018

<http://dx.doi.org/10.1097/MD.00000000000011327>

2. Case report

The patient provided informed consent for the publication of his clinical and imaging data. This case report was approved by Medical Ethical Committee of Hunan Children's Hospital.

A 32-month-old boy with 12 kg of weight was admitted to our cardiology department by found heart murmurs for a year. Echocardiography confirmed pmVSD, the base measuring 8 mm and top opening 5.3 mm. The patient underwent transcatheter pmVSD closure with a 9-mm VSD occluder (VSDO, Shanghai Shape Memory Alloy Co Ltd, Shanghai, China). Postprocedural transthoracic echocardiography (TTE) revealed a 1 mm residual shunt at the superior edge of occluder. He had remained on regular follow-up for a year. Twelve months later, TTE founded the device displaced, 4 mm shunt across the ventricular septum and moderate tricuspid regurgitation (TR) detected (Fig. 1). He was referred for surgical operation.

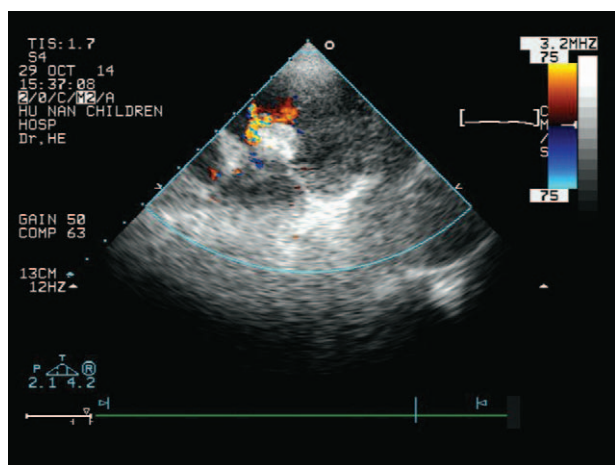


Figure 1. TTE after transcatheter pmVSD closure showing 1 mm residual shunt at the upper edge of occluder. pmVSD = perimembranous ventricular septal defect, TEE = transesophageal echocardiography.

He was operated upon under standard CPB with aorto-bicaval cannulation through a median sternotomy. The device was found to be displaced to the right ventricle and had endothelialized. The inferior and posterior edge of the occluder was still on the ventricular septum, but the superior and anterior edge was displaced. There was a 45 degree angle between the occluder and the ventricular septum (Fig. 2). The residual shunt was 4 to 5 mm and TR was moderate. Detachment of the septal leaflet of the tricuspid valve was performed to improve visualization of the device and surrounding tissues (Fig. 3). The occluder was carefully excised from the ventricular septum and the tricuspid septal valve using sharp dissection. There was no inadvertent injury to either ventricular septum or tricuspid valve. The VSD was closed with an autologous pericardium patch using running suture. Autologous pericardium was also used to strengthen the lower edge and septal annulus edge of VSD. The incision of the septal leaflet was repaired using interrupted suture. Postprocedural transesophageal echocardiography (TEE) showed there was no residual shunt and mild TR. The postoperative recovery was uneventful. One year postprocedural follow-up TTE showed there was no residual shunt and no TR.

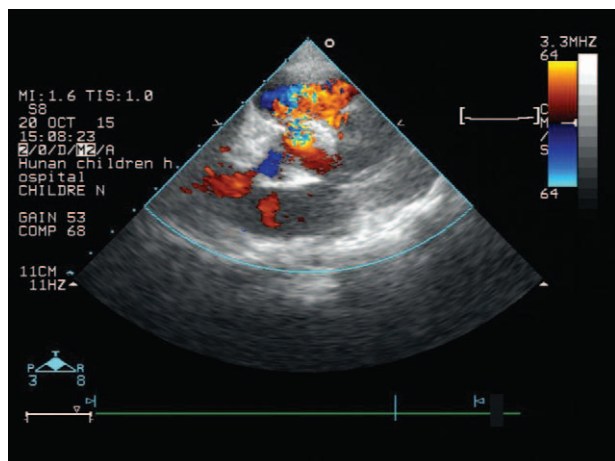


Figure 2. TTE 1 year after transcatheter pmVSD closure showing residual shunt enlarged.

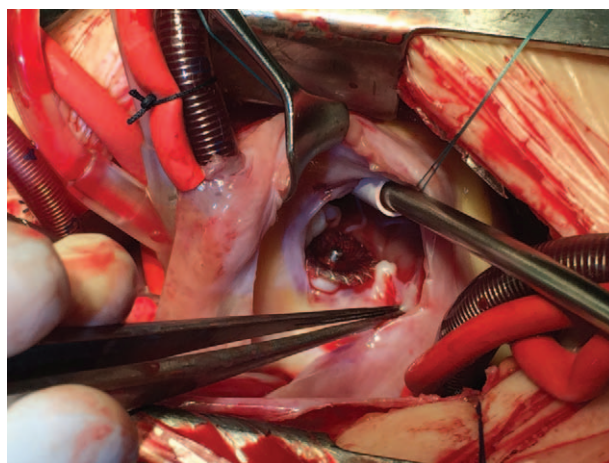


Figure 3. Intraoperative photograph showing an angle between the occluder and the ventricular septum.

3. Discussion

VSDs are the most common congenital heart defect in children. Surgical closure is the gold standard for VSDs repair. To avoid the effects of CPB and other complications relating to surgery, percutaneous closure is considered a valuable alternative for some suitable lesions at many institutions.^[1,3] Not all types of pmVSDs are amenable to device closure. It is defined by the location, shape, and size of the VSD and the relationship between the aortic and tricuspid valves.

Transcatheter closure of pmVSDs in children is a safe and effective treatment associated with excellent success and closure rates, at present.^[4,5] Complications can include arrhythmia, device embolization, vascular regurgitation, residual shunt, etc.^[4,5]

Displacement of VSD occluder device is a rare complication of this interventional procedure. Such a complication requires surgical intervention to remove it. In our literature review, device displacement was reported in several cases with atrial septal defect and Patent ductus arteriosus after interventional procedure. None of VSD occluder displacement which needed surgical removal was reported. Similar to other percutaneous transcatheter closure techniques, size and location of the defect, and presence of infection might be correlated with the stability of the occluder device.^[6]

In our case, postprocedural TTE revealed a 1 mm residual shunt at the superior edge of the occluder. Rates of residual shunts on long-term follow-up were lower than those noted immediately after device closure, suggesting spontaneous closure of the majority of residual shunts over time.^[4] So if a residual shunt occurred, the patient needed to follow up for about 1 year to give chance for its spontaneous closure. But in this case, the real problem was that the device was a little smaller. The superior edge of the occluder could not hold the position to the subaortic area. After regular follow-up of a year, TTE showed the shunt had become larger and TR increased. According to the TTE result, it revealed displacement of the device, we had to surgically remove it. After a year, the device was fully endothelialized and its removal required excision from the surrounding ventricular and tricuspid valve tissues. During the operation, any structure around the device could have been injured. But he was lucky that

there was no atrioventricular block and tricuspid valve regurgitation vanished.

In conclusion, transcatheter closure of VSD is an attractive alternative to surgery in simple pmVSDs. Proper follow-up should be emphasized to the patient, when a residual shunt is identified, then meticulous follow-up required for spontaneous closure or surgical closure. A chance should be given for its spontaneous closure. Six to 12 months later, the residual defect should be closed; otherwise, surgical therapy is essential for the removal of the device and closure of the defect.

Author contributions

Conceptualization: Peng Huang.

Data curation: Xicheng Deng.

Writing – original draft: Renwei Chen.

Writing – review & editing: Renwei Chen, Jiwen Luo.

References

- [1] Butera G, Carminati M, Chessa M, et al. Transcatheter closure of perimembranous ventricular septal defects: early and long-term results. *J Am Coll Cardiol* 2007;50:1189–95.
- [2] Wei Y, Wang X, Zhang S. Transcatheter closure of perimembranous ventricular septal defects (VSD) with VSD occluder: early and mid-term results. *Heart Vessels* 2012;27:398–404.
- [3] Liu S, Chen F, Ding X, et al. Comparison of results and economic analysis of surgical and transcatheter closure of perimembranous ventricular septal defect. *Eur J Cardiothorac Surg* 2012;42:157–62.
- [4] Yang LQ, Tai BC, Khin LW, et al. A systematic review on the efficacy and safety of transcatheter device closure of ventricular septal defects (VSD). *J Interv Cardiol* 2014;27:260–72.
- [5] Ghaderian M, Merajie M, Mortezaeian H, et al. Efficacy and safety of using amplatzer ductal occluder for transcatheter closure of perimembranous ventricular septal defect in pediatrics. *Iran J Pediatr* 2015;25:e386.
- [6] Yuan SM, Shinfeld A, Raanani E. Displacement of the Amplatzer occluder device from the mitral paraprosthetic leak. *Interact Cardiovasc Thorac Surg* 2008;7:1131–3.