

***Equid herpesvirus 1 and rhodococcus equi* coinfection in a foal with bronchointerstitial pneumonia**

Alejandro PEREZ-ECIJA¹*, Francisco Javier MENDOZA¹, José Carlos ESTEPA¹, María José BAUTISTA¹ and José PÉREZ¹

¹Department of Animal Medicine and Surgery, University of Cordoba, Campus Universitario Rabanales. Ctra. Madrid-Cadiz km 396. 14014 Cordoba, Spain

(Received 18 January 2016/Accepted 13 May 2016/Published online in J-STAGE 3 June 2016)

ABSTRACT. A 2-month-old foal with septic shock and severe respiratory distress was referred to the Veterinary Teaching Hospital. Due to poor prognosis, the foal was euthanized. Histopathology showed lesions suggestive of *Rhodococcus equi* infection associated with a diffuse interstitial infiltrate of foamy macrophages and syncytial cells presenting large acidophilic intranuclear inclusion bodies, fibrin exudates and hyaline membranes. Bacteriological examination from lung and respiratory exudates confirmed *R. equi* infection, whilst immunohistochemistry and PCR yielded a positive result for *Equid herpesvirus type 1* (EHV-1). Several etiologies have been proposed for bronchointerstitial pneumonia in foals, although a multifactorial origin for this lesional pattern could be possible. This work is the first one describing a combined EHV-1 and *R. equi* infection in a foal affected with bronchointerstitial pneumonia.

KEY WORDS: *Equine herpesvirus*, immunohistochemistry, pneumonia, *rhodococcus equi*

doi: 10.1292/jvms.16-0024; *J. Vet. Med. Sci.* 78(9): 1511–1513, 2016

Bronchointerstitial pneumonia (BP) is a sporadic disease in foals characterized by a rapid and fatal onset. Affected animals are commonly one to four months old and present a range of clinical patterns that can consist of a total lack of clinical signs to an acute evolution with dyspnea, tachypnea, pyrexia, variable hypercapnia and severe hypoxemia, commonly classified under the umbrella of acute respiratory distress [3, 4]. In this case, patients are typically unresponsive to treatment, and prognosis is guarded, turning this condition into an important concern for equine practitioners.

Grossly, a diffuse to lobular pattern of lung consolidation is commonly found. Typical histology findings in those areas are epithelial necrosis, hyaline membranes, fibrin exudates and a mixed population of neutrophils and syncytial cells in alveoli and bronchi [2].

A viral origin has been traditionally suspected, being *Equid herpesvirus type 2* (EHV-2) or Equine Influenza virus, the most commonly isolated in case of BP [2, 6, 10]. However, concomitant bacterial infections, overall by *Rhodococcus equi*, are a common finding in BP, with more than 40% of these animals showing foci of liquefactive or pyogranulomatous pneumonia [3].

A 2-month-old foal, Andalusian breed, weighting 85 kg, with a 2-day evolution history of profound dyspnea and tachypnea, was referred to the Veterinary Teaching Hos-

pital of the University of Cordoba. On admission, the foal presented septic shock and severe respiratory distress with fever (39.1°C), prolonged capillary refill time (4 sec), grey mucous membranes, hypovolemia, hypotension, azotemia, severe hypoxemia and hypercapnia with respiratory and metabolic acidosis. Thoracic ultrasound showed numerous abscess-like images (mean size 6 × 5 cm) on both lungs. Due to poor prognosis, the foal was euthanized.

At necropsy, both lungs appeared diffusely edematous and reddish, non-collapsing and consolidated, being this lesion more apparent in ventral locations of the right lung (Fig. 1). In cranioventral areas of the left lung, a pyogranulomatous bronchopneumonia composed of coalescing nodules ranging up to 10 cm was recorded. There were also two nodules (5 cm) in the caudal lobes of the left lung (Fig. 1). Mesenteric lymph nodes were also enlarged.

Microscopically, pyogranulomatous nodules featured a necrotic center with debris and degenerated neutrophils surrounded by macrophages, lymphocytes, plasma cells and fibroblast, but lacking a real fibrous capsule. Intracytoplasmatic coccobacilli bacteria were easily distinguished in some macrophages. In the parenchyma surrounding these nodules and diffusely in the right lung, the most striking finding was the presence of a diffuse interstitial infiltrate of foamy macrophages and syncytial cells accompanied by bronchiolar and alveolar epithelium necrosis, fibrin exudates and hyaline membranes (Fig. 2). Numerous foamy macrophages and syncytial cells presented large acidophilic intranuclear inclusion bodies (Fig. 2, inset A). Mesenteric lymph nodes showed a pyogranulomatous lesion similar to the one described in the left lung.

Gram, Periodic acid Schiff, Grocott's methenamine silver, Ziehl-Neelsen and Giemsa techniques were performed in order to confirm the presence of any pathogen.

*CORRESPONDENCE TO: PEREZ-ECIJA, A., Department of Animal Medicine and Surgery, University of Cordoba, Campus Universitario Rabanales. Ctra. Madrid-Cadiz km 396. 14014 Cordoba, Spain. e-mail: alejandro.perez.ecija@uco.es

©2016 The Japanese Society of Veterinary Science

This is an open-access article distributed under the terms of the Creative Commons Attribution Non-Commercial No Derivatives (by-nc-nd) License <<http://creativecommons.org/licenses/by-nc-nd/4.0/>>.

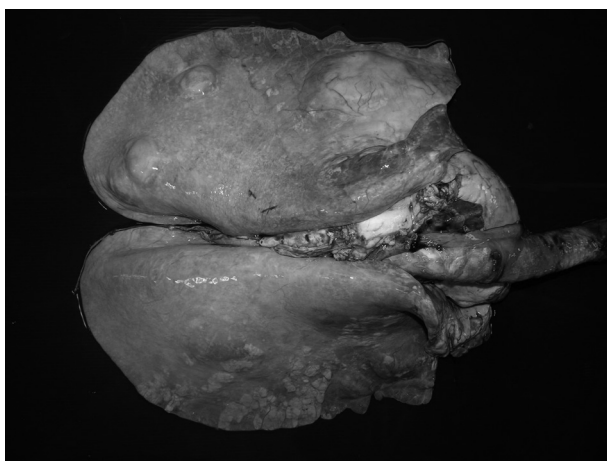


Fig. 1. Lungs; equine. Both lungs appear diffusely edematous and reddish, non-collapsing and consolidated (more apparent in ventral right lung), corresponding histologically with bronchointerstitial pneumonia. In the left lung, several nodules up to 10 cm in diameter were noticed. Histologically, these nodules were recognized as pyogranulomas with presence of *Rhodococcus equi*.

Intracytoplasmic bacteria observed in lung macrophages were Gram positive and identified as *R. equi* by means of lung and exudate bacteriological examination. No other agent was identified. An immunohistochemical study was performed in order to recognize the viral agent responsible for the intranuclear inclusion bodies. An avidin-biotin-peroxidase technique using a caprine anti-EHV-1 polyclonal antibody (VMRD Inc., Pullman, WA, U.S.A.) was performed following previous reports [12]. Inclusion bodies, both those easily identified in syncytial cells and the inconspicuous ones in foamy macrophages, showed a strong immunostaining (Fig. 2, inset B). Tissue samples from lungs were sent to the National Reference Laboratory for Equid Herpesviruses, and a nested multiplex PCR was performed following a previously described method [13]. Samples were positive for EHV-1, but negative for EHV-4, EHV-2 or EHV-5.

The histological lesion was BP with the presence of syncytial cells and foamy macrophages containing EHV-1 inclusion bodies and a concurrent pyogranulomatous pneumonia and mesenteric lymphadenitis. Based on histological findings, biomolecular and bacteriological examinations, a diagnosis of EHV-1 and *R. equi* coinfection was made.

This foal came from a farm with enzootic *R. equi* infection, and several newborns in the same season had been treated for this reason. EHV-1 cases (abortions) had been sporadically diagnosed in the premises, and a vaccine program had been established. Nonetheless, foals can get infected during their first week of life independently of the mare vaccination status [5, 9].

The histological appearance found in our case (right lung and areas surrounding pyogranulomas of the left lung) matches previous descriptions in subacute stages of BP, with a predominance of hyaline membranes and an alveolar filling of neutrophils and foamy macrophages, some of which

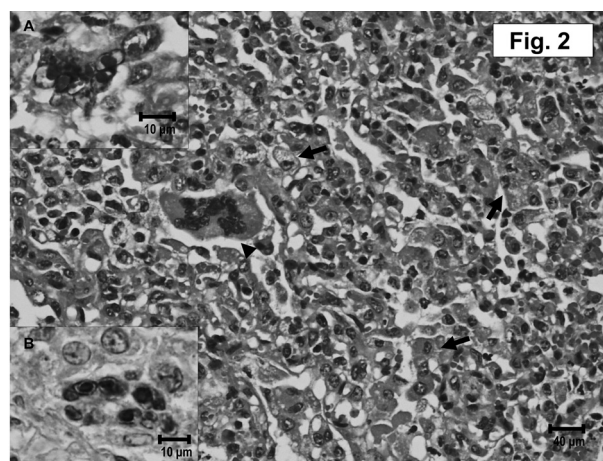


Fig. 2. Lungs; equine. Alveolar septa and lumina show severe infiltration of foamy macrophages (arrows) and syncytial cells (arrowhead), some of which contained basophilic intranuclear inclusion bodies. Hematoxylin-eosin. Bar: 40 µm. Inset A: Detail of inclusion bodies in syncytial cell. Hematoxylin-eosin. Bar: 10 µm. Inset B: Immunohistochemistry using caprine anti-Equid Herpesvirus 1 (EHV-1) polyclonal antibody showing strong immunostaining in inclusion bodies of a syncytial cell. Avidin-biotin-peroxidase. Bar: 10 µm.

turn binucleated or multinucleated, forming syncytia [2, 3]. The frequency of syncytial cells in BP is different between reports, but they have been consistently found in retrospective reviews [8, 10, 11]. In spite of this, no previous report has described the presence of obvious inclusion bodies in pulmonary lesions, even less in syncytial cells.

A viral etiology has traditionally been suspected for BP, even if it is not always easy to identify the viruses in the lesions. For instance, one study failed to isolate any virus [11], whereas only 1 out of 13 foals in another retrospective study resulted positive for EHV-2 [8]. A recent study associated BP with Equine Influenza virus [10], although no inclusion bodies were found in this study and hence EHV-1 was not investigated. None of the aforementioned reports described inclusion bodies in the lesions, which emphasizes the importance of this clinical case.

In most BP reported cases, a concurrent mycotic or bacterial infection exists. A rich histiocytic interstitial pneumonia in foals has been recently linked to *Pneumocystis carinii* [1], but silver staining was negative in this foal. On the other hand, *R. equi* has been commonly isolated in cases of BP and even proposed as a cause [3].

In this foal, EHV-1 probably worsened an initial infection with *R. equi*, making the foal unable to react to both pathogens.

In the present case, molecular diagnosis by means of PCR confirmed the presence of EHV-1 in the lungs, whereas other herpesviral species were not identified. Moreover, strong immunoreactivity to EHV-1 polyclonal antibody was found in the inclusion bodies of syncytial cells. The utility of immunohistochemistry in the detection of EHV-1 in equine tissues has been widely demonstrated [7, 12].

EHV-1 causes respiratory, neurological and generalized neonatal disease as well as abortion [9]. Systemic neonatal infections with EHV-1 are possible and fatal, with similar lesions to those observed in aborted fetuses [3]. Microscopical pulmonary changes consist of interstitial edema and infiltration of lymphocytes and macrophages and severe necrosis of bronchial and alveolar epithelial cells. Inclusion bodies are usually found in the nuclei of the bronchial and alveolar epithelia. These features match with lesions reported in this case, although the presence of inclusion bodies was in both macrophages and syncytial cells.

To the knowledge of the authors, this is the first description of EHV-1 inclusion bodies in syncytial cells of a foal with bronchointerstitial pneumonia. The concomitant histological, immunohistochemical and molecular evidences of EHV-1 in this case reinforce the role of this virus in this disease.

REFERENCES

- Ainsworth, D. M., Weldon, A. D., Beck, K. A. and Rowland, P. H. 1993. Recognition of *Pneumocystis carinii* in foals with respiratory distress. *Equine Vet. J.* **25**: 103–108. [[Medline](#)] [[CrossRef](#)]
- Buergelt, C. D., Hines, S. A., Cantor, G., Stirk, A. and Wilson, J. H. 1986. A retrospective study of proliferative interstitial lung disease of horses in Florida. *Vet. Pathol.* **23**: 750–756. [[Medline](#)]
- Caswell, J. L. and Williams, K. J. 2007. The respiratory system. pp. 544–632. *In: Pathology of Domestic Animals*, 5th ed. vol 2. (Jubb, K.V.F., Kennedy, P.C. and Palmer, N. eds.), Elsevier Saunders, New York.
- Dunkel, B., Dolente, B. and Boston, R. C. 2005. Acute lung injury/acute respiratory distress syndrome in 15 foals. *Equine Vet. J.* **37**: 435–440. [[Medline](#)] [[CrossRef](#)]
- Foote, C. E., Love, D. N., Gilkerson, J. R., Wellington, J. E. and Whalley, J. M. 2006. EHV-1 and EHV-4 infection in vaccinated mares and their foals. *Vet. Immunol. Immunopathol.* **111**: 41–46. [[Medline](#)] [[CrossRef](#)]
- Fortier, G., van Erck, E., Pronost, S., Lekeux, P. and Thiry, E. 2010. Equine gammaherpesviruses: pathogenesis, epidemiology and diagnosis. *Vet. J.* **186**: 148–156. [[Medline](#)] [[CrossRef](#)]
- Jönsson, L., Beck-Friis, J., Renström, L. H., Nikkilä, T., Thebo, P. and Sundquist, B. 1989. Equine herpes virus 1 (EHV-1) in liver, spleen, and lung as demonstrated by immunohistology and electron microscopy. *Acta Vet. Scand.* **30**: 141–146. [[Medline](#)]
- Lakritz, J., Wilson, W. D., Berry, C. R., Schrenzel, M. D., Carlson, G. P. and Madigan, J. E. 1993. Bronchointerstitial pneumonia and respiratory distress in young horses: clinical, clinicopathologic, radiographic, and pathological findings in 23 cases (1984–1989). *J. Vet. Intern. Med.* **7**: 277–288. [[Medline](#)] [[CrossRef](#)]
- Lunn, D. P., Davis-Poynter, N., Flaminio, M. J., Horohov, D. W., Osterrieder, K., Pusterla, N. and Townsend, H. G. 2009. Equine herpesvirus-1 consensus statement. *J. Vet. Intern. Med.* **23**: 450–461. [[Medline](#)] [[CrossRef](#)]
- Patterson-Kane, J. C., Carrick, J. B., Axon, J. E., Wilkie, I. and Begg, A. P. 2008. The pathology of bronchointerstitial pneumonia in young foals associated with the first outbreak of equine influenza in Australia. *Equine Vet. J.* **40**: 199–203. [[Medline](#)] [[CrossRef](#)]
- Prescott, J. F., Wilcock, B. P., Carman, P. S. and Hoffman, A. M. 1991. Sporadic, severe bronchointerstitial pneumonia of foals. *Can. Vet. J.* **32**: 421–425. [[Medline](#)]
- Szeredi, L., Aupperle, H. and Steiger, K. 2003. Detection of equine herpesvirus-1 in the fetal membranes of aborted equine fetuses by immunohistochemical and in-situ hybridization techniques. *J. Comp. Pathol.* **129**: 147–153. [[Medline](#)] [[CrossRef](#)]
- Wang, L., Raidal, S. L., Pizzirani, A. and Wilcox, G. E. 2007. Detection of respiratory herpesviruses in foals and adult horses determined by nested multiplex PCR. *Vet. Microbiol.* **121**: 18–28. [[Medline](#)] [[CrossRef](#)]