Biomedicine Hub

Novel Insights from Clinical Practice

Biomed Hub 2024;9:89–93
DOI: 10.1159/000538709

Received: January 13, 2024
Accepted: April 1, 2024
Published online: May 27, 2024

Portable Percussive Massage Device-Related Rectus Sheath Hematoma and Obstructive Uropathy: A Case Report

Lawrence Kwon

Nephrology, Westchester Medical Center, Poughkeepsie, NY, USA

Established Facts

- Immediately after the onset of ureteral obstruction, intratubular pressures rise, while the glomerular filtration rate is maintained due to the dilation of afferent arterioles. However, this mechanism does not account for the decreased excretion of sodium and water present in cases of acute partial ureteral obstruction.
- Rectus sheath hematomas (RSHs) can occur at the site of anticoagulant administration and result in retroperitoneal bleeding and obstructive uropathy.

Novel Insights

- Use of handheld deep-tissue percussive massage devices should be considered as a cause of or contributor to RSHs, particularly in patients who are receiving anticoagulation therapy.
- In hospitalized patients, the presentation of acute hyponatremia alongside hyperuricemia should alert clinicians to the potential for acute partial unilateral obstructive uropathy, which may stem from an expanding RSH, particularly when accompanied by a sudden decrease in hemoglobin levels as well.

Keywords
COVID-19 · Acute ureteral obstruction · Rectus sheath hematoma · Portable massage device · Case report

Abstract

Introduction: Rectus sheath hematomas (RSHs) can occur from the rupture of the epigastric arteries, leading to blood accumulation within the rectus abdominis sheath. Herein, we report the unique case of an RSH resulting in acute ureteral obstruction, which was associated with the use of a handheld deep-tissue percussive massage device in attempts to relieve abdominal pain. ***Case Report:*** A morbidly obese man in his late 50s was admitted with complications of COVID-19, including acute respiratory syndrome, bilateral peroneal deep vein thromboses, and acute kidney injury. He was treated with anticoagulants (subcutaneous enoxaparin and apixaban), dexamethasone, and remdesivir. He developed severe abdominal pain, and a large (14 × 17 cm) right rectus

karger@karger.com
www.karger.com/bmh

© 2024 The Author(s).
Published by S. Karger AG, Basel

This article is licensed under the Creative Commons Attribution-NonCommercial 4.0 International License (CC BY-NC) (http://www.karger.com/Services/OpenAccessLicense). Usage and distribution for commercial purposes requires written permission.

Correspondence to:
Lawrence Kwon, Lawrence.Kwon@wmchealth.org

sheath and an extraperitoneal pelvic hematoma were identified by computed tomography. The hematoma extended across the midline into the left pelvis and the retroperitoneum with associated mild right hydronephrosis. A handheld percussive massage device (Theragun®) was applied repeatedly at the site of enoxaparin injection into the abdominal wall in attempts to alleviate the pain. On day 12, bilateral nephrostomy tubes were inserted. A nephrostogram revealed mild hydroureteronephrosis to the ureterovesicular junction bilaterally and extrinsic compression of the bladder. On day 17, the patient suffered a cardiac arrest and died. ***Conclusion:*** This case report offers insights into the pathophysiology of obstructive uropathy and is a reminder of the importance of considering uncommon causes of obstructive uropathy in the diagnosis and management of AKI, particularly in hospitalized patients receiving anticoagulation. We know of no previous reference of obstructive uropathy caused by retroperitoneal hematoma associated with the use of a portable massage device applied to the abdominal wall.

© 2024 The Author(s).
Published by S. Karger AG, Basel

Introduction

Acquired urinary tract obstruction can be intrinsic to the urinary tract or from extrinsic causes. Intrinsic causes include nephrolithiasis, deposition of drug crystals, multiple myeloma, ureteral strictures, conditions leading to neurological dysfunction, and medications inducing bladder dysfunction. Extrinsic factors encompass a wide range of conditions, such as pelvic and retroperitoneal tumors, benign prostatic hyperplasia, and vascular and inflammatory diseases. Cases of obstructive uropathy due to rectus sheath hematoma (RSH) [1, 2] and RSH in patients hospitalized with COVID-19 [3, 4] have been documented, but we present a unique case of a patient admitted with COVID-19 acute respiratory syndrome exhibiting both conditions concurrently.

Case Presentation

A morbidly obese gentleman in his late 50s presented with acute respiratory syndrome due to COVID-19. He had not seen a physician in several years and was not taking any medications or supplements prior to hospitalization. He was immediately placed on bilevel positive airway therapy because of respiratory distress. A chest radiograph revealed bilateral multifocal airspace opacities, and the D-dimer value was >128,000 ng/mL. Table 1 displays the notable laboratory values recorded during the hospitalization. The patient's inability to lie down due to back pain and dyspnea prevented the assessment of pulmonary emboli via computed tomography (CT) angiogram of the chest. Nevertheless, bilateral peroneal vein and deep vein thromboses were identified by ultrasound, leading to the initiation of treatment with subcutaneous enoxaparin 1 mg/kg twice a day along with dexamethasone and remdesivir. On day 9, enoxaparin was replaced with apixaban 10 mg twice daily due to the patient's intolerance to injections, citing pain at the abdominal injection sites that was exacerbated by coughing. On day 10, the patient experienced severe acute lower abdominal and suprapubic pain. He requested the insertion of a Foley catheter as he believed he was retaining urine and lacked energy to void, and he hoped a catheter would alleviate the pressure and pain. Widespread ecchymoses were present on the right lower side of the trunk, extending to the back. Urine microscopy revealed diffuse muddy brown granular casts and >100 RBCs/HPF. A CT of the abdomen and pelvis revealed a large right rectus sheath and extraperitoneal pelvic hematoma, measuring 14 × 17 cm. The hematoma extended across the midline into the left pelvis and the retroperitoneum with associated mild right hydronephrosis. There was no evidence of left hydronephrosis, but the bladder was externally compressed (Fig. 1). Apixaban was discontinued, and one unit of blood was transfused. On day 11, blood pressure was 84/56 mm Hg, and CT of the abdomen and pelvis revealed a slight increase in the right pelvic retroperitoneal hematoma and interval development of left-sided hydronephrosis. The nursing staff noted that a family member had brought in a handheld percussive massage device (Theragun®) to help alleviate the pain at the site of enoxaparin injection into the abdominal wall since day 7. Use of the massage device was suspected of contributing to the development of the hematoma. On day 12, bilateral nephrostomy tubes were inserted. A nephrostogram revealed mild hydroureteronephrosis to the ureterovesicular junction bilaterally and extrinsic compression of the bladder. On day 17, the patient suffered cardiac arrest and died.

Discussion

The renal functional consequences of urinary tract obstruction necessitate assessment for both peri- and post-obstruction. The consequences are critically modulated by the obstruction's laterality (unilateral vs. bilateral), temporality (acute vs. chronic), and extent (partial vs. complete).

Within the immediate 2–3 h after the onset of unilateral ureteral obstruction (UUO) or bilateral ureteral obstruction (BUO), the reduction in antegrade urine flow leads to increased intratubular pressure. During this early stage of obstruction, the increased pressure in Bowman's space does not immediately affect the glomerular filtration rate (GFR). The explanation for

Table 1. Patient's laboratory data

Date	WBC	Hgb	LDH	Na^+	K^+	Cl^-	CO_2	BUN	Cr	UA	U Na^+	U Cl^-	U K^+	U UA	U Cr	U osm
Adm	12.08	13.3	1,894	136	5.2	102	27	22	1.24							
Day 8	18.86	14.1	1,285	137	5.7	97	30	28	1.17	7.1	141	134	38.6	50.2	56.8	677
Day 9	22.65	12	1,089	131	4.9	99	27	32	1.06	7.4						
Day 10	35.92	10.4	933	128	5.1	93	23	44	2.02	9	45	26	80		132.7	505
Day 11	37.96	8.8	991	118	5.5	91	17	71	3.6	11	30	<20	40.2	39.8		409
Day 17	25.84	9		130	4.7	99	28	16	0.8							

WBC, white blood cell: k/mm^3; Hgb, hemoglobin: g/dL; LDH, lactate dehydrogenase: U/L; Na^+, sodium: mmol/L; K^+, potassium: mmol/L; Cl^-, chloride: mmol/L; total CO_2, total carbon dioxide: mmol/L; UA, uric acid: mg/dL; BUN, blood urea nitrogen: mg/dL; Cr, creatinine: mg/dL; osm, osmolality: mosm/kg; U, urine.

this apparent paradox is that in response to obstruction, the afferent arterioles dilate, resulting in decreased arteriolar resistance and increased glomerular capillary hydraulic pressure [5]. This dilation is linked to reduced myogenic tone, influenced by intrarenal pressure changes affecting wall tension and vessel radius, as per Laplace's law [6]. Additionally, vasodilator prostaglandins such as E2 may contribute to this response [5, 6]. With prolonged complete ureteral obstruction, either UUO or BUO, renal blood flow drops (about equally with both kinds of obstruction) [6].

Both UUO and BUO impair the tubular transport of water, sodium (Na^+), K^+, and H^+. During acute partial UUO, there is a significant decrease in Na^+, potassium, and solute excretion, with a decrease in urine Na^+ concentration and an increase in urine osmolality [6]. Despite the preservation of GFR, there is a decrease in the flow rate through the distal nephron with an increase in the efflux of Na^+ or a decrease in its back diffusion, resulting in a higher net reabsorption of Na^+ [6]. These changes mimic the characteristics of prerenal oliguria as was evidenced in this patient by laboratory values seen on hospital day 9, including hyponatremia and increasing serum urea and uric acid (UA) concentrations.

Top of Form

The reduced capacity to concentrate urine after a 24-h UUO (in this case by day 10) is primarily due to a decrease in the GFR [5, 6]. The decreased GFR, in conjunction with an increased fractional reabsorption in the outer cortical nephrons, leads to a diminished delivery of solute to the medulla [5, 6]. Additionally, there is a reduced fractional fluid reabsorption in the deep nephrons [5, 6]. Another factor contributing to this condition is the enhanced lymphatic drainage, which facilitates the removal of medullary solutes [6]. Consequently, a lowered gradient of solute concentration in the medullary interstitium results. Moreover, the collecting ducts have a decreased reabsorption capacity, largely due to a diminished response to antidiuretic hormone [5, 6]. This effect was evident in our patient on day 10 when hyponatremia rapidly worsened.

After UUO is relieved, there is no absolute increase in Na^+ and water excretion, though the fractional excretion from the kidney that had been obstructed is higher [5]. In contrast, after the relief of acute complete BUO, post-obstructive diuresis occurs despite a significant reduction in GFR [6]; this diuresis is influenced by systemic factors linked to volume expansion [5, 6], which include reduced activity of the sympathetic nervous system, lower values of circulating aldosterone, and elevated values of urea, prostaglandin E2, and atrial natriuretic peptide [5, 6].

In our patient, the application of a handheld percussive device, and the use of anticoagulants likely combined to cause or exacerbate the right pelvic retroperitoneal hematoma and the obstructive uropathy. Handheld massage devices, which have become popular among sports medicine professionals, produce an effect like that of manual percussion or tapotement used in therapeutic massage [7]. We have found no reference of portable massage device-associated retroperitoneal hematoma or obstructive uropathy as in this case. RSHs resulting from abdominal trauma commonly stem from the rupture of the inferior epigastric arteries, particularly below the arcuate line where posterior rectus sheaths are absent [8]. Below this line (approximately 5 cm below the umbilicus), the rectus abdominal muscle and the epigastric vessels are separated from the peritoneum by only the transversalis fascia [8].

In a study of 126 patients with RSHs, 69% were receiving anticoagulation therapy, and the primary causes

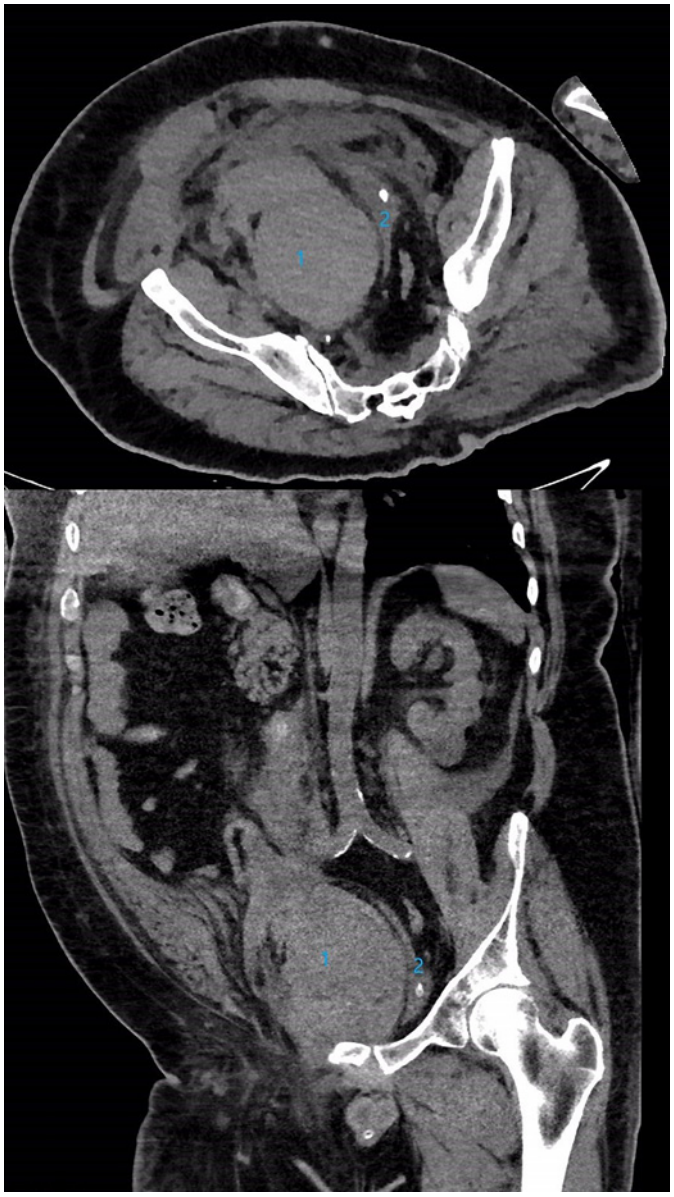

Fig. 1. Supine position axial and coronal oblique CT scan views of the abdomen and pelvis. Due to the patient's positioning, fully coronal images could not be obtained. The scans reveal a hematoma (labeled 1) compressing the bladder, with a Foley catheter (labeled 2) in situ.

of the RSHs were nonsurgical abdominal trauma, especially acute coughing spells, and recent abdominal surgery. Common findings were abdominal pain, an abdominal wall mass, and a decrease in hemoglobin (Hgb) levels by 0.4 g/dL or more. About half the patients had nonsurgical abdominal wall trauma, mainly due to coughing. Urine retention occurred in only 1.6% of the patients [9].

Although the role of a percussive device in the development of an RSH in this patient is uncertain, we feel it may have been at least a contributing factor. The possible risk of using such devices in patients with severe COVID-19 who are on anticoagulant therapy must be considered, as these patients have a high incidence of major bleeding [10], including spontaneous RSHs [4]. Indeed, the retrospective study by Emekli et al. [3] of 9,876 hospitalized COVID-19 patients receiving anticoagulants identified 0.12% (12 patients) who developed RSHs, with anticoagulant use ranging from 4 to 10.75 days at therapeutic doses. Symptoms leading to an RSH diagnosis included abdominal pain, sudden drops in Hgb, palpable mass, and ecchymosis. No cases of obstructive uropathy were reported. In the case reported here, RSH might have been suspected earlier because of the Hgb decrease from 14 to 12 g/dL within 24 h from day 8 to 9, alongside an acute drop in Na^+ concentration from 137 mmol/L to 131 mmol/L and a slight rise in serum UA from 7.1 mg/dL to 7.4 mg/dL without a concurrent increase in serum creatinine levels. This pattern suggests an RSH due to acute partial UUO from the expanding hematoma. While rising lactate dehydrogenase levels have been proposed as a predictor of RSH [11], in this case, the levels, although elevated, did not rise sequentially but rather decreased throughout the hospital stay.

Conclusion

In the context of acute abdominal pain during hospitalization, RSH is an uncommon yet important consideration, especially with a concurrent acute Hgb drop in patients receiving anticoagulation therapy. This is particularly pertinent in severe COVID-19 pneumonia. An acute decrease in serum Na^+ and an increase in UA followed by a decline in GFR support the diagnosis of RSH leading to urinary obstruction. The use of portable massagers for pain relief at injection sites should be suspected as a rare contributor to the development of RSH. The CARE Checklist was completed by the author of this case report, attached as supplementary material (for all online suppl. material, see https://doi.org/10.1159/000538709).

Statement of Ethics

As per the New York Medical College Ethics Committee, this study is exempt from requiring ethics approval. Nevertheless, it was conducted in compliance with the ethical standards of the Helsinki Declaration. Additionally, written informed consent for

the publication of the medical case details and any accompanying images was obtained from the patient's next of kin, following the patient's passing at the end of their hospitalization.

Conflict of Interest Statement

The author has no conflicts of interest to declare.

Funding Sources

This research did not receive any specific grant from funding agencies in the public, commercial, or not-for-profit sectors.

Author Contributions

Dr. Lawrence Kwon was solely responsible for the conceptualization, data collection, analysis, and manuscript preparation for this case report.

Data Availability Statement

Access to the patient files and datasets used in this study is restricted to protect privacy. Qualified investigators may request access to these confidential data. For data related to this case report, extracted from the electronic medical record, please direct inquiries to the corresponding author.

References

1 Dangle PP, Patel MB, Terán M, Chehval MJ. Obstructive uropathy secondary to rectus sheath hematoma. W V Med J. 2013;109(2):32–3.
2 Hoe V, Kinnear N, Christidis D, O'Connell H. Rectus sheath haematoma causing ureteric obstruction. BMJ Case Rep. 2018;2018: bcr2018225671.https://doi.org/10.1136/bcr-2018-225671.
3 Emekli E, Yıldırım M, Türkkanı MH, Ödemiş Başpınar E. Rectus sheath hematoma as a complication in patients with COVID-19: clinical and imaging findings. Cureus. 2023; 15(5):e38943. https://doi.org/10.7759/cureus.38943.
4 Özer M, Terzioglu SG, Keskinkılıç Yağız B, Gürer A, Dinç T, Coskun A. Does COVID-19 increase the incidence of spontaneous rectus sheath hematoma? Turkish J Trauma Emerg Surg. 2022;28(7):920–6. https://doi.org/10.14744/tjtes.2022.85681.
5 Yu ASL, Chertow GM, Luyckx VA, Marsden PA, Skorecki K, Taal MW. Brenner & rector's the kidney. 11th ed. Elsevier; 2020.
6 Wilson DR, Wilson DDR. Pathophysiology of obstructive nephropathy. Kidney Int. 1980;18(3): 281–92. https://doi.org/10.1038/ki.1980.138.
7 Cheatham SW, Baker RT, Behm DG, Stull K, Kolber MJ. Mechanical percussion devices: a survey of practice patterns among healthcare professionals. Int J Sports Phys Ther. 2021; 16(3):766–77. https://doi.org/10.26603/001c.23530.
8 Hatjipetrou A, Anyfantakis D, Kastanakis M. Rectus sheath hematoma: a review of the literature. Int J Surg. 2015;13:267–71. https://doi.org/10.1016/j.ijsu.2014.12.015.
9 Cherry WB, Mueller PS. Rectus sheath hematoma: review of 126 cases at a single institution. Medicine. 2006;85(2):105–10. https://doi.org/10.1097/01.md.0000216818.13067.5a.
10 Nakamura J, Tsujino I, Yachi S, Takeyama M, Nishimoto Y, Konno S, et al. Incidence, risk factors, and clinical impact of major bleeding in hospitalized patients with COVID-19: a sub-analysis of the CLOT-COVID Study. Thromb J. 2022;20(1):53. https://doi.org/10.1186/s12959-022-00414-x.
11 Mahmoudabadi HZ, Hadadi A, Fattahi MR, Kafan S, Ashouri M, Allahbeigi R, et al. Rectus sheath hematoma in COVID-19 patients as a mortal complication: a retrospective report. Int J Clin Pract. 2022;2022:7436827. https://doi.org/10.1155/2022/7436827.