

# Intravitreal bevacizumab for macular edema due to proton beam radiotherapy: Favorable results shown after eighteen months follow-up

Eleni Loukianou  
Dimitrios Brouzas  
Eleni Georgopoulou  
Chrysanthi Koutsandrea  
Michael Apostolopoulos

Eye Department, University of Athens,  
Athens, Greece

**Purpose:** To evaluate the safety and efficacy of intravitreal injections of bevacizumab (Avastin®) as a treatment option for radiation maculopathy secondary to proton beam radiotherapy for choroidal melanoma.

**Case:** A 61-year-old woman presented with a gradual decrease in left eye visual acuity (VA) 29 months after proton beam radiotherapy for choroidal melanoma. On presentation, her best-corrected VA (BCVA) was 2/10 in the left eye and the intraocular pressure was 15 mmHg. Fundoscopy revealed cystoid macular edema, intraretinal hemorrhages, epiretinal membrane in the posterior pole, and residual tumor scar with exudative retinal detachment and hard exudates in the periphery of the superotemporal quadrant. A treatment with intravitreal injections of bevacizumab (Avastin®) was recommended. The injections were performed on a six-weekly basis.

**Results:** The central retinal thickness prior to the treatment was 458  $\mu\text{m}$ . After the first intravitreal injection of bevacizumab, the retinal thickness at the centre of the fovea was reduced to 322  $\mu\text{m}$ . After the third injection, the central retinal thickness was 359  $\mu\text{m}$  and 18 months after presentation, it reduced to 334  $\mu\text{m}$ . The BCVA increased to 3/10 after the intravitreal injections of bevacizumab and remained stable during the follow-up period. The intraocular pressure was within normal range during the follow-up period.

**Conclusion:** Bevacizumab should be regarded as a treatment option for macular edema due to proton beam radiotherapy for choroidal melanoma. By reducing the central retinal thickness, intravitreal bevacizumab can improve VA or ameliorate further decline caused by radiation maculopathy.

**Keywords:** bevacizumab (Avastin®), choroidal melanoma, macular edema, radiation retinopathy

## Case report

A 61-year-old woman presented with a gradual decrease in left eye visual acuity (VA) 29 months after proton beam radiotherapy for choroidal melanoma. On presentation, her best-corrected visual acuity (BCVA) was 2/10 in the left eye and intraocular pressure was 15 mmHg. Ophthalmoscopy revealed cystoid macular edema, intraretinal hemorrhages and epiretinal membrane. Residual tumor with scar, exudative retinal detachment, and hard exudates were seen in the superotemporal periphery.

The patient was evaluated by fluorescein angiography and optical coherence tomography (OCT), and intravitreal injections of 1.25 mg bevacizumab (Avastin®) were recommended.

Correspondence: Eleni Loukianou  
12 Alkmanos St, Ilisia-Athens  
11528, Greece  
Tel +30 21 12216903  
Fax +30 21 12216903  
Email eleniloukianou@yahoo.com

The patient was informed that the therapy was off-label and signed a relevant consent form.

The central retinal thickness before treatment was 458  $\mu\text{m}$  (Figure 1) and a cystoid macular edema was evident on OCT and fluorescein angiography.

The procedure was carried out in the operation theatre. Topical proparacaine hydrochloride 0.5% was applied to the ocular surface followed by preparation with 5% povidone iodine. A cotton-tipped applicator soaked in proparacaine hydrochloride was applied to the injection site 4 mm posterior to the limbus. The intravitreal dose of bevacizumab (Avastin<sup>®</sup>) was 1.25 mg and we performed an intravitreal injection every six weeks. Indirect ophthalmoscopy was used to confirm uneventful intravitreal placement. Six weeks after the first intravitreal injection of bevacizumab (Avastin<sup>®</sup>), the central retinal thickness was reduced to 322  $\mu\text{m}$ . The VA improved to 3/10 and the intraocular pressure remained stable and a second injection was suggested. Six weeks after the second injection, the central retinal thickness increased to 377  $\mu\text{m}$ , and the patient was re-evaluated by ophthalmoscopy and OCT. A third intravitreal injection of bevacizumab was carried out and six weeks after the third injection, the central retinal thickness was reduced once again to 359  $\mu\text{m}$  (Figure 2). The VA was 3/10 and the intraocular pressure was

14 mmHg. At this point, treatment was discontinued and no further injections were recommended.

The patient was examined again 18 months after presentation. Her BCVA was 3/10 and intraocular pressure was 15 mmHg. Central retinal thickness was 334  $\mu\text{m}$ , as documented by OCT (Figure 3). The ophthalmoscopic findings were consistent with mild macular edema, epiretinal membrane, and residual tumor scar with exudative retinal detachment and hard exudates. The intraretinal hemorrhages have been absorbed.

Radiation retinopathy is a vision-threatening complication resulting from the therapeutic irradiation of ocular, orbital, periorbital, facial, nasopharyngeal, and cranial structures. It is a slow and progressive retinal microangiopathy with delayed-onset varying from 1 month to 15 years, but usually occurs within 3 years of treatment.<sup>1,2</sup> Clinical manifestations of the disorder include macular edema and nonproliferative and proliferative retinopathy, similar to changes seen in diabetic retinopathy. The fundamental abnormality of chronic radiation damage is endothelial cell injury, primarily in capillaries, followed by capillary closure (this can be revealed by fluorescein angiography), subsequent retinal ischemia, necrosis of nerve tissue, and fibrovascular proliferation.<sup>3</sup>

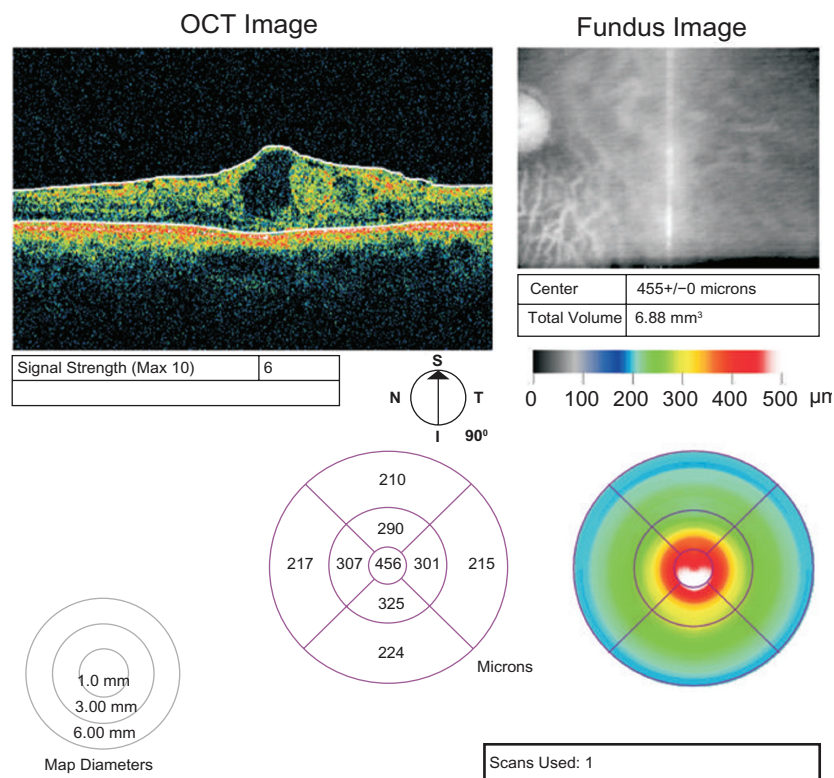


Figure 1 Central foveal thickness on presentation.

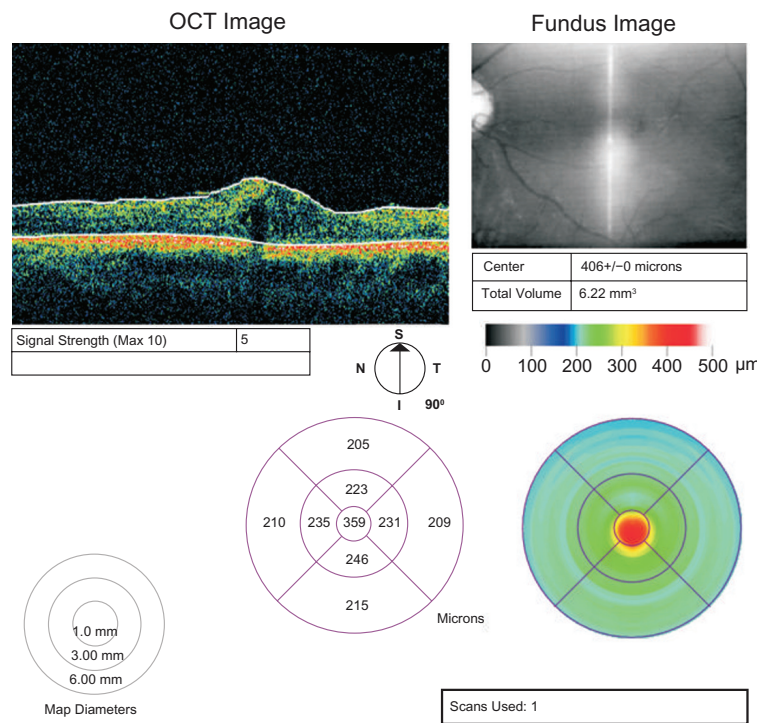


Figure 2 Central foveal thickness after the third intravitreal bevacizumab injection.

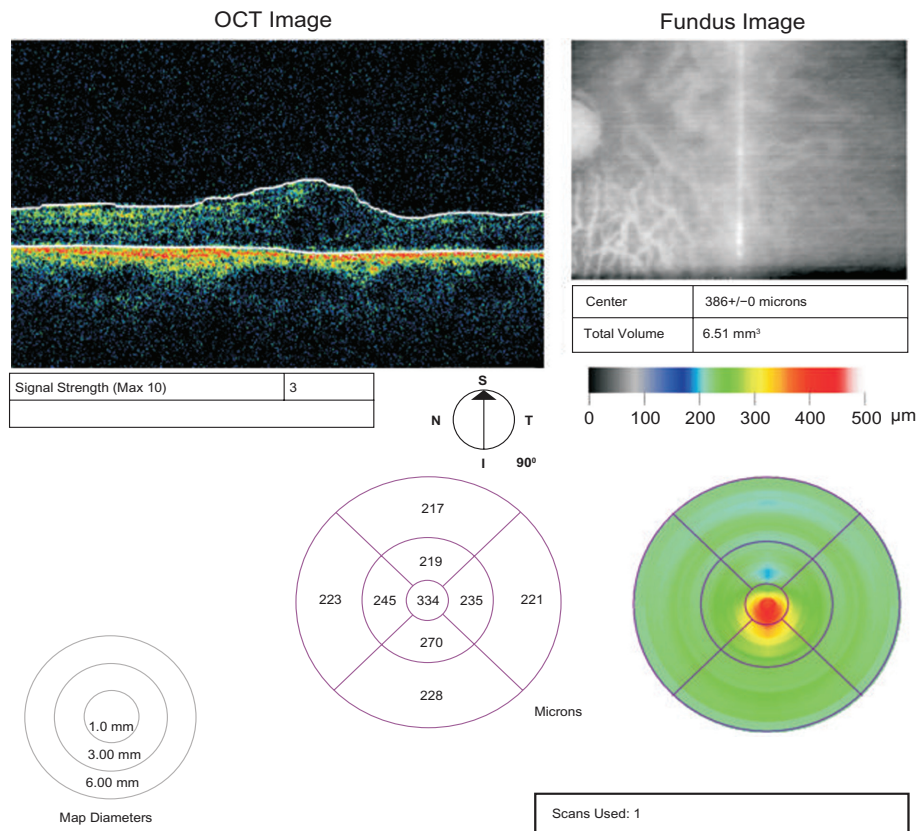


Figure 3 Central foveal thickness 18 months after presentation.

Consequently, increased concentrations of vascular endothelial growth factor (VEGF) were found in treated and untreated eyes with uveal melanoma.<sup>4,5</sup> The radiation macular edema can be treated with laser photocoagulation, photodynamic therapy, and intravitreal triamcinolone acetonide.<sup>6</sup> The macular edema may also respond to anti-VEGF therapy.<sup>7,8</sup> Bevacizumab is a recombinant humanized, full length, anti-VEGF monoclonal antibody that binds with all VEGF-A isoforms.

This case report suggests that cystoid macular edema, caused by proton beam radiotherapy for choroidal melanoma, responds to intravitreal injections of bevacizumab. This is shown by the reduction of the central retinal thickness on OCT. Also, anti-VEGF therapy seems to prevent further reduction and shows improved VA. The advantages of this treatment over the triamcinolone acetonide treatment are: the absence of intraocular pressure increase and cataract formation. Given that no serious side effects were observed, bevacizumab should be regarded as a treatment option for macular edema due to proton beam radiotherapy for choroidal melanoma.

## Disclosures

The authors report no conflicts of interest in this work.

## References

1. Brown GC, Shields JA, Sanborn G, Augsburger JJ, Savino PJ, Schatz NJ. Radiation retinopathy. *Ophthalmology*. 1982;89:1494–1501.
2. Wara WM, Irvine AR, Neger RE, Howes EL Jr, Phillips TL. Radiation retinopathy. *Int J Radiat Oncol Biol Phys*. 1979;5:81–83.
3. Irvine AR, Alvarado JA, Wara WM, Morris BW, Wood IS. Radiation retinopathy: An experimental model for the ischemic-proliferative retinopathies. *Trans Am Ophthalmol Soc*. 1981;79:103–122.
4. Missotten GS, Notting IC, Schlingemann RO, et al. Vascular endothelial growth factor A in eyes with uveal melanoma. *Arch Ophthalmol*. 2006;124:1428–1434.
5. Boyd SR, Tan D, Bunce C, et al. Vascular endothelial growth factor is elevated in ocular fluids of eyes harbouring uveal melanoma: identification of a potential therapeutic window. *Br J Ophthalmol*. 2002;86:368–369.
6. Shields CL, Demirci H, Dai V, et al. Intravitreal triamcinolone acetonide for radiation maculopathy after plaque radiotherapy for choroidal melanoma. *Retina*. 2005;25:868–874.
7. Finger PT. Radiation retinopathy is treatable with anti-vascular endothelial growth factor bevacizumab (Avastin). *Int J Radiat Oncol Biol Phys*. 2008;15;70(4):974–977.
8. Mason JO 3rd, Albert MA Jr, Persaud TO, Vail RS. Intravitreal bevacizumab treatment for radiation macular edema after plaque radiotherapy for choroidal melanoma. *Retina*. 2007;27(7):903–907.

### Therapeutics and Clinical Risk Management

### Publish your work in this journal

Therapeutics and Clinical Risk Management is an international, peer-reviewed journal of clinical therapeutics and risk management, focusing on concise rapid reporting of clinical studies in all therapeutic areas, outcomes, safety, and programs for the effective, safe, and sustained use of medicines. This journal is indexed on PubMed Central, CAS,

Submit your manuscript here: <http://www.dovepress.com/therapeutics-and-clinical-risk-management-journal>

Dovepress

EMBASE, Scopus and the Elsevier Bibliographic databases. The manuscript management system is completely online and includes a very quick and fair peer-review system, which is all easy to use. Visit <http://www.dovepress.com/testimonials.php> to read real quotes from published authors.