



Analysis of the Chest Wall Reconstruction Methods after Malignant Tumor Resection

Gang Yeon Jo, MD¹ Sae Hwi Ki, MD, PhD^{1,2}

¹Department of Plastic and Reconstructive Surgery, Inha University Hospital, Incheon, South Korea

²Department of Plastic and Reconstructive Surgery, School of Medicine, Inha University, Incheon, South Korea

Address for correspondence Sae Hwi Ki, MD, PhD, Department of Plastic and Reconstructive Surgery, Inha University School of Medicine, 27 Inhang-ro, Jung-gu, Incheon 400-711, South Korea (e-mail: mdkee0923@gmail.com).

Arch Plast Surg 2023;50:10–16.

Abstract

Background The chest wall defects can be caused by various reasons. In the case of malignant tumor resection of the chest wall, it is essential to reconstruct the chest wall to cover the vital tissue and restore the pulmonary function with prevention of paradoxical motion. With our experience, we analyzed and evaluated the results and complications of the chest wall reconstructions followed by malignant tumor resection.

Methods From 2013 to 2022, we reviewed a medical record of patients who received chest reconstruction due to chest wall malignant tumor resection. The following data were retrieved: patients' demographic data, tumor type, type of operation, method of chest wall reconstruction of the soft and skeletal tissue and complications.

Results There were seven males and six female patients. The causes of reconstruction were 12 primary tumors and one metastatic carcinoma. The pathological types were seven sarcomas, three invasive breast carcinoma, and three squamous cell carcinomas. The skeletal reconstruction was performed in six patients. The series of the flap were eight pedicled latissimus dorsi (LD) myocutaneous flaps, two pectoralis major myocutaneous flap, two vertical rectus abdominis myocutaneous free flap, and one LD free flap. Among all the cases, only one staged reconstruction and successful reconstruction without flail chest. Most of the complications were atelectasis.

Conclusion In the case of accompanying multiple ribs and sternal defect, skeletal reconstruction would need skeletal reconstruction to prevent paradoxical chest wall motion. The flap for soft tissue defect be selected according to defect size and location of chest wall. With our experience, we recommend the reconstruction algorithm for chest wall defect due to malignant tumor resection.

Keywords

- ▶ malignant tumor
- ▶ chest wall tumor
- ▶ chest wall reconstruction

Introduction

Primary chest wall malignant tumor is rare and represents about 5% of all thoracic neoplasms.^{1–4} It is from various origins, including bones and cartilage, skin, muscles, blood

vessels, nerves, and even some hematologic disorder.⁴ The chest wall that allows to breathe and pump blood to be delivered to whole body is a complex and protective structure of the vital organ, which is possible due to the integrity of all the chest wall layers.⁵ Chest wall reconstruction needs

received
February 27, 2022
accepted
November 2, 2022

DOI <https://doi.org/10.1055/s-0042-1760290>.
eISSN 2234-6171.

© 2023. The Korean Society of Plastic and Reconstructive Surgeons. All rights reserved.

This is an open access article published by Thieme under the terms of the Creative Commons Attribution-NonDerivative-NonCommercial-License, permitting copying and reproduction so long as the original work is given appropriate credit. Contents may not be used for commercial purposes, or adapted, remixed, transformed or built upon. (<https://creativecommons.org/licenses/by-nc-nd/4.0/>)

Thieme Medical Publishers, Inc., 333 Seventh Avenue, 18th Floor, New York, NY 10001, USA

Table 1 Patients demography, medical history, surgical complications

	Number
Age	16–77 y (57 y)
Sex	
Male	7 (54%)
Female	6 (46%)
DM	3 (23%)
Hypertension	1 (8%)
Coronary artery occlusive disease	1 (8%)
Tuberculosis	1 (8%)
Symptoms	
Mass	7 (54%)
Bleeding	3 (23%)
Pain	3 (23%)
Pathological diagnosis	Number
Sarcoma	
Fibrosarcoma	4 (23%)
Chondrosarcoma	2 (8%)
Pleomorphic sarcoma	1 (8%)
Squamous cell carcinoma	3 (23%)
Invasive breast carcinoma	3 (23%)

skeletal and soft tissue reconstruction. Skeletal support to prevent a flail chest and subsequent respiratory failure is important for the successful management of chest wall malignant tumor.⁶ If the reconstruction of the chest wall failed, it could result in serious life-threatening condition. Reconstructive surgeon should take various factors into consideration that can affect chest wall reconstruction, especially in multiple ribs resection case or sternotomy case to restore chest wall integrity. The treatment methods of malignant chest wall tumor are reported previously, however, there are no clear conclusions yet about the complication rate based on the number of resected ribs; the methods for skeletal fixation depend on location and defect size. Even though there are not many cases of malignant chest wall tumor due to its prevalence, we retrospectively reviewed and analyzed our experience with malignant chest wall tumor resection followed by chest wall reconstruction.

Materials and Methods

This study is a retrospective review. From April 2013 to February 2022, medical records of patients with chest wall defect due to chest wall tumor were collected. In the cases, patients who needed the chest wall reconstruction as malignant tumor arising from structures that support the thorax, including bone, cartilage, and associated soft tissue, were included in this study. Patients who had the chest wall

reconstruction as malignant tumor arising from structures that support the thorax, including bone, cartilage, and associated soft tissue, were included in this study. Medical records, such as gender, age, pathology of chest wall carcinoma, surgical record, such as size of the tumor excision and defect, method of reconstruction, and surgical outcomes were collected. The materials used, method of skeletal fixation, and location of skeletal reconstruction were noted in cases of skeletal reconstruction.

Results

The total number of cases that met the required criteria is 13 (► **Tables 1** and **2**). There were seven males and six females. Mean age was 57.0 years (range, 16–77 years). The causes of the chest wall defect were nine primary chest tumors, three breast cancer, and one metastatic carcinoma from laryngeal cancer. In pathological details of the tumors, there were four fibrosarcoma, three squamous cell carcinoma, three invasive carcinoma of breast, two chondrosarcoma, and one pleomorphic sarcoma (► **Table 1**). The most common symptoms were palpable mass (54%) and bleeding (23%). The size of soft

Table 2 Factors influencing for reconstruction

Factors.	Number (%)
Indication	
Primary chest wall tumor	9 (69%)
Breast cancer	3 (23%)
Laryngeal cancer	1 (8%)
Defect size	
100 cm ² <	4 (31%)
100 cm ² ≥	9 (69%)
Defect type	
Only a Soft tissue defect	7 (54%)
Skeletal and soft tissue defect	6 (46%)
Reconstruction methods	
Latissimus dorsi (LD) musculocutaneous rotation flap	8 (62%)
Vertical rectus abdominis myocutaneous (VRAM) free flap	2 (15%)
Pectoralis major muscle advancement flap	2 (15%)
Latissimus dorsi (LD) free flap	1 (8%)
Rib resection	
Yes	6 (46%)
No	7 (54%)
Multiple ribs (>3)	6 (46%)
Sternal resection	
Partial sternotomy	1 (8%)
Total sternotomy	1 (8%)

tissue chest wall defect was from 54 to 230 cm² (mean: 151.8 cm²). Six cases had necessary skeletal reconstruction due to multiple rib defects and sternal defects. Chest wall tumor resection and reconstruction were performed in all patients simultaneously. Five patients had postoperative radiotherapy.

The process of skeletal reconstruction method as an algorithm was presented based on our experiences. For soft tissue defect, considering rotation arc and defect size, local flap was first choice if possible. If rotation arc was not available or defect size was too large to perform local flap, free flap was selected with appropriate donor. For stabilization of skeletal structure, metal plates and screws and artificial material were used for skeletal reconstruction (►Figs. 1, 2) (►Table 3). The location of defect is as follows: five middle lateral defect, four median defect, two posterolateral defect, one upper lateral defect, and one inferolateral defect. Appropriate flap selection according to the defect size and location was conducted (►Table 4). In soft tissue reconstruction, there were eight latissimus dorsi musculocutaneous (LDMC) rotation flap (►Fig. 1), two pectoralis major musculocutaneous (PMMC) flap, two vertical rectus abdominis musculocutaneous (VRAM) free flap (►Fig. 2), and one LDMC free flap. All flaps survived. Two patients had partial necrosis of the flap treated with debridement

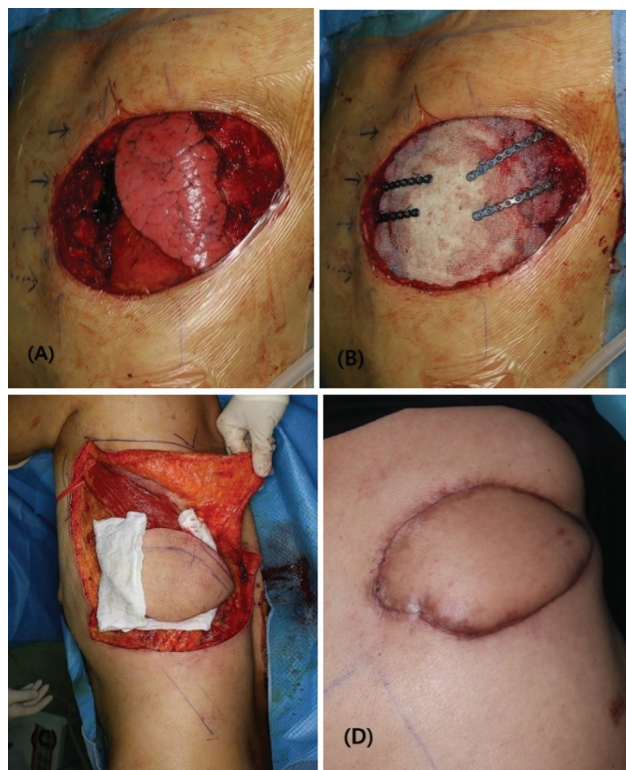

Fig. 1 Case 1. (A) Anterolateral chest wall defect including second to fifth rib resection. Exposed lung and pericardium. (B) Skeletal reconstruction with bone cement, titanium plate, and Marlex mesh. (C) Soft tissue reconstruction with pedicled latissimus myocutaneous flap. (D) Final result after partial necrosis due to surgical site infection.

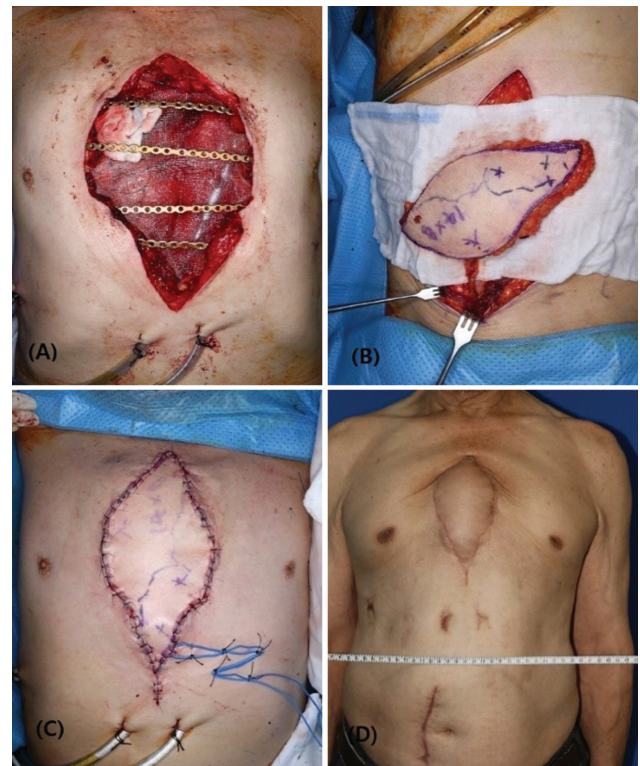

Fig. 2 Case 2. (A) Midline chest wall defect including third to sixth rib resection and total sternum. Exposed lung and pericardium. (B) Skeletal reconstruction with titanium plate, screw, and Prolene mesh. (C) Soft tissue reconstruction with free vertical rectus abdominis myocutaneous flap. (D) Final result.

and secondary wound healing. There were six postoperative pulmonary complications: four temporary atelectasis, one pneumonia, and one acute respiratory distress syndrome treated with conservative pulmonary care and antibiotics. Three patients had postoperative chemotherapy and five patients had postoperative radiotherapy. Two patients complained temporary limitation of shoulder mobilization after radiotherapy. The mean follow-up period was 11.52 months (range, 6–30 months).

Discussion

Chest wall tumors are not common and are presented with different symptoms. Patients usually get symptomatic with palpable mass or pain and both symptoms at the site of tumor.^{2,7,8} Defects of the chest wall occur due to tumor ablation, radiation injury, infection, and trauma.⁹ Chest wall may be reconstructed with musculocutaneous flaps, such as latissimus dorsi (LD) musculocutaneous flap or free flaps combined with the synthetic or autologous materials used to prevent pneumothorax and paradoxical chest wall motion.

According to previous studies, importance of rigid stability for the prevention of uncoordinated chest wall motion is unclear. In addition, there is no direct association between the number of resected ribs and the need for

Table 3 Our reconstruction methods for skeletal reconstruction

Patient	Defect location	Defect size	Skeletal defect	Reconstruction method	Material
Patient 1	Median	15 × 15 cm ²	Six ribs removed Sternum resected	VRAM free flap	Goretex Titanium plate with screw
Patient 2	Infero-lateral	11 × 20 cm ²	Four ribs removed	LD free flap	Goretex
Patient 3	Mid-lateral	15 × 7 cm ²	Four ribs removed	LD rotation flap	Marlex mesh and bone cement Titanium plate with screw and wire
Patient 4	Midian/inferior-Medial	12 × 8 cm ²	Eight ribs removed Sternum resected	VRAM free flap	Prolene mesh Titanium plate with screw and wire
Patient 5	Mid-lateral	10 × 8 cm ²	Three ribs removed	LD rotation flap	Prolene mesh
Patient 6	Infero-lateral	15 × 15 cm ²	Four ribs resected	LD rotation flap	Prolene mesh and bone cement Titanium plate with screw and wire

Abbreviations: LD, latissimus dorsi; VRAM, vertical rectus abdominis musculocutaneous.

Table 4 Flap selection according to the defect size and location

Defect location	Average defect size	Reconstruction method	Number of cases
Mid-lateral	136 cm ²	First choice: LD rotation flap Second choice: LD free flap	Five cases
Median	159 cm ²	First choice: VRAM free flap Second choice: Pectoralis major muscle advancement flap	Four cases
Postero-lateral	119 cm ²	First choice: LD rotation flap Second choice: Serratus anterior perforator flap	Two cases
Infero-lateral	225 cm ²	First choice: LD rotation flap Second choice: LD free flap	One case
Upper lateral	54 cm ²	First choice: LD rotation flap Second choice: LD free flap	One case

Abbreviations: LD, latissimus dorsi; VRAM, vertical rectus abdominis musculocutaneous.

skeleton reconstruction. After chest wall resection, however, skeletal reconstruction is necessary to protect intrathoracic contents as well as to preserve respiratory capacity in our experiences.

Previous history of radiotherapy is a factor that makes surgery difficult because of radiation-induced tissue toxicity. Some of the studies revealed that radiation reduces osteogenic cell numbers, alters cytokine capacity, and delays or damages bone remodeling. It can affect the chest wall stability and immunity.¹⁰ Therefore, in those cases, we favored skeletal reconstruction with metal plate with musculocutaneous flap when the patient had a radiation history. The lack of sternal or spinal stability in antero/anterolateral aspect makes the patient more prone to flail chest deformities following chest wall resection.^{11,12} The method of skeletal reconstruction of the

chest wall depends on the location, number of the ribs loss, and the size of the defect. Deschamps et al said, skeletal reconstruction is not necessary in cases, such as the skeletal defect with less than 5 cm diameter sized, the very apex of the chest, under the scapula and very close to the vertebrae.⁹ The thickness of the muscle at anterior and lateral chest wall is thinner than that of the muscle at posterior chest wall and fragile, so whenever defect of the anterior and lateral chest wall is greater than 5 cm, skeletal reconstruction with autologous or artificial materials is mandatory and most of them simultaneously need soft tissue flap reconstruction.¹³ When four or more ribs are resected, skeletal reconstruction is necessary in chest wall reconstruction.^{12,14} In five patients, more than four ribs were removed during surgery and they had skeletal operation in our study. There were no significantly different

Table 5 Comparison of complication with other authors

Author	No.	Surgical site infection	Flap loss	Myocardial infarction	Respiratory	Arrhythmia	Seroma/Hematoma	Other
Kachroo et al.	51	2	1	0	1	1	0	5
Deschamps et al.	197	9	0	3	48	5	14	12
Mansour et al.	200	9	10	0	38	5	3	4
Our research	14	1	2	0	6	1	0	0

Abbreviation: ARDS, acute respiratory distress syndrome.

outcomes compared with other patients in our study. As per research by Scarnecchia et al, multiple resected ribs (≥ 4) influenced the incidence of deformities. Furthermore, a significant statistical correlation was found between the site of demolition and the incidence of chest wall deformities and flail chest. Patients who underwent chest wall reconstruction in anterior or lateral chest area get significant aggravation of chest wall stability so that they are vulnerable to get acute respiratory complications, flail chest, and deformities of the chest wall.¹² Early trials at chest wall resection were severely restricted by the availability of appropriate materials for reconstruction. Primary materials consisted of autogenous tissue such as fascia lata grafts, rib grafts, or large cutaneous grafts.^{3,15} Since the 1980s, the prosthetic materials including poly-tetrafluoroethylene, polypropylene mesh, and polypropylene mesh-methyl methacrylate have been used in conjunction with musculocutaneous flaps to successfully reconstruct even the largest chest wall defects.⁹ These materials can provide structural stability and support the mechanical forces applied during respiration. When patients underwent two to three ribs resection without sternal resection, surgeons could reconstruct the soft tissue defect without skeletal reconstruction. When multiple ribs (≥ 4) or sternal resection is performed, metal plates and screw fixation is considered in mostly cases for structural stability. The useful materials for chest wall reconstruction have utilized a variety of synthetic patches, meshes, or acellular dermal matrix (ADM).¹⁶ We thought adequate mesh usage helps to provide good skeletal support and pliability. Prolene, Marlex, and PTPE mesh were often used. Alloplastic materials can be used to get advantage due to lack of donor-site morbidity, wide availability, and sizing options for coverage of large defects. Plastic surgeon can use synthetic grafts such as expanded polytetrafluoroethylene and ADM to reconstruct chest wall. Some researchers favor ADM for reconstruction, when there are concerns related to field contamination, active infection, or delayed wound healing.¹⁶ The choice of suitable materials for skeletal reconstruction of chest wall is still controversial. Even though rigid materials compared to non-rigid materials are more vulnerable to infection and can disrupt physiological respiratory movement, there are some advantages such as providing stability and being inexpensive. Because of prioritizing early stability over late stability, we per-

formed chest wall reconstruction using rigid material, especially in multiple ribs resection case or sternotomy case.¹⁷ Recently, preoperative computed tomography with reconstructed three-dimensional (3D) images may be used as reference for manufacturers to customize more unusual implant configurations.^{18,19}

The partial thickness loss of the soft tissue defect of the chest wall can be repaired with skin grafts or local flap. Sometimes, unilateral, or bilateral PMMC pectoralis and serratus muscle can be used for soft tissue coverage. The availability of reconstructive options with well-vascularized tissue allows wide and appropriate resection and helps to ensure successful long-term outcomes.¹⁴ The greater omentum is often available as the reconstructive method provides well-vascularized tissue to areas of extensive radiation damage or infection.²⁰ It was described by Jurkiewicz in 1977, for the coverage of anterior chest wall. In our cases, LDMC flap is preferred to reconstruct defect on lateral aspect of chest wall. The unilateral or bilateral PMMC flap is preferred for the defect of anterior aspect of chest wall around midline. Free flap was considered when regional flaps were unavailable, for large-sized defect, or previously failed reconstruction. We used the LD free flap and VRAM free flap.

Complications after chest wall resection are relatively common. Deschamps et al said that overall postoperative complication rate was 46% and the most common complication was respiratory complication (42.8%).⁹ In our study, the proportion of respiratory complication was high (46%) even though most of these were temporary atelectasis. Number of complications reported in previous studies was compared with our study^{9,13,21} (► **Table 5**). Destruction of chest integrity and pain may lead to prolonged respiratory support and pulmonary complications in the postoperative period. Despite the increased rate of postoperative pneumonia, the period of intensive care unit and admission was not increased in our patients.

In conclusion, with our experience, we recommend our reconstruction algorithm for chest wall with the defect due to malignant tumor resection (► **Fig. 3**). The limitation of this study is that we had relatively few cases and it was difficult to determine the effect of reconstructive surgery on pulmonary function because pulmonary function test was not performed before surgery. Further research is necessary by comparing preoperative respiratory function with the postoperative respiratory function.

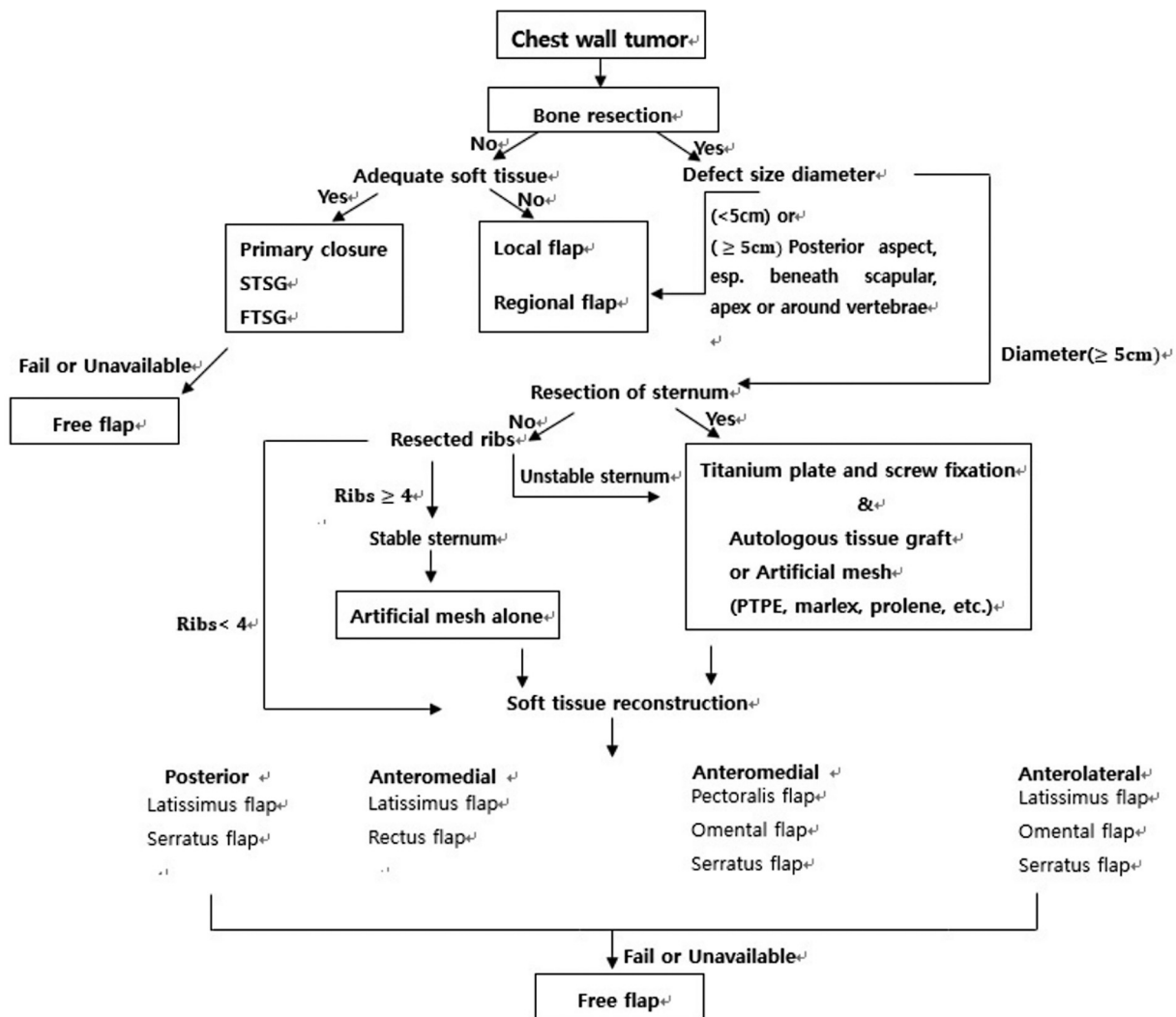


Fig. 3 Our reconstruction algorithm for chest wall defect due to malignant tumor resection

Authors' Contributions

Writing original draft: G.Y.J., Review and editing: S.H.K. Supervisor: S.H.K. All authors read and approved the final manuscript.

Ethical Approval

The study was approved by the Institutional Review Board of Inha University Hospital (IRB_POPDS_1001).

Patient Consent

Patients provided written informed consent for the publication and the use of their images.

Conflict of Interest

S.H.K. is an editorial board member of the journal but was not involved in the peer reviewer selection, evaluation, or decision process of this article. No other potential conflicts of interest relevant to this article were reported.

References

- Graeber GM, Snyder RJ, Fleming AW, et al. Initial and long-term results in the management of primary chest wall neoplasms. *Ann Thorac Surg* 1982;34(06):664–673
- Threlkel JB, Adkins RB Jr. Primary chest wall tumors. *Ann Thorac Surg* 1971;11(05):450–459
- Incarbone M, Pastorino U. Surgical treatment of chest wall tumors. *World J Surg* 2001;25(02):218–230
- Hsu PK, Hsu HS, Lee HC, et al. Management of primary chest wall tumors: 14 years' clinical experience. *J Chin Med Assoc* 2006;69(08):377–382
- Novoa NM, Aranda Alcaide JLuis, Gomez Hernández MTeresa, Fuentes MG, Ender Goñi, Jimenez Lopez MF. Chest wall- reconstruction: yesterday, today, and the future. *Shanghai Chest* 2019; 3:15
- Weyant MJ, Bains MS, Venkatraman E, et al. Results of chest wall resection and reconstruction with and without rigid prosthesis. *Ann Thorac Surg* 2006;81(01):279–285
- Edaigbini SA, Delia IZ, Aminu MB, et al. Reconstruction of the chest wall after excision of a giant malignant peripheral nerve sheath tumor. *Niger J Clin Pract* 2012;15(04):484–486

- 8 Bagheri R, Haghi SZ, Kalantari MR, et al. Primary malignant chest wall tumors: analysis of 40 patients. *J Cardiothorac Surg* 2014;9:106
- 9 Deschamps C, Tirnaksiz BM, Darbandi R, et al. Early and long-term results of prosthetic chest wall reconstruction. *J Thorac Cardiovasc Surg* 1999;117(03):588–591, discussion 591–592
- 10 Jegoux F, Malard O, Goyenville E, Aguado E, Daculsi G. Radiation effects on bone healing and reconstruction: interpretation of the literature. *Oral Surg Oral Med Oral Pathol Oral Radiol Endod* 2010;109(02):173–184
- 11 Losken A, Thourani VH, Carlson GW, et al. A reconstructive algorithm for plastic surgery following extensive chest wall resection. *Br J Plast Surg* 2004;57(04):295–302
- 12 Scarnecchia E, Liparulo V, Capozzi R, Ceccarelli S, Puma F, Vanucci J. Chest wall resection and reconstruction for tumors: analysis of oncological and functional outcome. *J Thorac Dis* 2018;10(suppl 16):S1855–S1863
- 13 Thakur B, BoTZ, Lamichhane N, Shrestha BM, Neupane PR, Dudani R. Retrospective study of chest wall tumors at a cancer hospital in Nepal. *Nepal Med Coll J* 2005;7(01):39–42
- 14 Mansour KA, Thourani VH, Losken A, et al. Chest wall resections and reconstruction: a 25-year experience. *Ann Thorac Surg* 2002;73(06):1720–1725, discussion 1725–1726
- 15 Arnold PG, Pairolero PC. Chest-wall reconstruction: an account of 500 consecutive patients. *Plast Reconstr Surg* 1996;98(05):804–810
- 16 Sodha NR, Azoury SC, Sciortino C, Sacks JM, Yang SC. The use of acellular dermal matrices in chest wall reconstruction. *Plast Reconstr Surg* 2012;130(5, suppl 2):175S–182S
- 17 Colella S, Brandimarte A, Marra R, et al. Chest wall reconstruction in benign and malignant tumors with non-rigid materials: an overview. *Front Surg* 2022;9:976463
- 18 Turna A, Kavakli K, Sapmaz E, et al. Reconstruction with a patient-specific titanium implant after a wide anterior chest wall resection. *Interact Cardiovasc Thorac Surg* 2014;18(02):234–236
- 19 Ng CS. Recent and future developments in chest wall reconstruction. *Semin Thorac Cardiovasc Surg* 2015;27(02):234–239
- 20 Jurkiewicz MJ, Arnold PG. The omentum: an account of its use in the reconstruction of the chest wall. *Ann Surg* 1977;185(05):548–554
- 21 Kachroo P, Pak PS, Sandha HS, et al. Single-institution, multidisciplinary experience with surgical resection of primary chest wall sarcomas. *J Thorac Oncol* 2012;7(03):552–558