

# Hemolytic Anemia and Gastric Carcinoid in a Russian Seafarer: Highlighting the Role of Diagnostic Technologies in Modern Clinical Practice

Tafadzwa L. Chaunzwa<sup>a,\*</sup>, Jesse O'Shea<sup>b</sup>, Nathan A. Boggs<sup>b</sup>, Jeremy I. Schwartz<sup>c</sup>, Joanna Gibson<sup>d</sup>, and Katherine A. Gielissen<sup>c</sup>

<sup>a</sup>Yale School of Medicine, New Haven, CT; <sup>b</sup>Yale Primary Care Program, Yale New Haven Hospital, New Haven, CT; <sup>c</sup>Section of General Internal Medicine, Yale School of Medicine, New Haven, CT; <sup>d</sup>Department of Pathology, Yale School of Medicine, New Haven, CT

Vitamin B-12 deficiency, most commonly due to pernicious anemia, can cause intramedullary hemolysis. The pathogenesis is thought to be due to increased membrane rigidity and reduced red blood cell elasticity, which predisposes the patient to hemolysis and microangiopathic hemolytic anemia. In this article, we discuss a Russian engineer who worked aboard a petroleum tanker that presented from his ship with profound B-12 deficiency, microangiopathic anemia, elevated lactate dehydrogenase levels, low haptoglobin, and reticulocyte count in the setting of normal renal and neurologic function. The patient traveled around the world seven months of the year for work and had occupational exposure to fluorinated hydrocarbons. Extensive diagnostic work-up, including endoscopic biopsy, and a radio-labeled octreotide scan was performed. The patient was found to have autoimmune gastritis and a gastric carcinoid tumor. With assistance from his global health insurance provider and a local hospital near his hometown in Russia, care was coordinated to be transitioned there with a plan for repeat endoscopy and mapping biopsies to determine the extent of his tumor burden. This study adds to the now growing base of literature describing this atypical presentation of pernicious anemia with normal neurologic function and underscores the importance of screening for B-12 deficiency in these patients. It also highlights the increased risk of gastric carcinoids in patients with autoimmune gastritis. With the collaboration of different medical specialists, the full gamut of medical technology was utilized in the care of the patient. This included *in vitro* diagnostics, advanced endoscopic tools, pathology, and radio-isotope based imaging studies.

## INTRODUCTION

Severe vitamin B-12 (cobalamin) deficiency can cause ineffective erythropoiesis and has been associated with intramedullary hemolysis [1]. The most common

cause of vitamin B-12 deficiency is pernicious anemia, which often presents with neurologic dysfunction, given cobalamin's role in myelination [1,2]. Gastric carcinoids are rare neuroendocrine tumors that can also be associated with pernicious anemia and autoimmune disease [3].

\*To whom all correspondence should be addressed: Tafadzwa L. Chaunzwa, Yale University School of Medicine, 333 Cedar Street, New Haven, CT 06510; Tel: 339-222-7932, Email: tafadzwa.chaunzwa@yale.edu.

†Abbreviations: TIGC, Type I Gastric Carcinoid; TTP, Thrombotic thrombocytopenic purpura; ECL, Enterochromaffin-like cells.

Keywords: hemolysis, anemia, carcinoid

In this article we discuss an international patient presenting with atypical pernicious anemia, found to have a Type I gastric carcinoid (TIGC+) requiring extensive work-up.

## CASE PRESENTATION

A 43-year-old Russian electrical engineer with no significant past medical history who worked aboard a petroleum tanker presented with nausea, fatigue, and shortness of breath. He first noted nausea one month prior to presentation, which progressed to vomiting, loss of appetite, and palpitations. His family history was significant for gastric malignancy in his grandfather. The patient traveled around the world seven months of the year for work, and his most recent travels had been to Europe and the United States. He reported eating a balanced diet aboard the ship. His review of systems and physical exam were unremarkable except for pallor and mild cervical lymphadenopathy. He had no paresthesias, weakness, gait abnormality, altered mental status, jaundice or tongue soreness. Initial laboratory results showed hemoglobin 5.4 g/dL (12.0-18.0 g/dL), hematocrit of 15.4% (37.0-52.0%), mean corpuscular volume 100 fL (78.0-94.0 fL), reticulocytes 2% (0.6-2.7%), platelets 67,000/uL (140,000-440,000/ $\mu$ L), white blood cell count  $5.2 \times 10^9$ /L ( $4-10 \times 10^9$ /L), total bilirubin 2.0 mg/dL (0.2-1.2 mg/dL), and direct bilirubin 0.4mg/dL (<0.2mg/dL). A peripheral blood smear showed schistocytes.

### Assessment

A workup for hemolysis revealed a haptoglobin of 0 mg/dL (20-198 mg/dL) and lactate dehydrogenase of 6,000 U/L (118-273 U/L). Workup of his macrocytosis revealed a vitamin B-12 level of 32 pg/mL (179-1132 pg/mL), methyl-malonic acid of 12.1  $\mu$ mol/L (<0.40  $\mu$ mol/L), and homocysteine of 92.4  $\mu$ mol/L (5-15  $\mu$ mol/L). Further history was negative for raw fish consumption, though social history did reveal he had exposure to solvents in his work tasks, which included intermittent cleaning of engine parts with a hydrocarbon-based solvent ("Electrosolve"). His neurologic examination, including vibratory sensation, strength, reflexes, and vision, remained normal. He remained cognitively intact. HIV, hepatitis, malaria, babesia, diphyllobothrium latum, and stool O&P testing were all negative.

Given concerns for malabsorption, endoscopic biopsies were performed, which identified atrophic gastritis and the presence of TIGC on one random biopsy of the gastric body (Figure 1). Antral biopsies showed reactive gastropathy and *Helicobacter pylori* was not identified.

Fasting serum gastrin levels were found to be markedly elevated at 498 pg/mL (reference <100 pg/mL) and gastric parietal cell antibodies were present. Radio-

labeled octreotide scan to stage the tumor was negative for isotope uptake, indicating the absence of a gastrin-secreting tumor.

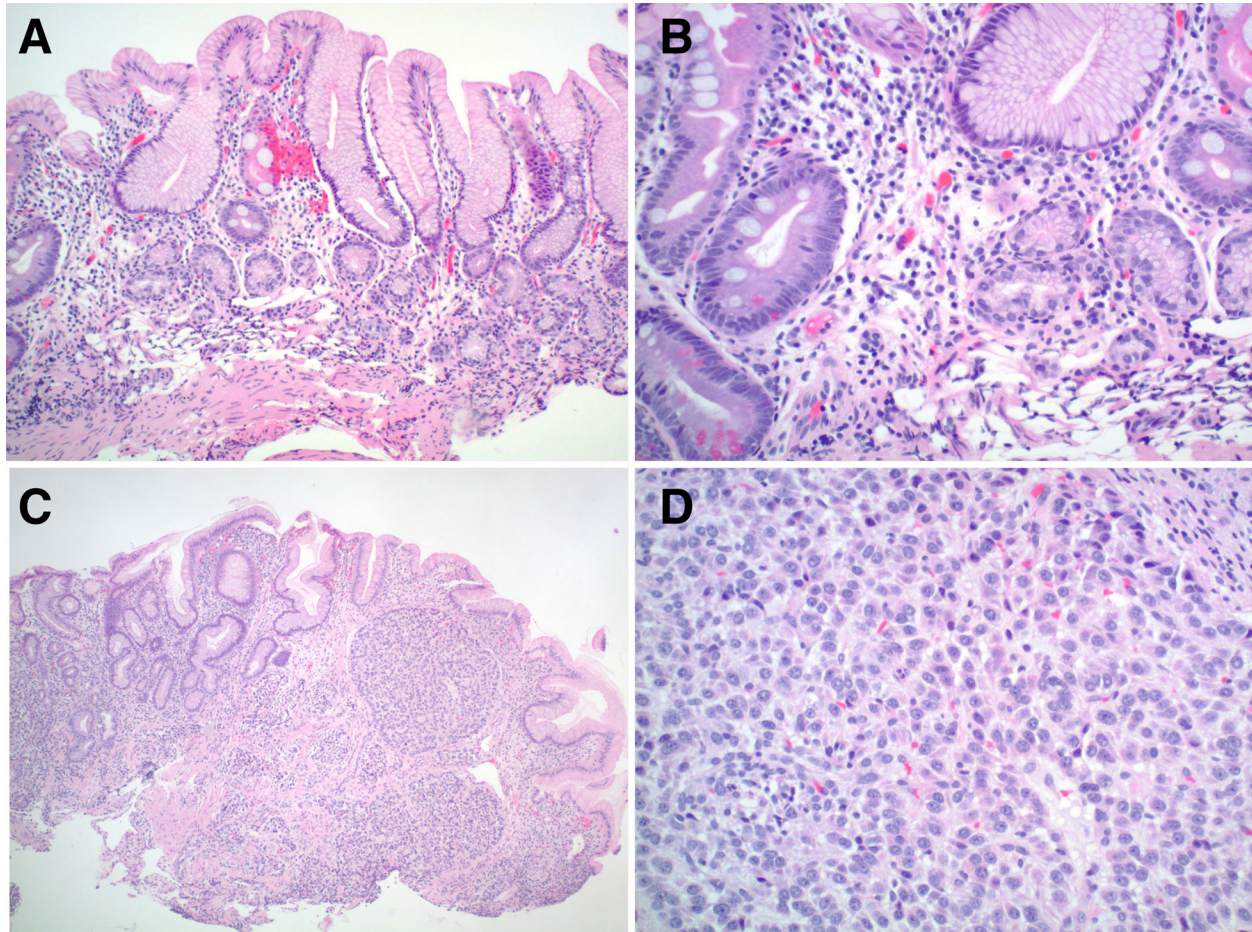
## DISCUSSION

Though rare, a few other case reports have documented similar cases of atypical pernicious anemia with elevated lactate dehydrogenase, low haptoglobin, and no neurologic deficits [4,5]. This is thought to be due to increased membrane rigidity and reduced red blood cell elasticity, which predisposes to hemolysis and microangiopathic hemolytic anemia [4,6]. The lactate dehydrogenase levels were much higher than that seen typically in Thrombotic thrombocytopenic purpura (TTP) (1000-1200) [4]. This underscores the importance of screening for vitamin B-12 in patients presenting with the combination of thrombocytopenia, microangiopathic anemia, and macrocytosis but without renal impairment and an inappropriately low reticulocyte count [4].

Additionally, chlorofluorocarbons have been linked to vitamin B-12 deficiency, macrocytic anemia, and neurologic abnormalities in a single case report [7]. The patient had potential occupational exposure to fluorinated hydrocarbons, such as Electrosolve. While our patient's exposures are limited, given intermittent exposures to small amounts, it is an interesting consideration for his presentation.

Patients with pernicious anemia are at increased risk for gastric carcinoid, presumably due to up-regulation of serum gastrin. Hyperstimulation of enterochromaffin-like (ECL) cells in the context of hypochlorhydria from atrophic gastritis leads to ECL hyperplasia and development of TIGC [8]. Autoimmune gastritis may predispose to gastric carcinoids or adenocarcinomas in up to 10 percent of patients. This provides rationale for screening, early diagnosis, and treatment, such as endoscopy [3,9].

Through a multispecialty effort, a wide range of technologies were utilized in the care of this patient, including *in vitro* diagnostics, advanced endoscopic tools, and scintigraphic imaging. *In vitro* diagnostics tests, which are for the most part performed on medical devices in hospital laboratories, and account for a large proportion of all clinical diagnoses, were used to assess the patient's blood and other tissue samples. Gastroenterologists performed an esophagogastroduodenoscopy (EGD) on the patient, utilizing illuminated optical technology on advanced tubular instrumentation to examine the upper gastrointestinal tract. This nonsurgical procedure can be used for both diagnostic and therapeutic purposes. Scintigraphic imaging, taking advantage of radionuclide uptake patterns in physiologic and diseased states was performed by the nuclear medicine service. Given the suspicion for neuroendocrine malignancy in this patient, an octreotide



**Figure 1.** **A.** Low power view of gastric body biopsies showing complete oxyntic gland atrophy pseudopyloric metaplasia, and intestinal metaplasia. **B.** High power view of atrophic gastric body mucosa with pseudopyloric metaplasia, intestinal metaplasia, and neuroendocrine cell hyperplasia. **C.** Low power view of well-differentiated neuroendocrine cell tumor within atrophic mucosa. **D.** High power view of neuroendocrine cell tumor showing homogenous cells in clusters, cords, and trabeculae with uniform nuclei.

scan was performed. The logistics and rationale for using these diagnostic medical technologies were discussed with the patient and guided by his clinical presentation.

## CONCLUSIONS

The patient was treated with intramuscular vitamin B-12 1000mcg daily for 1 week, followed by weekly injections planned for 4 weeks with a plan to inject monthly thereafter indefinitely. Haptoglobin, lactate dehydrogenase, and complete blood count improved after initiation of therapy. The patient was discharged home to Russia with assistance from his international health insurance provider, and a local hospital near his hometown. Care was coordinated to be transitioned to the Russian hospital with a plan for repeat endoscopy with mapping biopsies

to determine the extent of his neuroendocrine tumor burden. It is likely he will require lifelong endoscopic surveillance.

## REFERENCES

1. Sri LH, Manchandani RP, Oneal P. Pernicious Anemia with Autoimmune Hemolytic Anemia: A Case Report and Literature Review. *Case Rep Hematol.* 2016;1-4: <https://doi.org/10.1155/2016/7231503>.
2. Miller A, Korem M, Almog R, Galboiz Y. Vitamin B12, demyelination, remyelination and repair in multiple sclerosis. *J Neurol Sci.* 2005;233(1-2):93–7.
3. Postlewait LM, Baptiste GG, Ethun CG et al. A 15-Year Experience with Gastric Neuroendocrine Tumors: Does Type Make a Difference? *J Surg Oncol.* 2016;114(5):576–80.
4. Dalsania CJ, Khemka V, Shum M, Devereux L,

- Lachant NA. A Sheep in Wolf's Clothing. *Am J Med.* 2008;121(2):107–9.
5. Garderet L et al. Schizocytosis in pernicious anemia mimicking thrombotic thrombocytopenic purpura. *Am J Med.* 2003;114(5):423–5.
  6. Ballas SK, Saidi P, Constantino M. Reduced Erythrocytic Deformability in Megaloblastic Anemia. *Am J Clin Pathol.* 1976;66:953–7.
  7. Bhaskar H, Chaudhary R. Vitamin B12 Deficiency due to Chlorofluorocarbon: A Case Report. *Case Rep Med.* 2010;2010:3–6.
  8. Vannella L, Lahner E, Annibale B et al. Risk for gastric neoplasia in patients with chronic atrophic gastritis: A critical reappraisal. *World J Gastroenterol.* 2012;18(12):1279–85.
  9. Toh B, Chan J, Kyaw T, Alderuccio F. Cutting Edge Issues in Autoimmune Gastritis. *Clin Rev Allergy Immunol.* 2012 Jun;42(3):269–78.