

Comparing *in-vivo* confocal microscopy and ex-vivo light and scanning electron microscopy images of the hairs of the pine processionary caterpillar embedded in the cornea: Report of three cases

Francisco Pérez-Bartolomé, Jorge Peraza-Nieves¹,
 JI Fernández-Vigo², Rosalía Méndez-Fernández²,
 Julio Gonzalez Martín-Moro³,
 Pedro Arriola-Villalobos²

This report describes three cases of pine processionary caterpillar hairs (setae) embedded in the cornea: one in a 69-year-old man with acute keratouveitis, a second case in a 65-year-old man with an epithelial defect and a stromal infiltrate, and the third case affecting a 54-year-old woman with mild keratitis. The two first patients had one hair embedded in the anterior corneal layers while the last one had several hairs deeply embedded in the stroma. By comparing *in-vivo* confocal microscopy (IVCM) with ex-vivo light microscopy (LM) and scanning electron microscopy (SEM) images, the morphology of the setae was identified and confirmed.

Key words: *In-vivo* confocal microscopy, keratitis, light microscopy, processionary caterpillar, scanning electron microscopy

Accidental contact with the hairs of the pine processionary caterpillar *Thaumetopoea pityocampa* can induce from mild keratitis to severe systemic reactions.^[1-5] The morphology of these hairs, or setae, on *in-vivo* confocal microscopy (IVCM) seems to be pathognomonic.^[6] We here describe three cases in which processionary caterpillar hairs were found embedded

in the cornea. The diagnosis was confirmed by IVCM, scanning electron microscopy (SEM), and light microscopy (LM).

Case Reports

Case 1

A 69-year-old man presented at the emergency room with intense pain in his left eye [oculus sinister (OS)]. Symptoms had started 3 days after visiting a pine forest. On slit-lamp examination (SLE), the OS showed a small central epithelial defect, a diffuse infiltrate in the adjacent stroma, mild stromal edema and folds in Descemet's membrane [Fig. 1a]. We observed a small elongated brown foreign body in the middle of the stroma that resembled a caterpillar hair. In an anterior segment optical coherence tomography (AS-OCT) (Heidelberg Engineering GmbH, Heidelberg, Germany), a hyperreflective point could be seen in the anterior stroma [Fig. 1b]. IVCM (Heidelberg IVCM HRTIII-Rostock Cornea Module) revealed a harpoon-shaped foreign body compatible with a processionary caterpillar seta [Fig. 1c].

Treatment was topical dexamethasone 1 mg/ml tapered, ofloxacin 3 mg/ml, and cyclopentolate 1mg/ml. Within two weeks, the pain and inflammation subsided although the hair was still visible in the corneal stroma.

Case 2

A 65-year-old man presented at the emergency room because of pain in his OS starting a few hours previously. He reported having been walking near a pinewood and felt something enter his eye, realizing later it was a caterpillar which he brought to our center. On SLE, the OS showed a paracentral infiltrate in the middle and deep stroma without epitheliopathy. Adjacent to the infiltrate, several long, thin brown foreign bodies were observed [Fig. 2a]. In an AS-OCT, hyperreflective lines could be seen, one of which had penetrated the corneal endothelium [Fig. 2b]. On IVCM, we detected multiple spiculated hairs, similar to those observed in Case 1 [Fig. 2c]. In LM and SEM images of the caterpillar brought by the patient, we could distinguish spicules on the hairs [Figs. 2d-f and 3]. In response to the same treatment as in Case 1, inflammation resolved within three weeks.

Case 3

A 54-year-old woman presented at the emergency room complaining of mild pain in her OS after having spent the previous day in her garden. On biomicroscopy, a long brown foreign body was detected on the epithelium in the OS [Fig. 4a]. AS-OCT revealed no apparent injury. On IVCM, we detected a long foreign body with spicules on its margins compatible

Access this article online	
Quick Response Code:	Website: www.ijo.in
	DOI: 10.4103/ijo.IJO_1735_19

Department of Ophthalmology, Hospital Universitario Ramón y Cajal, Universidad Alcalá de Henares, ²Department of Ophthalmology, Hospital Clínico San Carlos, Universidad Complutense de Madrid, ³Department of Ophthalmology, Hospital del Henares, Coslada, Universidad Francisco de Vitoria, Madrid, ¹Department of Ophthalmology, Hospital Clínic, Barcelona, Spain

Correspondence to: Dr. Francisco Pérez-Bartolomé, Department of Ophthalmology, Hospital Universitario Ramón y Cajal, Ctra. Colmenar Viejo, Km. 9, 100, 28034 Madrid, Spain. E-mail: Franciscoperezbartolome@gmail.com

Received: 25-Sep-2019

Revision: 18-Dec-2019

Accepted: 20-Feb-2020

Published: 24-Jul-2020

This is an open access journal, and articles are distributed under the terms of the Creative Commons Attribution-NonCommercial-ShareAlike 4.0 License, which allows others to remix, tweak, and build upon the work non-commercially, as long as appropriate credit is given and the new creations are licensed under the identical terms.

For reprints contact: WKHLRPMedknow_reprints@wolterskluwer.com

Cite this article as: Pérez-Bartolomé F, Peraza-Nieves J, Fernández-Vigo JI, Méndez-Fernández R, Gonzalez Martín-Moro J, Arriola-Villalobos P. Comparing *in-vivo* confocal microscopy and ex-vivo light and scanning electron microscopy images of the hairs of the pine processionary caterpillar embedded in the cornea: Report of three cases. Indian J Ophthalmol 2020;68:1672-5.

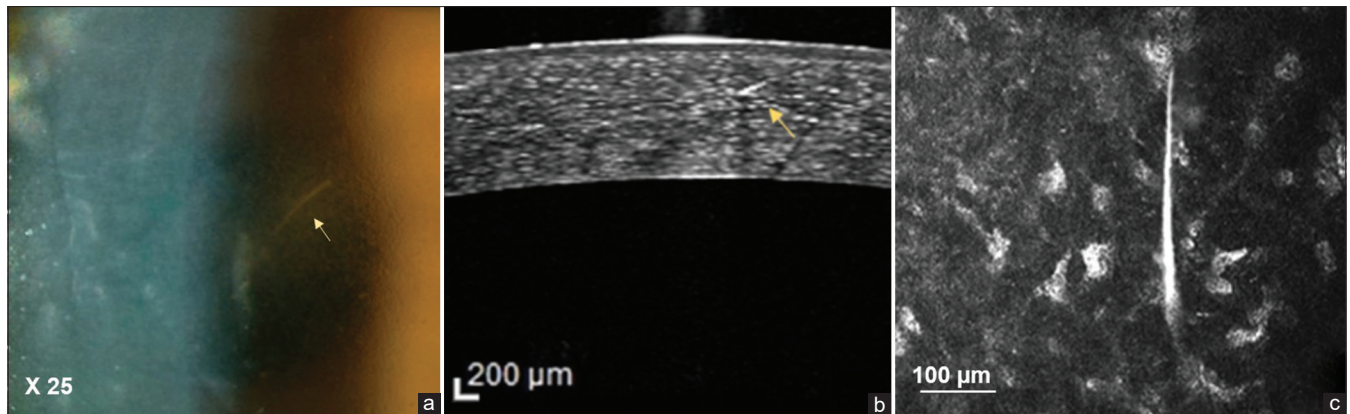


Figure 1: Patient 1: (a) Slit lamp: elongated brown foreign body compatible with the hair of a processionary caterpillar. (b) Anterior segment optical coherence tomography (AS-OCT): hyperreflective point in the anterior stroma with adjacent indirect hyporeflectivity. (c) *In vivo* confocal microscopy (IVCM): harpoon-shaped foreign body consisting of a stalk with spicules orientated towards its sharp tip

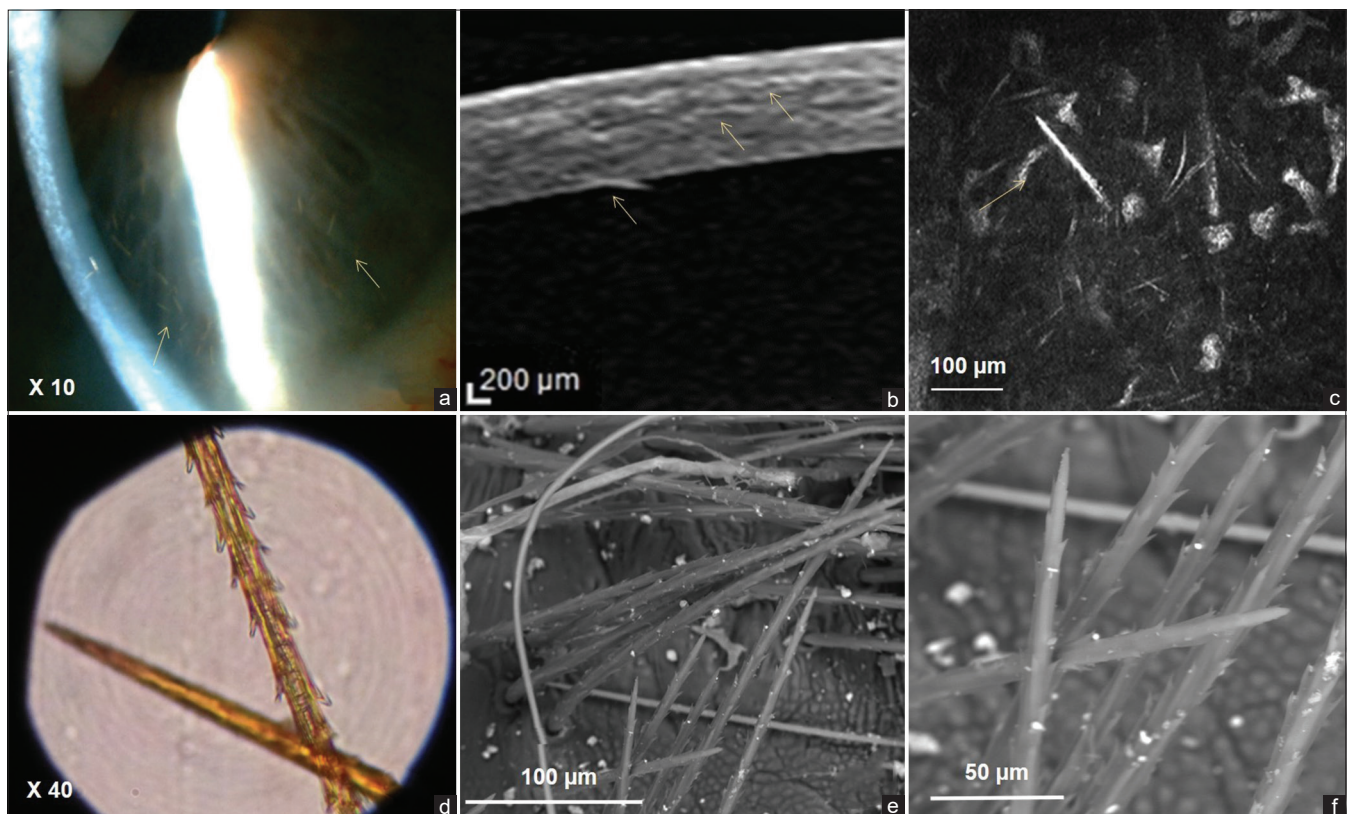


Figure 2: Patient 2: (a) Slit lamp: elongated thin brown foreign bodies. (b) AS-OCT: numerous hyperreflective lines compatible with caterpillar hairs, one of which can be seen to cross into the corneal endothelium. (c) IVCM: multiple spiculated foreign bodies similar to those of the previous case. (d) Bright field microscopy (BFM) of the hairs obtained from the caterpillar brought by the patient showing numerous spicules orientated towards the hair tip. (e and f) Scanning electron microscopy (SEM) of the caterpillar revealed the similar morphology of the hairs observed by LM and IVCM

again with the hairs of the processionary caterpillar [Fig. 4b]. After removing the hair with a cotton swab, LM and SEM observations confirmed the similar seta morphology as in the previous case [Fig. 4c and d]. In response to the same treatment as described for Cases 1 and 2, inflammation resolved in two weeks.

Discussion

The hairs of the pine processionary caterpillar are lethal airborne weapons able to penetrate the skin or ocular surface

producing a broad spectrum of disorders. The pathogenic mechanism could be mechanical irritation through contact with the spiculated sharp-tipped hairs or a massive immune reaction resulting in overlapping of allergic and non-allergic responses. The protein thaumetopoein found in the caterpillar's hairs is capable of inducing immunoglobulin E (IgE)-dependent basophil degranulation.^[7] Despite an antigen stimulus of similar magnitude (one hair) in two of our patients, Case 1 showed a likely allergic keratouveitis with intense inflammation, while




Figure 3: Stereomicroscopy and SEM of the caterpillar. (a-c). Stereomicroscopy image showing at increasing magnification the size ratio between the body and hairs of the caterpillar. (d-f). SEM micrograph showing the characteristic spicules at increasing magnification




Figure 4: Patient 3: (a) A single elongated brown foreign body on the surface of the epithelium penetrating into the mid stroma without evident corneal inflammation. (b) IVCM revealed a hyperreflective foreign body on the surface of the epithelium with the same serrated edges as in patients 1 and 2. (c) BFM of the hair extracted from the cornea of the patient. The same serrated edges with spicules facing the hair tip were observed as in the BFM image obtained in patient 2. (d) SEM of the hair removed

in Case 3 there was only mildly irritating keratitis. The deeper position of the embedded hair in Case 1 could explain this allergic reaction. Similarly, a high antigen load in the second case triggered an inflammatory response that was not as intense as in Case 1 and only in the deep corneal stroma. Thus, it seems that not only the antigen load is responsible for variation in symptom intensity.

Epithelial debridement and removal of embedded hairs are controversial because of iatrogenic risks. When pulled, hairs may break into smaller fragments, which may exacerbate the inflammatory reaction by releasing new toxins.^[6] Corneal perforation is rare but has been described.^[4,8]

Imaging the cornea with non-invasive techniques such as IVCM is useful to confirm a suspected diagnosis made after SLE, and also to locate, and assess the size and shape of the foreign body.^[6] The hairs found here showed a pathognomonic morphology: hyper-reflective, non-branched, tiny linear foreign bodies with sharp tips and serrated edges consisting of spicules pointing towards the tips. These are the main features that distinguish them from corneal nerves.^[5] Some authors report that AS-OCT offers images of sufficiently high resolution to assess the location, size, and depth of hairs and to monitor their possible migration, which is useful for planning surgical removal.^[5,9] However, in Case 3, we were unable to locate the embedded hair by AS-OCT while IVCM was successful as it offers information at the cellular level. As limitations of IVCM, we should mention that it requires specific training and image interpretation is subjective. Furthermore, because it is a contact technique, it may exacerbate symptoms.^[6]

Conclusion

To the best of our knowledge, this is the first study to compare the use of IVCM, SEM, and LM to examine the morphology of pine processionary caterpillar setae inducing keratitis. IVCM emerged as a useful diagnostic tool recommended when the etiology of corneal inflammation is uncertain.

Acknowledgements

The authors acknowledge the help provided by María de la Concepción Magaña Loarte at the Forensic Anatomy Department of the Complutense University Medical School

of Madrid and Department of Non-destructive Techniques of the Natural Science Museum of Madrid.

Declaration of patient consent

The authors certify that they have obtained all appropriate patient consent forms. In the form the patient(s) has/have given his/her/their consent for his/her/their images and other clinical information to be reported in the journal. The patients understand that their names and initials will not be published and due efforts will be made to conceal their identity, but anonymity cannot be guaranteed.

Financial support and sponsorship

Nil.

Conflicts of interest

There are no conflicts of interest.

References

1. Portero A, Carreño E, Galarreta D, Herreras JM. Corneal inflammation from pine processionary caterpillar hairs. *Cornea* 2013;32:161-4.
 2. Ramesh Bhat Y, Vinayaka G, Sushma S. Systemic allergic reaction to a caterpillar in a 3-month-old infant. *Ann Trop Paediatr* 2010;30:83-6.
 3. Cadera W, Pachtman MA, Fountain JA, Ellis FD, Wilson FM. Ocular lesions caused by caterpillar hairs (ophthalmia nodosa). *Can J Ophthalmol* 1984;19:40-4.
 4. Sengupta S, Reddy PR, Gyatsho J, Ravindran RD, Thiruvengadakrishnan K, Vaidee V. Risk factors for intraocular penetration of caterpillar hair in Ophthalmia Nodosa: A retrospective analysis. *Indian J Ophthalmol* 2010;58:540-3.
 5. Shibui H, Kawashima H, Kamata K, Sasaki H, Inoda S, Shimizu H. Vitrectomy for caterpillar seta-induced endophthalmitis. *Arch Ophthalmol* 1997;115:555-6.
 6. Jullienne R, He Z, Manoli P, Grivet D, Cinotti E, Perrot JL, *et al.* *In vivo* confocal microscopy of pine processionary caterpillar hair-induced keratitis. *Cornea* 2015;34:350-2.
 7. Vega JM, Moneo I, García-Ortiz JC, González-Muñoz M, Ruiz C, Rodríguez-Mahillo AI, *et al.* IgE sensitization to *thaumetopoea pityocampa*: Diagnostic utility of a setae extract, clinical picture and associated risk factors. *Int Arch Allergy Immunol* 2014;165:283-90.
 8. González-Martín-Moro J, Contreras-Martín I, Castro-Rebollo M, Fuentes-Vega I, Zarallo-Gallardo J. Focal cortical cataract due to caterpillar hair migration. *Clin Exp Optom* 2019;102:89-90.
 9. Mantopoulos D, Cruzat A, Hamrah P. *In vivo* imaging of corneal inflammation: New tools for clinical practice and research. *Semin Ophthalmol* 2010;25:178-85.
-