

An Unusual Acute Cyanide Intoxication

Abstract

Suicide with cyanides is relatively rare but highly lethal. The lethal oral dose of cyanide salts is 200 mg, and concentrations >3 mg/L may be potentially lethal. The symptoms of poisoning are predominating in the central nervous system and cardiovascular system. We report the case of a 43-year-old goldsmith man who presented with self-poisoning by cyanide salt ingestion. Patient's symptoms included confusion, cardiac arrhythmias, hyperkalemia, leukocytosis, metabolic acidosis with high anion gap, hypotension, and then hypertension. The cause of the patients poisoning was not initially diagnosed. Intensive supportive treatment was performed. The patient died on the 3rd day of admission following cardiac arrest. At autopsy, hemorrhagic gastritis and cherry-red discoloration of the chest muscles were observed. Forensic toxicology showed cyanide in the blood and tissues. Cyanide poisoning could appear in different forms, and like our case, the symptoms can last for several days with nonspecific symptoms.

Keywords: Cyanides, poisoning, suicide, symptom

Introduction

Suicide with pure cyanides (CN) is relatively rare.^[1] Hydrogen CN (HCN), sodium CN, and potassium CN are extremely toxic and highly lethal. CN used in some industries such as metallurgy, electroplating of gold, chemical processes, and laboratory, and unfortunately in criminal activity, illicit euthanasia, and suicide attempts.^[2] Suicide with CN is one of the methods used by goldsmiths and chemists.^[3] CN exerts its toxic effects by induces cellular hypoxia and followed by connecting to the ferric atom and inhibiting intracellular cytochrome oxidase at the cytochrome a3c portion of the electron transport chain, and leading to rapid disruption of vital functions.^[2]

CN salts release HCN gas in contact with water and gastric acid. Unlike HCN gas, symptoms caused by the ingestion of cyanogenic chemicals can be delayed for 3–24 h. The lethal oral dose of CN salts is 200 mg, and a whole-blood CN level in excess of 2.5 mg/L is associated with coma and respiratory depression and concentrations >3 mg/L may be potentially lethal. Elimination half-life of CN is 1.2–66 h.^[2,3]

This is an open access journal, and articles are distributed under the terms of the Creative Commons Attribution-NonCommercial-ShareAlike 4.0 License, which allows others to remix, tweak, and build upon the work non-commercially, as long as appropriate credit is given and the new creations are licensed under the identical terms.

For reprints contact: WKHLRPMedknow_reprints@wolterskluwer.com

Acute CN poisoning symptoms include headache, vertigo, confusion, palpitations, metabolic acidosis, acute respiratory failure, and hyperventilation. It can rapidly progress to a coma, hypotension, bradycardia, seizures, cardiorespiratory arrest, shock, and death.^[1-2] The treatment of CN toxicity includes immediate supportive management, decontamination (gastric lavage and activated charcoal), correction of acidosis, crystalloids, and vasopressors for hypotension and antidotal therapy.^[4] The most commonly used effective antidotes are hydroxocobalamin and combination of sodium nitrite and sodium thiosulfate.^[5]

The signs and symptoms of an unusual case of CN salts compounded suicide were described. This case has nonspecific and long-lasting symptoms. Furthermore, significant findings have been observed in its autopsy.

Case Report

A 43-year-old goldsmith man with a past history of addiction and hypertension was transferred by the emergency service due to decreased consciousness and unknown poisoning. The patient was referred to the medical toxicology department of Khorshid Hospital in Isfahan on January

Gholamali Dorooshi, Amin Dorostkar¹, Alireza Rahimi², Shafeajafar Zoofaghari

From the Department of Clinical Toxicology, Isfahan Clinical Toxicology Research Center, Khorshid Hospital, ¹Isfahan Clinical Toxicology Research Center, Medical Student Research Committee, Isfahan University of Medical Sciences, ²Clinical Informationist Research Group, Health Information Research Center, Isfahan University of Medical Sciences, Isfahan, Iran

Address for correspondence:

Dr. Gholamali Dorooshi,
Department of Clinical Toxicology, Isfahan Clinical Toxicology Research Center, Khorshid Hospital, Isfahan, Iran.
E-mail: gdorvashy@med.mui.ac.ir

Access this article online

Website: www.advbiores.net

DOI: 10.4103/abr.abr_128_20

Quick Response Code:



How to cite this article: Dorooshi G, Dorostkar A, Rahimi A, Zoofaghari S. An unusual acute cyanide intoxication. Adv Biomed Res 2020;9:42.

Received: 02 June 2020

Revised: 03 June 2020

Accepted: 09 June 2020

Published: 28 August 2020

30, 2018. The patient had a history of suicidal thoughts and committed suicide several times in the past with different drugs. The patient had used opium, alcohol, and recently methadone. Patient medications history includes captopril, amlodipine, and diazepam. On examination, the patient was lethargic. The pupils were miotic and reactive. Deep-tendon reflexes were +2. The distal pulses were weakened, but heart and lung examinations were normal. Initial vital signs included a body temperature of 36.8°C, heart rate at 69/min, a respiratory rate of 14/min, blood pressure at 85/45 mmHg, and 90% finger pulse oximetry. Mismatch between pulse rate and blood pressure was observed. Metabolic and respiratory acidosis with a high anion gap (30.6) and hyperkalemia were observed in tests (venous blood PH: 7.028, PCO₂: 75.1 kPa, PO₂: 27 kPa, HCO₃: 18.8 mmol/L, base excess: -13.3 mmol/L, K: 7 and Na: 137).

In the 1st h of hospitalization, the patient had severe thirst. Blood pressure had dropped (80/50 mmHg), and the pulse rate gradually elevated. Conservative management with normal saline, intravenous sodium bicarbonate, and then vasopressor were started. Electrocardiogram revealed wide QRS complex tachycardia. The patient was then shocked twice with 100 and 200 joules, and then, 150 mg of amiodarone was injected. The echocardiogram showed conserved ventricular function with an ejection fraction of 55%. The patient intubated and was transferred to the intensive care unit (ICU). Brain computed tomography scan was normal.

In ICU, blood pressure was not detected. The patient was given calcium gluconate, magnesium sulfate, insulin plus dextrose, hydrocortisone, N-acetylcysteine, and norepinephrine infusion. The central venous catheter was inserted. Blood pressure increased for a few hours but decreased again. On the second day, the patient regained

consciousness and said he had taken a CN-containing compound. Nephrology consult was performed, and the patient was dialyzed for 4 h.

In the next few hours, the patient's condition became unstable again. On the 3rd day, refractory hyperkalemia and cardiac arrhythmias, especially ventricular tachycardia, and severe change in paraclinical tests (high PCO₂, gradual decrease in SPO₂, leukocytosis, gradual decrease in platelet count, increase in creatinine, international normalized ratio, alanine aminotransferase, aspartate aminotransferase, creatine phosphokinase, and lactate dehydrogenase) were the important patient symptoms. These can indicate progression to pulmonary edema and multiorgan failure. The patient died of cardiac arrest 63 h after admission despite prolonged cardiopulmonary resuscitation) [Figure 1].

In postmortem investigations, smell of bitter almond was terrifying. The gastric mucosa was highly inflammatory and completely irritated. Chest muscles showed marked cherry-colored appearance. Forensic toxicology showed CN in blood and tissues.

Discussion

In this report, we presented the case of fatal CN poisoning that had some nonspecific and prolonged signs and symptoms. Suicide with all types of CNs is rarely seen in the clinical toxicology wards of Iran and especially Isfahan due to the severity of the poisoning, which leads to patient's death before admission in the hospital. However, according to the Forensic Medicine Organization, in cases of fatal poisoning, CN poisoning is significant.^[6] CN poisoning in our goldsmith patient was suicidal and often occurred in specific jobs such as jewelry store in Iran.^[6] The early clinical effects of CN poisoning are generalized, nondiagnostic, and nonspecific.^[2] Thereby,

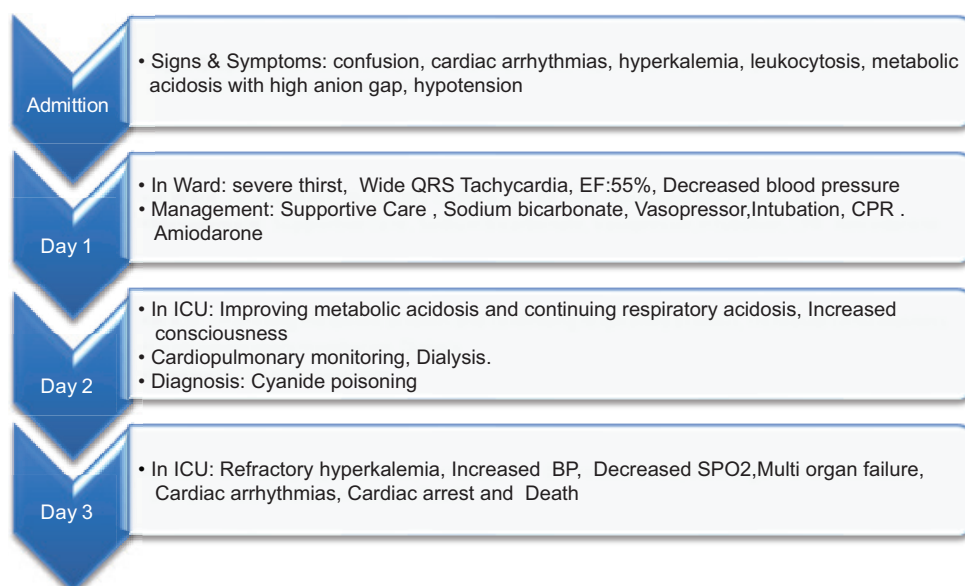


Figure 1: Timeline of progress of patient during admission

it is difficult to diagnose toxicity correctly and quickly, that's why our patient's poisoning has not been diagnosed. Clinical manifestations are due to rapid dysfunction of oxygen-sensitive organs. The findings are predominating in CNS and cardiovascular system.^[2] The typical seriously poisoned patient has a loss of consciousness, hyperventilation, hypotension, and bradycardia.^[7] The most of these symptoms were observed in the reported case. Laboratory findings include elevated venous oxygen saturation, increased anion gap severe metabolic acidosis, and elevated lactate concentration.^[2,5] Unlike many studies, our patient's venous PO₂ was normal with no seizures.

Unfortunately, in this case, the diagnosis and consequently treatment were delayed due to the lack of proper history and unavailability of serum CN, lactate, and other toxin levels. In the US, 74% of CN poison patient do not receive an antidote, mostly because of the failure of the initial treatment team to diagnosis the poisoning.^[8] In our country, none of CNs antidotes are easily available because of sanctions. A smell of bitter almonds and cherry-red skin color are uncommon and were not noticeable in our patient. Electrocardiographic changes in CN are nonspecific, and the most important finding of our case was ventricular tachycardia. Unlike this case, it was reported in previous cases that eye pupils were mydriatic and responsive to light.^[4,9]

Gastrointestinal CN toxicity occurs after the ingestion of CN salts and causes hemorrhagic gastritis, and as a result, abdominal pain, nausea, and vomiting. Hemorrhagic gastritis is frequently seen on autopsy and is secondary to corrosive nature of these salts. This complication is only seen in prolonged CN poisoning.^[2,10] In our case, which died after 3 days, this finding was observed at autopsy. Numerous textbooks report a cherry-red discoloration of the lividity, in our case, this finding was observed in autopsy.^[3,10]

Conclusion

Cyanide poisoning could appear in different forms, and like our case, the symptoms can last for several days with nonspecific symptoms.

Declaration of patient consent

The authors certify that they have obtained appropriate patient consent forms. In the form, the patient's father has given his consent for patient's clinical information to be reported in the journal. He understood that patient's name will not be published and due efforts will be made to conceal patient's identity.

Financial support and sponsorship

Nil.

Conflicts of interest

There are no conflicts of interest.

References

1. Amizet L, Pruvot G, Remy S, Kfoury M. Occupational cyanide poisoning. *BMJ Case Rep.* 2011 Nov 21;2011.
2. Nelson LS, Howland MA, Lewin NA, Smith SW, Goldfrank LR, Hoffman RS. *Goldfrank's Toxicologic Emergencies.* 11th ed. New York: McGraw-Hill Companies; 2019. P. 1684-8.
3. DiMaio VJ, DiMaio D. *Forensic Pathology.* 2nd ed. CRC Press LLC; 2001. P. 290-3.
4. Hsiao PJ, Chang CF, Chiu CC, Chan JS, Chiang WF, Wu CC, Lin SH, Chen JS. High Anion Gap Metabolic Acidosis after a Suicide Attempt with Cyanide: The Rebirth of Cyanide Poisoning. *Intern Med.* 2015;54(15):1901-4.
5. Coentrão L, Neves A, Moura D. Hydroxocobalamin treatment of acute cyanide poisoning with a jewellery-cleaning solution. *BMJ Case Rep.* 2010 Jul 15:2010
6. Akhgari M, Baghdadi F, Kadkhodaei A. Cyanide poisoning related deaths, a four-year experience and review of the literature, *Australian Journal of Forensic Sciences.* 2016 Mar; 48(2):186-194.
7. Tintinalli JE. *Tintinalli's Emergency Medicine.* 8th ed. New York: McGraw-Hill Education; 2016. p. 1223-4.
8. Bebart VS, Pitotti RL, Borys DJ, Morgan DL. Seven years of cyanide ingestions in the USA: critically ill patients are common, but antidote use is not. *Emerg Med J.* 2011;28:155-8.
9. Zakharov S, Navratil T, Pelcova D. Non-fatal suicidal self-poisonings in children and adolescents over a 5-year period (2007–2011). *Basic & clinical pharmacology & toxicology.* 2013; 112(6):425-30.
10. Saukko P, Knight B. *KNIGHT's Forensic Pathology.* 4th ed. Taylor & Francis Group, LLC; 2016. P. 623-625