

Paraneoplastic limbic encephalitis associated with mixed olfactory neuroblastoma and craniopharyngioma

A case report and literature review

Hiroshi Nagafuji, MD^a, Hidenori Yokoi, MD, PhD^{a,*}, Masachika Fujiwara, MD, PhD^b, Dai Sato^a, Koichiro Saito, MD, PhD^a

Abstract

Rationale: Paraneoplastic limbic encephalitis (PLE) is a rare disorder of the nervous system associated with malignant disease. It has a subacute onset with the following symptoms: cognitive dysfunction, seizures, irritability, hallucinations, and short-term memory loss. Herein, we report the case of a 35-year-old man with PLE, an olfactory neuroblastoma (ONB) admixed with craniopharyngioma, and serum anti-Hu antibodies.

Patient concerns: The patient presented with generalized seizures, short-term memory loss, and a polypoid mass located high in the nasal cavity.

Interventions: He underwent surgical resection of the tumor and postoperative chemoradiotherapy with concurrent intra-arterial cisplatin administration.

Diagnosis: Pathological examination indicated an ONB admixed with craniopharyngioma.

Outcomes: The patient's neurological symptoms gradually diminished after surgery. No evidence of recurrence was observed during a 4-year follow-up.

Lessons: We reported a histologically unusual heterogeneous tumor that comprised ONB and craniopharyngioma. This is the first reported case of PLE with anti-Hu antibodies possibly associated with ONB admixed with craniopharyngioma.

Abbreviations: CSF = cerebrospinal, CT = computed tomography, FLAIR = fluid-attenuated inversion recovery, MRI = magnetic resonance image, ONB = olfactory neuroblastoma, PLE = paraneoplastic limbic encephalitis, PND = paraneoplastic neurological disorder, SNTC = sinonasal teratocarcinoma.

Keywords: anti-Hu antibodies, craniopharyngioma, olfactory neuroblastoma, paraneoplastic limbic encephalitis, paraneoplastic neurological disorder

1. Introduction

Paraneoplastic limbic encephalitis (PLE) is a paraneoplastic neurological disorder (PND) associated with a malignancy, although evidence of the malignancy could be unclear at the time of PLE presentation.^[1] PLE presents as a subacute onset neurologic disorder that includes cognitive dysfunction, seizures, irritability, hallucinations, and short-term memory loss. Several specific antibodies have been isolated from plasma and

cerebrospinal fluid (CSF) in patients with PLE, of which anti-Hu is the type most commonly found. Electroencephalography usually reveals foci of epileptic activity in one or both temporal lobes, or focal or generalized slow activity. Fluid-attenuated inversion recovery (FLAIR) magnetic resonance imaging (MRI) or T2 sequences show hyperintense signals in the medial portion of one or both temporal lobes. The diagnosis is made according to the clinical features combined with findings on electroencephalography, MRI, and inflammatory changes in the CSF.

In general, PND occurs in ~0.01% of patients with cancer.^[1] Several cases of PLE associated with thymoma, Hodgkin's lymphoma, and small-cell cancers of either the lung, testis, or breast have been reported.^[2] Olfactory neuroblastoma (ONB) and craniopharyngioma have not been previously associated with PLE, although mixed ONB-craniopharyngioma associated with a syndrome of inappropriate secretion of antidiuretic hormone has been reported.^[3] To the best of our knowledge, this report is the first to document a case of PLE and serum anti-Hu antibodies associated with ONB admixed with craniopharyngioma.

2. Case presentation

Written consent was obtained from the patient and the requirement for approval from the ethics committee was waived owing to the nature of the study.

Editor: N/A.

The authors have no funding and conflicts of interest to disclose.

^a Department of Otolaryngology-Head and Neck Surgery, Kyorin University School of Medicine, Tokyo, Japan, ^b Department of Pathology, Kyorin University School of Medicine, Tokyo, Japan.

* Correspondence: Hidenori Yokoi, Department of Otorhinolaryngology-Head and Neck Surgery, Kyorin University School of Medicine, 6-20-2 Shinkawa, Mitaka, Tokyo 181-8611, Japan (e-mail: h-yokoi@ks.kyorin-u.ac.jp).

Copyright © 2018 the Author(s). Published by Wolters Kluwer Health, Inc. This is an open access article distributed under the terms of the Creative Commons Attribution-Non Commercial-No Derivatives License 4.0 (CCBY-NC-ND), where it is permissible to download and share the work provided it is properly cited. The work cannot be changed in any way or used commercially without permission from the journal.

Medicine (2018) 97:24(e10932)

Received: 7 February 2018 / Accepted: 8 May 2018

<http://dx.doi.org/10.1097/MD.00000000000010932>

A 35-year-old man who presented with generalized seizures, short-term memory loss, and mild temporal and spatial disorientation over 4 weeks was referred to our hospital. His initial mental status was assessed using the Mini-Mental State Examination and a score of 27/30 was obtained. An electroencephalogram showed paroxysmal epileptiform activity. Viral serologic tests and assays for antinuclear, anti-double-stranded DNA, anti-Sjögren's syndrome-A/B, antithyroid, antithyroid peroxidase, and anticononeural (anti-Ma2, anti-Ma1, anti-CV2, anti-Ri, anti-Yo, and amphiphysin) antibodies were negative. In addition, the cancer indicators carcinoembryonic antigen, cancer antigen 19-9, and squamous cell carcinoma antigen were absent, although the patient tested positive for anti-Hu antibodies and neuron-specific enolase (14 ng/mL; reference range: 0–10 ng/mL). Analysis of his CSF showed normal findings. A computed tomography (CT) scan revealed a $35 \times 30 \times 32$ mm mass in his left ethmoid sinus, and our department was consulted. The tumor was accompanied with calcification and invaded the left maxillary sinus, whereas his medial orbital wall, nasal septum, and cribriform plate were uninvolved (Fig. 1A). A gadolinium-enhanced, T1-weighted MRI of his sinus showed an enhanced heterogeneous and expansive mass in the left ethmoidal sinus with no evidence of invasion into the base of his skull (Fig. 1B). A CT scan showed 2 enlarged lymph nodes in his left neck and in his lateral retropharyngeal space. A magnetic

resonance (MR) angiography revealed the maxillary artery to be the feeding artery of his paranasal cancer (Fig. 1C). A T2-weighted and FLAIR MRI showed strong signals in his bilateral medial temporal lobes (Fig. 2A). CT scans of his chest, abdomen, and pelvis showed no evidence of metastasis.

The clinic biopsy specimen demonstrated that the tumor contained malignant neuroepithelial elements. ONB was suspected, although it could not be confirmed at that time. However, this patient was diagnosed with PLE associated with a paranasal tumor based on the diagnostic criteria for paraneoplastic neurological syndromes.^[4]

We surgically resected the tumor using a lateral rhinotomy procedure. The patient received postoperative chemoradiotherapy concurrent with intra-arterial cisplatin administration. The total dose was 60 Gy, divided into 2-Gy doses, and the total cisplatin dose was 234.3 mg. Twelve weeks later, we performed a planned neck dissection. A final histological examination showed 2 distinct cell populations in the tumor. Most of the lesion consisted of small-sized tumor cells within a neurofibrillary matrix (Fig. 3). Immunohistology confirmed that the cells were positive for CD56, neuron-specific enolase, vimentin, and chromogranin A (Table 1). A second population of the tumor cells consisted of well-differentiated epithelium disposed in lobules and irregular trabeculae bordered by palisading columnar epithelium. Immunohistochemically, the tumor was positive for cytokeratin AE1/AE3, cytokeratin-19, and CK903/cytokeratin

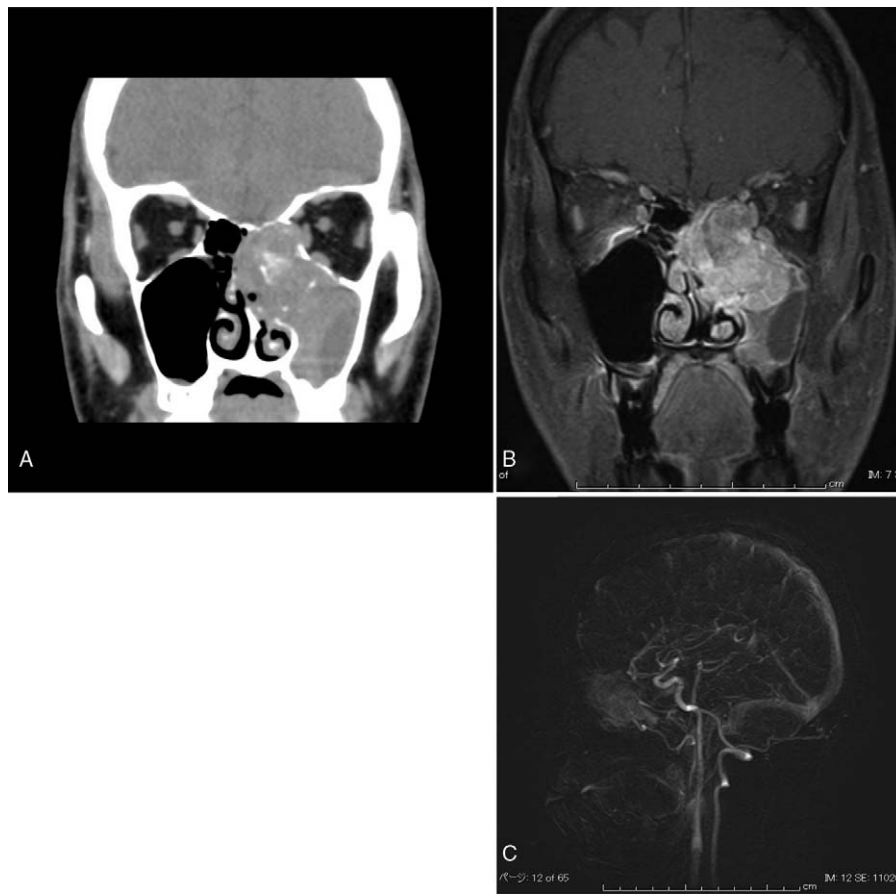


Figure 1. Image of the patient's tumor. (A) A coronal CT image revealed an expansive nasal mass in the patient's left ethmoid sinus that had calcification extending into his maxillary sinus. The cribriform plate, orbit, and nasal septum were not involved. (B) A coronal MRI of the patient's brain and nasal and paranasal cavities showed an enhanced image of the tumor in the left ethmoid sinus. (C) MR angiography of the patient's sinus showing the maxillary artery (arrow) feeding the paranasal cancer (arrowhead).

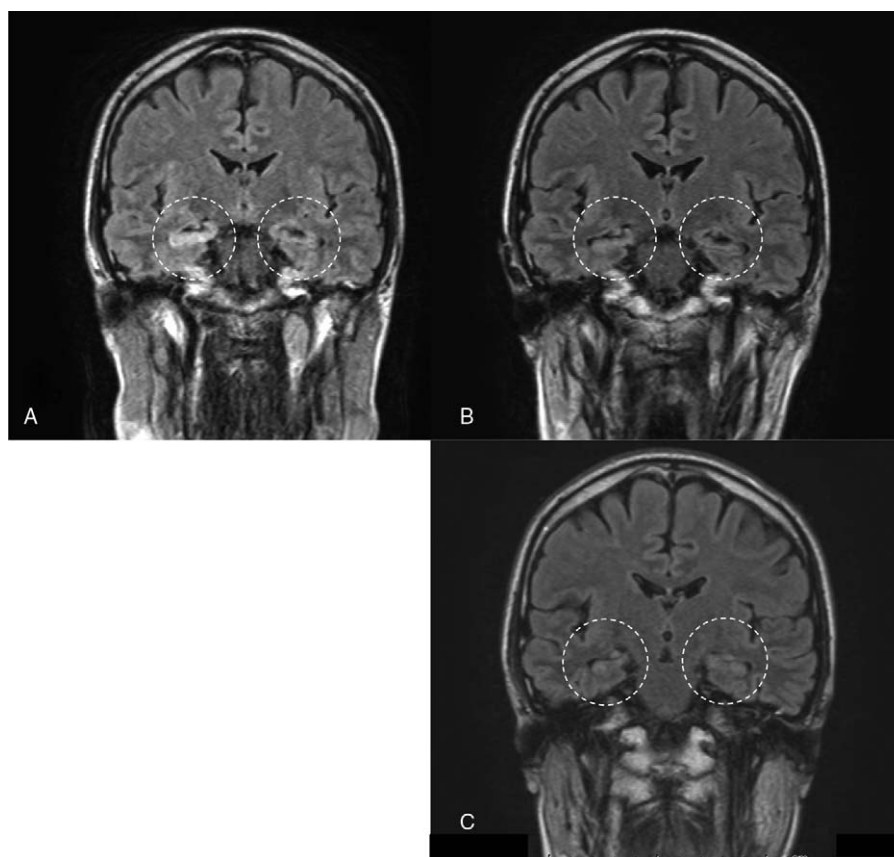


Figure 2. FLAIR MRI images of the patient's brain before and after treatment. (A) The image shows intense signals in the patient's bilateral medial temporal lobes and his hippocampus (dotted circular line). (B, C) FLAIR MRI images showing that the intensities in the patient's bilateral hippocampal lobes became less detectable after treatment for the ONB (dotted circular line).

34 beta E12. In addition, the tumor did not contain mesenchymal components. The histological and immunohistochemical patterns supported a diagnosis of ONB admixed with craniopharyngioma. Our final definitive diagnosis was PLE associated with anti-Hu antibodies and an ONB admixed with craniopharyngioma.

Two months after surgical resection, a FLAIR MRI of the patient's brain showed lower intensities in the bilateral medial temporal lobes than the preoperative images (Fig. 2B), and his Mini-Mental State Examination score improved to 29/30. Six months after surgical resection, MRI did not detect any abnormal findings in his bilateral temporal lobes (Fig. 2C). At this time, the patient's serum was negative for anti-Hu antibodies.

The patient survived without any seizure attack for 4 years after surgery. However, he suffered mild short-term memory loss and required ^{18}F -fluorodeoxyglucose positron emission tomography/CT to assess tumor recurrence. Fortunately, no recurrence was detected, and his electroencephalogram remained negative for epileptiform activity.

3. Discussion

This report highlights the case of a unique development of PLE, and the tumor comprised 2 elements: ONB and craniopharyngioma. Although rare cases of ONB have shown divergent differentiation with focal populations of cells showing distinct characteristics, including melanocytic, myogenic, neural, or epithelial cells, ONB admixed with other non-neuroepithelial neoplasms are extremely rare.^[5] Only 4 cases of ONB admixed

with an otherwise typical tumor have been reported.^[3,6,7] One was an adenocarcinoma mixed with ONB,^[6] 1 was a squamous cell carcinoma mixed with ONB,^[6] and 2 were a craniopharyngioma mixed with ONB.^[3,7] Although mixed tumors have been also described in other organs,^[8] their pathogenesis remains unclear. Moreover, whether they are collision tumors derived from independent stem cells or whether they originate from a single stem cell undergoing divergent differentiation remains unclear.

One of 2 cases of mixed ONB and craniopharyngioma was reported as sinonasal teratocarcinoma (SNTC). SNTC is extremely rare, and only approximately 60 cases have been reported. SNTC is a histologically heterogeneous neoplasm of the paranasal sinuses and is composed of variably benign or malignant neuroepithelial, epithelial, and mesenchymal elements. This tumor is unlikely to be of germ cell origin, but probably arises from a primitive cell in the olfactory membrane that not only reproduces the neuroectodermal features of olfactory neuroblastoma, but can also differentiate into divergent types of somatic cells. Phenotypically, multiple tissue types with varying degrees of maturity are derived from 2 or 3 germ layers. Defining whether the tumor is SNTC with limited differentiation or olfactory neuroblastoma admixed with craniopharyngioma is difficult. Further research is needed to fully understand the pathophysiology of SNTC with limited differentiation and an olfactory neuroblastoma and immunophenotypically divergent epithelial cell population, including craniopharyngioma, in the same tumor.

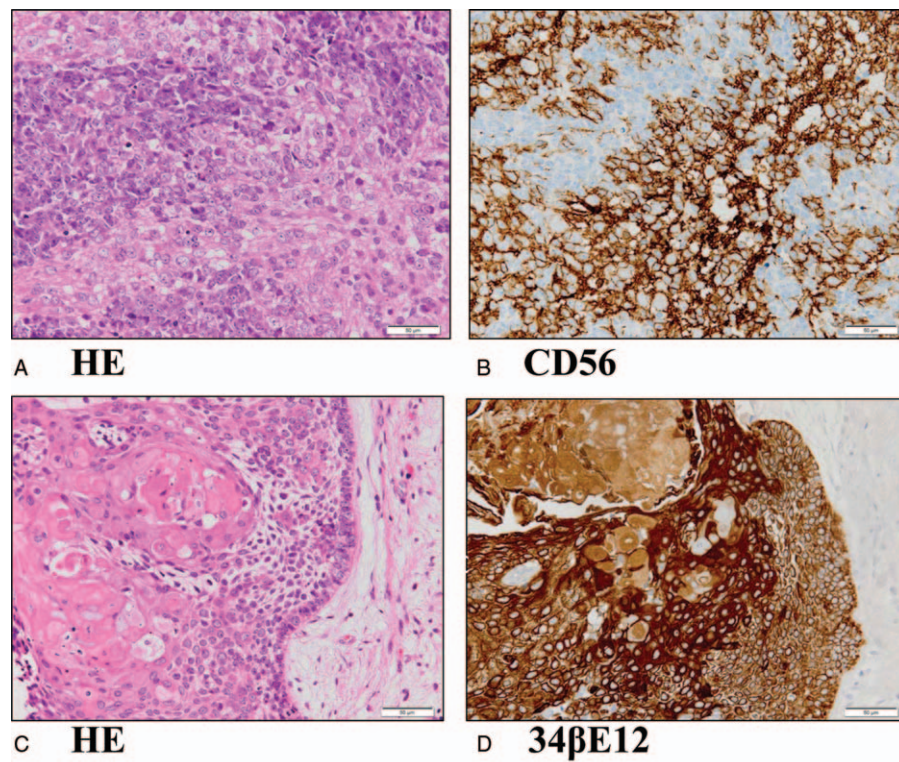


Figure 3. Histopathological features of the patient's tumor. (A) In most of the lesion, the neoplastic cells had uniformly small and round nuclei with little cytoplasm, and had dispersed nuclear chromatin that varied between being coarse and fine in structure (hematoxylin–eosin staining, scale bar = 50 μ m). (B) Immunostaining for CD56 (scale bar = 50 μ m). (C) In the second lesion, nests of tumor cells of various sizes consisting of squamous epithelial cells with intercellular bridges and obvious keratinization are seen (hematoxylin–eosin staining, scale bar = 50 μ m). (D) Immunostaining for 34 β E12 (scale bar = 50 μ m).

The diagnosis of PLE is based on the clinical features combined with findings on electroencephalography and MRI, and the indicated inflammatory changes in the CSF.

Most cases of PLE are thought to be immune mediated. Although a PND-related immune attack may be triggered by the presence of a cancer, the targeted antigens will be common both to the cancer and the nervous system, as evidenced by 60% of patients with PLE having antibodies in their serum or CSF against antigens related to the nervous system and the underlying cancer.^[2] Currently, PLE is classified into 2 groups according to the location(s) of the targeted antigens: intracellular or classic paraneoplastic antigens, including the intracellular Hu antigen, and cell membrane antigens. We confirmed that our patient was positive for the Hu antigen.

Table 1

Immunohistochemical staining of the tumor cells.

	ONB lesion	Second lesion	Tumor stroma
Cytokeratin AE1/AE3	(+)	(+)	(–)
CK903 (cytokeratin 34 beta E12)	(–)	(+)	(–)
S100	(–)	(–)	A few cells (+)
Neuron-specific enolase	(+)	Weakly (+)	(–)
Neurofilament	(–)	(–)	(–)
CD56	(+)	(–)	(–)
Chromogranin A	Weakly (+)	(–)	(–)
Synaptophysin	Weakly and focally (+)	(–)	(–)
Vimentin	(+)	(–)	(+)
Glial fibrillary acidic protein	(–)	(–)	(–)

3.1. Treatment

Two types of treatments are used to ameliorate the symptoms of classic PLE. The first involves removal of the tumor, and the second involves suppression of the immune response via plasma exchange, intravenous immunoglobulin therapy, and/or administration of immunosuppressive agents (e.g., corticosteroids, cyclophosphamide, or tacrolimus).^[9] PLEs associated with antibodies against intracellular antigens are resistant to immunotherapy, whereas PLEs accompanied by antibodies against cell membrane antigens respond to immunotherapy.^[10,11] We did not pursue an immunotherapy regimen because the Hu antigen is intracellular. Instead, we successfully treated our patient via surgical resection of his tumor and post-operative chemoradiotherapy as we believed his PLE was associated with his cancer.

4. Conclusion

We reported a histologically unusual heterogeneous tumor composed of 2 cell populations, namely, ONB and craniopharyngioma. This report is the first documented case of PLE with serum anti-Hu antibodies associated with ONB admixed with craniopharyngioma.

Author contributions

Conceptualization: Hiroshi Nagafuji, Hidenori Yokoi.

Data curation: Hiroshi Nagafuji, Hidenori Yokoi, Dai Sato.

Formal analysis: Hiroshi Nagafuji, Hidenori Yokoi.

Funding acquisition: Hidenori Yokoi.

Investigation: Hiroshi Nagafuji, Hidenori Yokoi, Masachika Fujiwara.

Methodology: Hidenori Yokoi.

Supervision: Koichiro Saito.

Visualization: Masachika Fujiwara.

Writing – original draft: Hiroshi Nagafuji.

Writing – review & editing: Hidenori Yokoi.

References

- [1] Darnell RB, Posner JB. Paraneoplastic syndromes involving the nervous system. *N Engl J Med* 2003;349:1543–54.
- [2] Gultekin SH, Rosenfeld MR, Voltz R, et al. Paraneoplastic limbic encephalitis: neurological symptoms, immunological findings and tumour association in 50 patients. *Brain* 2000;123:1481–94.
- [3] Kleinschmidt-DeMasters BK, Pflaumer SM, Mulgrew TD, et al. Sinonasal teratocarcinosarcoma (“mixed olfactory neuroblastoma-craniopharyngioma”) presenting with syndrome of inappropriate secretion of antidiuretic hormone. *Clin Neuropathol* 2000;19:63–9.
- [4] Graus F, Delattre JY, Antoine JC, et al. Recommended diagnostic criteria for paraneoplastic neurological syndromes. *J Neurol Neurosurg Psychiatry* 2004;75:1135–40.
- [5] Faragalla H, Weinreb I. Olfactory neuroblastoma: a review and update. *Adv Anat Pathol* 2009;16:322–31.
- [6] Miller DC, Goodman ML, Pilch BZ, et al. Mixed olfactory neuroblastoma and carcinoma. A report of two cases. *Cancer* 1984; 54:2019–28.
- [7] Chang KC, Jin YT, Chen RM, et al. Mixed olfactory neuroblastoma and craniopharyngioma: an unusual pathological finding. *Histopathology* 1997;30:378–82.
- [8] Finzi G, Cerati M, Marando A, et al. Mixed pituitary adenoma/craniopharyngioma: clinical, morphological, immunohistochemical and ultrastructural study of a case, review of the literature, and pathogenetic and nosological considerations. *Pituitary* 2014;17: 53–9.
- [9] Viaccoz A, Honnorat J. Paraneoplastic neurological syndromes: general treatment overview. *Curr Treat Options Neurol* 2013;15: 150–68.
- [10] Croteau D, Owainati A, Dalmau J, et al. Response to cancer therapy in a patient with a paraneoplastic choreiform disorder. *Neurology* 2001; 57:719–22.
- [11] Keime-Guibert F, Graus F, Fleury A, et al. Treatment of paraneoplastic neurological syndromes with antineuronal antibodies (Anti-Hu, anti-Yo) with a combination of immunoglobulins, cyclophosphamide, and methylprednisolone. *J Neurol Neurosurg Psychiatry* 2000;68: 479–82.