



Contents lists available at ScienceDirect

International Journal of Surgery Case Reports

journal homepage: www.casereports.com

Pubic osteomyelitis after surgery for perforated colonic diverticulitis with fecal peritonitis: A case report



Daichi Kitaguchi*, Tsuyoshi Enomoto, Yusuke Ohara, Tatsuya Oda, Nobuhiro Ohkohchi

Department of Gastrointestinal and Hepato-Biliary-Pancreatic Surgery, Faculty of Medicine, University of Tsukuba, Tsukuba, Ibaraki, 305-8575, Japan

ARTICLE INFO

Article history:

Received 25 April 2017

Received in revised form 15 June 2017

Accepted 8 July 2017

Available online 13 July 2017

Keywords:

Pubic osteomyelitis

Wound infection

Postoperative complication

ABSTRACT

INTRODUCTION: Pubic osteomyelitis is a rare type of suppurative osteomyelitis. Early diagnosis of pubic osteomyelitis is difficult, and prolonged inflammation results in progressive bone degradation, severe pelvic pain and a wide-based gait.

PRESENTATION OF CASE: We report the case of an 82-year-old woman who was admitted to a previous hospital with severe abdominal pain caused by a perforated colonic diverticulum with fecal peritonitis. She underwent an emergency operation and a postoperative wound infection occurred. Despite treatment of the infection, purulent exudate was discharged for three months and she gradually showed a gait disturbance.

CT and MRI revealed that pubic symphysis showed osteolysis and there was severe inflammation around the wound. After administration of appropriate antibiotics, an operation, which included the removal of a fistula, debridement of sequestra and lavage of the abscess cavity, was performed. The inflammation improved promptly after the operation, and the patient was discharged on postoperative day 27 without any complications.

DISCUSSION: Pubic osteomyelitis does not show the findings of typical acute suppurative osteomyelitis and hematological findings are nonspecific. It is important for early diagnosis to consider the risk factors of pubic osteomyelitis during examination.

CONCLUSION: We would emphasize that a definitive diagnosis by CT and MRI and appropriate antimicrobial therapy combined with surgical treatment are important for pubic osteomyelitis.

© 2017 The Authors. Published by Elsevier Ltd on behalf of IJS Publishing Group Ltd. This is an open access article under the CC BY-NC-ND license (<http://creativecommons.org/licenses/by-nc-nd/4.0/>).

1. Introduction

Osteomyelitis of the pubis is an uncommon entity. It accounts for less than 1% of all cases of hematogenous osteomyelitis [1]. An early diagnosis of pubic osteomyelitis is difficult to obtain because the symptoms are nonspecific and do not present the typical septic arthritis of a joint. Delayed diagnosis and treatment leads to progressive bone degradation and induces severe complications, resulting in severe pelvic pain and a wide-based gait [2]. We report a case of pubic osteomyelitis induced by wound infection after surgery for perforated diverticulitis with fecal peritonitis, followed by a brief literature review.

This work has been reported in line with the SCARE criteria [3]

Abbreviations: Hb, hemoglobin; Alb, albumin; WBC, white blood cell; CRP, C-reactive protein; ESR, erythrocyte sedimentation rate; MSSA, methicillin sensitive *Staphylococcus aureus*; CT, computed tomography; MRI, magnetic resonance imaging.

* Corresponding author at: 2-1-1, Amakubo, Tsukuba, Ibaraki 305-8576, Japan.

E-mail addresses: s0611600@gmail.com (D. Kitaguchi), eno@md.tsukuba.ac.jp (T. Enomoto), y.ohara@md.tsukuba.ac.jp (Y. Ohara), tatoda@md.tsukuba.ac.jp (T. Oda), nokochi3@md.tsukuba.ac.jp (N. Ohkohchi).

<http://dx.doi.org/10.1016/j.ijscr.2017.07.015>

2210-2612/© 2017 The Authors. Published by Elsevier Ltd on behalf of IJS Publishing Group Ltd. This is an open access article under the CC BY-NC-ND license (<http://creativecommons.org/licenses/by-nc-nd/4.0/>).

2. Presentation of case

An 82-year-old woman, with hypertension but her medical history was otherwise healthy, was admitted to the previous hospital with severe abdominal pain. She underwent an emergency laparotomy. Intraoperative findings showed that a diverticulum of rectosigmoid was perforated and feces was leaked into the peritoneal cavity. After the perforation was sutured closed, peritoneal lavage and ileostomy was performed.

Wound infection occurred one week after the operation. The wound was opened and the pus was discharged. A subcutaneous lavage of the wound was continued. Purulent exudate had been discharged from the lower end of the wound and a fistula was formed from the pubic bone to the lower end of the wound. She had mild tenderness at the pubic bone, and gradually showed a gait disturbance due to the pelvic instability.

Three months after the initial operation, she was introduced to our department to treat purulent exudate discharging from the fistula. Laboratory values revealed mild anemia (Hb 10.5 g/dl) and malnutrition (Alb 3.1 g/dl). WBC and CRP were within normal range. Bacteriological findings from the pus showed Enterobacter aerogenes and MSSA.

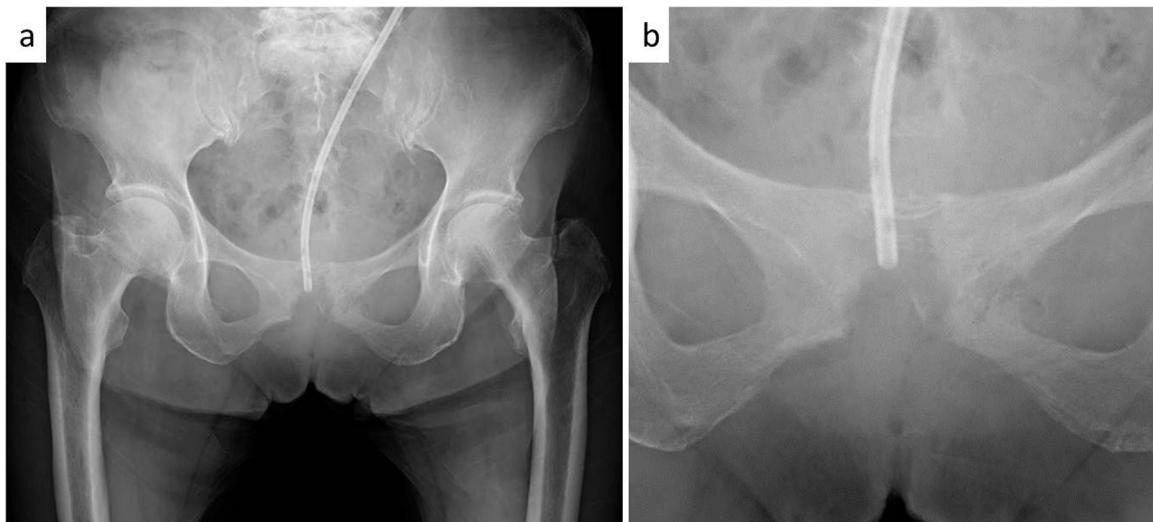


Fig. 1. a. Plain radiograph of the pelvis demonstrated severe atrophy and irregularity of the cortex of the pubic symphysis. b. Close-up image of pubic symphysis.

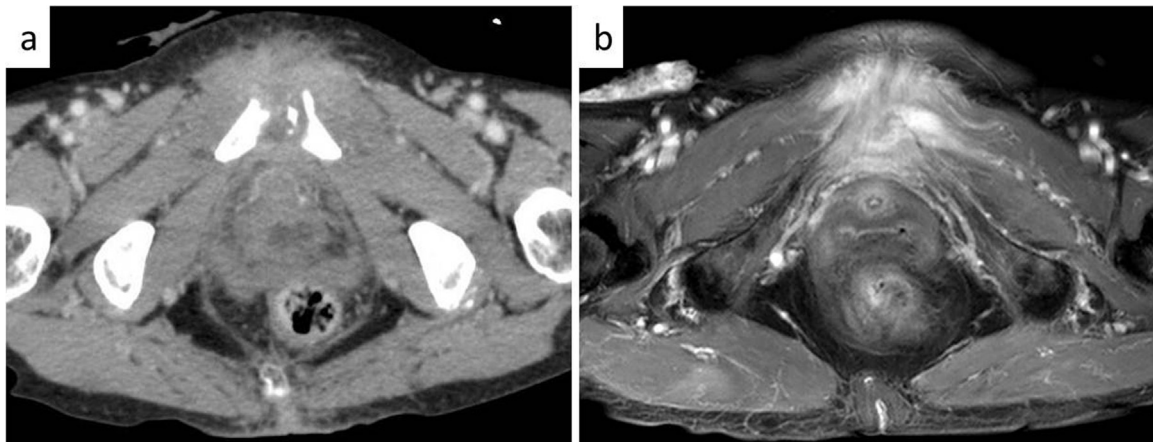


Fig. 2. a. CT revealed that osteolysis and strong irregularity of pubic symphysis. b. MRI revealed that fistula and abscess extended to the back side of the pubic symphysis and fluid collection around the wound.

Plain radiograph of the pelvis demonstrated severe atrophy and irregularity of the cortex of the pubic symphysis (Fig. 1). CT and MRI revealed that osteolysis, strong irregularity of pubic symphysis, fistula and abscess extended to the back side of the pubic symphysis and fluid collection around the wound (Fig. 2).

The definitive diagnosis of pubic osteomyelitis caused by the postoperative wound infection was made. At first, the patient received oral antibiotics based on the bacteriological findings and a drainage tube was inserted into the fistula to attempt healing by negative pressure. The amount of pus discharged from the fistula was approximately 20 ml in a day; however, the wound did not heal for two weeks. Therefore, an operation with debridement of the pubis with curettage was performed.

In the operation, the fistula was completely removed and the pubic symphysis was exposed. Debridement of sequestra, curettage of pubic symphysis and lavage of the abscess cavity were carried out. During the operation, the fistula was firmly adhered to the bladder wall; therefore, a partial bladder resection was required. A cement spacer containing an antibacterial agent was placed in the pubic symphysis aiming to maintain the stability of the pelvis.

Following the operation, intravenous cefazolin was given for 5 days followed by oral clindamycin for 28 days. The wound improved promptly and she was discharged on postoperative day 27 without any postoperative complications. Three months after

the initial operation, the cement spacer containing antimicrobial agents was removed with an additional operation. Finally, her gait disturbance was resolved and she could walk without any assistance after the surgery.

3. Discussion

The etiology of the pubic osteomyelitis is hypothesized to be a bone infection resulting from hematogenous spread, direct or contiguous inoculation. Common causes of pubic osteomyelitis are trauma, postoperative complications of gynecology-urology surgery, inguinal-femoral hernia surgery and the influence of adjacent infection foci [2,4–6]. Osteomyelitis of the pubic bone is rarely described. In hematogenous myelitis, the incidence of pubic osteomyelitis accounts for less than 1% [1].

Clinical symptoms of pubic osteomyelitis are fever or pain at the pubic bone. Severe symptoms include gait disturbance or restriction of the movable range of the hip joint, which are induced by the prolonged condition. In study of 100 patients with pubic osteomyelitis, only 74% had fever, 59% had a painful gait and 45% had pain with hip motion [7,8]. However, pubic osteomyelitis does not show the findings of typical acute suppurative osteomyelitis. The reasons are, perhaps, the deep location of the pelvic bone and limitation of its motion [9].

Hematological findings were also nonspecific. The values of leukocyte, ESR and CRP, as inflammatory markers, were elevated in only 35% of patients, but are not specific for this disease [7].

Therefore, it is difficult to make an early diagnosis with clinical symptoms and hematological findings. It is important for early diagnosis to consider the risk factors of pubic osteomyelitis during examination [8].

Plain X-ray has been used for the diagnosis of osteomyelitis; however, it is not suitable for early diagnosis because the appearance of bone destruction and periosteal reaction occurs 7–14 days after onset [10]. A definitive diagnosis of pubic osteomyelitis is typically made based on an imaging examination. CT and MRI are useful for the definitive diagnosis for pubic osteomyelitis. The sensitivity and specificity of MRI for pubic osteomyelitis is 97% and 94%, respectively [11,12]. MRI is suitable for the evaluation of soft tissues, and it can clearly distinguish between normal and infected bone marrow. Therefore, MRI can capture the specific traits of pubic osteomyelitis, such as edematous change and the effect on bone marrow. MRI is also superior in evaluating the extent of inflammation or to detect abscess formation [12–14]. If pubic osteomyelitis is clinically suspected, CT and MRI should be considered

The treatment of pubic osteomyelitis is based on the administration of antimicrobial agents and surgical therapy. Because of the rich blood flow in the pelvis, pubic osteomyelitis often shows spectacular improvement in inflammation with only intravenous antimicrobial therapy. Busto et al. reported that they reviewed seven patients with osteomyelitis of the pubis. Patients received antibiotic treatment for a minimum of three weeks and a maximum of 12 weeks. The response to antibiotic therapy was good in all patients and none required surgical debridement [1].

Surgical therapy, which includes a large debridement of infected and necrotic tissues, is also recommended. After surgical treatment, intravenous antimicrobial therapy is recommended for a minimum of six weeks and, after that, at least three weeks of orally antimicrobials, especially for pubic osteomyelitis by pyogenic bacteria in the adult patient. [9,15].

In our case, a delayed diagnosis and prolonged wound infection resulted in pubic osteomyelitis by direct inoculation of inflammation. The reason for delayed diagnosis is that the patient did not have typical clinical symptoms of pubic osteomyelitis and there are only a few case reports of pubic osteomyelitis caused by wound infection after abdominal surgery. However, CT and MRI study strongly contributed to a definitive diagnosis. Once the diagnosis was made, appropriate antimicrobial therapy and surgical treatment were rapidly implemented, which resulted in improving the patient without any complications of pubic osteomyelitis.

4. Conclusion

We report a case of pubic osteomyelitis induced by wound infection after surgery for perforated colonic diverticulitis with fecal peritonitis. Delayed diagnosis and prolonged wound infection resulted in pubic osteomyelitis by direct inoculation of the infection. Therefore, we would emphasize that early diagnosis by CT and MRI, appropriate antimicrobial therapy combined with surgical treatment are critical.

Conflicts of interest

None.

Open Access

This article is published Open Access at sciedirect.com. It is distributed under the [IJSCR Supplemental terms and conditions](#), which permits unrestricted non commercial use, distribution, and reproduction in any medium, provided the original authors and source are credited.

Source of funding

None.

Ethical approval

This report is not research study.

Consent

Written informed consent was obtained from the patient for publication of this case report and accompanying images. A copy of the written consent is available for review by the Editor-in-Chief of this journal on request.

Author contribution

DK is the corresponding author and carried out revision of the manuscript. TE supervised the writing of the manuscript. All authors read and approved the final manuscript.

Guarantor

Daichi Kitaguchi.

References

- [1] R. del Busto, E.L. Quinn, E.J. Fisher, T. Madhavan, Osteomyelitis of the pubis. Report of seven cases, *JAMA* 248 (1982) 1498–1500.
- [2] T. Koakutsu, M. Kawamura, K. Takada, E. Itoi, Osteomyelitis of the pubic symphysis as a complication of bladder neck suspension procedure with use of bone anchors: a case report, *Rheumatol. Curr. Res.* (2013), <http://dx.doi.org/10.4172/2161-1149.s16-002>, S16:002.
- [3] R.A. Agha, A.J. Fowler, A. Saetta, I. Barai, S. Rajmohan, D.P. Orgill, The SCARE Group, The SCARE statement: consensus-based surgical case report guidelines, *Int. J. Surg.* 34 (2016) 180–186.
- [4] G. Lavien, G. Chery, U.B. Zaid, A.C. Peterson, Pubic bone resection provides objective pain control in the prostate cancer survivor with pubic bone osteomyelitis with an associated urinary tract to pubic symphysis fistula, *Urology* 100 (2017) 234–239.
- [5] R. Tekin, R. Ceylan Tekin, F. Ceylan Cevik, R. Cevik, Acute osteomyelitis of the symphysis pubis after inguinal hernia surgery, *Case Rep. Rheumatol.* 2015 (2015) 845–867, <http://dx.doi.org/10.1155/2015/845867>, Epub 2015 Apr 20.
- [6] B. Plateau, M. Ruivard, P.F. Montoriol, Prostatosymphysal fistula and osteomyelitis pubis following transurethral resection of the prostate: CT and MRI findings, *J. Med. Imaging Radiat. Oncol.* 59 (6) (2015) 713–715, <http://dx.doi.org/10.1111/1754-9485.12304>, Epub 2015 Apr 23.
- [7] J.J. Ross, Hu LT: Septic arthritis of the pubic symphysis, *Medicine (Baltimore)* 82 (2003) 340–345.
- [8] J. Yax, D. Cheng, Osteomyelitis pubis: a rare and elusive diagnosis, *West J. Emerg. Med.* 15 (2014) 880–882.
- [9] R.E. Rosenthal, W.A. Spickard, R.D. Markham, R.K. Rhamy, Osteomyelitis of the symphysis pubis: a separate disease from osteitis pubis. Report of three cases and review of the literature, *J. Bone Joint Surg. Am.* 64 (1982) 123–128.
- [10] K. Kozłowski, O. Hochberger, B. Povysil, Swollen ischiopubic synchondrosis: a dilemma for the radiologist, *Australas. Radiol.* 39 (1995) 224–227.
- [11] P.J. Carek, L.M. Dickerson, J.L. Sack, Diagnosis and management of osteomyelitis, *Am. Fam. Phys.* 63 (2001) 2413–2420.
- [12] B. Sammak, M. Abd El Bagi, M. Al Shahed, D. Hamilton, J. Al Nabulsi, B. Youssef, M. Al Thagafi, Osteomyelitis: a review of currently used imaging techniques, *Eur. Radiol.* 9 (1999) 894–900.
- [13] H. Umans, N. Haramati, G. Flusser, The diagnostic role of gadolinium enhanced MRI in distinguishing between acute medullary bone infarct and osteomyelitis, *Magn. Reson. Imaging* 18 (2000) 255–262.
- [14] A.M. Herneth, S. Trattng, T.R. Bader, A. Ba-Ssalamah, W. Pnhold, K. Wandl-Vergesslich, L.S. Steinbach, *Magn. Reson. Imaging* 18 (2000) 519–524.
- [15] D. Wilmes, P. Omoumi, J. Squifflet, O. Cornu, H. Rodriguez-Villalobos, J.C. Yombi, Osteomyelitis pubis caused by *Kingella kingae* in an adult patient: report of the first case, *BMC Infect. Dis.* 12 (2012), <http://dx.doi.org/10.1186/1471-2334-12-236>, 236.