


Original Research

# Electromyographic Evaluation of Early-Stage Shoulder Rehabilitation Exercises Following Rotator Cuff Repair

Peter K Edwards, PhD<sup>1</sup> , Patrick Wai Hang Kwong, PhD<sup>2</sup>, Timothy Ackland, PhD<sup>3</sup>, Allan Wang, FRACS, PhD<sup>4</sup>, Cyril J Donnelly, PhD<sup>5</sup>, Jay R Ebert, PhD<sup>3</sup>

<sup>1</sup> School of Human Sciences, University of Western Australia; School of Physiotherapy and Exercise Science, Curtin University, <sup>2</sup> Rehabilitation Research Institute of Singapore, Nanyang Technological University, <sup>3</sup> School of Human Sciences, University of Western Australia, <sup>4</sup> Department of Orthopaedic Surgery, The University of Western Australia; Murdoch Centre of Orthopaedic Research, <sup>5</sup> School of Human Sciences, University of Western Australia; Rehabilitation Research Institute of Singapore, Nanyang Technological University

Keywords: rotator cuff, rehabilitation, range of motion, electromyography

<https://doi.org/10.26603/001c.29513>

---

## International Journal of Sports Physical Therapy

Vol. 16, Issue 6, 2021

---

### Background

Electromyography (EMG) is frequently used as a guide for exercise rehabilitation progression following rotator cuff repair. Knowledge of EMG activity during passive and active-assisted exercises may help guide clinicians when considering exercise prescription in the early post-operative period.

### Purpose

The purpose of this study was to investigate EMG activity of the rotator cuff and deltoid musculature during passive and active-assisted shoulder range of motion (ROM) exercises commonly performed in post-operative rehabilitation.

### Study Design

Descriptive cohort laboratory study using healthy subjects.

### Methods

In sixteen active healthy volunteers, surface and fine-wire EMG activity was measured in the supraspinatus, infraspinatus, subscapularis, and anterior, middle and posterior deltoid muscles during eight common ROM exercises. Mean %MVIC values and 95% confidence intervals were used to rank exercises from the least to the most amount of muscular activity generated during the exercises.

### Results

Standard pendulum exercises generated low levels of EMG activity in the supraspinatus and infraspinatus ( $\leq 15\%$  MVIC), while active-assisted table slides, and the upright wall slide generated low levels of EMG activity in only the supraspinatus. No exercises were found to generate low levels of muscular activation ( $\leq 15\%$  MVIC) in the subscapularis.

### Conclusion

This study found no clear distinctions between the EMG activity of the supraspinatus or the infraspinatus occurring during common passive and active-assisted ROM exercises. Subdividing ROM exercises based on muscle activity, may not be necessary to guide progression of exercises prior to commencing active motion after rotator cuff repair.

### Level of Evidence

Level 3b

## INTRODUCTION

Despite positive clinical results, failure after rotator cuff repair is common, with the large majority of these occurring within the first six months following surgery.<sup>1</sup> A successful outcome after surgery is dependent on a myriad of factors,

including the quality of repair tissue, pre-operative tear size, the repair technique and individual patient factors such as smoking, body mass and physical activity.<sup>2,3</sup> Post-operative rehabilitation is also one of the more important factors in determining a successful outcome, with exercises aimed at restoring glenohumeral motion often utilized within the first post-operative month.<sup>4</sup> Current expert con-

sensus states that rehabilitation after rotator cuff repair should include a two-week period of strict immobilization followed by a staged introduction of range of motion (ROM) activities, initially with protected, passive ROM (PROM) exercises to six weeks, followed by restoration of active ROM (AROM).<sup>5</sup> However, the time in which certain exercises may be implemented, and progressed from PROM to AROM has been debated. This is especially important during the early post-operative stages, where loading should not exceed the biomechanical limits of the healing tissues, while still facilitating the alignment of newly formed collagen fibers.<sup>6</sup>

Deciding on which exercises to prescribe in these first six weeks following repair is largely based on clinical opinion and patient feedback, with limited evidence regarding whether a particular exercise may be adversely loading the repair tissues. Muscular activity measured by electromyography (EMG) remains the best available direct estimate of stress placed on the rotator cuff tendon, to guide clinicians through appropriate exercise selection following cuff repair.<sup>5,7</sup> In the earlier post-operative stages, a better understanding of how commonly employed PROM and active-assisted ROM (AAROM) exercises specifically load the rotator cuff would be of benefit to the therapist prescribing these activities to patients. The purpose of this study was to investigate EMG activity of the rotator cuff and deltoid musculature during PROM and AAROM exercises commonly performed in post-operative rehabilitation.

## METHODS

### PARTICIPANTS

A total of 16 physically active healthy volunteers (11 males, 5 females) with normal shoulder examination, no previous shoulder injury, and no pain with activities of daily living were recruited for this study. Participants were recruited using flyers on community notice boards and on social media platforms. Inclusion criteria for the study included participants 18 to 40 years of age, no previous shoulder injury or surgery to the dominant arm, no current shoulder pain, and the ability to demonstrate full active shoulder ROM. The study received approval from the University of Western Australia Human Research Ethics Committee (HREC), and all participants provided written informed consent prior to their study participation. This study conforms to all STROBE guidelines and reports the required information accordingly.

### INSTRUMENTATION AND ELECTRODE INSERTION

Participants attended a single two-hour EMG testing session, whereby electromyographic data were collected simultaneously from six muscular locations around the dominant shoulder, using a combination of surface and indwelling fine-wire electrodes. A 16-channel telemetry EMG system (Myon 320, Myon AG, Zurich, Switzerland) sampling at 4000 Hz was used to record muscle excitations. The anterior deltoid, middle deltoid, and posterior deltoid were assessed with disposable, self-adhesive pre-gelled surface EMG electrodes (3M, Minnesota, USA), and placed on participants as described by Basmajian and De Luca.<sup>8</sup> Electrode placements were confirmed by visualization of the EMG signal during

active muscle activation, and all transition cells were secured with adhesive tape. Prior to electrode placement, the area was scrubbed with an abrasive sponge, then cleaned with isopropyl alcohol to reduce skin impedance. Intramuscular fine-wire electrodes were used to record muscle excitations of the supraspinatus, infraspinatus, and subscapularis. Using aseptic technique, the skin was prepared using a chlorohexidine solution. Intramuscular fine wire electrodes were inserted via a sterile 30 mm, 27-gauge hypodermic needle with a pair of 0.051 mm, insulated, bent end Teflon coated stainless steel wires and 200 mm tail with 5 mm bare-wire terminations (Chalgren Enterprises, USA) in accordance with the protocols described by previous studies.<sup>8-10</sup> All electrode insertions were performed by a trained medical professional experienced in the practice. All fine wire insertions were guided by real time ultrasound (Telemed Echo Blaster 128 EXT-1Z, TELEMED Medical Systems, Italy). The ultrasound unit was also used to confirm electrode placement, in concert with visual inspection of live EMG time traces during isometric contractions.

### EXPERIMENTAL PROTOCOL

Prior to the commencement of data collection, participants were instructed to complete a brief warm-up by moving their arms through full active flexion and abduction ROM to ensure that the intramuscular electrodes had settled into position within the muscle, and the signal from each muscle was adequately detected. All participants underwent a familiarization session approximately one to two days before testing. During these sessions, each participant was given verbal and visual instruction of each exercise from a qualified Exercise Physiologist, upon which they subsequently practiced the exercise techniques and maximal voluntary isometric contraction (MVIC) protocols that will be discussed later.

### EXERCISES

Eight ROM exercises, including four PROM and four AAROM, that are commonly prescribed during early rehabilitation following rotator cuff repair were included for evaluation in this study (Table 1, Figure 1). Active arm flexion and abduction were also evaluated against gravity to serve as a comparison with the PROM and AAROM exercises (Table 1, Figure 1). One set of six repetitions for each exercise was performed. A metronome was used to control arm speed, following a cadence of 15 beats per minute. Previous EMG studies have evaluated exercises at a speed of 60 beats per minute,<sup>11,12</sup> while Gaunt et al<sup>13</sup> in their study of active-assisted shoulder exercises, evaluated exercises at a speed of 30 degrees per second (approximately five beats per minute). Participants were given a 30 second rest between each trial to reduce fatigue effects. The order of these exercises was performed in a randomized fashion between participants to prevent order effects.

### MAXIMAL VOLUNTARY ISOMETRIC CONTRACTION (MVIC)

Prior to the exercise testing session, participants were in-

**Table 1. Descriptions of the four passive (PROM), four active-assisted (AAROM) and two active (AROM) exercises included in this study.**

Exercise	Exercise Type	Description
Pendulum (Figure 1A)	PROM	Participant is standing and bent forward 90° at the waist, using the non-dominant hand to support themselves on a table for support. Participant has their dominant arm “hanging” down towards the ground at 90° of arm flexion and 0° of elbow flexion, circumducting the arm generated from the motion at the waist.
Rock the Baby – Circumduction (Figure 1B)	PROM	Participant is standing and bent forward 90° at the waist, supporting the dominant arm at the elbow with their opposite, non-dominant hand, at the elbow. Using the non-dominant arm, the dominant arm is guided and supported through circumduction through available range of motion.
Rock the Baby – Elevation (Figure 1C)	PROM	Participant is standing and bent forward 90° at the waist, supporting the dominant arm at the elbow with their opposite, non-dominant hand, at the elbow. Using the non-dominant arm, the dominant arm is guided and supported through arm flexion through available ROM.
Table Slide (Figure 1D)	PROM	Participant is in a seated position at a table, with their dominant hand of the dominant arm on a cloth placed on the table, set at elbow height, with the elbow at the midline of body. The participant slides their hand directly forward (toward full elbow extension) and backward in the sagittal plane, bending slightly forward with their body to achieve additional flexion ROM
Pulley-assisted Elevation (Figure 1E)	AAROM	Participant is standing facing a wall with a rope and pulley attached to a door overhead. Holding on to either side of the pulley with both arms, the participant elevates their dominant arm by pulling down on the pulley with their non-dominant arm.
Assisted Wall Slide (Figure 1F)	AAROM	Participant is standing upright facing a wall, with the “dominant” hand resting at shoulder level on the wall in approximately 90° arm flexion, with the non-dominant arm supporting the dominant side at the elbow. The participant is then instructed to slide hand up and down the wall, using the non-dominant hand to assist this motion, going through full ROM.
Dowel-assisted Forward Elevation (Figure 1G)	AAROM	Participant is standing upright using the non-dominant arm to raise and lower the dominant or arm into elevation, while grasping a broomstick for assistance, going through full arm flexion ROM.
Dowel-assisted External Rotation (Figure 1H)	AAROM	Participant is standing upright, with the dominant arm grasping one end of a broomstick, with the elbow placed at the side of the thorax. Having the non-dominant arm grasping the other end of the broomstick, the dominant arm is assisted into external rotation, going through full external rotation ROM.
Active Flexion	AROM	Participant is standing upright, and raises their dominant arm into full flexion ROM.
Active Abduction	AROM	Participant is standing upright, and raises their dominant arm into full abduction ROM.

structed to perform a series of three MVICs, across a total of four muscle tests (Table 2). The four MVIC positions tested in this study have been previously reported (Table 2).<sup>9,14</sup> Each contraction lasted for approximately five seconds, with a gradual increase of contraction strength over one second, sustained maximum contraction for three seconds and a gradual release over the final second. To reduce the effects of fatigue, each MVIC trial was performed three times for five seconds, with a three-minute rest between each trial. The highest value from the middle one-second interval of each MVIC trial was recorded for each portion of each muscle.

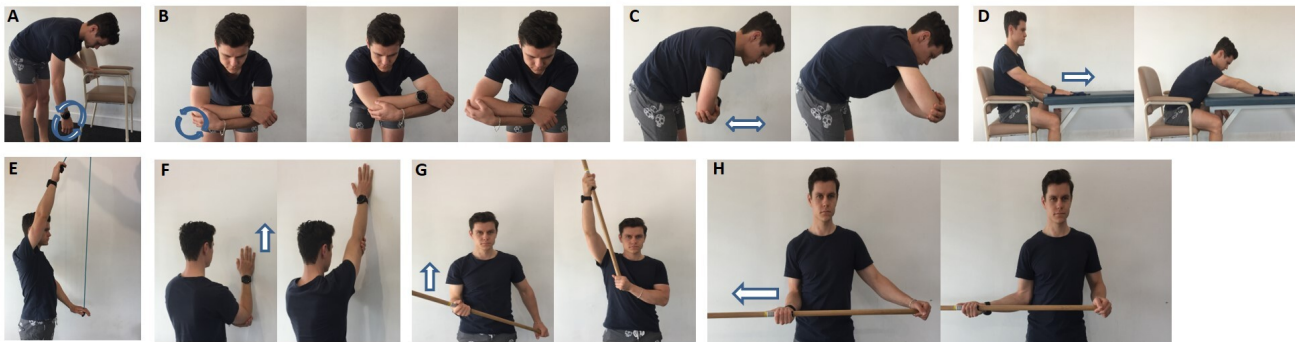
#### DATA PROCESSING AND ANALYSIS

For surface and fine wire EMG data processing, a customized software platform in MATLAB (2009a, The Math Works, Inc., Natick, Massachusetts, USA) was employed, following SENIAM standards.<sup>15</sup> For both the fine wire and

surface EMG data, direct current offsets were removed. For the surface EMG data, a fourth-order, zero-lag bandpass digital Butterworth filter between 20 and 500 Hz was used. For the fine wire EMG data, a fourth-order, zero-lag bandpass digital Butterworth filter between 20 and 750 Hz was used. Both the surface and fine wire EMG data were then full-wave rectified and then linear enveloped by low-pass filtering with a zero-lag fourth-order Butterworth at 6 Hz. All data were then normalized to each muscle MVIC and expressed as a percentage MVIC (%MVIC). For the analysis of the surface and fine wire EMG outputs, R language (R Core Team, version 3.6, Vienna, Austria) and RStudio (version 1.2.1335, RStudio Team RStudio, Inc., Boston, MA) were used. For each condition (i.e., exercise), the first and sixth repetition were discarded from analyses, leaving four repetitions for each condition. The peak muscle activation (%MVIC) from each of the four trial was obtained, then averaged for each individual participant, which is consistent with previous methods to obtain a %MVIC.<sup>13</sup> An ensemble

**Table 2. Maximal Voluntary Isometric Contraction (MVIC) test procedures.**

MVIC test	Muscle	Test description
Empty can test <sup>9</sup>	Supraspinatus	Shoulder abducted to 90° in the scapula plane with internal humeral rotation and the elbow extended. The arm is maximally and isometrically abducted as resistance is applied at the elbow.
Internal rotation <sup>9</sup>	Subscapularis	Shoulder abducted to 90° in the scapula plane with neutral humeral internal rotation and the elbow flexed to 90°. The arm is maximally and isometrically internally rotated as resistance is applied at the wrist.
External rotation <sup>13</sup>	Infraspinatus	Shoulder abducted to 0°, neutral humeral internal rotation and the elbow flexed to 90°. The arm is maximally and isometrically externally rotated as resistance is applied at the wrist.
Abduction	Anterior, middle and posterior deltoid	The shoulder is abducted to 90° with the participant upright. Resistance is applied just above the elbow.



**Figure 1. The eight exercises completed during the study, including: (A) Pendulum, (B) Rock the Baby (Circumduction), (C) Rock the Baby (Elevation), (D) Table Slide, (E) Pulley-assisted Elevation, (F) Assisted Wall Slide, (G) Dowel-assisted Forward Elevation, (H) Dowel-assisted External Rotation.**

average across all participant's mean peak muscle activations were then calculated for each muscle and condition.

#### DATA ANALYSIS

Descriptive statistics are reported and displayed for each individual muscle as mean  $\pm$  95% confidence intervals. Maximum EMG expressed in %MVIC values for each muscle were averaged for the participant's three trials. Muscle activity was categorized as low, 0% to 15% MVIC; low to moderate, 16% to 20% MVIC; moderate, 21% to 40% MVIC; high, 41% to 60% MVIC; and very high, greater than 60% MVIC.<sup>7</sup> Descriptive statistics and radar plots for each condition were presented.

#### RESULTS

The mean ( $\pm$  SD) age, height, and weight for the entire group was 28.5  $\pm$  4.6 years, 1.75  $\pm$  0.10 m, and 75.9  $\pm$  13.8 kg, respectively. Table 3 shows mean %MVIC values and 95% confidence intervals for the supraspinatus, infraspinatus, subscapularis, and deltoid muscles according to exercises performed, ranked from least to the most amount of activity generated. Specifically, for the supraspinatus, the standard pendulum, and gravity-minimized exercises, such

as the table slide and assisted wall slide, were the only exercises to generate low-levels of activation (i.e., below 15% MVIC). Interestingly, the rock-the-baby exercises recruited the shoulder muscles to a greater extent than that of the standard pendulum exercise; especially the elevation version of the exercise which consistently generated moderate levels of activity.

Figures 2 and 3 present radar plots visualizing comparisons between evaluated muscles in terms of muscle activation expressed as %MVIC during the four PROM (Figure 2) and four AAROM (Figure 3) exercises.

#### DISCUSSION

The main finding of the current study was that clear differences were observed between active and assistive (PROM and AAROM) exercises for the anterior deltoid and supraspinatus, but not for the infraspinatus or subscapularis. However, a clear distinction between PROM and AAROM exercises could not be identified. Furthermore, the majority of PROM and AAROM exercises (apart from the pendulum exercise, table slide exercise and the supported vertical wall slide) all exceeded the 15% MVIC threshold, which has been suggested as an upper limit of a safe loading range during exercises in the early stages following rotator

**Table 3. Percent MVIC for passive (PROM) and active-assisted (AAROM) exercises from least to greatest, for each muscle tested.**

Supraspinatus	Infraspinatus	Subscapularis	Anterior Deltoid	Middle Deltoid	Posterior Deltoid
Pendulum, 14 (11 to 18)	Pendulum, 12 (8 to 16)	Dowel-assisted ER, 18 (9 to 27)	Dowel-assisted ER, 3 (2 to 3)	Dowel-assisted ER, 13 (5 to 21)	Dowel-assisted ER, 3 (2 to 3)
Table slide, 15 (12 to 17)	Rock the baby circumduction, 15 (11 to 19)	Pendulum, 19 (12 to 26)	Table slide, 12 (10 to 14)	Table slide, 14 (9 to 20)	Table slide, 5 (4 to 7)
Assisted wall slide, 15 (11 to 20)	Table slide, 16 (13 to 20)	Pulley elevation, 23 (18 to 28)	Rock the baby circumduction, 15 (13 to 17)	Pendulum, 16 (12 to 20)	Pendulum, 10 (8 to 13)
Rock the baby circumduction, 17 (14 to 21)	Dowel-assisted elevation, 20 (15 to 24)	Active flexion, 24 (18 to 31)	Pendulum, 17 (14 to 20)	Rock the baby circumduction, 16 (12 to 20)	Rock the baby circumduction, 12 (10 to 14)
Dowel-assisted ER, 18 (13 to 23)	Rock the baby elevation, 20 (15 to 24)	Dowel-assisted elevation, 25 (18 to 33)	Pulley elevation, 27 (23 to 31)	Assisted wall slide, 28 (24 to 31)	Assisted wall slide, 16 (12 to 21)
Dowel-assisted elevation, 20 (15 to 24)	Dowel-assisted ER, 25 (20 to 30)	Rock the baby circumduction, 25 (20 to 30)	Assisted wall slide, 29 (27 to 31)	Pulley elevation, 29 (24 to 35)	Pulley elevation, 17 (13 to 21)
Pulley elevation, 20 (16 to 25)	Pulley elevation, 25 (19 to 31)	Rock the baby elevation, 26 (17 to 35)	Rock the baby elevation, 30 (26 to 33)	Dowel-assisted elevation, 33 (27 to 29)	Dowel-assisted elevation, 17 (13 to 20)
Rock the baby elevation, 22 (18 to 27)	Assisted wall slide, 25 (20 to 30)	Table slide, 26 (17 to 34)	Dowel-assisted elevation, 33 (30 to 36)	Rock the baby elevation, 34 (29 to 40)	Rock the baby elevation, 26 (21 to 32)
Active flexion, 43 (40 to 47)	Active abduction, 25 (19 to 30)	Assisted wall slide, 28 (20 to 35)	Active flexion, 43 (40 to 47)	Active flexion, 42 (37 to 48)	Active flexion, 26 (21 to 30)
Active abduction, 48 (44 to 52)	Active flexion, 28 (23 to 34)	Active abduction, 33 (24 to 42)	Active abduction, 48 (44 to 52)	Active abduction, 47 (44 to 52)	Active abduction, 35 (29 to 40)

Results are presented as means (95% confidence intervals).

cuff repair.<sup>16</sup> As such, many of the exercises evaluated in this study, and their use in the earlier stages of a rehabilitation continuum to regain active motion should be questioned, and moreover, subdividing exercises into categories of PROM and AAROM may not be necessary following rotator cuff repair. Instead, progression of exercises prior to commencing active motion should be based on factors such as patient comfort, pain tolerance, and available ROM.<sup>13</sup>

In the current study, active flexion and abduction for the supraspinatus, anterior deltoid, and middle deltoid elicited high mean %MVICs, compared to all assistive (PROM and AAROM exercises) which generated low, low-to-moderate and moderate mean %MVICs. For the infraspinatus, active flexion and abduction was only seen to generate a moderate mean %MVICs, clearly not differentiating between assistive exercises which were also found to generate low, low-to-

moderate and moderate %MVICs. This finding is similar to that by Gaunt et al,<sup>13</sup> who also observed clear distinctions between assistive exercises (PROM and AAROM) and active exercises for the supraspinatus and anterior deltoid, but not infraspinatus. In the current study, the subscapularis was also found to only generate moderate mean %MVICs, which did not materially differ from more assistive exercises. However, no clear differences were observed between exercises categorized as passive (PROM) or active-assisted (AAROM), which suggests further subdividing assistive exercises into PROM and AAROM exercises based on muscle activity is not necessary to protect the supraspinatus following a rotator cuff repair, nor for scenarios in which deltoid protection is necessary, such as for an open rotator cuff repair.<sup>13</sup>



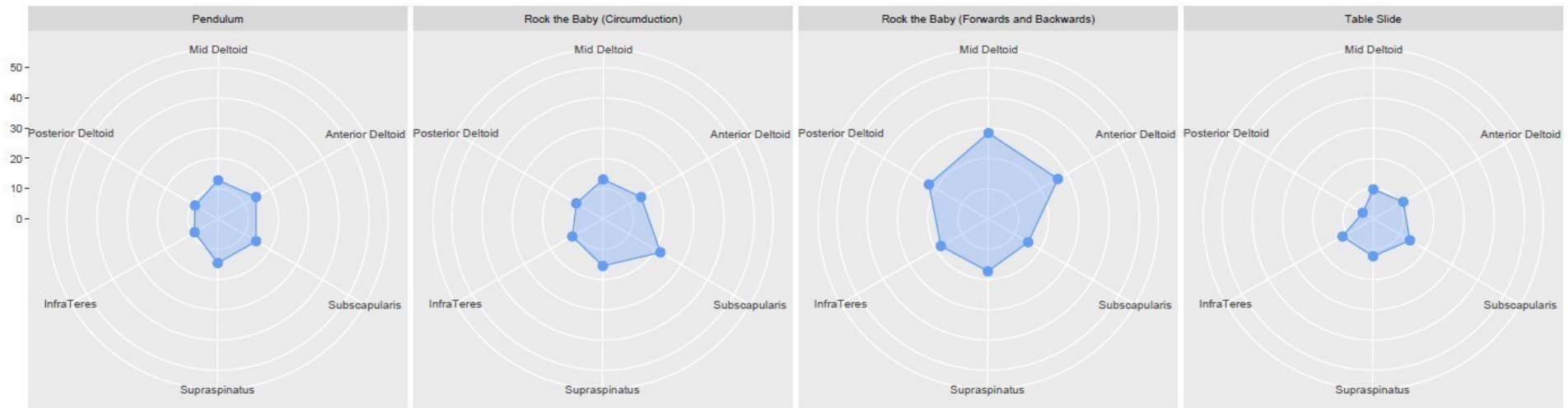


Figure 2. Radar plots showing muscular activity during the four passive range of motion (PROM) rehabilitation exercises.

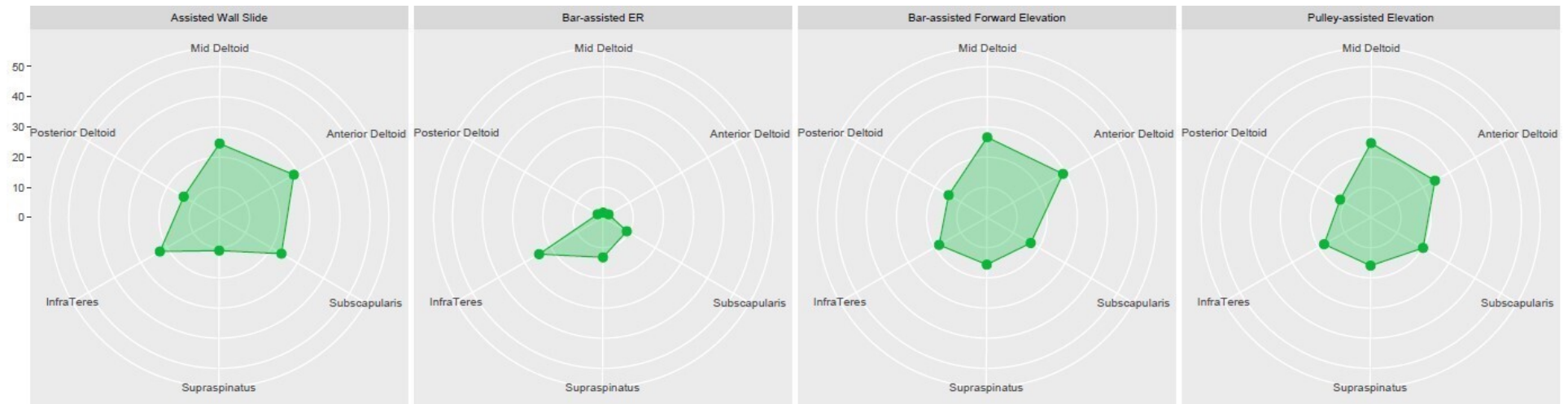

Figure 3. Radar plots showing muscular activity during the four active-assisted range of motion (AAROM) rehabilitation exercises.

In the current study, the pendulum exercise was one of two exercises considered “passive” which did not generate >15% MVIC in the supraspinatus. The pendulum is a popular exercise amongst therapists, and commonly employed early in rehabilitation to restore shoulder mobility following rotator cuff repair.<sup>16</sup> Indeed, the pendulum has been the subject of many EMG analyses which have frequently found it to generate low levels of EMG activity.<sup>17–19</sup> The mean %MVIC of the supraspinatus during pendulum exercises in the current study was 14%, greater than that reported by Gurney et al (12%),<sup>18</sup> McCann et al (9%),<sup>19</sup> and Ellsworth et al (10%),<sup>20</sup> though more similar to the large, correctly performed pendulums in the study by Long et al (13.7%).<sup>16</sup> In their study, Long et al<sup>16</sup> found that large, incorrectly performed pendulums generate moderate levels of supraspinatus muscle activity (18.8%). In what is meant to be a PROM exercise on the shoulder generated by trunk motion, patients often perform this as an AROM exercise by using their shoulder muscles to swing the arm rather than simply allowing it to hang in a relaxed state.<sup>16</sup> Given that pendulum exercises are often prescribed as a home exercise, it is possible that patients may incorrectly perform these without proper instruction and supervision, which may potentially overload a newly repaired rotator cuff.

The rock-the-baby exercise is an alternate version of the standard pendulum exercise performed by having the patient control the operated arm with the non-surgical arm, with the goal of protecting the repair from increased stress that the standard pendulum can cause if performed incorrectly. With the non-surgical arm guiding and supporting the surgical arm, the weight of the arm is reduced and, theoretically, reduces the demand on the shoulder musculature. Previous research has supported this rationale of unloading the surgical arm during AROM and AAROM exercises.<sup>21</sup> In the current study, it was interesting to note that the rock-the-baby exercise (when performing circumduction) elicited a low-to-moderate mean %MVIC (17%), and a moderate mean %MVIC (22%) when performing elevation on the supraspinatus. This was higher than the mean %MVIC during pendulum exercise reported in this study, as well as others.<sup>13,16–18</sup> No previous studies have directly compared this assisted version of the pendulum with the standard pendulum exercise, making comparison to existing literature difficult. However, it is possible that the rock-the-baby produced more muscle activity than standard pendulum exercises were that, despite being unloaded by the contralateral arm, these exercises may have been supported through a larger ROM, generating more muscle activity. This is consistent with the findings by Long et al<sup>16</sup> who found that pendulums, when performed in a larger diameter, generated significantly higher mean %MVICs. Future research could look to expand on this research by controlling for small and large diameter versions of this exercise.

The table slide was another exercise below the 15% MVIC threshold which could be considered appropriate to be prescribed in early-stage rehabilitation. The primary concentric phase of the table slide, that is the forward motion of the exercise, moves perpendicular to gravity with the weight of the arm supported and removing a large gravitational burden on the shoulder, subsequently reducing the demand on the shoulder musculature.<sup>21</sup> The mean %MVIC

of the supraspinatus during this exercise produced similar MVICs to that reported by Gaunt et al (12%),<sup>13</sup> yet much higher than those reported in the study by Jung et al (4%).<sup>22</sup> It is possible these differences are due to how the exercise was performed. In the study by Jung et al,<sup>22</sup> participants were instructed to generate forward movement by flexing the trunk, with the hand passively sliding until reaching an end range. Conversely, in this present study, forward movement was generated preferentially by the shoulder, similar to that by Gaunt et al,<sup>13</sup> which may explain the reason for the larger mean %MVICs in the supraspinatus, and also for the infraspinatus and subscapularis. The mean %MVIC of the anterior deltoid and middle deltoid produced similar MVICs to those observed in the study by Cools et al<sup>23</sup> (11% and 11.9%, respectively).

The supported vertical wall slide was the only AAROM exercise which did not generate over 15% MVIC. The mean %MVIC of the supraspinatus during this exercise produced similar MVICs to those reported by Wise et al (13%)<sup>21</sup> and Gaunt et al (21%).<sup>13</sup> This observed low muscle activation is potentially due to unloading and compressive effects of the supporting surface, and possibly due to additional support of the shoulder from the contralateral arm, throughout AROM.<sup>21</sup> However, this exercise has conflicting clinical evidence regarding its use in early rehabilitation. It has been suggested this exercise, also known as the wall slide or wall walk, is more appropriately used in later stages of rehabilitation once the patient can actively elevate the arm to at least 130° without pain, to build endurance for active elevation rather than as an assist for improving elevation ROM.<sup>5</sup> Mean %MVICs observed for the anterior and middle deltoid were similar to those observed in the study by Cools et al<sup>23</sup> (11% and 11.9%, respectively).

Dowels and pulleys are often used by patients to actively assist forward flexion motion so as not to place excessive stress on an early cuff repair. AAROM exercises using a dowel or pulley to elevate the arm were shown to generate over 15% MVIC for muscles of the rotator cuff which is consistent with previous studies, suggesting that their use early in rehabilitation might not be appropriate.<sup>13,17,18</sup> The mean %MVIC of the supraspinatus when using a pulley to elevate the arm in the current study (20%) was similar to that reported by Gurney et al (18.5%),<sup>18</sup> Gaunt et al (17%),<sup>13</sup> and Dockery et al (17.6%),<sup>17</sup> all classified as low-to-moderate.

No exercises employed in the current study were found to generate low levels of muscular activation in the subscapularis. This is an important consideration for clinicians working with patients undergoing rotator cuff repair involving the subscapularis, or even in shoulder arthroplasty surgery whereby the release and subsequent repair of the subscapularis tendon is involved. In these cases, clinicians should abide by soft-tissue precautions; so as not to jeopardize the newly repaired tissue. The mean %MVICs in the current study were inconsistent when compared with those reported by Gurney et al.<sup>18</sup> In their study, pulley elevation, pendulums and dowel-assisted elevation generated 7.3%, 9.4% and 9.6% median MVIC, respectively; all falling considerably below the low activity threshold.<sup>18</sup> Aside from the differences in statistical reporting, the differences observed between the study by Gurney et al.<sup>18</sup> and the present study are possibly due to variances in testing procedures. In the



current study, peak amplitudes across four repetitions were averaged over three trials to provide a mean %MVIC value, which differs from the study by Gurney et al,<sup>18</sup> who reported mean EMG activity values for one repetition (or 10 seconds in the case of pendulums) of a task.

#### LIMITATIONS

Firstly, this study evaluated participants with healthy functioning shoulders in order to obtain an accurate maximal voluntary contraction for comparison. As a result, the activity of the shoulder muscles in healthy participants may not be representative of the activity of individuals with a pathological or post-surgical shoulder. Previous authors have suggested that patients with painful, symptomatic shoulders activate muscles differently and are unable to remain as passive as healthy control subjects.<sup>20,24</sup> Therefore, caution should be applied in extrapolating data collected from healthy subjects and applying results to clinical populations. We did have concerns about undertaking such a study in an early post-operative cuff cohort, given the risk of introducing infection and seeking more insight into the specific loading capabilities of each exercise initially.

Secondly, the mean age of the participants in our cohort is younger than the typical patient undergoing rotator cuff surgery. However, the current study sought to initially recruit a cohort with a lower risk of asymptomatic shoulder pathology. Furthermore, many of the participants in the current study were either physiotherapists or exercise physiologists and, therefore, were familiar with most of the rehabilitation tasks which also served to ensure the exercises were performed correctly.

Finally, repair site tension can only be estimated, as EMG is not a direct measurement of the potential damaging force incurred at the site of repair. As a result, EMG studies cannot provide definitive guidelines on “safe” versus “unsafe” exercises applicable to all patients without assumptions regarding the force-EMG relationships, as well as the force levels that will cause damage (or failure) to a repair. Muscle activity level, along with the plane of motion, cyclic loading and the weight and length of an individual’s upper limb, are also likely to affect the tension on the repaired tissue.<sup>5,7</sup> While only moderate correlations have been made between muscle tension and EMG activity,<sup>25</sup> in the clinical setting, where stress and tension imparted by rehabilitation exercises cannot be measured, EMG evidence does offer a prag-

matic method to base the progression of therapeutic exercises on likely stress on the repaired rotator cuff.<sup>5,7</sup>

#### CONCLUSION

The results of the current study indicate that commonly performed PROM and AAROM exercises, with the exception of the pendulum exercise, table slide exercise and the assisted wall slide, all exceeded the 15% MVIC threshold of the supraspinatus. Fifteen percent or below (defined as low activity) has been suggested as an upper limit of a safe loading range during exercises in the early stages following rotator cuff repair.<sup>16</sup> A clear distinction between PROM and AAROM exercises could only be identified for the anterior deltoid, and not for the supraspinatus, which suggests that subdividing PROM and AAROM forward flexion exercises based on muscle activity is not necessary to protect the supraspinatus following rotator cuff repair. The current study, which was undertaken in normal, asymptomatic shoulders, would suggest that the early progression of exercises prior to commencing active motion after rotator cuff repair may be better based on factors such as patient comfort, pain tolerance and available ROM.

#### ETHICS APPROVAL

Ethics approval was obtained by the University of Western Australia Human Research Ethics Office (RA/4/1/7559).

#### CONFLICT OF INTEREST STATEMENT

No other authors have any conflicts of interest.

#### ACKNOWLEDGEMENTS

The authors thank Daniel Cottam and Jonathan Staynor from the School of Human Sciences Biomechanics Laboratory at University of Western Australia for their help with data collection.

Submitted: November 08, 2020 CST, Accepted: June 15, 2021 CST



## REFERENCES

1. Miller BS, Downie BK, Kohen RB, et al. When do rotator cuff repairs fail? Serial ultrasound examination after arthroscopic repair of large and massive rotator cuff tears. *Am J Sports Med.* 2011;39(10):2064-2070. doi:10.1177/0363546511413372
2. Fermont AJ, Wolterbeek N, Wessel RN, Baeyens JP, de Bie RA. Prognostic factors for recovery after arthroscopic rotator cuff repair: a prognostic study. *J Shoulder Elbow Surg.* 2015;24(8):1249-1256. doi:10.1016/j.jse.2015.04.013
3. Fermont AJ, Wolterbeek N, Wessel RN, Baeyens JP, de Bie RA. Prognostic factors for successful recovery after arthroscopic rotator cuff repair: a systematic literature review. *J Orthop Sports Phys Ther.* 2014;44(3):153-163. doi:10.2519/jospt.2014.4832
4. Huang TS, Wang SF, Lin JJ. Comparison of aggressive and traditional postoperative rehabilitation protocol after rotator cuff repair: A meta-analysis. *J Nov Physiother.* 2013;3(4):1000170. doi:10.4172/2165-7025.1000170
5. Thigpen CA, Shaffer MA, Gaunt BW, Leggin BG, Williams GR, Wilcox RB III. The American Society of Shoulder and Elbow Therapists' consensus statement on rehabilitation following arthroscopic rotator cuff repair. *J Shoulder Elbow Surg.* 2016;25(4):521-535. doi:10.1016/j.jse.2015.12.018
6. Uhl TL, Muir TA, Lawson L. Electromyographical assessment of passive, active assistive, and active shoulder rehabilitation exercises. *PM and R.* 2010;2(2):132-141.
7. Edwards PK, Ebert JR, Littlewood C, Ackland T, Wang A. A systematic review of electromyography studies in normal shoulders to inform postoperative rehabilitation following rotator cuff repair. *J Orthop Sports Phys Ther.* 2017;47(12):931-944. doi:10.2519/jospt.2017.7271
8. Basmajian JV, de Luca CJ. *Muscles Alive: Their Functions Revealed by Electromyography.* Baltimore: Williams & Wilkins; 1985.
9. Boettcher CE, Ginn KA, Cathers I. Standard maximum isometric voluntary contraction tests for normalizing shoulder muscle EMG. *J Orthop Res.* 2008;26(12):1591-1597. doi:10.1002/jor.20675
10. Kadaba MP, Cole A, Wootten ME, et al. Intramuscular wire electromyography of the subscapularis. *J Orthop Res.* 1992;10(3):394-397. doi:10.1002/jor.1100100312
11. Alizadehkhayat O, Hawkes DH, Kemp GJ, Frostick SP. Electromyographic analysis of the shoulder girdle musculature during external rotation exercises. *Orthop J Sports Med.* 2015;3(11):2325967115613988. doi:10.1177/2325967115613988
12. Dark A, Ginn KA, Halaki M. Shoulder muscle recruitment patterns during commonly used rotator cuff exercises: an electromyographic study. *Phys Ther.* 2007;87(8):1039-1046. doi:10.2522/ptj.20060068
13. Gaunt BW, McCluskey GM, Uhl TL. An electromyographic evaluation of subdividing active-assistive shoulder elevation exercises. *Sports Health.* 2010;2(5):424-432. doi:10.1177/1941738110366840
14. Reinold MM, Wilk KE, Fleisig GS, et al. Electromyographic analysis of the rotator cuff and deltoid musculature during common shoulder external rotation exercises. *J Orthop Sports Phys Ther.* 2004;34(7):385-394. doi:10.2519/jospt.2004.34.7.385
15. Stegeman D, Hermens H. Standards for surface electromyography: The European project Surface EMG for non-invasive assessment of muscles (SENIAM). 2007;1.
16. Long JL, Ruberte Thiele RA, Skendzel JG, et al. Activation of the shoulder musculature during pendulum exercises and light activities. *J Orthop Sports Phys Ther.* 2010;40(4):230-237. doi:10.2519/jospt.2010.3095
17. Dockery ML, Wright TW, LaStayo PC. Electromyography of the shoulder: an analysis of passive modes of exercise. *Orthopedics.* 1998;21(11):1181-1184.
18. Gurney AB, Mermier C, LaPlante M, et al. Shoulder electromyography measurements during activities of daily living and routine rehabilitation exercises. *J Orthop Sports Phys Ther.* 2016;46(5):375-383. doi:10.2519/jospt.2016.6090
19. McCann PD, Wootten ME, Kadaba MP, Bigliani LU. A kinematic and electromyographic study of shoulder rehabilitation exercises. *Clin Orthop Relat Res.* 1993;(288):179-188.
20. Ellsworth AA, Mullaney M, Tyler TF, McHugh M, Nicholas S. Electromyography of selected shoulder musculature during un-weighted and weighted pendulum exercises. *N Am J Sports Phys Ther.* 2006;1(2):73-79.

21. Wise MB, Uhl TL, Mattacola CG, Nitz AJ, Kibler WB. The effect of limb support on muscle activation during shoulder exercises. *J Shoulder Elbow Surg.* 2004;13(6):614-620. [doi:10.1016/j.jse.2004.04.006](https://doi.org/10.1016/j.jse.2004.04.006)

22. Jung MC, Kim SJ, Rhee JJ, Lee DH. Electromyographic activities of the subscapularis, supraspinatus and infraspinatus muscles during passive shoulder and active elbow exercises. *Knee Surg Sports Traumatol Arthrosc.* 2016;24(7):2238-2243. [doi:10.1007/s00167-015-3586-8](https://doi.org/10.1007/s00167-015-3586-8)

23. Cools AM, Tongel AV, Berckmans K, et al. Electromyographic analysis of selected shoulder muscles during a series of exercises commonly used in patients with symptomatic degenerative rotator cuff tears. *J Shoulder Elbow Surg.* 2020;29(10):e361-e373. [doi:10.1016/j.jse.2020.03.019](https://doi.org/10.1016/j.jse.2020.03.019)

24. Murphy CA, McDermott WJ, Petersen RK, Johnson SE, Baxter SA. Electromyographic analysis of the rotator cuff in postoperative shoulder patients during passive rehabilitation exercises. *J Shoulder Elbow Surg.* 2013;22(1):102-107. [doi:10.1016/j.jse.2012.01.021](https://doi.org/10.1016/j.jse.2012.01.021)

25. Escamilla RF, Yamashiro K, Paulos L, Andrews JR. Shoulder muscle activity and function in common shoulder rehabilitation exercises. *Sports Med.* 2009;39(8):663-685. [doi:10.2165/00007256-200939080-00004](https://doi.org/10.2165/00007256-200939080-00004)