



## Sustained volume decreases in simple renal cysts after sclerotherapy using NBCA with or without hydrodissection



Mario I. Cárdenas-Vargas<sup>a,\*</sup>, Mario I. Ortiz<sup>b</sup>, Jeannett Izquierdo-Vega<sup>b</sup>, Mariana Díaz-Zamudio<sup>c</sup>

<sup>a</sup> Radiology Department, Hospital General de Pachuca, Pachuca, Hidalgo, Mexico

<sup>b</sup> Academic Area of Medicine, Universidad Autónoma del Estado de Hidalgo, Pachuca, Hidalgo, CP 42160, Mexico

<sup>c</sup> Radiology Department, Unidad de Patología Clínica, Guadalajara, Jalisco, Mexico

### ARTICLE INFO

#### Keywords:

Renal cyst  
N-butyl-2-cyanoacrylate  
Sclerotherapy  
Hydrodissection

### ABSTRACT

The present study aimed to determine the effectiveness of sclerotherapy using NBCA (Histoacryl Blue®; B. Braun, Melgungen, Germany), with or without hydrodissection, for the treatment of simple renal cysts. **Materials and Methods:** Patients who presented to an interventional radiology clinic for the diagnosis of symptomatic renal cysts which had previously been identified at an outpatient clinic were selected for inclusion in this study. A total of 28 patients were randomly divided into 2 groups, based on whether or not they underwent hydrodissection along with ultrasound-guided NBCA-based sclerotherapy. Sonographs were performed at 0, 7, and 180 days post-procedure to record the residual volume of the renal cysts and to determine the efficacy of the procedure. **Results:** A total of 32 cysts in 28 patients were treated with sclerotherapy, 18 (64%) females and 10 (36%) males. The average age of the patients was 61.8 years (range: 33–89 years). All patients reported an improvement in symptoms associated with the existing renal cysts at 7 and 180 days post-procedure, and at 7 days post-procedure a statistically significant reduction in cyst volume was observed (all patients: 96.8%; group A: 96%; group B: 97.6%). The reduced cyst volume was still observed 180 days post-procedure (all patients: 98.6%; group A: 98.2%; group B: 98.9%). There was no significant difference between the two treatment groups. **Conclusion:** There is a significant and persistent reduction in the volume of renal cysts, in addition to an improvement of the associated symptoms, after treatment with NBCA-based sclerotherapy, with or without hydrodissection.

### Introduction

Simple kidney cysts have a high rate of occurrence in adults, and are classified as either an inherited or acquired kidney cystic disease. Conventionally, asymptomatic simple renal cysts, which are classified as Bosniak I, do not require follow-up. Simple renal cysts are, however, currently recognized as a possible cause of various symptoms, such as unspecified lower back pain, proteinuria or hematuria, recurrent urinary tract infections, chronic constipation, decreased glomerular filtration rate, and an association with systemic hypertension.<sup>1–3</sup>

It is also worth noting that the prevalence of these Bosniak I cysts increases with age, hypertension, and smoking.<sup>4,5</sup> When a patient has a symptomatic cyst, a minimally invasive, safe, fast, and accessible treatment option is needed.<sup>6</sup> Image-guided sclerotherapy, using either ultrasound or computed tomography, constitutes an excellent option to treat patients for symptomatic renal cysts, reducing risk and hospitalization time. Previous reports have focused on the administration of alcohol at

variable doses or reinjection protocols; however, cyst relapse is a common outcome with these treatments.<sup>7,8</sup>

The monomeric form of cyanoacrylate consists of an ethylene molecule with a cyano group and an ester attached to carbon atoms. When hydrocarbons join the ester in its terminal position, N-butyl-2-cyanoacrylate (NBCA) is formed. Adhesion to endothelial tissue depends on the polymerization of the cyanoacrylate monomer, which occurs when an anion (primarily hydroxyl) from water or blood and an ethylene group attach, forming a covalent bond. This process creates a solid state with a stable connection to adjacent tissues in order, when subsequently creates fibrosis. This polymerization process starts seconds after NBCA contacts the anion, and ends completely after 1–2min.<sup>9–12</sup> NBCA is a liquid ester that is water insoluble and colorless, and is usually combined with ethiodized oil, creating a miscible compound, to minimize exothermic injuries. The presence of molecules in ethiodized oil allows it to control the polymerization of cyanoacrylate, because the oil molecules prevent NBCA from contacting the anion. Ethiodized oil is also used as a contrast

\* Corresponding author. Department of Radiology, Hospital General de Pachuca, Pachuca Hidalgo Mexico, Pachuca-Tulancingo 101, Pachuca, 42070, Mexico.  
E-mail address: [micv8403@gmail.com](mailto:micv8403@gmail.com) (M.I. Cárdenas-Vargas).

<https://doi.org/10.1016/j.jimed.2020.10.002>

Received 14 July 2020; Received in revised form 28 September 2020; Accepted 10 October 2020

Available online 13 October 2020

2096-3602/© 2020 Shanghai Journal of Interventional Radiology Press. Publishing services by Elsevier B.V. on behalf of KeAi Communications Co. Ltd.

agent in some imaging studies.<sup>13–15</sup>

Hydrodissection is a technique which helps to isolate a particular structure with water. When treating kidney cysts, it may increase the sclerosing effect of NBCA by producing an external force that surrounds the cyst with NBCA, allowing it to act longer.<sup>16–18</sup> The present study aimed to determine the effectiveness of sclerotherapy when using NBCA accompanied by hydrodissection, particularly in regards to the reduction of the initial and sustained volumes of simple renal cysts in symptomatic patients.

## Materials and methods

All consecutive patients between December 2018 and June 2019 who were referred to an interventional radiology clinic in a public primary health care unit and had been previously diagnosed with symptomatic renal cysts in an outpatient clinic were evaluated. For this prospective study, symptomatic patients with a previous diagnosis of a renal cyst classified as Bosniak I (defined as a cyst with a density of 0–20 HU, with a thin wall, and without septa, calcification, or enhancement postcontrast administration) with a minimum diameter of 3 cm were selected.

A diagnostic radiologist, who was not involved with the procedures, performed a diagnostic ultrasound before the procedure, and at 7 and 180 days after the procedure. The size of the renal cysts was calculated using formula  $V = (l \times w \times d) (0.52)$ , where length = (l), width = (w), and depth = (d). Complete resolution was defined as an absence of anechoic fluid within the cyst on the follow-up studies. A total of 28 patients were selected based on their medical history, physical examination, and ultrasound results, in addition to the results of coagulation tests conducted before the procedure. Patients were randomly divided into two groups: patients in group A were treated with ultrasound-guided NBCA sclerotherapy only, and patients in group B were treated with both ultrasound-guided NBCA sclerotherapy and hydrodissection (Fig. 1). All patients underwent only one sclerotherapy session, and none of the patients received antibiotics, pre- or post-procedure. All patients who were

selected received detailed information about the intervention, as well as the benefits, risks, and possible complications of the procedure. The patients who agreed to participate in the study signed a written informed consent. The hospital ethics committee approved this protocol with the number 2018/039.

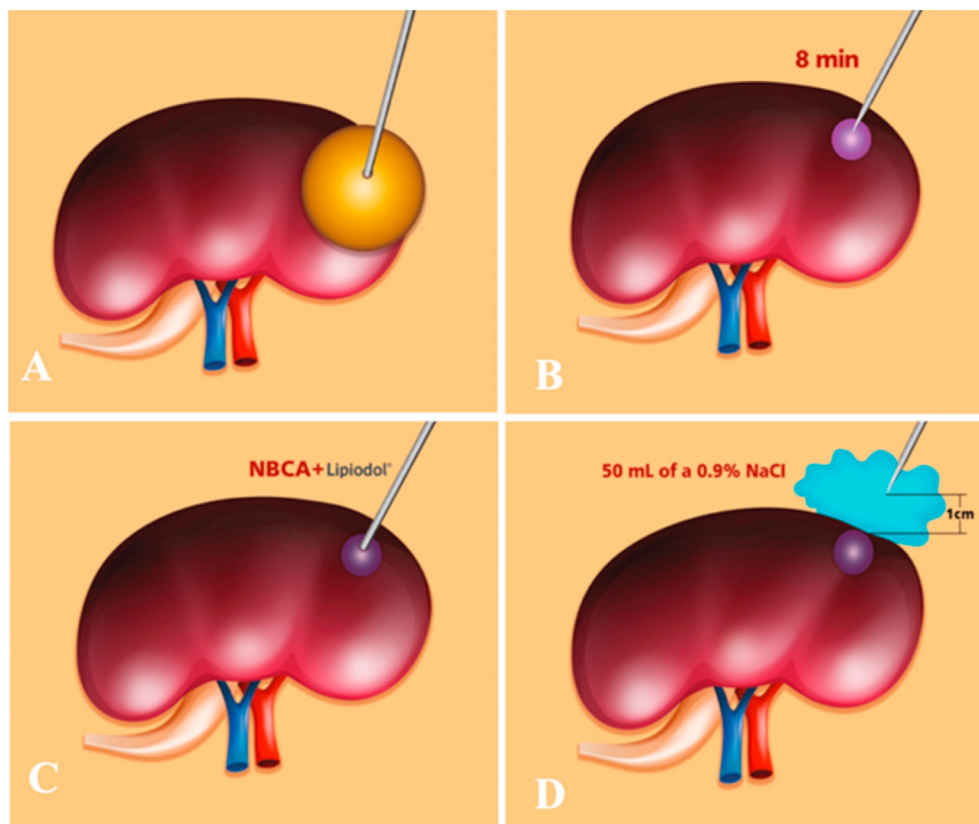
In both groups, the first part of the procedure was the same: following the insertion of a 16fr Foley catheter, the patient was placed in a prone position, and asepsis was performed on the corresponding flank region. Under ultrasound guidance, 10 mL of local anesthetic (2% lidocaine) was injected. Using a 22 G needle, 75% of the cyst contents were aspirated, followed by the injection of 5 mL of methylene blue. After 8 min, the urine in the catheter drainage bag was inspected to exclude communication with the collecting system. The remaining cyst contents were then aspirated.

After the aspiration, patients in Group A were injected with 0.5 mL of 5% glucose, followed by NBCA and Ethiodized oil. NBCA doses were calculated according to the diameter of the cyst(s) for both groups (Table 1). Before withdrawing the needle, an additional 0.5 mL of 5% glucose was injected, to prevent leakage of the mixture into adjacent tissue. After the aspiration, patients in group B underwent hydrodissection after an injection of NBCA. Using a 20 G needle placed 1 cm from the cyst wall (perirenal fat), 50 mL of 0.9% NaCl was then injected (Fig. 2).

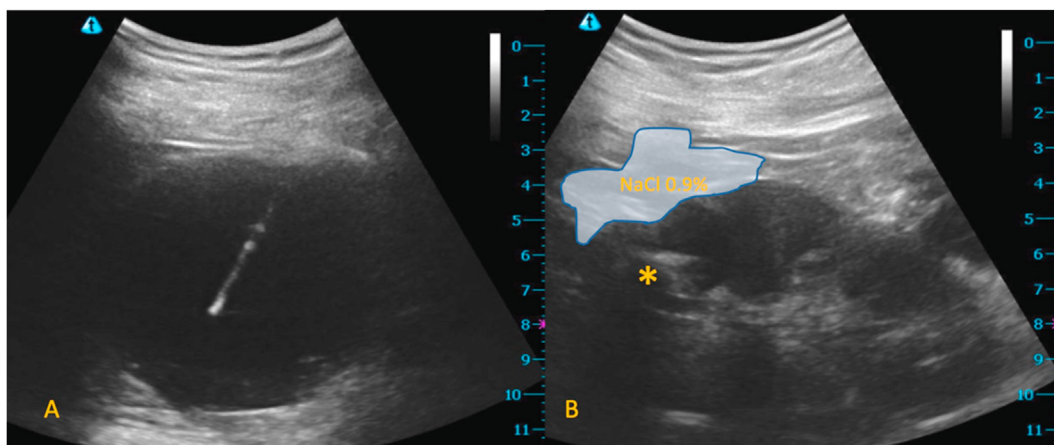
**Table 1**

NBCA dose used in sclerotherapy, dependent on the maximum size of the renal cyst.

Diameter (cm)	NBCA (mL)	Ethiodized oil (mL)
3–4.9	1	1
5–6.9	1.5	1
7–8.9	2	1
9–10.9	2.5	1
>11	3	1



**Fig. 1.** Hydrodissection technique. A) under ultrasound guidance, the renal cyst was punctured with a 22 G needle to extract 75% of the cyst content; B) 5 mL of methylene blue were injected, wait 8 min to exclude communication with the collecting system; C) thereafter, were injected with 0.5 mL of 5% glucose, followed by NBCA and ethiodized oil (NBCA doses were calculated according to cyst diameter); D) Using a 20 G needle which was placed 1 cm from the cyst wall (perirenal fat) were injected 50 mL of a 0.9% NaCl.



**Fig. 2.** Sclerotherapy with hydrodissection, A) the initial volume cyst was 311 mL, observe the hyperechogenic needle in the cyst center, B) ultrasound control after treatment, the kidney returned to the habitual localization, site where NBCA was injected (\*), it's now a small hyperechogenic zone, the blue zone in the peri renal fat is the site where the saline solution was injected, the cyst residual volume is 0 mL.

At the end of the procedure for patients in both groups, the urinary catheter was removed. All patients remained under observation for 2 h, after which complications were assessed via patient-reported discomfort, and any changes around the renal puncture site were evaluated with ultrasound. None of the patients received conscious sedation or general anesthesia.

A descriptive statistical analysis measuring central tendency and dispersion was performed. For group comparisons, the chi-squared test, Student's t-test, Mann Whitney U test, and Friedman test were used for discrete and continuous variables. IBM SPSS Statistics for Macintosh, Version 25.0 (2017). Was used for the analysis of the parametric and nonparametric data, and a *p*-value < 0.05 was considered statistically significant.

**Results**

We treated a total of 32 cysts in 28 patients, 18 (64%) females and 10 (36%) males. The mean age was 61.8 years (range: 33–89 years). There were no significant differences in age and sex between the groups (Table 2). The most frequent patient complaint was lumbar spine pain (25 patients; 89%), followed by recurrent urinary tract infections (3 patients; 11%).

The procedure was successfully completed in all of the patients, with an average procedure time of 12 min. One patient had persistent pain at the puncture site 30 min after the procedure, which subsided after the administration of oral NSAIDs. All of the patients were discharged after 120 min, with no complications, and reported an improvement in their cyst-related symptoms at the 7 day follow-up. After 180 days of follow-

**Table 2**  
Basal characteristics of patients and cysts (Chi-squared and Student's t-test).  
Change in cyst volume at 7 days.

		Group A (n = 12)	Group B (n = 16)	All (n = 28)	<i>p</i>
Age	Mean ± SD	64.33 ± 14.6	59.94 ± 12.9		0.405
	Minimum	40	33	33	
	Maximum	89	79	89	
Gender	Males	5	5	10	0.569
	Females	7	11	18	
Cyst Basal Volume (mL)	GA (n = 15)		GB (n = 17)	All (n = 32)	0.455
	Mean ± SD	61 ± 73	140 ± 180	103 ± 144	
	Minimum	9.73	8.23		
	Maximum	266	608.34		

up, all patients remained asymptomatic.

*Basal renal cyst volume*

The mean initial volume of the renal cysts was 103 mL (range: 8.2–608 mL). There were no significant differences in the initial cyst volumes between the treatment groups (Table 2), showing that before treatment, the patients presented with similarly sized renal cysts.

In the present study, we observed a significant reduction in the volume of the cysts, with a decrease of 96.8% in all patients (Fig. 3), 96% in group A, and 97.6% in group B (Table 3); however, there was no significant difference between the treatment groups (Fig. 4). In the gender analysis, there was a significant reduction in cyst volume, again with no significant difference between the treatment groups (Fig. 5). Complete resolution was observed in 50% of the patients overall (33% of group A and 64% of group B), with a non-significant *p*-value (0.07).

*Change in cyst volume at 180 days*

The reduction in the volume of the cysts was maintained at 180 days, reaching a decrease of 98.6% in all patients (Fig. 3), 98.2% in group A and 98.9% in group B, and again, there were no significant differences between the treatment groups (Fig. 4). Complete resolution was observed at 180 days in 62.5% of all patients (60% of group A and 64% of group B), also with a non-significant *p*-value (0.78).

**Discussion**

The present study shows a persistent and significant reduction of >90% in the volume of the renal cysts after sclerotherapy using NBCA. Sclerotherapy is a technique which uses different substances to treat simple renal cysts.<sup>19,20</sup> Baysal et al.<sup>21</sup> reported a reduction in renal cyst volume of 62.5%, and Ali et al.<sup>22</sup> showed a decrease of 83.7%, both using NBCA. In the present study, we observed a technical effectiveness of 100% for the procedure, the resolution of the initial symptoms in all patients, and a notable reduction in cyst volume of 96.8% and 98.6% at 7 and 180 days of follow-up, respectively. The sclerotherapy treatment used in both treatment groups was safe and highly reliable; none of the patients had any acute or major complications associated with the procedure. No patient remained hospitalized for more than 2 h, and none returned for emergency treatment. All procedures required local anesthesia only, and no specialized equipment, unlike laparoscopic surgery, which requires general anesthesia and equipment not available in most hospitals.<sup>23–25</sup>

The range of the initial cyst volumes had a wide distribution, and both

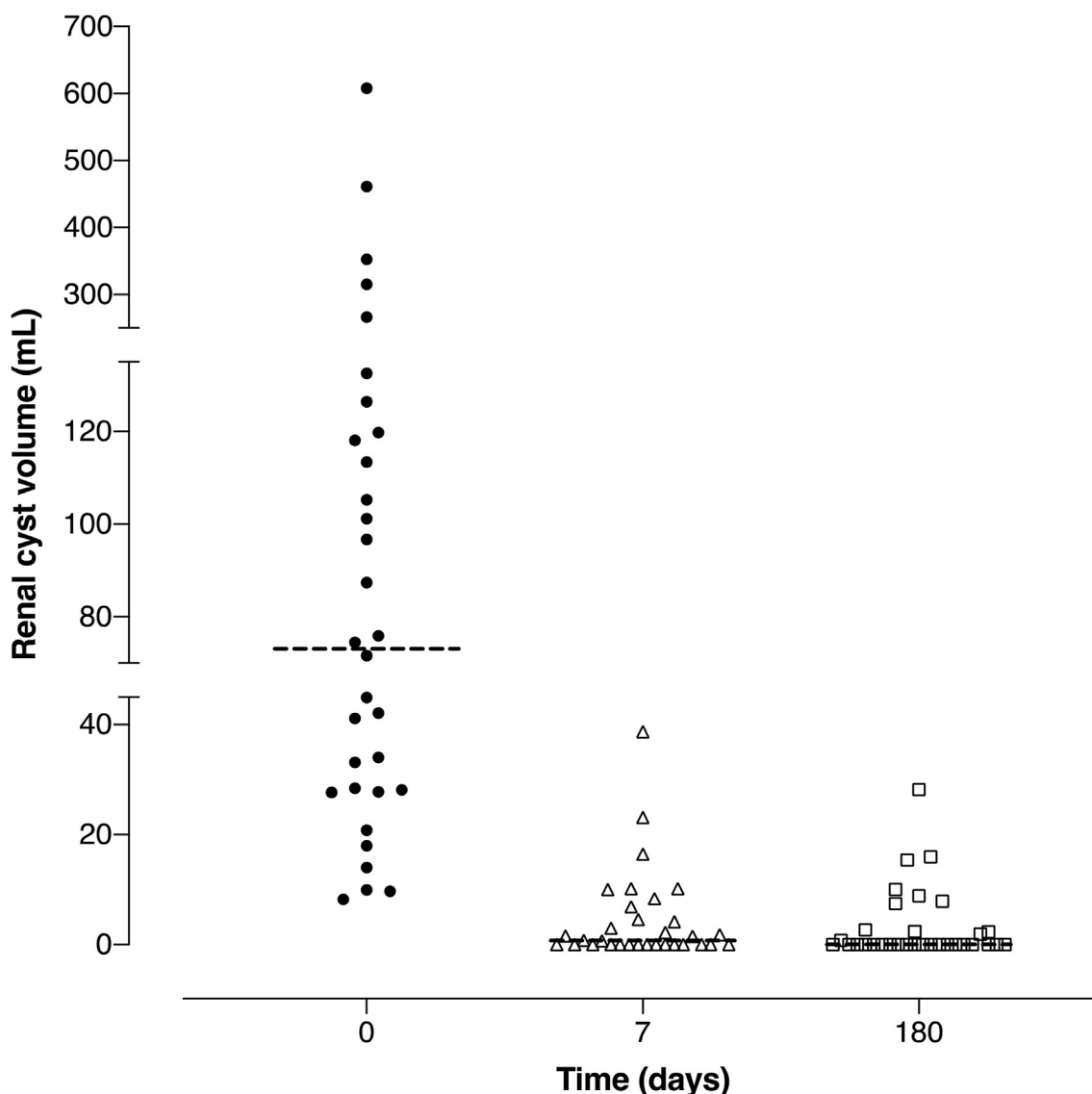


Fig. 3. Cyst Volume reduction in all patients at 7 and 180 days. At 7 day average volume reduction was 96.8% ( $p = 0.01$ ). At 180 day average volume reduction was 98.6% ( $p = 0.01$ ) (Friedman).

Table 3

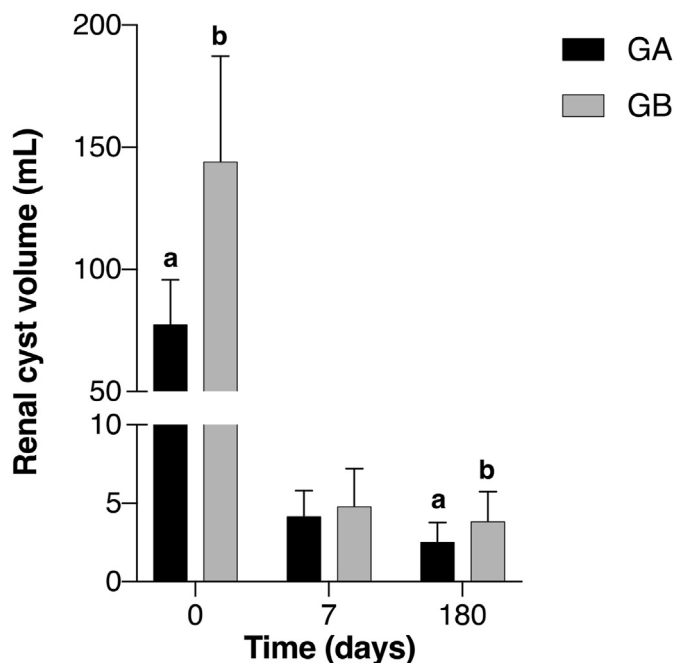
Cyst volume after treatment, and percentage of volume reduction at 7 and 180 days after treatment (Chi-squared and Student’s t-test).

	All (n = 32)	Group A (n = 15)	Group B (n = 17)	p
7 day follow-up volume mL (SD)	3.9 ( $\pm 8$ )	3.9 ( $\pm 6.3$ )	3.8 ( $\pm 9.5$ )	0.96
180 day follow-up volume mL (SD)	2.6 ( $\pm 6.8$ )	1.7 ( $\pm 4.2$ )	3.2 ( $\pm 8.4$ )	0.31
7 day volume reduction (%)	96.8	96	97.6	0.36
180 day volume reduction (%)	98.6	98.2	98.9	0.4
Patients with complete resolution (n; %) at 7 days	16; 50%	5; 33%	11; 64%	0.07
Patients with complete resolution (n; %) at 180 days	20; 62.5%	9; 60%	11; 64%	0.78

small (<11 cm in diameter) and large cysts (>11 cm in diameter) were successfully treated with our technique, which benefits clinical practice in which symptomatic patients may present with a wide variety of kidney cyst sizes. The initial cyst volumes were similar in both treatment groups, and in total there was a reduction of 98.6% in the cyst volumes. These

results can be attributed to the technique in which the dose of NBCA depends on the largest diameter of the renal cyst being treated, which aims to standardize the treatment plan. In previous studies, the dose of NBCA was the same, regardless of size of the cyst.<sup>21,22,26</sup> When the results were analyzed regarding the complete resolution of the cysts, it was observed that the group which underwent hydrodissection showed a greater improvement; however, the difference was not statistically significant. This finding was likely due to the small number of patients included in the present study. In the evaluations at 7 and 180 days, a progressive benefit was observed in the NBCA-only group at 180 days, while in the NBCA plus hydrodissection group, the effect on the volume reduction was obvious from day 7.

In this study, the addition of hydrodissection to the procedure achieved a greater reduction in the volume of the cysts, although the difference between this group and the monotherapy group was not significant, which can be explained using the three mechanisms of action of the NBCA. First, one effect of this compound is that it creates stable bonds with any adjacent tissue once the polymerization has been completed, which starts when the NBCA comes into contact with the anion present in the liquid inside the renal cyst. In previous studies, it has been shown that this polymerization ends after a maximum of 2 min,



**Fig. 4.** Cyst volume reduction between treatment groups. a, b shows significant difference in the same group at different time (0 day compared with 180 day), this means, in group A was a 98.2% volume reduction ( $p = 0.01$ ), in group B was a 98.9% volume reduction ( $p = 0.01$ ) (Friedman). There is no significant difference between A and B groups at 0 days ( $p = 0.439$ ), at 7 days ( $p = 0.359$ ) and at 180 months ( $p = 0.965$ ) (U de Mann Whitney).

after which the force exerted by the hydrodissection is no longer necessary. It is because the compound solidifies in the first 2 min, and not

because the cyst walls remain united longer, that a greater decrease in volume is observed.<sup>13,14,27</sup> Second, NBCA has an effect on cells which are developing fibrosis. Epithelial cells that come into contact with NBCA generate fibrous scar tissue, and also become incapable of producing fluid. Additionally, previous studies have proven, that over time, the thickness of the fibrous layer increases.<sup>28,29</sup> Third, NBCA degenerates into a granuloma, and therefore does not cause necrosis. This granuloma occupies the physical space where the cyst was initially located, hindering future growth and fluid production.<sup>29,30</sup> These mechanisms may explain why an increased dose of NBCA effects the reduction of the volume of simple renal cysts. Bosniak 1 renal cysts (round or oval in shape, anechoic content, without septa or calcifications, with thin and smooth walls), have a low rate of malignancy (<1%). We believe that in the setting of minimally invasive procedures, an efficient strategy with ultrasound follow-up could be a safe and affordable choice.<sup>19,31–33</sup>

**Conclusion**

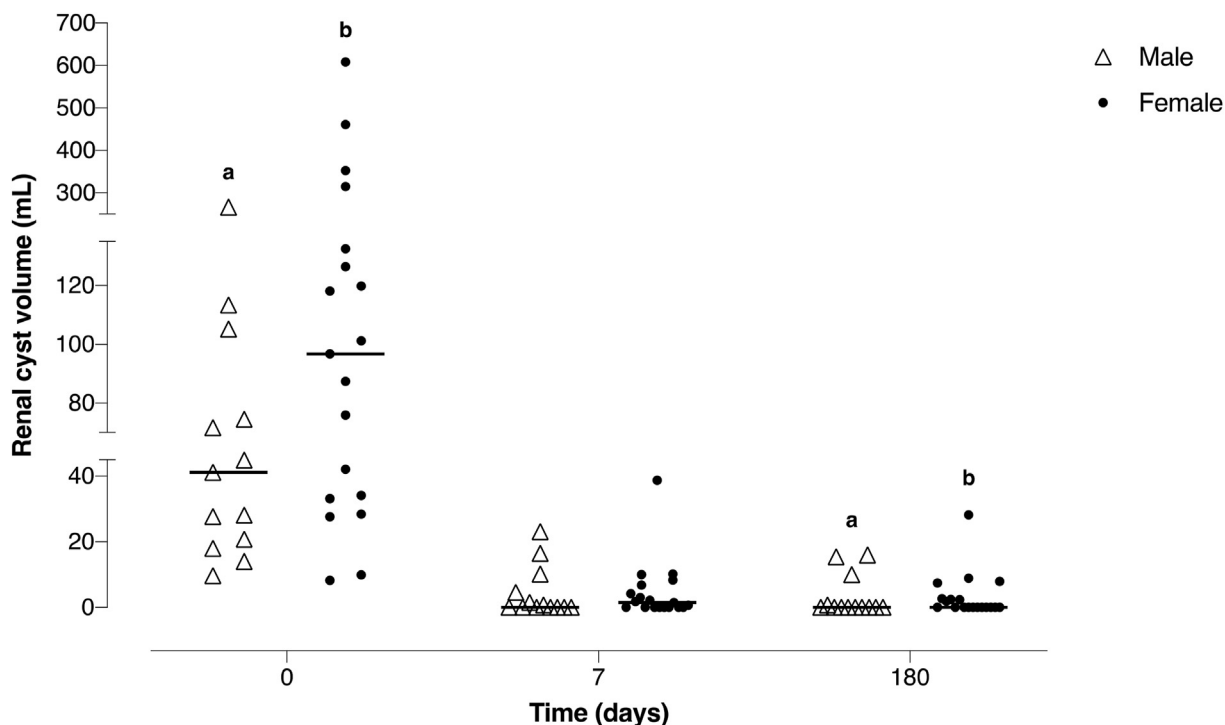
Treating symptomatic renal cysts with sclerotherapy using NBCA is a safe and effective treatment. There is a persistent reduction in cyst volume, as well as a prolonged improvement of symptoms, when treating these cysts with sclerotherapy using NBCA as well as hydrodissection.

**Ethical approval**

The study was approved by the ethics committee of General Hospital of Pachuca. All clinical practices and observations were conducted in accordance with the Declaration of Helsinki. Informed consent was obtained from each patient before the study was conducted.

**Patient consent**

Written informed consent was obtained from patients for publication



**Fig. 5.** Cyst volume reduction in all patients by gender at 7 and 180 days. a, b shows significant difference in the same group at different time (0 day compared with 180 day), this means, in male group was a 97.4% volume reduction ( $p = 0.01$ ), in female group was a 97.7% volume reduction ( $p = 0.01$ ) (Friedman). There is no significant difference between male and female groups at 0, 7 and 180 day ( $p = 0.103$ ) (U de Mann Whitney).

of these case reports and any accompanying images.

### Declaration of competing interest

The authors declare that they have no conflicts of interests to this work. We declare that we do not have any commercial or associative interest that represents a conflict of interest in connection with the work submitted.

### Acknowledgments

None.

### References

- Chen J, Ma X, Xu D, et al. Association between simple renal cyst and kidney damage in a Chinese cohort study. *Ren Fail.* 2019;41(1):600–606.
- Simms RJ, Ong AC. How simple are “simple renal cysts”? *Nephrol Dial Transplant.* 2014;29(1):106–112.
- Park H, Kim CS. Natural 10-year history of simple renal cysts. *Korean J Urol.* 2015; 56(5):351–356.
- Mensel B, Kühn JP, Kracht F, et al. Prevalence of renal cysts and association with risk factors in a general population: an MRI-based study. *Abdom Radiol.* 2018;33(1): 107–114.
- Çalışkan S, Sungur M, Eser B, et al. Endothelin-1 level in patients with simple renal cyst. *Folia Med (Plovdiv).* 2019;61(4):545–550.
- Carrim ZI, Murchison JT, et al. The prevalence of simple renal and hepatic cysts detected by spiral computed tomography. *Clin Radiol.* 2003;58(8):626–629.
- Bas O, Nalbant I, Can N., et al., Management of Renal Cysts. *J Soc Laparosc Surg.* 2015;19(1):49–55.
- El-Kader OA, Mohyelden K, Metwally AH, et al. Ethanolamine oleate vs. absolute ethanol as sclerosing agents for treating symptomatic simple renal cysts. *Arab J Urol.* 2014;12(4):294–298.
- Pollak JS, White J. The use of cyanoacrylate adhesives in peripheral embolization. *J Vasc Intervent Radiol.* 2001;12(8):907–913.
- Hill H, Chick JF, Hage A, et al. N-butyl cyanoacrylate embolotherapy: techniques, complications, and management. *Diagnostic Interv Radiol.* 2018;24(2):98–103.
- Mestieri LB, Saska S, Carrodegua RG, et al. Evaluation of n-butyl cyanoacrylate adhesive in rat subcutaneous tissue. *Dermatol Surg.* 2012;38(5):767–771.
- Suthar P, Shah S, Wanknis P, et al. Comparing intra-oral wound healing after alveoloplasty using silk sutures and n-butyl-2-cyanoacrylate. *J Korean Assoc Maxillofac Surg.* 2020;46(1):28–35.
- Carral J, Gueorguieva G, Rodríguez V, et al. Efectos locales de la aplicación del n-butyl 2-cianoacrilato en la microcirugía vascular experimental. *Rev Cubana Med Mil.* 2006;35(3):1–8.
- Li YJ, Barthès-Biesel D, Salsac AV. Polymerization kinetics of n-butyl cyanoacrylate glues used for vascular embolization. *J Mech Behav Biomed Mater.* 2017;69(2): 307–317.
- González JM. Cianoacrilato: definición y propiedades. Toxicidad y efectos secundarios. Aplicaciones en medicina y odontología. *Av Odontostomatol.* 2012; 28(2):95–102.
- Liu CH, Yu CY, Chang WC, et al. Computed tomographic-guided percutaneous radiofrequency ablation with hydrodissection of hepatic malignancies in the subcapsular location: evaluation of safety and technical efficacy. *J Chin Med Assoc.* 2016;79(2):93–100.
- Johnson A, Sprangers A, Cassidy P, et al. Design and validation of a thermoreversible material for percutaneous tissue hydrodissection. *J Biomed Mater Res B.* 2013;101(8): 1400–1409.
- Mauri G, Nicosia L, Varano GM, et al. Tips and tricks for a safe and effective image-guided percutaneous renal tumour ablation. *Insights Imaging.* 2017;8(3):357–363.
- Skolarikos A, Laguna MP, de la Rosette JJ. Conservative and radiological management of simple renal cysts: a comprehensive review. *BJU Int.* 2012;110(2): 170–178.
- Cheng D, Amin P, Ha T. Percutaneous sclerotherapy of cystic lesions. *Semin Intervent Radiol.* 2012;29(4):295–300.
- Baysal T, Soylu A. Percutaneous treatment of simple renal cysts with n-butyl cyanoacrylate and iodized oil. *Diagnostic Interv Radiol.* 2009;15(2):148–152.
- Ali TA, Mohamed A, Enite1 A, et al. Ultrasound-guided percutaneous sclerotherapy of simple renal cysts with n-butyl cyanoacrylate and iodized oil mixture as an outpatient procedure. *Urol Ann.* 2016;8(1):51–55.
- Chen W, Xu ZB, Xu L, et al. Modified mini-laparoscopic surgery optimized the laparoscopic decortication of renal cyst. *Urol J.* 2019;16(6):547–551.
- Choi JD, Yoo TK, Kang JY, et al. A comparative study of percutaneous aspiration with sclerotherapy and laparoscopic marsupialization. *J Laparosc Adv Surg Tech.* 2020:1–6.
- Zhang X, Cao D, Han P, et al. Aspiration-sclerotherapy versus laparoscopic de-roofing in the treatment of renal cysts: which is better? *BMC Nephrol.* 2020;21(1):1–7.
- See HK, Seung HK, Jeong YC. Cyst ablation using a mixture of N-butyl cyanoacrylate and iodized oil in patients with autosomal dominant polycystic kidney disease: the long-term results. *Korean J Radiol.* 2009;10(4):377–383.
- Hayashi N, Takeuchi Y, Miura H, et al. Is the cessation of blood flow faster than the polymerization of an n-butyl cyanoacrylate–lipiodol mixture? An in vitro phantom study. *Cardiovasc Intervent Radiol.* 2020;43(4):630–635.
- Kukleta JF, Freytag C, Weber M. Efficiency and safety of mesh fixation in laparoscopic inguinal hernia repair using n-butyl cyanoacrylate: long-term biocompatibility in over 1, 300 mesh fixations. *Hernia.* 2012;16(2):153–162.
- Suh YJ, Yu HW, Kim SJ, et al. Biocompatibility of n-butyl-2-cyanoacrylate (Histoacryl) in cervical structures of rats: prospective in vivo study. *Ann Surg Treat Res.* 2019;96(4):162–168.
- Aksoy F, Yilmaz F, Yildirim YS, et al. Use of N-butyl cyanoacrylate in nasal septoplasty: histopathological evaluation using rabbit nasal septum model. *J Laryngol Otol.* 2010;124(7):753–758.
- Whelan TF. Guidelines on the management of renal cyst disease. *J Can Urol Assoc.* 2010;4(2):98–99.
- Tay SY, Tiu CM, Hu B, et al. Characterization and management of various renal cystic lesions by sonographic features. *J Chin Med Assoc.* 2018;81(12):1017–1026.
- Eissa A, El Sherbiny A, Martorana E, et al. Non-conservative management of simple Renal cysts IN adults: a comprehensive review of literature. *Minerva Urol Nefrol.* 2018;70(2):179–192.