



Musculo-skeletal problems of the hand in haemophilia

Elena Bravo¹

Raul Barco²

E. Carlos Rodríguez-Merchán³

- Musculo-skeletal complications of the hand in the haemophilia patient are rare, and they include synovitis, arthropathy, pseudotumours, carpal tunnel syndrome and vascular aneurysms and pseudoaneurysms.
- The best way to prevent the aforementioned musculo-skeletal complications is early continuous haematological primary prophylaxis (intravenous infusion of the deficient coagulation factor, ideally from cradle to death).
- There is a wide range of procedures that a hand surgeon treating these patients should be able to manage, including synovectomy, prosthetic replacement of small joints, removal or curettage of pseudotumours, release of carpal tunnel and, occasionally, vascular reconstruction of aneurysms.
- The treatment of these patients should be made at an institution with close collaboration between haematologists and hand surgeons (all surgical procedures must always be performed under cover of the deficient coagulation factor).

Keywords: aneurysm; arthropathy; bone cyst; carpal tunnel syndrome; haemophilia; hand; pseudotumour

Cite this article: *EFORT Open Rev* 2020;5:328-333.

DOI: 10.1302/2058-5241.5.190078

Introduction

Haemophilia is a hereditary recessive disease linked to sex, causing a coagulation disorder characterized by bleeding episodes, which can be spontaneous or as a result of minor trauma. There are two types of haemophilia: type A, due to a deficiency of factor VIII and type B, due to a deficit of factor IX. Due to their kind of inheritance, males are affected more by the disease.¹ Based on the level of clotting factors, haemophilia is classified into mild (clotting factor level 5–40%), moderate (1–5%), and severe (< 1%).

Von Willebrand disease (VWD) is a condition considered to be related to haemophilia, affecting between 0.6% and

1.6% of the population.^{2,3} VWD is caused by a deficiency or by dysfunctional von Willebrand factor (VWF). There are three types: type I, which is the most common form (75%), and involves insufficient levels of VWF; type II in which VWF is dysfunctional; and type III, the most severe and rarest type, which combines both alterations.

Bleeding episodes induce musculo-skeletal damage through a cytotoxic effect on cartilage. Depending on the severity of the condition, bleeding may be caused by minor injury or may follow major operations or injury to the affected region.^{4,5} Haemophilic and von Willebrand patients present with 80–90% of their bleeding episodes happening in the musculo-skeletal system, especially in large synovial joints, being less frequent in small joints such as the hands.⁶ It is somewhat striking how the hand with its multiple small joints, constant movements, and trauma escapes significant damage.⁷ Injuries to the hand have rarely been analysed in the literature. This review aims to analyse the musculo-skeletal problems of haemophilia in the hand, with a focus on possible clinical presentations and an update on correct diagnosis and treatment strategies.

Methods

A review of the literature was performed on hand problems in haemophilia. The public search engines PubMed and the Cochrane Library were used for the search, including all available literature up to 1 December 2019. Inclusion criteria were haemophilia problems of the hand. The search strategy rendered 264 articles, of which, after reading titles and abstracts, 23 were selected and reviewed. Fig. 1 shows our search strategy.

Haemophilic arthropathy in joints of the hand

Haemophilic arthropathy in the joints of the hands may be affected by spontaneous joint bleeding, with repeated

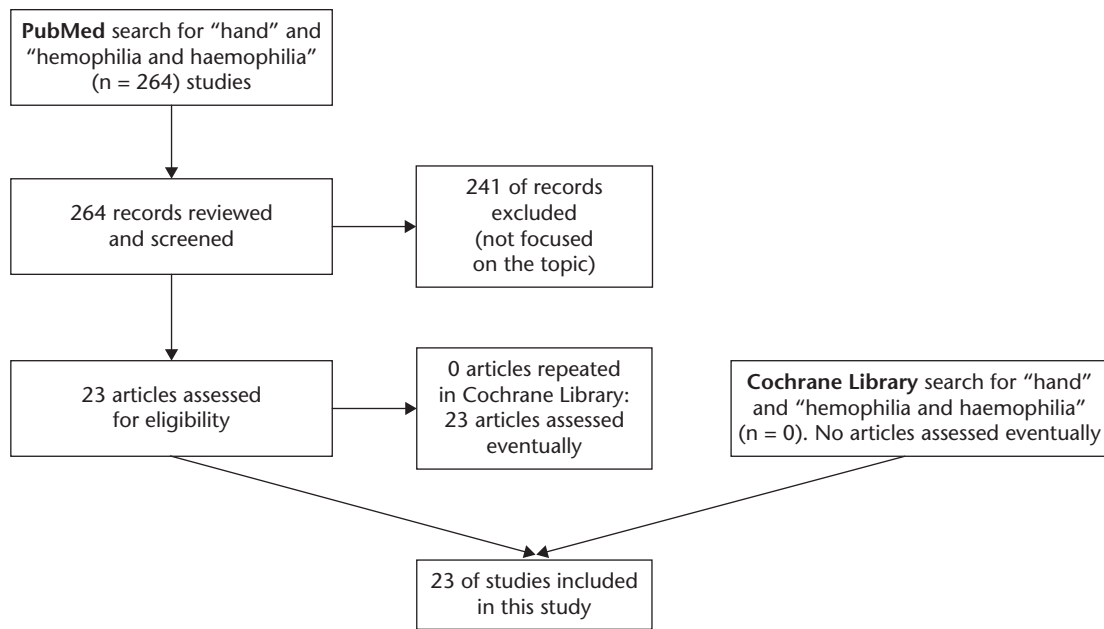


Fig. 1 Flowchart of our search strategy regarding hand problems in haemophilia.

haemarthrosis leading to haemophilic arthropathy, a debilitating disease with a negative impact on mobility and quality of life. Synovitis is one of the earliest complications of haemarthrosis and is characterized by synovial hypertrophy, and a high degree of neo-angiogenesis with subsequent bleeding, cartilage degeneration, and bone damage. This process perpetuates synovitis, forming a vicious circle.

The metacarpophalangeal (MCP) joints are predominantly involved (42 of 50 joints) in the hand.⁸ Van Deuken et al described the involvement of the different joints with bleeding in MCP joints in 52% of cases, proximal interphalangeal (PIP) joints in 48%, and distal interphalangeal (DIP) joints in 26%, the causes being mostly traumatic (77%), followed by iatrogenic (58%) and spontaneous episodes (19%).⁹ Radiographic abnormalities are characterized by irregularity in the joint in haemophilic patients. Since more changes occur in large joints, small joints have not been primarily studied. The severity of the arthropathy increases with the age of the patient and with the number of bleeding episodes, although the correlation between these parameters is variable. The elbow joint is the most affected in the upper limb (87%), followed by the glenohumeral and wrist joints. Hand joints are uncommonly affected and rarely produce arthropathy.¹⁰

Treatment of this condition consists of preventing joint bleeding episodes and reconstructive orthopaedic procedures ranging from synovectomy to prosthetic replacement. There is currently no disease-modifying therapy available to fill the gap between preventive measures and reconstructive procedures. Considering the pathogenic

mechanisms and molecular pathways, potential targets for arthropathy therapy are iron chelators, anti-inflammatory treatment, anti-fibrinolytic, and bone-remodelling agents. These options have demonstrated beneficial effects, predominantly in a preclinical setting, but their clinical application is still a long way off.^{11,12}

Primary prophylaxis is the treatment of choice to prevent bleeding episodes, but access to these programmes might be limited by cost. Intravenous infusion of deficient factors has decreased the events of muscle, articular and bony bleeding episodes.¹³ New therapies for prophylaxis are extended plasma half-life coagulation factors. These can be given every 10–15 days, decreasing the burden of annual injections and, possibly, improving patient compliance.¹⁴

Emicizumab is a therapeutic antibody that links activated factor IX with factor X, allowing for blood clot formation without the need for factor VIII. It has recently been approved for the prevention of bleeding episodes in haemophilic patients. It allows well-spaced dosing intervals every one or two weeks with the advantage of subcutaneous injection.¹⁴ However, the search is ongoing to obtain curative gene transfer therapy, and stop bleeding with a single therapeutic intervention of life-long duration.¹⁵

Haemophilia pseudotumours in the hand

Haemophilic cysts and pseudotumours are uncommon presentations of bleeding disorders such as haemophilia A, haemophilia B, and VWD, with a reported incidence among these patients of 1.14%.¹⁶

Pseudotumours may originate in soft tissues or subperiosteal or intraosseous areas caused by recurrent bleeding. They are classified into three types according to the anatomic sites where bleeding occurs. In type I, bleeding occurs in the muscles with slow mass enlargement, developing a fibrous capsule and affecting surrounding tissues by pressure. In type II, subperiosteal bleeding occurs, and expansion of the lesion strips the periosteum, displacing soft tissue and facilitating bony erosion. Type III lesions are very infrequent and are characterized by the appearance of pseudotumours within the bone.^{17,18}

In the current literature, the terms haemophilic cysts and pseudotumours have been used interchangeably.¹⁹ According to Fernandez de Valderrama's classification, a haemophilic cyst is an extraosseous cystic swelling confined to the muscle with no effect on the adjacent bone, whereas in pseudotumours the adjacent bone is also affected.²⁰ Typical presentation in adult patients occurs in the proximal skeleton and is rare in small bones distally. Young patients with open epiphyseal growth plates are typically affected in the hand and these pseudotumours are characterized by faster growth when compared to other locations.^{21,22} They can develop after minor trauma or spontaneously, without correlation to the severity of the disease (factor count or orthopaedic disease).²³

Magallón et al reported that 60.5% of hand injuries occurred in patients with haemophilia A, 9.9% in haemophilia B, 18% in VWD, and 12.1% in other coagulopathies.²³ Other authors have reported all occurrences being in patients with haemophilia A.¹⁶

Bleeding may produce swelling, pain, and, with repeated and continued bleeding pseudotumours may increase in size and create bone erosion that leads to fractures and infections. Additionally, when a haemophilic pseudotumour is left untreated, it may induce compression and pressure necrosis of the adjacent structures. Its more frequent location is in the long bones of the lower extremities, often resulting in soft tissue destruction and neurovascular compression. In the early stages of radiologic findings, periosteal reactions might be so minimal that soft tissue mass may be the only finding. A large soft tissue mass with areas of adjacent bone destruction can be seen, with intraleisional calcification frequently observed. High-resolution computed tomography (CT) and T2-weighted magnetic resonance imaging (MRI) are useful in the evaluation of haemophilic pseudotumours. The latter has better soft tissue resolution capability, which helps to differentiate blood clots from haemophilic pseudotumours at the initial stage, and it is considered the investigative method of choice.²⁴

A differential diagnosis must be made with several other types of lesion, including intraosseous synovial cysts, osteosarcoma, angioleiomyoma, aneurysmal bone cysts, giant cell tumours of the bone, and non-ossifying fibroma.²⁵ Some of the most common haematologic

disorders may be detected in radiographs of the hand, especially in plasma cell dyscrasias and proliferative malignant diseases.²⁶ However, it is infrequent to see haemophilic arthropathy or cysts in developed countries.

There is a lack of consensus regarding the management of haemophilic cysts and pseudotumours. Various treatment options for this pathology have been proposed; however, because of its rarity, no standardized treatment protocol has been developed. Pseudotumours occurring in small bones, especially in younger patients, are managed with non-surgical measures using factor replacement therapy and immobilization for at least eight weeks.²⁷ When pseudotumours are larger than 3 cm in diameter or when prior non-surgical management has failed, curettage with bone-graft packing and factor replacement therapy may be required.^{16,28}

Indications for surgical excision include failure of conservative therapy, extensive lesions, soft tissue pseudotumours, imminent rupture, the presence of skin necrosis, and neurovascular complications.²⁹ Other options for treatment include the aspiration of the lesion with fibrin glue injection, embolization of the bleeding vessel, and radiotherapy. Fibrin glue consists of two separate solutions of fibrinogen and thrombin, which, when mixed, mimic the final stages of the clotting cascade to form a fibrin clot. This clot may produce haemostasis and promote wound healing.³⁰ Embolization is not appropriate for hand lesions due to the potential for vascular compromise. Radiotherapy is used when other methods can not control the bleeding, and it works by inducing inflammation and fibrosis of local blood vessels. Subasi et al have proposed radiotherapy as an alternative modality in haemophilic hand pseudotumours, even without factor VIII therapy, observing secondary calcification of the haemophilic pseudotumour within one month of treatment and complete healing by 2 to 3 months.³¹ The optimal radiation dose for haemophilic pseudotumours, however, has not been defined.³² Potential complications include stiffness and post-radiation neuropathy, which limits its use.^{33,34} Our experience of these options is very limited due to the success of haematological prophylaxis to prevent these problems.

Carpal tunnel syndrome

Haemophilia can cause haemarthrosis and haematomas, with the latter potentially resulting in compartment syndrome and nerve compression, acute carpal tunnel syndrome (CTS) being a rare complication (Fig. 2).³⁵ Acute CTS in haemophilic patients often begins following trivial upper limb trauma. In contrast, in healthy patients, it usually follows a fracture of the distal radius.³⁶ On clinical examination, patients may be tender over the volar aspect of the wrist, may have a positive Tinel or Phalen

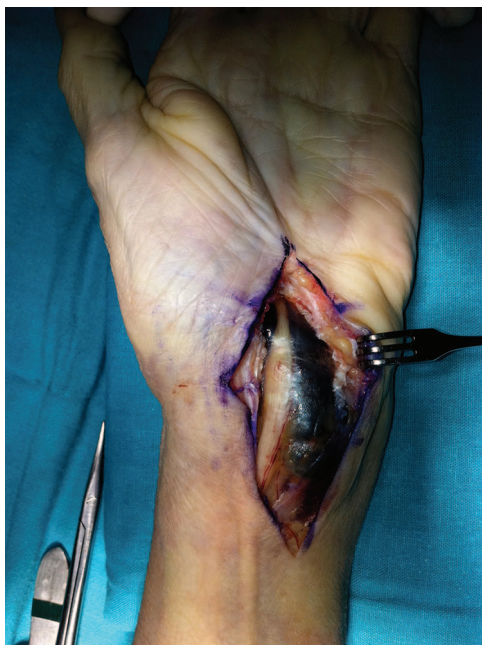

Fig. 2 Clinical picture of a surgical case of carpal tunnel syndrome (CTS) release. A 51-year-old woman with pain and paresthesias of the median nerve territory of her left hand was treated with adequate replacement therapy and surgical release after progressive symptoms. An extensile volar approach was used to adequately explore the extent of the haematoma. After carpal tunnel release, evacuation of the haematoma and neurolysis of the median nerve, the patient recovered swiftly.

test, and will show neurologic impairment of the median nerve. The diagnosis requires careful clinical evaluation, as initial clinical features may be subtle. The investigation of choice for acute CTS is an MRI of the wrist to image the carpal tunnel and to exclude articular pathology. When this investigation is not available, ultrasound scans are useful to image the soft tissue mass combined with radiographs to exclude an acute fracture. Differential diagnosis must be made with fractures, dislocations, and haematoma causing compartment syndrome.

Management includes early administration of recombinant factor VIII for 3–5 days in conjunction with elevation of the limb and immobilization.^{37,38} Close clinical observation is required to monitor the median nerve function. Urgent surgical decompression of the carpal tunnel may be needed if symptoms fail to improve, but this is a rare situation.³⁹ The timing of surgical intervention, however, remains unclear. Cases with apparent findings of acute CTS and adequate factor replacement therapy should undergo immediate surgical decompression to obtain complete and early recovery.⁴⁰ Similar to CTS, cubital tunnel syndrome can occur and should be handled conservatively in the majority of cases.⁴¹ Although this pathology is

rare, haemorrhage in the volar aspect of the wrist or in the anterior muscles of the forearm must always be followed to avoid potential complications such as compression neuropathies or muscular contractures.⁴²

Pseudoaneurysms and true aneurysms

Palmar digital artery aneurysms, like all other aneurysms, are classified into two broad categories, true and false (pseudoaneurysm). In true aneurysms, normal arterial wall architecture is maintained in contrast to false or pseudoaneurysms, where the wall consists of fibrous tissue or scar. Both types of aneurysms are infrequent lesions. Despite the high incidence of hand injuries, aneurysms of the digital arteries are extremely rare.⁴³ In our experience, pseudoaneurysms are more frequent than true aneurysms due to blunt trauma or puncture wound of the hand in haemophilic patients.

Pseudoaneurysm formation is preceded by a penetrating hand injury that breaks the arterial wall. The subsequent haematoma is organized, and then, recanalized.^{44–46} Aneurysms of the ulnar artery have also been reported for sequelae of hypothenar hammer syndrome.⁴⁷

Aneurysms can happen at any age, even as a newborn.⁴⁸ Clinical findings are usually a pulsating swelling in the hand associated with paresthesias and decreased sensation of the affected nerve. In 50% of cases, the mass may be pulseless, complicating the differential diagnosis from other lesions, including cysts, haematomas, foreign bodies, or granulomas.⁴⁹

Arteriography is considered the gold standard diagnostic tool because of its ability to identify the primary lesion and assess the extent of local damage, identify distal emboli, and differentiate the aneurysm from other injuries. Furthermore, it allows the evaluation of the collateral flow to facilitate possible reconstructive procedures.⁵⁰ Contrast-enhanced MRI angiography has high sensitivity and can be used in place of conventional arteriography in the investigation of lesions of the hand, albeit at a higher cost.⁴³ Alternatively, ultrasonography with colour-duplex scanning is helpful for diagnosis, being the most useful non-invasive diagnostic tool.

Small aneurysms should be treated with external compression as the first line of treatment. Larger aneurysms are better treated with surgical resection and ligation of the feeding artery when distal circulation is not compromised. Surgical reconstruction with end-to-end vascular anastomosis or vein graft interposition is warranted if distal circulation is compromised.⁴³ Percutaneous treatment using an injection of thrombin guided by Doppler ultrasound has been used safely with good results and could be an alternative treatment in haemophilic patients with pseudoaneurysms.⁵¹

Conclusions

Most pathologies of the hand in haemophilic patients are secondary to bleeding episodes. All efforts should focus on prevention, ensuring adequate patient education, training of health personnel, and elimination of social barriers to ensure early access to adequate treatment with correct replacement factor therapy. Future research should investigate the effect of different replacement protocols or gene therapy in the incidence of haemophilia-related problems of the hand. In our experience, musculo-skeletal problems of the hand in haemophilia are rare due to the low incidence of involvement of the small joints and the improved control of the disease. A high level of clinical suspicion is necessary to promptly identify problems of the hand and ensure appropriate diagnosis and proper treatment. While surgical procedures are similar to those for non-haemophilic patients, surgical treatment is recommended to be undertaken only at institutions where there is expert haematology support to monitor factor levels correctly. Failure to do so may increase the potential of uncontrolled bleeding with potentially life-threatening complications.

AUTHOR INFORMATION

¹Plastic Surgery Department, Hospital Universitario La Paz, Madrid, Spain.

²Upper Limb Unit, Orthopedic Surgery Department, Hospital Universitario La Paz, Madrid, Spain.

³Haemophilia Orthopedic Unit, Orthopedic Surgery Department, Hospital Universitario La Paz, Madrid, Spain.

Correspondence should be sent to: Elena Bravo, Pº Castellana, 261, Madrid 28046, Spain.

Email: elbrabra@hotmail.com

ICMJE CONFLICT OF INTEREST STATEMENT

RB reports that he is President Elect of the Spanish Society for Surgery of the Shoulder and Elbow (SEHC); has provided consultancy for Acumed and Exactech; has received grants from Acumed; and has received payment for lectures including service on speakers' bureaus from Smith and Nephew and Conmed, all outside the submitted work.

The other authors declare no conflict of interest relevant to this work.

FUNDING STATEMENT

No benefits in any form have been received or will be received from a commercial party related directly or indirectly to the subject of this article.

LICENCE

© 2020 The author(s)

This article is distributed under the terms of the Creative Commons Attribution-Non Commercial 4.0 International (CC BY-NC 4.0) licence (<https://creativecommons.org/licenses/by-nc/4.0/>) which permits non-commercial use, reproduction and distribution of the work without further permission provided the original work is attributed.

REFERENCES

1. **Berntorp E, Shapiro AD.** Modern haemophilia care. *Lancet* 2012;379:1447–1456.
2. **Berntorp E.** Von Willebrand disease. *Pediatr Blood Cancer* 2013;60:534–536.
3. **Leebeek FW, Eikenboom JC.** Von Willebrand's disease. *N Engl J Med* 2016;375:2067–2080.
4. **Atilla B, Güney-Deniz H.** Musculoskeletal treatment in haemophilia. *EFORT Open Rev* 2019;4:230–239.
5. **Rodríguez-Merchán EC.** The role of orthopaedic surgery in haemophilia: current rationale, indications and results. *EFORT Open Rev* 2019;4:165–173.
6. **Rodríguez-Merchán EC.** Musculo-skeletal manifestations of haemophilia. *Blood Rev* 2016;30:401–409.
7. **Heim M, Horoszowski H, Martinowitz U, Seligsohn U, Engel J.** Haemophilic hands: a three year follow-up study. *Hand* 1982;14:333–336.
8. **Pavlov H, Goldman AB, Arnold WD.** Haemophilic arthropathy in the joints of the hands and feet. *Br J Radiol* 1979;52:173–180.
9. **van Deukeren D, Mauser-Bunschoten EP, Schutgens REG, et al.** The prevalence and burden of hand and wrist bleeds in von Willebrand disease. *Haemophilia* 2019;25:e35–e38.
10. **Högh J, Ludlam CA, Macnicol MF.** Hemophilic arthropathy of the upper limb. *Clin Orthop Relat Res* 1987;218:225–231.
11. **Melchiorre D, Manetti M, Matucci-Cerinic M.** Pathophysiology of hemophilic arthropathy. *J Clin Med* 2017;6:63.
12. **Pulles AE, Mastbergen SC, Schutgens RE, Lafeber FP, van Vulpen LF.** Pathophysiology of hemophilic arthropathy and potential targets for therapy. *Pharmacol Res* 2017;115:192–199.
13. **Moreno MM, Cuesta-Barriuso R.** A history of prophylaxis in haemophilia. *Blood Coagul Fibrinolysis* 2019;30:S1–S3.
14. **Mannucci PM.** Hemophilia therapy: the future has begun. *Haematologica* 2020;105:545–553.
15. **Pasi KJ, Rangarajan S, Mitchell N, et al.** Multiyear follow-up of AAV5-hFVIII-SQ gene therapy for hemophilia A. *N Engl J Med* 2020;382:29–40.
16. **Thomas BP, Fouzia NA, Raveendran S, Pallapati SR, Abraham A, Srivastava A.** Management of hemophilic cysts and pseudotumors of the hand in bleeding disorders: a case series. *J Hand Surg Am* 2018;43:486.e1–486.e9.
17. **Bian Y, Weng XS, Zhai J.** Multiple intraosseous pseudotumors of distal radius and hands in a patient with haemophilia A: case report. *Haemophilia* 2014;20:e432–e435.
18. **Shaw JA, Wilson SC.** Multiple hemophilic bone cysts in the hand. *J Hand Surg Am* 1993;18:262–264.
19. **Rodríguez-Merchán EC.** Haemophilic cysts (pseudotumours). *Haemophilia* 2002;8:393–401.
20. **Fernandez de Valderrama JA, Matthews JM.** The haemophilic pseudotumor or haemophilic subperiosteal haematoma. *J Bone Joint Surg Br* 1965;47:256–265.
21. **Gilbert MS.** Characterizing the hemophilic pseudotumor. *Ann N Y Acad Sci* 1975;240:311–315.
22. **Pruzansky JS, Gilbert MS, Garcia RA, Gilbert RS.** Intraosseous pseudotumor of the distal radius in a patient with hemophilia: case report. *J Hand Surg Am* 2012;37:532–537.

23. Magallón M, Monteagudo J, Altisent C, et al. Hemophilic pseudotumor: multicenter experience over a 25-year period. *Am J Hematol* 1994;45:103–108.
24. Jaovisidha S, Ryu KN, Hodler J, Schweitzer ME, Sartoris DJ, Resnick D. Hemophilic pseudotumor: spectrum of MR findings. *Skeletal Radiol* 1997;26:468–474.
25. Gassel F, Kraft CN, Wallny T, Hess L, Schmitt O. Soft-tissue angioleiomyoma of the hand as a rare differential diagnosis of haemophilic pseudotumour. *Haemophilia* 2001;7:528–531.
26. Scutellari PN, Orzincolo C, Franceschini F. [The hand in hematologic diseases]. *Minerva Med* 1993;84:511–521.
27. Panotopoulos J, Ay C, Trieb K, et al. Surgical treatment of the haemophilic pseudotumour: a single centre experience. *Int Orthop* 2012;36:2157–2162.
28. Bayer WL, Shea JD, Curiel DC, Szeto IL, Lewis JH. Excision of a pseudocyst of the hand in a hemophiliac (PTC-deficiency): use of a plasma thromboplastin component concentrate. *J Bone Joint Surg Am* 1969;51:1423–1427.
29. Hopkins JD, Rayan GM. Hemophilic pseudotumor of the soft tissue of the hand: a case report. *J Okla State Med Assoc* 1999;92:227–230.
30. Chakal F, Viso R, Fernández Palazzi F. Percutaneous treatment of haemophilic digital pseudotumours. *Int Orthop* 2005;29:197–198.
31. Subasi M, Dirier A, Kapukaya A, Uludağ A, Karadayi B, Cebesoy O. Successful treatment of hemophilic hand pseudotumors by only radiotherapy. *Ann Plast Surg* 2007;59:338–340.
32. Kang JO, Cho YJ, Yoo MC, Hong SE. Hemophilic pseudotumor of the ulna treated with low dose radiation therapy: a case report. *J Korean Med Sci* 2000;15:601–603.
33. Espandar R, Heidari P, Rodriguez-Merchan EC. Management of haemophilic pseudotumours with special emphasis on radiotherapy and arterial embolization. *Haemophilia* 2009;15:448–457.
34. Xue F, Sun C, Sui T, Zhang L, Jiang L, Yang R. Hemophilic pseudotumor in chinese patients: a retrospective single-centered analysis of 14 cases. *Clin Appl Thromb Hemost* 2011;17:279–282.
35. Dumontier C, Sautet A, Man M, Bennani M, Apoil A. Entrapment and compartment syndromes of the upper limb in haemophilia. *J Hand Surg Br* 1994;19:427–429.
36. Bauman TD, Gelberman RH, Mubarak SJ, Garfin SR. The acute carpal tunnel syndrome. *Clin Orthop Relat Res* 1981;156:151–156.
37. Mayne AI, Howard A, Kent M, Banks J. Acute carpal tunnel syndrome in a patient with haemophilia. *BMJ Case Rep* 2012;2012:bcro320126152.
38. Molitor PJ, Wimperis JZ. Acute carpal tunnel syndrome in haemophiliacs. *Br J Clin Pract* 1990;44:675–676.
39. Moneim MS, Gribble TJ. Carpal tunnel syndrome in hemophilia. *J Hand Surg Am* 1984;9:580–583.
40. Rahimtoola ZO, van Baal SG. Two cases of acute carpal tunnel syndrome in classic haemophilia. *Scand J Plast Reconstr Surg Hand Surg* 2002;36:186–188.
41. Renwick SE, Moneim MS. Cubital tunnel syndrome in a child with hemophilia. *J Hand Surg Am* 1993;18:458–461.
42. Lancourt JE, Gilbert MS, Posner MA. Management of bleeding and associated complications of hemophilia in the hand and forearm. *J Bone Joint Surg Am* 1977;59:451–460.
43. Ballas KD, Rafailidis SE, Kouskouras KA, Fardellas J, Alatsakis MB, Sakadamis AK. False aneurysm of the proper palmar digital artery: report of a case. *Acta Chir Belg* 2006;106:249–251.
44. Adant JP, Grattagliano B, Fissette J. True aneurysm of digital artery in hemophilia: a case report. *Ann Chir Main Memb Super* 1994;13:278–281.
45. Khan UD, Page RE. Traumatic aneurysm of the digital artery: a diagnostic problem. *Injury* 1998;29:727–729.
46. Lokey H, Phelps DB, Boswick JA III. Traumatic false aneurysm of the hand in hemophilia. *J Trauma* 1978;18:283–284.
47. Vora S, Ibrahim T, Rajadurai VS. Radial artery pseudoaneurysm in a neonate with hemophilia A. *Indian Pediatr* 2014;51:921–923.
48. Plant MA, Scilley CG. Ulnar artery pseudoaneurysm in a patient with factor IX deficiency (hemophilia B). *Can J Plast Surg* 2007;15:223–225.
49. Yajima H, Tamai S, Ono H. Aneurysms of the digital artery: a review and report of three cases. *Microsurgery* 1995;16:566–570.
50. Erdoes LS, Brown WC. Ruptured ulnar artery pseudoaneurysm. *Ann Vasc Surg* 1995;9:394–396.
51. Ferreira V, Matos A, Rego D, et al. Percutaneous treatment pseudo-aneurism of the hand in hemophilic patient. *Rev Port Cir Cardiorac Vasc* 2017;24:178.