

OPEN

Case Report: Brown Fat Accumulation of Tc-99m Macroaggregated Albumin in a Lung Perfusion Study in a Patient With Multiple Lung Arteriovenous Malformations and Right-to-Left Shunting

Wael Marashdeh, MD and Richard L. Wahl, MD

Abstract: An 18-year-old man was preoperatively assessed for a varicocele and found to be hypoxemic. A Tc-99m macroaggregated albumin lung perfusion scan showed right-to-left shunting, evidenced by increased radiotracer uptake in the brain, kidneys, thyroid gland, and bilateral supraclavicular areas, a typical location for brown adipose tissue. Chest computerized tomography angiogram study showed supraclavicular fat density areas and multiple pulmonary arteriovenous malformations.

The authors report a rare case of brown fat visualization on a lung perfusion scan in a patient with right-to-left shunting, likely because of increased perfusion to activated brown adipose tissue.

(*Medicine* 94(42):e1820)

Abbreviations: AVM = arteriovenous malformation, BAT = brown adipose tissue, CTA = computerized tomography angiogram, FDG = flourodeoxyglucose, MAA = macroaggregated albumin, SPECT = single photon emission tomography.

INTRODUCTION

Brown adipose tissue (BAT) is type of adipose tissue that has a role in thermogenesis, especially in neonates and young children during cold exposure, by aging BAT becomes white adipose tissue; however, a lesser amount of persistent brown fat is present in adults, which also has a some role in energy metabolism, in the last decade due it to common use of F-18 fluorodeoxyglucose (FDG) BAT is commonly seen on these scans, especially in the supraclavicular, axilla, and paravertebral regions; however it can also be seen adjacent to visceral organs in the mediastinum and abdomen. In cases of cold

exposure, BAT becomes activated and ultimately becomes more apparent on F18 FDG scans.^{1,2,3,4}

METHODS

No Institutional Review Board approval was requested because such approval is not required for single case reports at the Johns-Hopkins Medical Institution. No consent was obtained because this publication contains no identifiable information.

This publication methodology included review of the electronic medical record and review of the available images for our case.

Patient Information

An 18-year-old patient was preoperatively assessed and found to be hypoxemic. The patient was investigated by a chest computerized tomography angiogram (CTA) and a Tc-99m macroaggregated albumin (MAA) lung perfusion study to evaluate for possibility of arteriovenous malformations (AVMs) within the lung.

Diagnostic Findings

The findings on an anterior perfusion view of the head and upper chest using Tc-99m MAA shows increased radiotracer uptake in the brain, thyroid, and bilateral supra-clavicular regions (Fig. 1). It has been demonstrated previously that in the presence of shunting in the lungs, a portion of the Tc-99m MAA particles bypass the lung capillary circulation and appear in the systemic circulation.^{5,6,7,8}

The uptake in the supra-clavicular region is presumed to be brown fat because of its location and anatomic correlation with the expected location of BAT.^{9,10}

A chest CTA image shows an AVM in the right lower lobe (Fig. 2). Other axial slices showed multiple AVMs. The multiplicity of these lesions suggested a diagnosis of hereditary hemorrhagic telangiectasia, which was subsequently treated successfully by vascular embolization, which improved the patient's hypoxemia.^{11,12}

A coronal chest CTA image shows structures that have fat density in the supraclavicular regions as shown in (Figure 3); these areas of well-perfused fat correspond to the areas of Tc-99m MAA accumulation seen on the perfusion scan and likely represent areas of BAT perfusion because of brown fat activation.

DISCUSSION

Brown adipose tissue uptake has been demonstrated previously with multiple radiotracers, such as Tl-201 chloride, I-123 metaiodobenzylguanidine, Tc-99m sestamib, F-18 and H-3 FDG, H-3 L-methionine, and H-3 thymidine. The regions of

Editor: Dwight Achong.

Received: August 16, 2015; revised: September 20, 2015; accepted: September 22, 2015.

From the Department of Radiology and Radiological Science, Division of Nuclear Medicine, Russell H. Morgan, Johns-Hopkins University School of Medicine, Baltimore, MD (WM), and the Mallinckrodt Institute of Radiology, Washington University in St. Louis School Of Medicine, St. Louis, MO (RLW).

Correspondence: Wael Marashdeh, MD, Russell H. Morgan Department of Radiology and Radiological Science, Division of Nuclear Medicine, Johns-Hopkins University School of Medicine, 601 N. Caroline Street suite 3223, Baltimore, MA 21287 (e-mail: wmarash1@jhmi.edu).

The authors have no conflicts of interest to disclose.

Copyright © 2015 Wolters Kluwer Health, Inc. All rights reserved.

This is an open access article distributed under the Creative Commons Attribution-NonCommercial-NoDerivatives License 4.0, where it is permissible to download, share and reproduce the work in any medium, provided it is properly cited. The work cannot be changed in any way or used commercially.

ISSN: 0025-7974

DOI: 10.1097/MD.0000000000001820

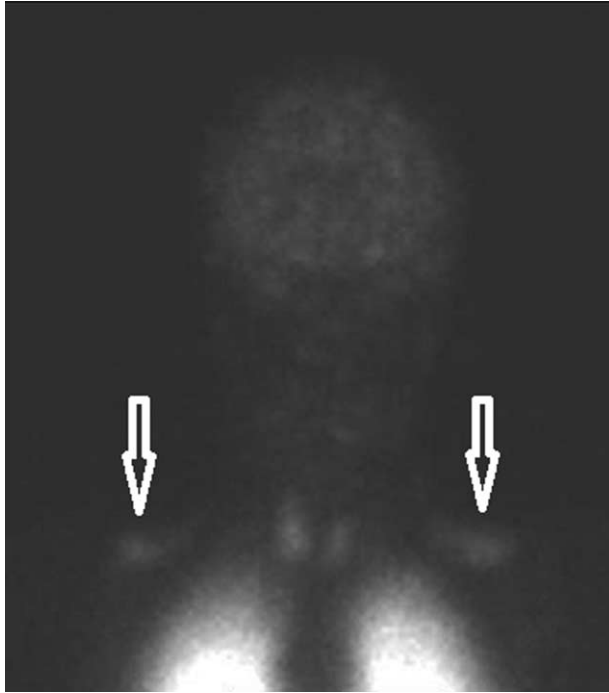

FIGURE 1. This is a perfusion scan using Tc-99 macroaggregated albumin of the head and upper chest showing uptake in the brain, thyroid gland, and bilateral supraclavicular regions (arrows).

BAT uptake in these radiotracers are usually the supraclavicular and paravertebral adipose tissues^{13,14}. The available images we have, however, show only Tc-99m MAA accumulation in the supraclavicular adipose tissue with no definite evidence of accumulation in the paravertebral adipose tissues, which if present may be obscured by the lung activity.

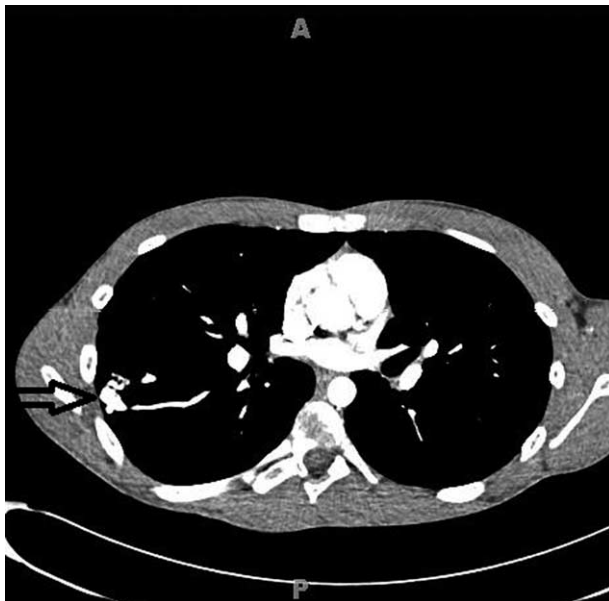


FIGURE 2. This is a representative slice of a chest computerized tomography angiogram showing one of the multiple arteriovenous malformations (arrow) detected on the study.

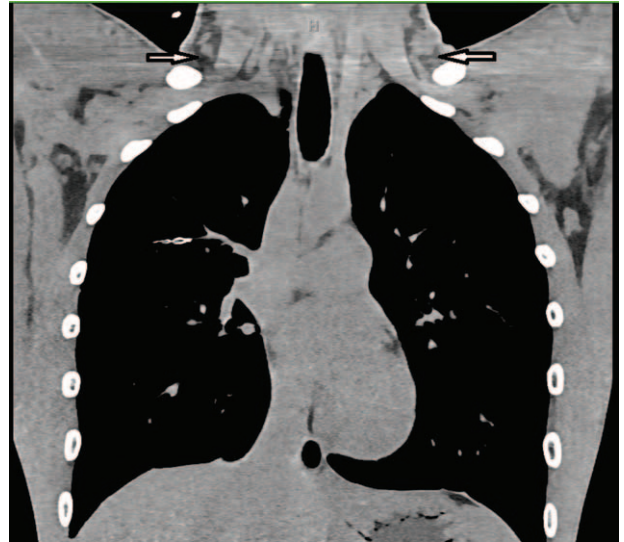


FIGURE 3. This is a coronal image of a chest computerized tomography angiogram showing fat tissue in the supraclavicular regions bilaterally (arrows).

Although we do not have a single-photon emission computed tomography image to show the accumulation of Tc-99m MAA in the supraclavicular brown fat, it can be considered that the supraclavicular region of uptake on the perfusion images is a site of brown fat accumulation of Tc-99m MAA because of the typical location and the presence of fat tissue in the supraclavicular region as shown on the chest CTA coronal image provided.

The presence of intrapulmonary shunting causing uptake in highly perfused organs including activated brown fat may be an important factor that allowed visualization of the activated brown fat in the supraclavicular regions in this patient. Given the fact that the examination was performed in a summer month (August) and although we do not have information regarding the environment surrounding the patient during the examination day, we believe the brown fat uptake is attributed to the presence of metabolically active brown fat with increased vascularity, which is mainly because of young age (18 years old) with the possibility of being because of a surrounding cold environment less likely.

Although the shunt fraction should have been estimated for this study, it was not calculated because the clinical concern was to evaluate for the presence of pulmonary embolism and the images were sufficient to suggest the diagnosis of intrapulmonary shunting.

We report a rare case of Tc-99m MAA accumulation in BAT in the supraclavicular region, which will help resolve diagnostic dilemma's in the future if a similar case is encountered.

REFERENCES

1. Sacks H, Symonds ME. Anatomical locations of human brown adipose tissue: functional relevance and implications in obesity and type 2 diabetes. *Diabetes*. 2013;62:1783–1790.
2. Poekes L, Lanthier N, Leclecrcq IA. Brown adipose tissue: a potential target in the fight against obesity and the metabolic syndrome. *Clin Sci*. 2015;129:933–949.

3. Hong TS, Shamma A, Charron M, et al. Brown adipose tissue 18F-FDG uptake in pediatric PET/CT imaging. *Pediatr Radiol*. 2011;41:759–768.
4. Chen KY, Brychta RJ, Linderman JD, et al. Brown fat activation mediates cold-induced thermogenesis in adult humans in response to a mild decrease in ambient temperature. *J Clin Endocrinol Metab*. 2013;98:1218–1223.
5. Lu G, Shih WJ, Chou C, et al. Tc-99m MAA total-body imaging to detect intrapulmonary right-to-left shunts and to evaluate the therapeutic effect in pulmonary arteriovenous shunts. *Clin Nucl Med*. 1996;21:197–202.
6. Palevsky HI, Alavi A. Ventilation perfusion lung scanning in the evaluation of right-to-left shunting. *J Nucl Med*. 1992;33:2036–2039.
7. Salimi Z, Thomasson J, Vas W, et al. Detection of right-to-left shunt with radionuclide angiography in refractory hypoxemia. *Chest*. 1985;88:784–786.
8. Dolezal J. The scintigraphic 99mTc-MAA imaging quantification of the right-to-left shunt in a patients with multiple pulmonary arteriovenous malformation and familial teleangiectasis. *Vnitř Lek*. 2008;54:206–209.
9. Hany TF, Gharehpapagh E, Kamel EM, et al. Brown adipose tissue: a factor to consider in symmetrical tracer uptake in the neck and upper chest region. *Eur J Nucl Med Mol Imaging*. 2002;29:1393–1398.
10. Cohade C, Osman M, Pannu HK, et al. Uptake in supraclavicular area fat (“USA-Fat”): description on 18F-FDG PET/CT. *J Nucl Med*. 2003;44:170–176.
11. Lacombe P, Lacout A, Marcy PY, et al. Diagnosis and treatment of pulmonary arteriovenousmalformations in hereditary hemorrhagic telangiectasia: an overview. *Diagn Interv Imaging*. 2013;94:835–848.
12. Cottin V, Dupuis-Girod S, Cordier JF, et al. Pulmonary vascular manifestations of hereditary hemorrhagic telangiectasia (rendu-osler disease). *Respiration*. 2007;74:361–378.
13. Fukuchi K, Tatsumi M, Ishida Y, et al. Radionuclide imaging metabolic activity of brown adipose tissue in a patient with pheochromocytoma. *Exp Clin Endocrinol Diabetes*. 2004;112: 601–603.
14. Baba S, Engles JM, Huso DL, et al. Comparison of uptake of multiple clinical radiotracers into brown adipose tissue under cold-stimulated and nonstimulated conditions. *J Nucl Med*. 2007;48:1715–1723.