

REVIEW ARTICLE

Hip Arthroscopy for Femoracetabular Impingement in China: A Review and Meta-Analysis

Hsueh Yang, PhD¹, Mingke You, MS², Ya Li, BS², Tao Li, MD¹, Taolin Qin, BS², Gang Chen, PhD¹

Department of ¹Sport Medicine and ²Clinical Medicine, West China Hospital of Sichuan University, Chengdu, China

Objective: To explore the development of hip arthroscopy in China through reviewing the change of the application of hip arthroscopy operation on treating femoracetabular impingement (FAI).

Method: Papers were retrieved from January 1, 2005 to November 1, 2019, from databases CNKI, Wanfang Data, VIP, PubMed, and Embase. The keywords are Hip Impingement, Femoroacetabular impingement, Hip arthroscopy, Arthroscopic operation, Hip Arthroscopy operation, and Arthroscope, etc. The quality of papers was assessed through MINORS, and statistics and meta-analysis were performed by Word, Excel, and Revman 5.3 Zurich, Switzerland.

Results: From a total of 8,953 papers, 46 review articles without data and 48 articles with data were involved, and 25 papers were included in the Meta-analysis. The twenty-five papers were selected from 48 papers with data, of which 41 were reported in Chinese, 11 were missing complete Harris scores, five did not mention the number of patients who had lost follow-up, three had minors quality scores below 7, one did not have enough FAI cases, and three did not have standard deviations in Harris scores. Overall, in China, the application of hip arthroscopy regarding FAI has flourished while maintaining a high level of treatment and has reached its peak in the past 2 years.

Conclusion: With the rapid development of hip arthroscopy in China, hip operation is widely recognized, many reports on its application on FAI have emerged successively, and the scope of application and technical level have been improved.

Key words: Arthroscope; Arthroscopy; Articular impingement; Femoracetabular impingement; Hip

Introduction

Repeated impacts of the proximal end of the femoral neck on the acetabular lip and its adjacent cartilage are important causes of adult hip pain and limited movement due to the abnormal morphology and structure of the femur and acetabulum. This type of impact phenomenon is known as femoracetabular impingement (FAI)¹. The hip stability depends upon the complex structure of bone, restraint of the capsule and cartilage between the acetabulum and proximal femur^{2,3}. Among them, the joint capsule is comprising of ischiofemoral ligaments, iliofemoral, iliocapsularis, and zona orbicularis, which is an important factor for the natural joint stability, guaranteeing the stability of the dynamic and static motion of the joint and bone around the hip joint⁴.

FAI treatment mainly includes surgical and non-surgical options. The use of open suture capsulorrhaphy for instability of the hip has been reported from many years. The primary goal of hip surgeons in open FAI surgery is to restore normal hip morphology as well as the physiological "sealing mechanism" of the acetabular labrum⁵. Given the deeper position of human body in arthroscopic techniques, the pathology and anatomy are disturbed, leading to a backward development of hip arthroscopy than other arthroscopic techniques⁵. Currently, arthroscopic surgery has become the best treatment option for the management of FAI. However, arthroscopic therapy for FAI gained less importance on the restoration of capsule surgery⁶. The first step is to establish a mid-anterior and anterolateral portal using a safe access approach. Moreover, the important step

Address for correspondence Gang Chen, Postal: No. 363 Furong Road, Yongning Street, Wenjiang District, Chengdu; Tel/Fax: 028-85582944; E-mail: drchengang@hotmail.com

Hsueh Yang and Mingke You contributed as first author

Received 15 January 2021; accepted 17 May 2021

in this process is the incision of the joint capsule. Most surgeons extend capsulotomies to get a better view under the arthroscope.

Various studies have proposed that routine capsular closure should be performed at the end of hip arthroscopy cases⁷. In 1931, hip arthroscopy was initially introduced by Burman, while China under a systematic review by Liu and Xiang in 2005 was found to be 20 years behind the fast growth of hip arthroscopy internationally. Among all hip injuries usually, FAI was always the major and comprehensive application of hip arthroscopy surgery and achieved significant status⁸. However, limited information is available on the applications and development of hip arthroscopy in FAI in China. The aim of the present study is to give an overview on: (i) applications and therapeutic effect of FAI surgery; and (ii) the history of hip arthroscopy in China deduced from their applications.

Methods

Search Strategy

In accordance with the research aim, PubMed, Embase, CNKI (China National Knowledge Infrastructure), Wanfang Data and VIP, were used to retrieve articles from 1 January 2005 and 1 November 2019. The medical subject headings and keywords included: (“femoroacetabular impingement” OR “impingements, femoroacetabular” OR “femoroacetabular impingement syndrome”) AND (“arthroscopy” OR “arthroscopic surgical procedures” OR “arthroscopic surgery” OR “surgeries, arthroscopic”).

Inclusion Criteria

Inclusion criteria: (i) FAI was definitely diagnosed, age and gender were not limited, post-operation follow-up for no less than 1 year; (ii) all the reported patients underwent hip arthroscopic surgery; (iii) at least one of the following outcomes was reported; and (iv) study type: randomized controlled trials (RCTs) and non-randomized controlled trials (nRCTs).

Exclusion Criteria

Exclusion criteria: (i) duplicate reports, only abstracts, reviews, clinical practice guidelines, non-comparative studies; (ii) case reports; and (iii) studies from non-Chinese authors.

Document Retrieval

Using author name, year of publication, titles, age, gender, study design, sample size, duration of follow-up, and outcome parameters, articles were included or excluded by three separate investigators (HY, TL, YX), and at the end of the search, data were shared and divergences were solved through discussion by the three.

Data Extraction

All the divergences had been solved by discussions and the data extraction table had been designed before starting to

draft the article. The information extracted from all primary research including contents of author, article types, publishing time, numbers of patients, follow-up periods, clinical results (pre and postoperative). Specifically, all papers met the first three criteria, while due to different article types, only literature with data were counted in the other indexes by discussion.

Quality Assessment

The same three researchers independently make the quality assessment by Review manager 5.3 Zurich, Switzerland for RCT by the Physiotherapy Evidence Database (PEDro) scale. And use the methodological index for non-randomized studies (MINORS) for prospective and retrospective controlled trials. For the RCT studies, each receives 2 points for low risk, 1 point for high risk and 0 points for unclear risk. A trial with a score of more than 7 was considered to be the high-quality study. For the prospective and retrospective controlled trials, 12 items received 2 points for each one and if the study reports the item, it will receive 2 points, if the message is not intact it will get 1 and if the study said nothing then it will be 0. Fourteen points will be a golden line.

Outcomes

The following outcomes were extracted from the included studies: (i) curative effect; (ii) equipment used; (iii) revisions number; (iv) Harris Hip Score (mHHS); (v) change in time.

Statistical Analysis

Review Manager (RevMan 5.3 software: Zurich, Switzerland) was used to conduct meta-analysis with a Mantel Haenszel random effects models. Mean and standard deviation (SD) was used for each outcome measure in meta-analysis. 95% CI, mean difference and standard mean difference (SMD) were also calculated. The chi-square test with $N - 1$ degrees of freedom and significance of 0.05 was used to calculate statistical heterogeneity. Inconsistency (I^2) was used to calculate the percentage variability in the effect estimates according to heterogeneity: $I^2 = ((Q - df)/Q) \times 100\%$, where Q is the χ^2 statistic and df is degrees of freedom. I^2 values of 25%, 50%, and 75% were considered as low, medium, and high heterogeneity, respectively. The fixed-effects model was used where $I^2 < 50\%$; otherwise, the random-effects model was used. The Grading of Recommendations Assessment, Development, and Evaluation (GRADE) approach was applied to each analysis performed to determine the quality of the evidence.

Results

Searching Results

From a total of 8953 articles, 46 review articles without data and 48 articles with data were involved. According to statistics, 25 were included screening from the total 48 data papers (41 in Chinese, 7 in English) with exclusion criteria as follows: 11 articles without Harris score pre and/or post

operation, 5 haven't mentioned the loss of follow-up, 1 that lacked of FAI cases, 3 without standard deviation in Harris score, 3 had a quality score less than 7 (Appendix 1). There are not enough FAI cases in the article and three do not have standard deviation of Harris score. Generally, in China, application of hip arthroscopy on FAI is increasing, while maintaining the treatment level is required and the speed of development has increased within 2 recent years.

Preoperative and Postoperative Outcomes of Hip Arthroscopy Surgery

Articles of the pre and postoperative results of hip arthroscopy in FAI treatment in China have grown rapidly to support the application of arthroscopic techniques since 2010, especially under a smaller scale of acetabulum lesion (Table 1). Pre and post operation nursing has only been mentioned in five articles (in 2009, 2013, 2017, 2018 respectively), which leaves a big gap in this area.

Group Comparison by Year

The study presents comparisons of article types, the sum of variation trend, changes in therapeutic effects, which were analyzed by three subgroups based on years: (i) 5 years ago (2005–2014); (ii) five to two years ago (2015–2017); (iii) 2 years (2018–2019). It is obvious that, the proportion of articles with data has increased over the years, with systematic reviews decreasing, which reflected that Chinese experts had gained confidence about arthroscopic surgery and applications of hip arthroscopy increased in China. With the rapid development of hip arthroscopy in China in recent years and the popularization of equipment and technology, physicians have had more opportunities to perform hip

arthroscopy, and much data and literature have been published (Fig. 1).

Unlike 2011 with a transient pop, English articles of hip arthroscopy in FAI treatment in China had been published successively on PubMed since 2015, meaning more influence and feedback internationally of hip arthroscopy in treating FAI. Furthermore, from then on, studies about hip arthroscopy in FAI treatment domestically, increased progressively, especially in the past 2 years, which further reflects the irreversible and swift development of hip arthroscopic technique in China (Fig. 2).

Quality Score

Twenty-five were finally included screened from the total 48 data papers (41 in Chinese, seven in English) with exclusion criteria as follows. Eleven articles without Harris score pre and/or post operation (Chen, 2010; Zhang, 2010; Chen, 2013; Ou, 2014; Chen, 2014; Gao, 2017; Dai, 2018; Yang, 2019; Shen, 2019; Kai, 2018; Zhu, 2019), five did not mention the loss of follow-up (Zhang, 2018; Luo2018, Hao, 2019; Chen, 2019; Hao, 2019), three were eliminated by a quality score below 7 (Zhao, 2016; Ren, 2017; Xie, 2018), one that lacked any FAI cases (Sun, 2011), three without standard deviation in the Harris score (Chen, 2009; Wei, 2009; Gao, 2019). In order to facilitate data processing, we have translated all Chinese and English literature author names into English in the Table 2. Two data papers were published by Zhang in 2008, and one was removed. Two data papers were published by Gao in 2019, and lack of standard deviation of Harris scores in one subgroup was found in one article, therefore, it was removed to avoid bias. The article by Chen

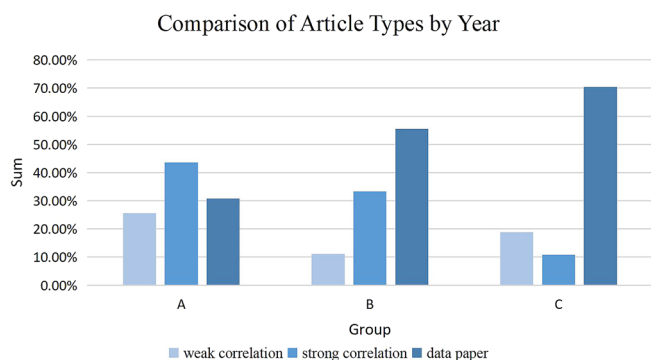


Fig 1 The graph showed the comparison of article types by year. Weak correlation, strong correlation and data by years were also presented. A, 5 years ago (2005–2014); B, five to two years ago (2015–2017); C, 2 years (2018–2019). Weak correlation: FAI is mentioned in these reviews or proceeding papers, most of which are reviews. Strong correlation: FAI take important position in these reviews or proceeding papers, most of which are reviews. Data paper: articles include operative monitoring with patients' data.

TABLE 1 Article type and number of hip arthroscopy in China (involving FAI) by year

Year	Weak correlation	Strong correlation	Data paper	Sum
2005	1	-	-	1
2006	-	1	-	1
2007	-	1	-	1
2008	-	2	-	2
2009	1	2	2	5
2010	1	6	2	9
2011	2	3	1	6
2012	2	1	1	4
2013	2	-	2	4
2014	1	1	4	6
2015	-	-	4	4
2016	1	4	1	6
2017	1	2	5	8
2018	5	1	11	17
2019	2	3	15	20

Note: Weak correlation: FAI is mentioned in these reviews or proceeding papers, most of which are reviews. Strong correlation: FAI take important position in these reviews or proceeding papers, most of which are reviews. Data paper: articles include operative monitoring with patients' data.

in 2019 used grouping by sutured or unsutured and was removed to avoid bias, since the loss of follow-up was mentioned in the suture group while not given in the unsutured group. The quality scores of included articles are presented in Table 2.

Meta-analysis

Curative Effect

Curative effect was determined in preoperation and post-operation surgery based on three different subgroups: (i) 5 years ago (2005–2014); (ii) five to two years ago (2015–2017); and (iii) recent 2 years (2018–2019) (Fig. 3). In group 1 (MD = 34.82, 95% CI, 26.98,42.74, $I^2 = 97%$, $P < 0.00001$), in group 2 (MD = 30.46, 95% CI, 26.33, 34.59, $I^2 = 88%$, $P < 0.00001$), and in group 3 (MD = 26.21, 95% CI, 22.71,29.71, $I^2 = 96%$, $P < 0.00001$).

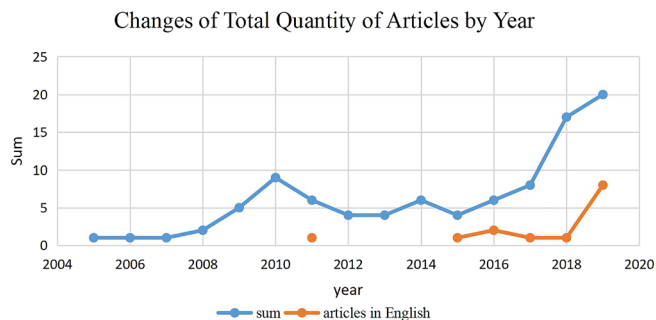


Fig 2 The graph showed change in article quantity by year.

Harris-Hip Score in Time Change

The absolute value of average change decreased gradually in numeral value: 2005–2014: 34.82 [26.89, 42.74], 2015–2017: 30.46 [26.33, 34.59], and 2018–2019: 26.21 [22.71, 29.71] (Table 3). In fact, the post Harris average score did not decrease gradually, with the main factor of higher Pre-Harris average score contributing to the reduced difference in China. Combined with the quantity of participants reported, in the past 2 years, the quantity of patients with FAI treated with arthroscopy was even larger than group 1 and 2 in sum, though some patients were not recorded after diagnosis.

Discussion

FAI commonly occurs due to the abnormality of the acetabulum or proximal femoral or with a combined morphological abnormality, resulting in bridging impingement between the proximal femur and the edge of acetabulum. Repetitive mechanical contacts are common during sports activities, especially in joint flexion and internal rotation, which may cause acetabular lesions and possibly spread to acetabular cartilage injury. Clinical evidence has shown that FAI is considered a pathological factor contributing to early osteochondritis². Until 2006, however, most Chinese experts believed that hip arthroscopy could not achieve the intended effect in treating FAI⁴. In 2008, a retrospective study conducted by Espinosa and Murphy^{6,7}, held a positive attitude toward the early effect on hip arthroscopy in treating FAI⁸. Meanwhile, therapeutic posture extended from lateral position to supine position, through various approaches, including anterolateral, anterior and distal lateral approach⁹.

TABLE 2 Quality score for 25 articles included (MINORS score)													
Title	1	2	3	4	5	6	7	8	9	10	11	12	Minor's score
Wu et al. 2021 ¹⁹	2	2	0	2	0	2	2	0	0	0	0	0	10
Zhou et al.2013 ³⁹	2	1	0	2	0	2	2	0	0	0	0	0	9
Li et al. 2014 ²⁴	2	1	0	2	0	2	0	0	0	0	0	0	7
Li et al. 2014 ⁴⁰	2	1	0	2	0	2	2	0	0	0	0	0	9
Sun et al. 2015 ²⁵	2	2	2	2	0	2	2	0	0	0	0	0	12
Yao et al. 2015 ²⁸	2	1	2	2	0	2	2	0	0	0	0	0	11
Wang et al. 2015 ²⁶	2	1	0	2	0	2	2	0	0	0	0	0	9
Hong et al. 2015 ²⁷	2	2	2	2	0	2	2	0	0	0	0	0	12
Deng et al. 2017 ¹⁰	2	2	2	2	0	2	2	0	0	0	0	0	12
You et al. 2017 ⁴¹	2	1	1	2	0	2	2	0	2	2	2	2	18
Zhuang et al. 2017 ³⁷	2	1	0	2	0	2	2	0	0	0	0	0	9
Xu et al. 2018 ⁴²	2	1	2	2	0	2	2	0	0	0	0	0	11
Zhang et al. 2018 ⁴³	2	1	0	2	0	2	2	0	0	0	0	0	9
Chen et al. 2018 ⁴⁴	2	1	0	2	0	2	2	0	0	0	0	0	9
Min et al. 2018 ⁴⁵	2	2	0	2	0	2	2	0	0	0	0	0	10
Li et al. 2018 ⁴⁶	2	1	0	2	0	2	2	0	0	0	0	0	9
Li et al. 2018 ⁴⁷	2	2	0	2	1	2	2	0	0	0	0	0	11
Pan et al. 2019 ⁴⁸	2	2	2	2	0	2	2	0	1	2	2	2	19
Huang et al. 2019 ⁴⁹	2	1	0	2	0	2	0	0	0	0	0	0	7
Ni et al. 2019 ⁵⁰	2	2	0	2	0	2	2	0	0	0	0	0	10
Wang et al. 2019 ⁵¹	2	2	0	2	0	0	2	0	0	0	0	0	8
Shen et al. 2019 ⁵²	2	1	0	2	0	2	2	0	0	0	0	0	9
Zhuo et al. 2019 ⁵³	2	2	0	2	0	1	2	0	1	2	1	2	15
Wu et al. 2019 ⁵⁴	2	2	0	2	0	2	0	0	0	0	0	0	8
Gao et al. 2019 ⁵⁵	2	1	0	2	0	2	1	0	0	0	0	0	8

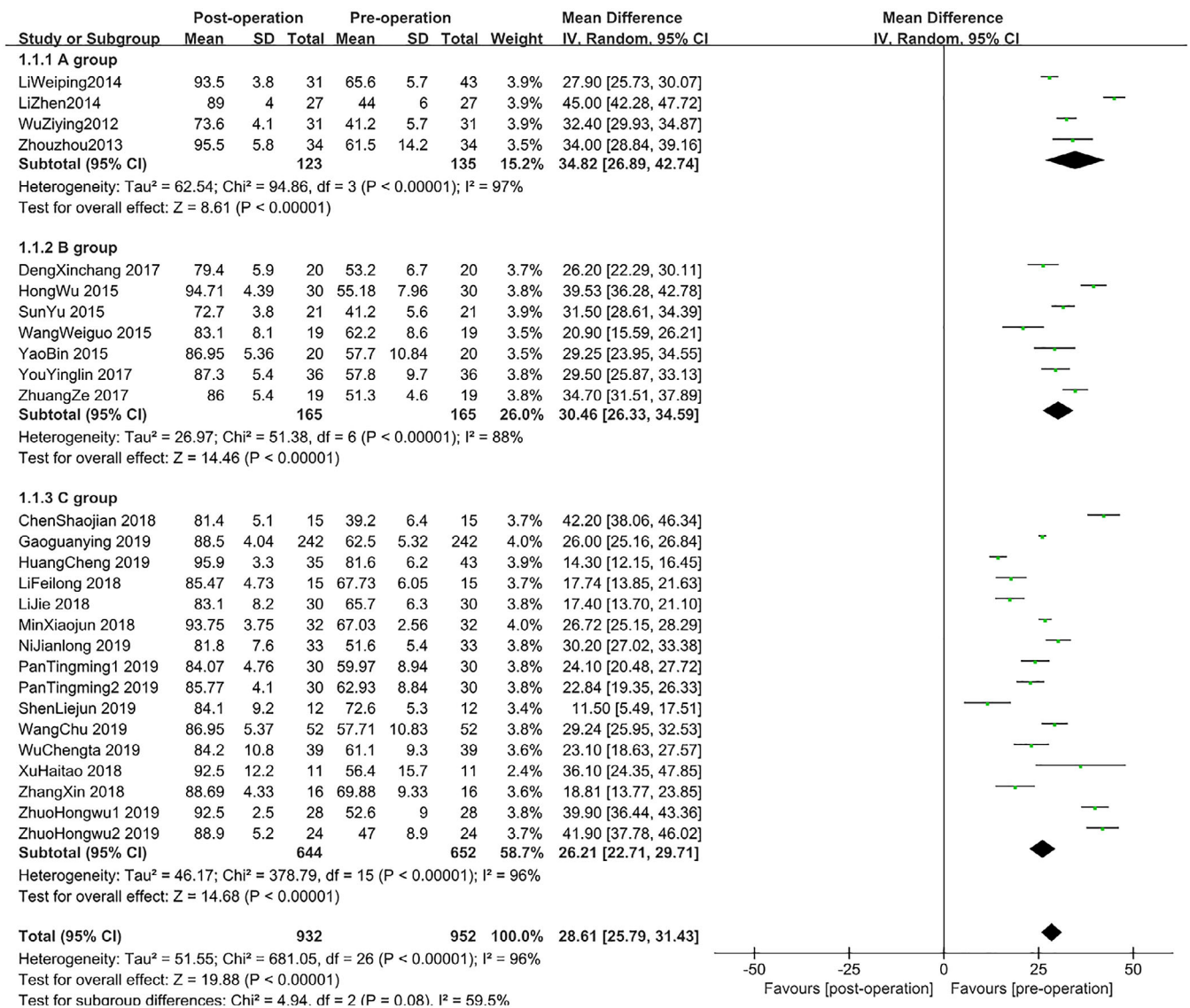


Fig 3 Forest plot of curative effect in three different subgroups. 1) five years ago (2005–2014), 2) five to two years ago (2015–2017), 3) recent two years (2018–2019).

Practically, FAI has been identified as two types: cam and pincer³. Cam type usually be seen in young male athletes, while pincer type mostly happens in busy middle-aged women⁴. The primary purpose of FAI is to widen the range of movement of the hip joint, together with relieving the bridging impingement between femoral head and the edge of acetabulum. Traditional treatment includes the femoral arthroplasty of FAI, which has been hardly used owing to a consequence of larger trauma size. Around 2005, hip arthroscopic surgery under direct vision had been carried out with arthroscopy¹. In 2001, Ganz had reported specifically on arthroscopic surgery treatment in FAI⁵. In brief, patient was placed at lateral position, the doctor enters the hip joint by the greater trochanteric approach and performs anterior

dislocation by instruments, the integrity of external rotation muscles (including piriformis) are protected during surgery in order to ensure the blood-supply of the femoral head. Then, the capsule incision in “Z” shape was centered to obtain adequate exposure for detailed examination.

Non-spherical parts include part of the femoral head were removed during surgery, and the remaining part was sutured to the edge. Simultaneously, some osteophytes needed to be excised in the outer proportion of femoral head, improving the line of force within the femoral head and femoral neck. After accomplishing the FAI osteoplasty, hip reduction and examination of whether impingement existed during the range of motion was performed. If there was still impingement during examination, a re-resection can

TABLE 3 Change in Harris score by year

Groups	Pre Harris average*	Change in Harris score	Post Harris average†
2005–2014	54.64	34.82 [26.89,42.74]	88.04
2015–2017	54.40	30.46 [26.33,34.59]	85.16
2018–2019	61.87	26.21 [22.71,29.71]	87.79

* Formula of Pre-Harris average: (sum of individual event Pre-Harris average score × sum of individual event number of participants) / sum of pre-operative participants.; † Formula of post Harris average: (sum of individual event post Harris average score × sum of individual event number of participants) / sum of participants with follow-up.

be conducted. Also, anterior trochanteric osteotomy, femoral neck osteotomy or intertrochanteric osteotomy can be conducted to improve osteophyte clearance and alleviate the impingement.

In 2009, “treatment of CAM-type of caput femoris FAI through femoral head and neck osteotomy under arthroscopy” (gist: femoral head and neck plasty under arthroscopy in treating cam type FAI) by Chen *et al.*¹⁰ came out, which was also considered the first essay of hip arthroscopy in treating FAI, together with another essay “Rehabilitation nursing of 16 patients with FIA treated under arthroscopy” (gist: the rehabilitation nursing after arthroscopy in treating FAI for 16 cases) by Wei *et al.*¹¹ simultaneously, regarding as the initial article in the FAI postoperative nursing process among the related articles retrieved. Therefore, the nursing process of hip arthroscopy in treating FAI in China was still under severe shortage both in time and quantity. In addition, Chinese experts prefer to cite an article by Larson *et al.*¹² in arthroscopic technique of FAI treatment since 2009, as well as articles from Ilizaliturri *et al.* and Mardones *et al.*^{13,14}. Under these circumstances, labeloplasty and early excision were not considered significant differences in early effects. However, in consideration of the importance of acetabulum structure, labeloplasty was still recommended during that period¹⁵.

In 2011, supportive evidence of early and mid-term result of hip arthroscopy further increased, which proved hip arthroscopy have the features of small wound and speedy recovery, affirming the effectiveness of the application to make diagnosis and treatment of FAI. While promoting hip arthroscopy in FAI treatment, techniques were highly required, and long-term clinical results were expected to be achieved.¹⁶ Noticeably, clinical application progress of hip arthroscopy by Jian *et al.*¹⁷, became the initial article, including the arthroscopy treatment of FAI from China published in PubMed, which was a systematic review of the clinical application progression of hip arthroscopic techniques.

In 2012, it was first proposed that hip arthroscopy in FAI treatment may cause heterotopic ossification around the hip joint, whereas non-steroidal anti-inflammatory drugs (NSAIDs) could effectively prevent this complication¹⁸, indicating that with the growing application of hip arthroscopy, Chinese experts raised thorough concerns about the

prognosis and other indexes (for example: hip flexion 40° in surgery). More specific indexes were found in postoperative rehabilitation of hip arthroscopy in FAI treatment in 2012¹⁹. However, due to the late start in the technique, the lack of surgical supplies including arthroscope, arthroscopic equipment and traction frames limited the further promotion of the treatment.

In 2013, with the cultivation of clinical experience and technical training, the numbers of applications of arthroscopy in treating FAI increased gradually, making this treatment attract wide attention and illustrate a good prospect, compared with open surgery that may cause more injury and influence the blood supply²⁰. Yet because of the need of precise diagnosis of the junction of femoral head and neck, avoiding overcorrection or undercorrection that led to complication or unsatisfied improvement, like the overcorrection may result in acetabulum deformation, some experts held a suspicious attitude towards the procedure²¹.

In 2014, it had covered the mostly recorded proceeding papers (three proceeding papers) during article retrieving^{22,23}, and many had reported on the postoperative clinical data, which meant in 2014, the attention of experts on hip arthroscopy in FAI treatment had increased and received primary clinical results. In 2015, articles about hip arthroscopy in FAI treatment were successively published, most of the patients had cam malformation, and were all exhibiting better overall outcomes^{24–27}. The functional recovery can be achieved gradually 1 year after surgery, and the 2-year follow-up indicated that it had sustained the therapeutic outcomes²⁸. However, there was still a deficiency in quantity of articles relating to hip arthroscopy in treatment of FAI.

In 2016, with the improvement of surgical techniques and specific equipment, together with the contemporary concept of minimally invasive and rapid recovery, hip arthroscopy became one of the primary treatments of FAI²⁹. On the other hand, the deficiency had been further recognized. First, hip arthroscopy possessed its own indications that cannot replace other forms of surgery (e.g., treatment of hip dysplasia, severe protrusion acetabuli, giant cartilage damage and giant joint hypokinesia)^{30–31}. Second, most of the literature results were small sample retrospective study types, and lacked prospective randomized controlled trials of different types of surgery in treating FAI³². Third, early treatment

mainly focused on the acetabulum lesion while potential original focal may be neglected³³. Furthermore, whether youngsters with asymptomatic FAI should be under prophylactic surgery was still controversial³⁴.

In 2017, the Chinese literature on hip arthroscopy for FAI maintained a steady yield. In the past, surgical hip dislocation (SHD) was considered the golden rule for treating FAI, but as hip arthroscopy matured, SHD was limited to deal with patients with severe abnormality structures³⁵. Also due to the limitations of arthroscopy, some patients (including deep acetabulum, acetabular protrusion, acetabular hypokinesia and obese patients) are more suitable for open surgery³⁶. Postoperative imaging and clinical effects had been observed to indicate fewer complications in arthroscopic technique in treating FAI compared with traditional open surgery³⁷.

In 2018, the numbers of the Chinese relative literatures were twice as many as that in 2017, and the first restudy essay of hip arthroscopic surgery was published¹¹, illustrating a more comprehensive development of hip arthroscopy, both in application of primary outcomes and study of re-surgery. In 2019, there was a further improvement of article quantity, and the initial articles of meta-analysis of hip arthroscopy in treating FAI was published³⁸. This illustrated the gradual perfecting of the application of hip arthroscopy in FAI treatment, but also demonstrated a trend that hip arthroscopy has been widely accepted and generally recognized as a stable and effective surgical technique by Chinese experts, which has made the further development of hip arthroscopy more anticipated.

Meta-analysis was performed to determine the curative effects in pre-operation and post-operation surgery based on three different subgroups. It showed that the equipment and facility of arthroscopy in treating FAI was more widespread, and more hospitals were able to conduct arthroscopic

surgery. Second, the cognition and acceptance of hip arthroscopy by doctors reached a peak level, leading to that more arthroscopic surgeries willing to be performed.

The Harris Hip score was also measured. Absolute value of average change decreased gradually in numeral value: group 1 34.82 [26.89, 42.74], group 2 30.46 [26.33, 34.59], group 3 26.21 [22.71, 29.71]. a higher pre-Harris average score may indicate wider preoperative requirements, a greater acceptance of patients towards hip arthroscopy and a potential trend that hip arthroscopy was chosen before deterioration. In general, hip arthroscopy for FAI in China has been booming in recent years while maintaining a high level of treatment, and has reached a peak in the last 2 years.

Limitations

This study has some limitations, including: (i) the number of articles included is limited; (ii) the quality of the included literature is generally not high, and the risks of methodological quality assessment are mostly unclear, which may have a certain impact on the research results of this systematic review; and (iii) some small journals may not be brought into these databases include PubMed, Embase, CNKI, VIP, Wanfang database, and thus have not been collected.

Conclusion

With the rapid development of hip arthroscopy in China, hip operation is widely recognized, more and more reports on its application on FAI have emerged successively, and the scope of application and technical level have been improved.

Conflict of Interest

The authors declares that they have no conflict of interest.

References

- Liu Y, Xiang Y. Progress in hip arthroscopic surgery. *Orthoped J China*, 2005, 21: 61–63.
- Wylie JD, Kim YJ. The natural history of femoroacetabular impingement. *J Pediatr Orthop*, 2019, 39: S28–S32.
- Pun S, Kumar D, Lane NE. Femoroacetabular impingement. *Arthritis Rheumatol*, 2015, 67: 17–27.
- Wang ZJ, Zhang CQ, Yang B, et al. Femoral Acetabular Impingement Syndrome. *Chinese J Postgrad Med*, 2006, 15: 74–76.
- Lin CM, Hu CM, Gu GS, et al. Femoral Acetabular Impingement Syndrome. *Orthop J China*, 2008, 7: 522–526.
- Espinosa N, Beck M, Rothenfluh DA, et al. Treatment of femoroacetabular impingement: preliminary results of labral refixation. *Surgical technique. J Bone Joint Surg Am*, 2007, 89: 36–53.
- Chen BC. Diagnosis and treatment of acetabular labrum injury by hip arthroscopy. Symposium of the 3rd International Congress of Chinese Orthopaedic Association. Suzhou, 2008; 140–142.
- Chen JW, Chen SY, Wu ZY, et al. Arthroscopic femoral head and neck arthroplasty for treatment of cam-type femoroacetabular impingement. *Proceedings of the 2009 Chinese Academic Conference on Sports Medicine and Arthroscopic Surgery. Qingdao 2009*; 194–212.
- Wei YH, Zhang J, Zhang J. Rehabilitation nursing care of 16 patients with Femoroacetabular Impingement treated under arthroscopy. *Chin J Nurs*, 2009, 44: 1073–1075.
- Deng XC, Wang C, Liang X, et al. Clinical observation on treatment of cam-type femoroacetabular impingement syndrome under hip arthroscopy. *J Beth Med Sci*, 2017, 15: 429–432.
- Wang F. Etiology of Hip Arthroscopic Reoperation and Functional Analysis of Hip Joint after Arthroscopic Reoperation. *China J Endosc*, 2018, 24: 66–69.
- Larson CM, Giveans MR. Arthroscopic management of femoroacetabular impingement: early outcomes measures. *Arthroscopy*, 2008, 24: 540–546.
- Ilizaliturri VM Jr, Orozco-Rodriguez L, Acosta-Rodriguez E, et al. Arthroscopic treatment of cam-type femoroacetabular impingement: preliminary report at 2 years minimum follow-up. *J Arthroplast*, 2008, 23: 226–234.
- Mardones RM, Gonzalez C, Chen Q, et al. Surgical treatment of femoroacetabular impingement: evaluation of the effect of the size of the resection. *J Bone Joint Surg Am*, 2005, 87: 273–279.
- Huang Z, Yin H, Xie J. Research progress in hip arthroscopic surgery. *Orthop J China*, 2009, 17: 684–687.
- Wang WG, Li ZR. Diagnosis progress of femoroacetabular impingement. *Chinese J Bone Joint*, 2010, 3: 78–83.
- Ruan JW, Chen M. Progress in clinical application of hip arthroscopy. *China J Orthop Traumatol*, 2011, 24: 794–797.
- Zhang JT. Research progress in femoroacetabular impingement syndrome. *Chinese J Mini Invasive Surg*, 2012, 12: 1145–1148.
- Wu ZY, Chen JW, Chen SY, et al. Arthroscopic femoral head and neck arthroplasty for treatment of cam-type femoroacetabular impingement. *Chinese J Orthop*, 2012, 32: 132–137.
- Yi BL, Liu HY. Research progress in femoroacetabular impingement. *J Clin Orthop*, 2013, 16: 221–224.
- Wang H. Diagnosis and treatment of femoroacetabular impingement syndrome. *Mod Diagnosis Treat*, 2013, 24: 1757–1758.
- Ouyang K, Lu W, Wang DP. Preliminary report on arthroscopic treatment of femoroacetabular impingement syndrome. *The 13th Asian Congress of Sports Medicine*, 2014, Beijing, China.
- Chen GX, Gu LC, Wang FL, He R, Yang L. Arthroscopic orthopedics of femoroacetabular impingement. *The 13th Asian Congress of Sports Medicine*. 2014, Beijing, China.

- 24.** Li WP, Song B, Yang R, et al., The treatment of femoroacetabular impingement syndrome under hip arthroscopy. The 13th Asian Congress of Sports Medicine. 2014, Beijing, China
- 25.** Sun Y, Chen CM, Gu M, Wu WT. Hip arthroscopic decompression for the treatment of cam-type femoroacetabular impingement syndrome. *J Pract Orthop*, 2015, 21: 878–882.
- 26.** Wang WG, Li ZR, Yue DB, Zhang NF, Wang BL, Guo WS. Arthroscopic osteoplasty for the treatment of cam-type femoroacetabular impingement. *China J Endosc*, 2015, 21: 587–591.
- 27.** Zhuo H, Wang X, Liu X, et al. Quantitative evaluation of residual bony impingement lesions after arthroscopic treatment for isolated pincer-type femoroacetabular impingement using three-dimensional CT. *Arch Orthop Trauma Surg*, 2015, 135: 1123–1130.
- 28.** Yao B, Zhao C, Gu HF, et al. *Evaluation of Early Efficacy of Hip Arthroscopy in The Treatment of Femoroacetabular Impingement Syndrome*. *Clin Educ Gener Pract*, 2015, 13: 548–550.
- 29.** Zhang D, Chen L, Wang G. Hip arthroscopy versus open surgical dislocation for femoroacetabular impingement: a systematic review and meta-analysis. *Medicine*, 2016, 95: 41.
- 30.** Jiang YF, Sun C, Sang WL, Ma JZ. Hip arthroscopy treatment for femoroacetabular impingement syndrome. *Orthop J China*, 2016, 24: 1679–1682.
- 31.** Yu TL, Lv SC. New progress in imaging diagnosis and treatment of femoroacetabular impingement syndrome. *Med Rec*, 2016, 22: 3231–3234.
- 32.** Ding R, Wang WG, Guo WS. Research progress of hip arthroscopy in the treatment of femoroacetabular impingement. *Chinese J Laparosc Surg*, 2016, 9: 187–189.
- 33.** Zhao L, Wang Y, Cai DZ, et al. Observation of short-term effect of arthroscopic treatment for femoroacetabular impingement syndrome. *Chinese J Reparat Reconstruct Surg*, 2016, 30: 21–24.
- 34.** Luo D, Zhang H. Classification and diagnostic criteria of femoroacetabular impingement are essential for clinical outcome evaluation: commentary on an article by Rachel M. Frank, MD, et al., Outcomes for hip arthroscopy according to sex and age: a comparative matched-group analysis. *J Bone Joint Surg Am*, 2016, 98: e42.
- 35.** Feng YQ, Li B, Li JM, Zhou JY. Clinical research progress of femoroacetabular impingement syndrome. *J Clin Med Lit*, 2017, 4.
- 36.** Chen XD. The road of "hip protection" will become wider and wider. *Chinese J Joint Surg*, 2017, 11.
- 37.** Shidehai Z. Extra-capsular approach and partial capsulotomy in hip arthroscopy for treatment of femoroacetabular impingement syndrome. *Asia-Pacific J Sports Med Arthrosc Rehabil Technol*, 2017, 9: 123–124.
- 38.** Lei P, Conaway WK, Martin SD. Outcome of surgical treatment of hip femoroacetabular impingement patients with radiographic osteoarthritis: a meta-analysis of prospective studies. *J Am Acad Orthop Surg*, 2019, 27: e70–e76.
- 39.** Zhou Z, Hu X, Ju XD. Perioperative nursing care of patients with femoroacetabular impingement syndrome treated by hip arthroscopy. *Chinese J Mini Invasive Surg*, 2013, 13: 958–960.
- 40.** Li Z, Ji BP, Wang RZ. 27 cases clinic report of acetabular disease treated by hip arthroscopy. *J Pract Orthop*, 2014, 20: 1042–1043.
- 41.** You YL. 36 cases of femoroacetabular impingement syndrome treated by arthroscopy. *Psychol Doc*, 2017, 23: 54–56.
- 42.** Xu HT, Zhu WH, Cao B, et al. Treatment of femoroacetabular impingement syndrome by using "outside-in" hip arthroscopy technique. *Chinese J Sports Med*, 2018, 37: 373–376.
- 43.** Zhang X, Xu Y, Ju XD, et al. Clinical study on arthroscopic treatment efficacy of femoroacetabular impingement syndrome in patients over 50 years old. *Chinese J Sports Med*, 2018, 37: 97–103.
- 44.** Luo Z, Chen XG, Chen SJ, et al. Therapeutic effect and X-ray index analysis of hip arthroscopy in the treatment of femoroacetabular impingement syndrome. *China J Endosc*, 2018, 24: 29–35.
- 45.** Min XJ, Pan ZJ, Sun C. Clinical observation of arthroscopic treatment of femoroacetabular impingement syndrome with first degree labrum injury. *Orthop Biomech Mater Clin Stud*, 2018, 15: 55–57 +70.
- 46.** Li FL, Zeng YR, Zeng JC. Efficacy observation of hip arthroscopy in the treatment of femoroacetabular impingement syndrome. *Shenzhen J Integ Trad Chinese West Med*, 2018, 28: 13–15 +199.
- 47.** Li J, Li FL, Feng WJ, et al. Short-and medium-term curative effect of hip arthroscopy on femoroacetabular impingement syndrome. *Chinese J Clin Anat*, 2018, 36: 578–581.
- 48.** Pan T, Wang X, Zhang J, Li X. Comparison of clinical efficacy of hip arthroscopic surgery with or without joint capsule suture for femoroacetabular impingement syndrome. *J Clin Orthop Res*, 2019, 4: 200–218.
- 49.** Huang C, Lu Z, Wang F, et al. Analysis of the curative effect of hip arthroscopy on athletes' hip injuries. *Chinese J Bone Joint Inj*, 2019, 34: 337–340.
- 50.** Ni JL, Shi ZB, Zhou XQ, et al. Short-term effect of hip arthroscopic treatment for cam-type femoroacetabular impingement syndrome. *Chinese J Bone Joint Surg*, 2019, 12: 221–225.
- 51.** Wang C. Clinical observation on treatment of femoroacetabular impingement syndrome under hip arthroscopy treatment. *Heilongjiang Med J*, 2019, 32: 278–280.
- 52.** Shen LJ, Li ZZ, Chen WF, Zhang WQ. Femoroacetabular impingement syndrome under the treatment of hip arthroscopy. *J Clin Orthop*, 2019, 22: 186.
- 53.** Zhuo HW, Zhang J. A comparative study of labrum suturing and cleaning in the treatment of *Femoroacetabular Impingement* with labrum tear. *J Clin Orthop Res*, 2019, 4.
- 54.** Wu CT, Mahameed M, Lin PC, et al. Treatment of cam-type femoroacetabular impingement using anterolateral mini-open and arthroscopic osteochondroplasty. *J Orthop Surg Res*, 2019, 14: 222.
- 55.** Gao GY, Zhang X, Dai LH, et al. Heterotopic ossification after arthroscopy for hip impingement syndrome. *Chin Med J*, 2019, 132: 827–833.

APPENDIX I

