

A Case of Acquired Angioedema with Low C1 Inhibitor (C1-INH) Associated with Splenic Marginal Zone Lymphoma

Authors' Contribution:
Study Design A
Data Collection B
Statistical Analysis C
Data Interpretation D
Manuscript Preparation E
Literature Search F
Funds Collection G

E 1 **Nizar N. Abdel-Samad**
E 2 **Judit S. Kokai**

1 Department of Internal Medicine, Division of Hematology and Medical Oncology, The Moncton Hospital, Moncton, New Brunswick, Canada
2 Dr. Sheldon H. Rubin Oncology Clinic, Clinical Trials, The Moncton Hospital – Horizon Health Network, Moncton, New Brunswick, Canada

Corresponding Author: Nizar N. Abdel-Samad, e-mail: Nizar.AbelSamad@horizonnb.ca
Conflict of interest: None declared
Source of support: Research service, Horizon Health Network, The Moncton Hospital

Patient: Male, 68
Final Diagnosis: AAE
Symptoms: Angioedema
Medication: —
Clinical Procedure: —
Specialty: Hematology





Objective: Rare co-existence of disease or pathology
Background: Angioedema is a vascular reaction of the soft tissues or mucosa, with localized increased permeability of blood vessels. Patients with late-onset angioedema without urticaria have an increased risk of non-Hodgkin lymphoma. We present a case of late-onset angioedema that demonstrates that it is sometimes necessary to treat an indolent malignancy to address the symptoms of a secondary condition.

Case Report: A 68-year-old man presented to the Emergency Department with distressing swelling of his tongue and lips. No urticaria was observed and the remainder of the physical examination was unremarkable. The patient's past medical history included chronic thrombocytopenia for the last 1.5 years, which had been asymptomatic. Routine laboratory testing revealed pancytopenia. The patient was referred to the Oncology Department, where he was diagnosed with splenic marginal zone lymphoma. A careful review of the patient's past medical history revealed 3 episodes of soft tissue swelling of the lower limbs and 2 episodes of unexplained colicky abdominal pain. The patient was started on maintenance therapy of danazol, which prevented further episodes of angioedema. He later underwent splenectomy to improve his pancytopenia and to treat his lymphoma. In the post-operative period, the patient discontinued the danazol therapy. Three months after the splenectomy, he was asymptomatic and had not had any further angioedema episodes, and his laboratory values showed he was in remission.

Conclusions: In this case, late-onset angioedema with recurrent episodes of soft tissue swelling was associated with underlying hematologic malignancy. The patient's angioedema resolved when the malignancy was treated.

MeSH Keywords: Angioedema • Splenectomy • Splenic Neoplasms

Full-text PDF: <https://www.amjcaserep.com/abstract/index/idArt/915558>

 3034  —  2  27



Background

Angioedema is a vascular reaction of the soft tissues or mucosa, with localized increased permeability of blood vessels, resulting in tissue swelling. It is generally mediated by either histamine or bradykinin. Histamine-mediated angioedema can be allergic, pseudoallergic, or idiopathic, whereas bradykinin-mediated angioedema can be drug-induced, acquired, or hereditary [1]. Hereditary angioedema (HAE) is a rare form of severe angioedema caused by genetic mutations in the complement C1 inhibitor (C1-INH) gene, often leading to a decrease in C1-INH. There are 3 types of hereditary angioedema, called types I, II, and III, which can be distinguished by their underlying causes and levels of a protein called C1 inhibitor in the blood (C1-INH); in type I (80–85% of cases of hereditary angioedema), a gene mutation reduces the synthesis of C1-INH, resulting in reduced C1-INH serum levels and activity; in type II (15–20% of cases), a dysfunctional C1-INH protein is synthesized, resulting in normal C1-INH serum levels but reduced activity; and in type III (rare), both serum levels of C1-INH and C1-INH activity remain normal. It is a disorder characterized by recurrent episodes of severe swelling (angioedema). The most common areas of the body to develop swelling are the limbs, face, and intestinal tract; airway swelling is rare. HAE is not associated with urticaria. Another form of angioedema without urticaria affects patients older than 40 years who do not have a family history of angioedema. This form of late-onset angioedema without urticaria is described in the literature as acquired angioedema (AAE) with C1 esterase inhibitor deficiency and low C1q, and has shared clinical features with HAE. It is a rare disorder, associated in type 1 with autoimmune diseases or B cell lymphoproliferative disorders (non-Hodgkin lymphoma or monoclonal gammopathy), and in type 2 with autoantibodies against C1-INH [2], which is more frequent, at around 74% [3].

Non-Hodgkin lymphoma encompasses a heterogeneous group of neoplasms of the lymphoid system. In the World Health Organization's classification system of tumors of hematopoietic and lymphoid tissues, the group of marginal zone lymphomas (MZL) comprises 3 different entities: extranodal marginal zone B cell lymphoma of mucosa-associated lymphoid tissue (currently named MALT lymphoma), nodal marginal zone B cell lymphoma, and splenic marginal zone B cell lymphoma (SMZL, with or without circulating villous lymphocytes) [4].

In both HAE and AAE, swelling is due to local accumulation of bradykinin released from high molecular weight kininogen upon uncontrolled activation of plasma kallikrein deprived of its major physiological inhibitor, C1-INH [5]. The low levels of C1-INH, which occur when C1-INH is consumed by pathological lymphatic tissue or inactivated by autoantibody-mediated processes, are associated with hyperactivation of the complement or contact system, which may further consume C1-INH.

The cellular origin of SMZL is still a matter of debate: it is unclear whether the cells are memory B cells, which normally reside in the marginal zone, or post-germinal-zone B cells. There might be a role of an antigen-driven selection process, and unmutated naïve B cells with a high frequency of 7q deletions have also been detected. It is essential to resolve this debate so that this lymphoma can be correctly classified [6].

Concomitant disease

Scattered reports have described acquired C1-INH deficiency associated with nonhematologic neoplasms, infections, or autoimmune diseases, and 14% of patients with acquired C1-INH deficiency have no other disease [7]. AAE is most frequently associated with lymphoproliferative diseases ranging from monoclonal gammopathies of uncertain significance to non-Hodgkin lymphoma and/or anti-C1-INH inactivating autoantibodies. The coexistence of true B cell malignancy, non-malignant B cell proliferation, and pathogenic autoimmune responses suggests that AAE patients are all affected by altered B cell proliferation control, although the clinical evolution of their disease may vary [8].

The case report presented below describes a patient with late-onset angioedema whose recurrent episodes of soft tissue swelling were associated with underlying hematologic malignancy. The case also shows that recurrent angioedema without urticaria and without pruritus can be the first symptom of a malignant disease. It illustrates the fact that clinicians sometimes need to treat a primary condition that otherwise would not require treatment (lymphoma in this case) in order to control a secondary condition (angioedema in this case).

Case Report

A 68-year-old man presented to the Emergency Department in November 2016, with distressing swelling of his tongue and lips (Figure 1, as example). The patient reported that the swelling had gradually increased over a few hours. It was not associated with pruritus. The patient denied any breathing difficulty or abdominal pain. No urticaria was observed on the skin and the remainder of the physical examination was unremarkable. The swelling slowly resolved in about 24 hours, without steroid treatment.

The patient's past medical history included hypertension, depression, and chronic thrombocytopenia for the last 1.5 years, which had been asymptomatic. The past surgical history included orchiectomy and irradiation therapy 30 years ago for testicular cancer (seminoma). He was allergic to adhesive tape, but had no drug or food allergy. Routine laboratory testing on October 22, 2016 before visiting the Emergency

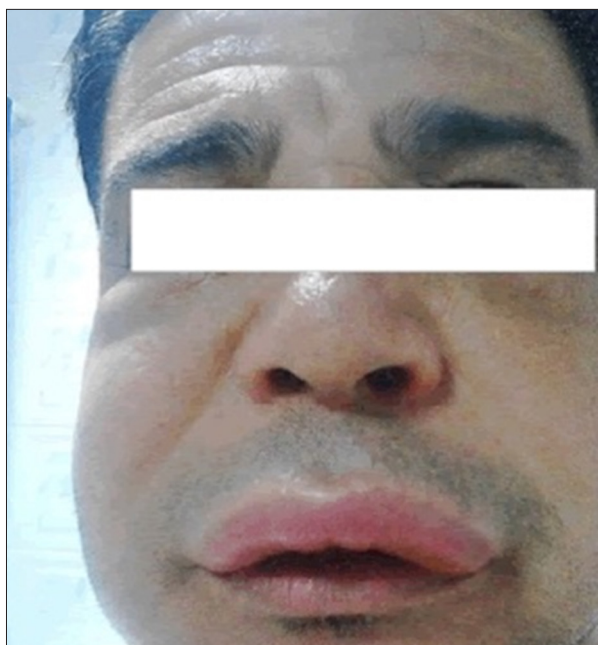

Figure 1. Angioedema of the face, most strikingly in the upper lip. *Boussetta N, Ghedira H, Hamdi MS et al.: Acquired Angioedema Revealing a B cell Non-Hodgkin Lymphoma in A Tunisian Man. Internal Medicine: Open Access (05). DOI: 10.4172/2165-8048.1000259. ISSN 21658048. Creative Commons Attribution License.*

Department, revealed pancytopenia with a white blood cell count of $3.1 \times 10^3/\mu\text{L}$, a hemoglobin level of 10.2 mg/dL, a mean corpuscular volume of 78.7 fL, and a platelet count of $65 \times 10^3/\mu\text{L}$.

The origin of the patient's symptoms was uncertain. It was hypothesized that he possibly had had an allergic reaction to cayenne pepper or his hypertension medication (losartan), but the hematologic abnormality required further investigations and he was referred to Hemato-Oncology.

Two months later, on December 29, 2016, the patient was seen at the Oncology Department of our institution. At that time, he complained of mild tiredness for the last 4 months and symptoms of acid reflux. He did not have a fever, sweating, or weight loss. During physical examination the patient was not in apparent distress, and his vital signs were within normal limits. He did not have any bruises, bleeding, palpable lymphadenopathy, cardio-respiratory changes, or lower-limb edema. The patient had massive splenomegaly of about 10 cm on abdominal palpation, although this was not easily appreciated because he was overweight.

The laboratory examination indicated pancytopenia similar in extent to that seen in the initial testing, with mild lymphopenia throughout the follow-up period. A blood smear revealed a few abnormal-looking lymphocytes, and red blood cells showed

microcytosis and mild anisocytosis. Protein electrophoresis did not show any abnormal monoclonal bands. Serum immunofixation showed equivocal monoclonal band in the light chain. The beta-2 microglobulin level was significantly higher than normal, at 9.16 mg/L. The anti-cardiolipin immunoglobulin G (IgG) was negative (2.2 GPL/mL), while the immunoglobulin M (IgM; 92.8 MPL/mL) was positive. The viral serology results for cytomegalovirus, Epstein-Barr virus, hepatitis A, B, and C, and HIV were all negative.

A bone marrow biopsy was performed and showed the presence of lambda-restricted monoclonal B cells, which constituted about 3–5% of marrow cellularity, suggesting marginal zone lymphoma. All lineages showed adequate numbers in the background, including the erythrocytic lineage and megakaryocytes, which points to peripheral causes of the patient's thrombocytopenia. The almost depleted iron stores explained the chronic microcytic anemia. All of these findings, including the bone marrow results, led us to the presumptive diagnosis of splenic marginal zone lymphoma (SMZL), with minimal involvement of the bone marrow. This case of asymptomatic low-grade lymphoma has not required any treatment.

A careful review of the patient's past medical history revealed 3 consecutive episodes of soft tissue swelling of the lower limbs and 2 episodes of unexplained colicky abdominal pain. The areas that swelled were the subcutaneous tissues of the right foot and groin, and these episodes resolved spontaneously over 24–48 hours. The patient described the abdominal episodes as gradually increasing, moderately severe periumbilical pain, which lasted for 2–3 days and resolved spontaneously; he did not seek medical attention for these episodes. There was no further episode involving the face or the upper respiratory track. There was no family history of angioedema or hematologic malignancy.

The diagnosis of acquired angioedema was confirmed on laboratory analysis, with low levels of C1-esterase (<0.06 mg/dL) and complement component 4 (<0.02 g/L). The C1q level was low as well (less than 2 RU/mL), confirming the acquired nature of the disease. Therapy with C1-INH concentrate would have been optimal. The concentrate was requested, but given that his attacks were brief, not severe nor frequent, he was started on maintenance therapy of danazol 200 mg twice daily, which has successfully prevented further episodes of angioedema.

At a follow-up visit 1 month later, the CT scan indicated that it measured 23 cm. He said that he had started to feel his spleen, as it was getting much larger, and it was causing him significant discomfort. The patient's pancytopenia and performance status had worsened. His white blood cell count was $2.36 \times 10^3/\mu\text{L}$, his hemoglobin level was 9.4 mg/dL, and his platelet count was $62 \times 10^3/\mu\text{L}$. The decision was made for

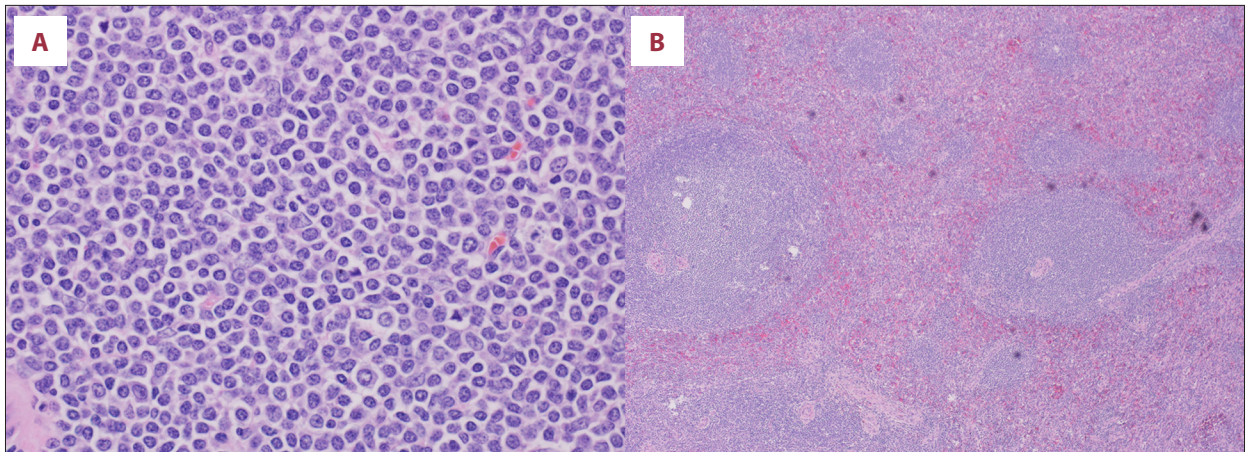


Figure 2. Pathologic evaluation of the patient's splenic tissue, confirming the presumptive diagnosis of splenic marginal zone lymphoma: higher (A) and lower (B) magnification.

the patient to undergo splenectomy to improve his pancytopenia and treat and control his lymphoma. After the patient received the recommended immunization against encapsulated organisms, splenectomy was performed on July 9, 2018, 18 months after the bone marrow biopsy. The patient's laboratory parameters have improved remarkably since then. On July 13, 2018, shortly before he was discharged, his white blood cell count was $12.92 \times 10^3/\mu\text{L}$, his hemoglobin level was 11.4 mg/dL, and his platelet count was $421 \times 10^3/\mu\text{L}$. Pathologic evaluation of the splenic tissue confirmed the presumptive diagnosis of SMZL (Figure 2).

In the postoperative period, the patient discontinued the danazol therapy. Now, 8 months after the splenectomy, he is still asymptomatic and has not had any further angioedema episodes, and his laboratory values showed persistent remission.

Discussion

The type of angioedema exhibited by this patient is rare: a report estimated that for every 12 patients diagnosed with HAE, 1 patient is diagnosed with AAE [9]. The prevalence of AAE may be between 1: 100 000 and 1: 500 000 [10]. The AAE cannot be confirmed in this patient by symptoms alone since AAE resembles HAE, except that it has a late onset (on average, after age 60 years) and patients lack a family history of angioedema. The largest cohort study of AAE, which included 92 patients, found that the most frequent manifestations of the condition were facial angioedema (75% of total cohort) and abdominal pain (60%), followed by angioedema of the extremities (48%), larynx (43%), tongue (32%), and genital organs (18%) [11]. The clinical differences between AAE and HAE are subtle: in HAE, angioedema of the skin is the most frequent symptom (91% of patients), followed in frequency by abdominal attacks (73%) and upper-airway edema (48%) [12]. Involvement of

the upper airways places patients at risk of asphyxiation, and the unexplained abdominal pain can mimic acute abdomen, which can lead to unnecessary surgery; hence, early diagnosis and adequate treatment of angioedema may be lifesaving.

The diagnosis of this patient was confirmed for AAE by laboratory workup results, including low C4, C1-INH, and C1q level. The C1q level, which is normal in HAE patients with rare exceptions, is low in most cases of AAE [13]. If a patient's C1q is found to be normal, autoantibodies to C1-INH and immunoglobulins preventing C1-INH function or binding C1-INH can be investigated; their presence at high titer allows AAE to be diagnosed [13].

The treatment of acute angioedema attacks in patients with AAE is derived from the management of HAE. Patients with AAE may not respond as well to plasma-derived C1-INH as patients with HAE because of the presence of C1-INH antibodies. Icatibant and ecallantide have been reported to be efficacious for the treatment of angioedema attacks in AAE [13].

Long-term treatment is often used to prevent angioedema symptoms. In HAE, androgen derivatives are very effective prophylactic agents, and in AAE, when it is secondary to lymphoproliferative disorder [4], as shown in this case. Although Danazol is not approved in some countries, but it is still most commonly used as the initial mode of treatment for prophylaxis. Because the effect of antifibrinolytic agents works through their anti-plasmin activity in C1-INH deficient patients, some consider them as the first-choice drug for angioedema prophylaxis in AAE [10].

In our patient, AAE was found to be associated with an underlying malignancy. According to the World Health Organization's classification system, the most frequent histotypes of malignancies in patients with acquired C1-inhibitor deficiency are nodal and splenic marginal zone lymphomas and lymphoplasmacytic

lymphomas/Waldenström's disease [14]. SMZL is typically a rare disorder, comprising less than 2% of all lymphoid malignancies [15], but its prevalence is remarkably higher among AAE patients (66%) [16]. The prevalence of monoclonal gammopathy of uncertain significance in patients with acquired C1-inhibitor deficiency is 35%, which is much higher than its prevalence (approximately 3%) in the general population under age 70 years [17].

Cicardi and colleagues followed 42 AAE patients at a single center; the majority (33 patients) had a form of B cell lymphoproliferation: non-Hodgkin lymphoma or monoclonal gammopathy of uncertain significance. AntiC1-INH autoantibodies were detected in 32 patients, 21 of whom had either non-Hodgkin lymphoma or monoclonal gammopathy of uncertain significance. Evaluation of the antigenic binding of the M components, by agarose electrophoresis followed by immunofixation, in a group of these patients showed that all M components recognized purified C1-INH. These data demonstrate that in AAE, lymphoproliferation and production of anti-C1-INH autoantibodies largely overlap [18].

The same group later described 72 AAE patients, 24 of whom were identified with underlying B cell non-Hodgkin lymphoma and 15 of whom had SMZL. This raises the question of whether the patient's AAE is secondary to the lymphoma or vice-versa. The authors found that patients with AAE have an increased risk of non-Hodgkin lymphoma compared with the general population; interestingly, the risk of lymphoproliferative disease is confined to specific histotypes that are rare in the general population. SMZL is the most common histotype among AAE patients, with a frequency of 75% of indolent non-follicular B cell lymphoproliferative disease and of 62.5% of all lymphoproliferative disease [19].

Most patients with SMZL are more than 60 years old, and the disease usually presents with massive splenomegaly, which produces abdominal discomfort and pain. The splenomegaly in this case was asymptomatic. Nearly all patients have bone marrow involvement, often accompanied by involvement of peripheral blood; however, peripheral lymph node or extranodal involvement is typically absent. The clinical course is usually indolent, with 5-year overall survival ranging from 65% to 80% [4]. Others have found that 5% to 10% of patients undergo transformation to diffuse large B cell lymphoma [20,21].

In our patient, the diagnosis of SMZL was confirmed by the pathology of the resected spleen. It is typically characterized by micronodular infiltration of the spleen, with marginal-zone differentiation. The immunophenotype is usually IgM+ IgD+/- cytoplasmic-Ig-/+ pan B antigens+ CD5- CD10- CD23- CD43-/+ cyclin D1-. Deletions of 7q and NOTCH2 mutations are almost specific lesions of SMZL, and thus are promising diagnostic biomarkers of this lymphoma [6]. Splenomegaly with cytopenia is

a feature of various lymphoproliferative disorders, so excision of the spleen is often necessary to confirm a diagnosis of SMZL.

Consensus guidelines recommend treating SMZL only in the presence of symptomatic splenomegaly, cytopenias, systemic symptoms, or progressive nodal disease. A wide range of therapeutic options are available for SMZL; they include splenectomy, chemotherapy, rituximab alone, and rituximab with chemotherapy [6].

In the series of Thieblemont and colleagues, no initial treatment was proposed for 20 patients with SMZL, but half of them required treatment after a median follow-up of 3 years because of the development of cytopenia or of a symptomatic spleen. At that time, splenectomy was considered the first-line treatment of choice. It produces only partial remission, but responses are generally sufficient for correcting cytopenia, improving quality of life and increasing survival [4,22]. The arrival of rituximab provided a new treatment option. Responses to splenectomy occurred in approximately 90% of patients, whereas rituximab monotherapy in 52 patients resulted in overall responses of 88% to 100%, with marked and prompt regression of splenomegaly and improvement of cytopenias [23]. Zucca and colleagues suggest that chemotherapy alone may be considered for patients who require treatment but have contraindication(s) to splenectomy, and for patients with clinical progression after spleen removal and that rituximab alone should be considered as the treatment of choice in elderly patients and in those with impaired renal function [4].

Currently, there are different opinions in the literature regarding the treatment of AAE with underlying hematologic disease. Treating the malignancy might be sufficient to control the angioedema, but given the rarity of the disease, no consensus has been reached yet.

In the AAE study of Gobert and colleagues, 7 patients with SMZL were treated with a splenectomy, and AAE improved in all cases [11]. In the same study, rituximab was administered to 34 patients for lymphoma ($n=10$), frequent angioedema attacks ($n=14$), or both ($n=10$), and AAE improved in 27 of these patients (79%). Some case reports also describe successful use of rituximab in the context of AAE with hematologic malignancy [24,25] or without it [24,26].

Castelli and colleagues described 15 AAE patients with SMZL. They administered various types of therapy: a non-anthracycline-containing single-agent regimen, an anthracycline-containing regimen, a bendamustine and rituximab combination, rituximab alone, or splenectomy alone. All except 2 patients experienced complete clinical improvement of their angioedema (<1 attack/year) [19].

These findings suggest that treatment of the lymphoid malignancy prevents acute angioedema attacks in most cases, regardless of the treatment options chosen. However, angioedema attacks may resume, even without evidence of relapse of the associated disease. In other patients, symptoms and complement parameters revert to normal on remission of the associated lymphoproliferative disease and do not return even with recurrence of the malignancy [27]; thus, close follow-up of these patients is essential.

Conclusions

We have presented a case in which late-onset angioedema (AAE) with recurrent episodes of soft tissue swelling was associated with an underlying hematologic malignancy – SMZL.

References:

1. Kanani A, Betschel SD, Warrington R: Urticaria and angioedema. *Allergy Asthma Clin Immunol*, 2018; 14(Suppl. 2): 59
2. Moon AT: Acquired angioedema due to C1 inhibitor deficiency. *Medscape reference*. June 29, 2017
3. Wu MA, Castelli R: The Janus faces of acquired angioedema: C1-inhibitor deficiency, lymphoproliferation and autoimmunity. *Clin Chem Lab Med*, 2016; 54(2): 207–14
4. Zucca E, Bertoni F, Stathis A, Cavalli F: Marginal zone lymphomas. *Hematol Oncol Clin North Am*, 2008; 22: 883–901
5. Cugno M, Zanichelli A, Foeni F et al: C1-inhibitor deficiency and angioedema: Molecular mechanisms and clinical progress. *Trends Mol Med*, 2009; 15: 69–78
6. Arcaini L, Rossi D, Paulli M: Splenic marginal zone lymphoma: From genetics to management. *Blood*, 2016; 127: 2072–81
7. Agostoni A, Aygören-Pürsün E, Binkley KE et al: Hereditary and acquired angioedema: problems and progress: Proceedings of the third C1 esterase inhibitor deficiency workshop and beyond. *J Allergy Clin Immunol*, 2004; 114: S51–131
8. Cugno M, Castelli R, Cicardi M: Angioedema due to acquired C1-inhibitor deficiency: A bridging condition between autoimmunity and lymphoproliferation. *Autoimmun Rev*, 2008; 8: 156–59
9. Zingale LC, Beltrami L, Zanichelli A et al: Angioedema without urticaria: A large clinical survey. *CMAJ*, 2006; 175: 1065–70
10. Cicardi M, Zanichelli A: Acquired angioedema. *Allergy Asthma Clin Immunol*, 2010; 6: 14
11. Gobert D, Paule R, Ponard D et al: A nationwide study of acquired C1-inhibitor deficiency in France. *Medicine (Baltimore)*, 2016; 95: e4363
12. Farkas H, Martinez-Saguer I, Bork K et al: International consensus on the diagnosis and management of pediatric patients with hereditary angioedema with C1 inhibitor deficiency. *Allergy*, 2017; 72: 300–13
13. Lang DM, Aberer W, Bernstein JA et al: International consensus on hereditary and acquired angioedema. *Ann Allergy Asthma Immunol*, 2012; 109: 395–402
14. Castelli R, Zanichelli A, Cicardi M, Cugno M: Acquired C1-inhibitor deficiency and lymphoproliferative disorders: A tight relationship. *Crit Rev Oncol Hematol*, 2013; 87: 323–32
15. Matutes E, Oscier D, Montalban C et al: Splenic marginal zone lymphoma proposals for a revision of diagnostic, staging and therapeutic criteria. *Leukemia*, 2008; 22: 487–95
16. Sbattella M, Zanichelli A, Ghia P et al: Splenic marginal zone lymphomas in acquired C1-inhibitor deficiency: Clinical and molecular characterization. *Med Oncol*, 2018; 35: 118
17. Frémeaux-Bacchi V, Guinépain MT, Cacoub P et al: Prevalence of monoclonal gammopathy in patients presenting with acquired angioedema type 2. *Am J Med*, 2002; 113: 194–99
18. Cicardi M, Zanichelli A: The acquired deficiency of C1-inhibitor: Lymphoproliferation and angioedema. *Curr Mol Med*, 2010; 10: 354–60
19. Castelli R, Wu MA, Arquati M et al: High prevalence of splenic marginal zone lymphoma among patients with acquired C1 inhibitor deficiency. *Br J Haematol*, 2016; 172: 902–8
20. Camacho FI, Mollejo M, Mateo MS et al: Progression to large B-cell lymphoma in splenic marginal zone lymphoma: A description of a series of 12 cases. *Am J Surg Pathol*, 2001; 25: 1268–76
21. Conconi A, Franceschetti S, von Hohenstaufen A et al: Histologic transformation in marginal zone lymphomas. *Ann Oncol*, 2015; 26: 2329–35
22. Thieblemont C, Felman P, Callet-Bauchu E et al: Splenic marginal-zone lymphoma: A distinct clinical and pathological entity. *Lancet Oncol*, 2003; 4: 95–103
23. Bennett M, Schechter GP: Treatment of splenic marginal zone lymphoma: Splenectomy versus rituximab. *Semin Hematol*, 2010; 47: 143–47
24. Levi M, Hack CE, van Oers MH: Rituximab-induced elimination of acquired angioedema due to C1-inhibitor deficiency. *Am J Med*, 2006; 119: e3–e5
25. Lam DH, Levy NB, Nickerson JM et al: Acquired angioedema and marginal zone lymphoma. *J Clin Oncol*, 2012; 30: e151–53
26. Ziakas PD, Giannouli S, Psimenou E et al: Acquired angioedema: A new target for rituximab? *Haematologica*, 2004; 89: ELT13
27. Zingale LC, Castelli R, Zanichelli A, Cicardi M: Acquired deficiency of the inhibitor of the first complement component: Presentation, diagnosis, course, and conventional management. *Immunol Allergy Clin*, 2006; 26: 669–90

The AAE was secondary to the lymphoma as this situation has been documented in the literature. The patient's symptoms were mainly related to AAE, and when his lymphoma was treated, the AAE resolved completely. Further studies are needed to establish a causal association between these 2 conditions.

Department and Institution where work was done

Department of Internal Medicine, Division of Hematology and Medical Oncology, The Moncton Hospital, Moncton, New Brunswick, Canada

Conflict of interest

None.