

Review article

Musculoskeletal and neurocognitive clinical significance of adult hypophosphatasia

Se-Min Kim^{*}, Funda Korkmaz, Steve Sims, Vitaly Ryu, Tony Yuen, Mone Zaidi

Center for Translational Medicine and Pharmacological Science, Icahn School of Medicine at Mount Sinai, New York, NY, USA



ABSTRACT

Hypophosphatasia (HPP), also called Rathbun disease, is a rare genetic disorder that is caused by the loss-of-function mutation in the *ALPL* gene encoding tissue non-specific alkaline phosphatase. Doctor Rathbun first described the case of a 3-week-old infant who presented with severe osteopenia, rickets, and multiple radiographic fractures, and died shortly after of epileptic seizure and respiratory distress. The term “hypophosphatasia” was coined as the patients’ alkaline phosphatase levels were significantly low. Since then, our understanding of HPP has evolved, and now we appreciate causative genetic mutation and the broad spectrum of clinical presentation depending on the age of onset, severity, and skeletal involvement: perinatal, infantile, childhood, adult and odontohypophosphatasia. The new development of enzyme replacement with asfostase alfa has saved the lives of severe form of hypophosphatasia. However, it is still unclear and remains challenging how to manage adult HPP that often presents with mild and non-specific symptoms such as muscle pain, joint stiffness, fatigue, anxiety, or low bone mass, which are common in the general population and not necessarily attributed to HPP. In this review, we will present 3 unique cases of adult HPP and discuss the pathophysiology, clinical presentation particularly neuromuscular and neurocognitive symptoms and management of adult HPP.

1. Introduction: case presentation

1.1. Case 1

A 25-year-old Caucasian woman presented with delayed healing after right hip osteotomy for hip dysplasia. She had a history of bow legs in infancy, and ankle fracture when slipping on the sand in childhood. She reported chronic neck, back, and hip pain as well as stiffness and intermittent weakness in her legs. Her menstruation was regular without history of eating disorder or malabsorption. Fatigue, mental foginess and feeling of sickness chronically affected her day-to-day activities. Family history was unremarkable. She had normal plasma calcium, phosphate, parathyroid hormone (PTH), and 25-OH vitamin D levels. Dual-energy X-ray absorptiometry (DXA) showed that her bone mineral density was 1.096 g/cm² (Z-score: 0.4) and 1.067 g/cm² (Z-score: 1.0) at lumbar spine and hip, respectively. However, she was noted to have low serum ALP of 24 U/L and 27 U/L (38–126) in 2 separate occasions. Her serum vitamin B6 levels were elevated 42.7 µg/L (2.0–32.8) supporting the diagnosis of hypophosphatasia. Procollagen type 1 N-terminal propeptide (P1NP), C-terminal telopeptide (CTX) and osteocalcin were 32 µg/L (22–87), 196 pg/mL (38–724) and 6.6 ng/mL (4.9–30.9), respectively. The genetic sequencing confirmed the heterozygous missense

mutation c.407G > A (p.Asp136His) of *ALPL* gene.

1.2. Case 2

A 52-year-old Hispanic man was referred for osteoporosis management. He was otherwise healthy except for well-controlled HIV/AIDS. He did not have any personal history of fracture. Dual-energy X-ray absorptiometry (DXA) scan showed T-score of –1.3 at lumbar spine, –2.4 at femur and –2.7 at femur neck. He denied having any musculoskeletal or neurocognitive symptoms. Secondary work-up for osteoporosis revealed low serum ALP levels at multiple occasions ranged from 17 to 27 IU/L (38–126). The serum vitamin B6 levels were high 329.9 µg/L (3.4–65.2). Subsequent sequencing confirmed the heterozygous missense mutation c.1010A > G (p.Asp337Gly) of *ALPL* gene. The bone turnover markers all came back low: P1NP: 19 µg/L (22–87), osteocalcin: 6.3 ng/mL (3.2–39.6) and CTX: 149 pg/mL (38–724).

1.3. Case 3

A 31-year-old Caucasian female was referred after finding low alkaline phosphatase levels. She was healthy without any musculoskeletal, dental or neurocognitive symptoms. Her alkaline phosphatase

Peer review under responsibility of The Korean Society of Osteoporosis.

^{*} Corresponding author. Center for Translational Medicine and Pharmacological Science, Icahn School of Medicine at Mount Sinai, 1 Gustave L. Levy Pl, New York, NY 10029, USA.

E-mail address: se-min.kim@mountsinai.org (S.-M. Kim).

<https://doi.org/10.1016/j.afos.2023.12.003>

Received 7 October 2023; Received in revised form 3 December 2023; Accepted 12 December 2023

Available online 20 December 2023

2405-5255/© 2023 The Korean Society of Osteoporosis. Publishing services by Elsevier B.V. This is an open access article under the CC BY-NC-ND license (<http://creativecommons.org/licenses/by-nc-nd/4.0/>).

levels were 19 and 25 (38–126 U/L). The serum vitamin B6 came back high normal 52.8 µg/L (3.4–65.2). The genetic testing found c.984_986del (p.Phe328del) of *ALPL* gene.

2. Overview of hypophosphatasia

Hypophosphatasia (HPP) is caused by decreased activity of the tissue-nonspecific alkaline phosphatase (TNSALP), which is orthophosphoric-monoester phosphohydrolase, highly conserved, ubiquitous ectoenzyme (membrane-associated glycoprotein) encoded by *ALPL* gene that is located on chromosome 1p36.1-p34 [1]. Doctor Rathbun from the Hospital of Sick Children in Toronto, Canada, first described the case of a 3-week-old infant who presented with painful cries and failure to thrive. He showed severe osteopenia, rickets, and multiple radiographic fractures, and died shortly after of epileptic seizure and respiratory distress [2]. The term “hypophosphatasia” was coined as the patients’ alkaline phosphatase levels were significantly low despite normal calcium and phosphate levels [2]. Since then, our understanding of HPP has evolved, and now we appreciate causative genetic mutation and the broad spectrum of clinical presentation depending on the age of onset, severity and skeletal involvement: perinatal, infantile, childhood, adult and odontohypophosphatasia [1]. Alkaline phosphatase is named as such because it enhances hydrolysis of monophosphate esters at alkaline pH. The accumulation of natural substances of TNSALP causes musculoskeletal and neurocognitive symptoms: inorganic pyrophosphate (PPi), pyridoxal 5’ phosphate (PLP), adenosine triphosphate (ATP), di-phosphoryl lipopolysaccharide (LPS), phosphoethanolamine (PEA) and phosphorylated osteopontin [3]. TNSALP isoforms by alternative splicing or posttranslational modification from liver, kidney and bone, and the isozymes, which is encoded by different genes on chromosome 2q34-37 but catalyze same reaction, are all measured and reported as total serum alkaline phosphatase [4].

The prevalence and causative genetic mutation of HPP varies depending on ethnicity and geography. In Canadian Mennonites, the prevalence of the severe HPP form was estimated at 1/2500 and heterozygote carrier was reported as high as 1/25, almost all of which was accounted for the point mutation (p.Gly334Asp) [4,5]. Other than Canadian Mennonites, the prevalence of severe HPP in the USA, Europe, and Japan is rare, approximately 1/100,000 to 1/400,000 [4,6,7].

The musculoskeletal role of TNSALP was studied extensively and confirmed through genetic modification in mice. *Akp2*^{-/-} hypophosphatasia mice, which had less than 1% of wild-type plasma TNSALP activity, was characterized by osteomalacia, spontaneous bone fractures, and increased PPi levels [8]. *Alpl*^{-/-} mice, provided with a pyridoxine-containing diet, survived and developed normally, but displayed decreased trabecular bone volume fraction, altered trabeculation, and decreased mineralization. *Alpl*^{-/-} mice also showed muscle and motor coordination deficiency as evidenced by grip strength, inverted screen test and horizontal bar test [9]. A comprehensive summary of the phenotype of knock-out, knock-in or transgenic mice of alkaline phosphatase has recently been reviewed [10].

Unfortunately, this line of pre-clinical data does not represent adult HPP, which often is associated with heterozygous mutation and mild clinical picture. The clinical spectrum of adult HPP is quite broad and heterogeneous from asymptomatic carrier to constellation of musculoskeletal, dental and neurocognitive symptoms. Consistently, the functional testing of 155 *ALPL* variants by protein structure modeling and activity predictions showed a wide range of residual activity. Adding more complexity, in vitro residual activity between the childhood, adult and odonto-HPP groups were not significantly different [11]. Furthermore, the substantial phenotypic variability was exemplified in several studies reporting siblings, despite sharing the same *ALPL* gene mutation, exhibited with variable clinical presentations [12–14]. Our adult HPP cases highlight the heterogeneity and poor genotype-phenotype correlation observed in HPP. The clinical manifestation of reported cases

involving each mutation from our patient are summarized for clearer presentation in Table 2.

The clinical diagnosis of adult HPP is made by identifying low ALP levels in suspicious patients, followed by confirmatory genetic sequencing. Based on a retrospective study, 1.1% of 458,767 subjects of Marshfield clinic in the USA had at least 2 serum values less than 40 U/L and 0.2% had at least 2 values less than 30 U/L [15]. Another study also reported 0.49% of patients (N = 3285) who were seen for osteoporosis were found to have low ALP levels at least 2 occasions [16]. Therefore, it is important to review the potential confounding conditions that can present with low ALP levels (Table 1). Acute illnesses such as major trauma, major surgery, sepsis, starvation, cancer, or medical treatment like transfusion or chemotherapy can lower ALP levels. In addition, a list of medical conditions can cause low ALP levels: endocrine disorders such as hypothyroidism, Cushing’s disease, vitamin D intoxication, liver disease like Wilson’s disease, pernicious anemia, hypomagnesemia, Celiac disease or anti-resorptive use for osteoporosis [15].

Genetic testing serves as a definitive method for confirming a diagnosis of HPP. In a study conducted at an osteoporosis clinic, 87.5% of patients who had low ALP level at least 2 separate occasions were found to have potentially pathogenic variants in *ALPL* in heterozygous form [16]. Another study selected 589 patients with low ALP below 30 U/L, screened them for clinical signs and symptoms of HPP, and subsequently conducted genetic testing on 21 patients. Among them, 10 patients harbored a heterozygous pathogenic variant [17].

3. Musculoskeletal complication of adult HPP

According to the data from the global HPP Registry, over half of patients reported experiencing chronic bone pain (52.5%) [18]. Joint pain associated with arthropathy and chondrocalcinosis are also common [17,19]. Dental complications such as tooth pain, periodontitis, and dental caries can occur [17–19]. The excess presence of pyrophosphate (PPi) can cause various complications, including calcium pyrophosphate dihydrate (CPPD) deposition (CPPD arthropathy), PPi arthropathy, or pseudogout. In some cases, there is a paradoxical deposition of hydroxyapatite crystals in ligaments or around joints, a condition called calcific periarthritis [20–23].

Of most concern is the increased fracture risk in adult patients with HPP. The prevalence of fracture varies in studies depending on the criteria. Some studies identify HPP-related fracture when the circumstance meets the criteria (≥ 2 out of 5), namely, no or minimal trauma, prodromal pain, diaphyseal fracture, radiographic findings (pseudofracture/bicortical lucency or beaking/flaring). These criteria are also characteristic of atypical femur fracture associated with prolonged anti-resorptive use [24,25]. In adult HPP patients, approximately 20%–50% have experienced at least 1 fracture, and many of them have had multiple events [18,19,24]. Atypical fracture or HPP-related fracture occurs

Table 1
Conditions associated with low serum alkaline phosphatase levels.

Skeletal disorder	Endocrine/Mineral disorder	Gastrointestinal disorder	Others
Hypophosphatasia	Hypothyroidism	Celiac disease	Major surgery (Cardiac bypass)
Osteogenesis imperfecta	Cushing’s syndrome	Liver disease (Wilson disease)	Major trauma
Osteoporosis (on anti-resorptive medication)	Milk-alkali disease		Massive transfusion
Renal osteodystrophy	Hypomagnesemia		Starvation, caloric restriction
	Vitamin D intoxication		Sepsis Pernicious anemia

Table 2

The variable clinical phenotype resulting from mutation in our cases.

Mutation	Reported Cases	Type	Allele	Clinical presentation
c.407G > A (p. Asp136His)	Case 1	Adult HPP	Heterozygous	Hip dysplasia, delayed healing, non-specific neurocognitive symptoms (ie, fatigue, mental foginess, chronic pain)
	Taillandier et al. [63]	Adult HPP	Heterozygous	Two cases of late-onset (ages 77 and 60)
	Tenorio J et al. [64]	Adult HPP	Heterozygous	Detailed phenotype is not available except absence of fracture
	Tenorio J et al. [64]	Infantile HPP	Compound heterozygous (c.1540G > A)	Detailed phenotype is not available
	Li DF et al. [65]	Infantile HPP	Compound heterozygous (c.228delG)	Skeletal dysplasia, failure to thrive, developmental delay, recurrent pneumonia and respiratory failure
c.1010A > G (p. Asp337Gly)	Case 2	Adult HPP	Heterozygous	Low bone mass
	Whyte et al. [66]	Childhood HPP	Compound heterozygous (c.571G > A)	Premature tooth loss, decreased grip strength, low bone mass
c.984_986del (p. Phe328del)	Case 3	Adult HPP	Heterozygous	Asymptomatic
	Chang et al. [67]	Adult HPP	Heterozygous	Asymptomatic, normal alkaline phosphatase level
	Taillandier et al. [68]	Perinatal HPP	Compound heterozygous (c.1460C > T)	32 weeks old fetus with short and curved long bones
	Chang et al. [67]	Perinatal HPP	Compound heterozygous (c.650delTinsCTAA)	Diffuse skeletal demineralization, respiratory distress, undetectable alkaline phosphatase
	Seefried et al. [69]	Childhood HPP	Compound heterozygous (c.571G > A)	Detailed phenotype is not available
	Xu et al. [70]	Childhood HPP	Compound heterozygous (c.29T > C)	Early deciduous tooth loss, multiple fracture, severe rickets, rachitic chest, valgum deformity of right genu

in up to 20% of adult HPP patients [24,26,27].

The skeletal involvement in adult HPP varies in terms of presence and severity. Studies utilizing dual-energy X-ray absorptiometry (DXA) have indicated that adult HPP patients may have slightly reduced or, in some cases, even higher areal BMD (Z-score) [19,24,28,29]. A more detailed analysis focusing on bone quality (ie, microstructural structure and bone turnover) or biomechanical strength provided insights into the elevated fracture risk within this group. High-resolution peripheral quantitative computed tomography (HR pQCT) showed reduced cortical thickness and cortical BMD in the majority of adult HPP patients [19]. When comparing HPP patients with patients with low BMDs but without HPP, it was observed that fractures are more frequent in metatarsal/foot and femoral shaft region in HPP patients, while vertebral fractures were more common in low-BMD groups [29]. Additionally, HPP patients showed decreased bone turnover markers, such as PINP and β -crosslaps in comparison to the control group [28]. These factors, indicating decreased bone turnover, should be taken into consideration when determining appropriate therapeutic approaches.

Lastly, the biochemical parameter for disease activity may hold prognostic value. In patients with HPP-related fracture, there were notable differences in their biochemical profiles, including significantly lower levels of ALP, elevated PLP and urinary PEA [24]. Also, patients with a history of fracture or multiple clinical symptoms tended to have higher PLP levels [19].

4. Neurocognitive aspect of adult HPP

Seizures are a potential neuromanifestation of severe forms, such as perinatal or infantile HPP, but they do not typically occur in childhood, adult or odonto HPP types. This distinction is attributed to the significant role played by TNSALP in vitamin B6 metabolism. Specifically, TNSALP acts by dephosphorylating pyridoxal 5'-phosphate (PLP) to pyridoxal, a critical step necessary for the passage of this compound across the blood-brain barrier (BBB) [30]. Within neuronal cells, pyridoxal is subsequently phosphorylated back to PLP, serving as a co-factor for a number of PLP-dependent enzymes (Fig. 1). These enzymes, including aromatic amino acid decarboxylase (AADC), branched-chain amino acid 2-oxoglutarate aminotransferase, gamma-aminobutyric acid (GABA) transaminase, glutamate decarboxylase (GAD), glycine cleavage enzyme, kynureninase, kynurenine-aminotransferase and L-serine racemase are intricately involved in the metabolic pathways regulating dopamine, serotonin, glutamate, glycine, GABA, D-serine and

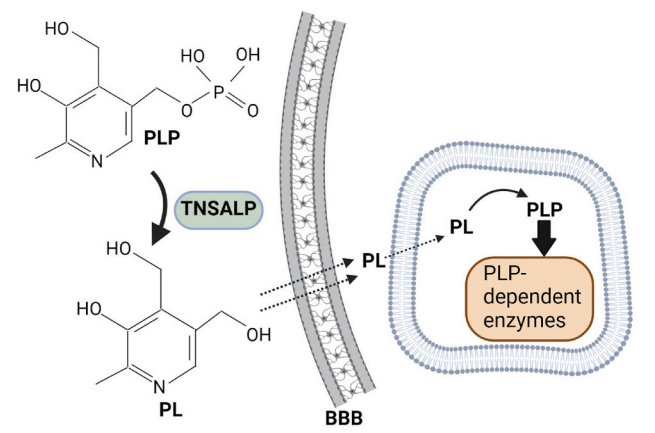


Fig. 1. Pyridoxal 5'-phosphate (PLP) is dephosphorylated by tissue non-specific alkaline phosphatase (TNSALP) to pyridoxal (PL) and cross the brain-blood barrier (BBB). In neuronal cell, PL is re-phosphorylated to active form of vitamin B6, PLP, and serves as a co-factor for a variety of PLP-dependent enzyme.

taurine [31]. With that said, it is unsurprising that vitamin B6 deficiency is not only linked with seizures, but also with dystonic movements and defects in neuronal migration [31].

In adult HPP, it is important to note that approximately 1 out of 4 patients encounter neurocognitive symptoms including fatigue, persistent myalgia, lack of energy, headache, a general feeling of unwellness and mental foginess [17–19,32]. In a study that assessed physical, functional and cognitive performance in 15 adult patients, it was found that HPP patients had a slower gait and decreased dexterity. Furthermore, the fatigue severity score was significantly higher than that in healthy population. Also, adult HPP patients reported higher scores for depression, anxiety and stress [33].

These neurocognitive aspects in adult HPP can be linked to impaired vitamin B6 metabolism, potentially disrupting the synthesis of GABA, dopamine or serotonin, crucial neurotransmitters [30,34]. However, in many cases, individuals with HPP exhibit normal plasma pyridoxal levels, even though PLP levels are elevated, except in severe cases [30,35,36].

Additionally, it can arise as a direct consequence of the enzyme deficiency, considering several distinct cell populations in the brain such as neuronal cells, microglia, astrocytes, oligodendrocytes and endothelial cells have been identified to express TNSALP [37]. TNSALP is also expressed within the parenchyma of the cerebral cortex, particularly in neuropile of thalamo-cortical innervation of internal granular layer in rodents and primates [38–40]. In humans, TNSALP has been localized to the cerebral cortex, particularly, to the internal pyramidal cell layer [41]. TNSALP activity has been shown to be regulated by sensory experience. It mirrors the activity of glutamate decarboxylase (GAD), an enzyme responsible for synthesizing GABA in presynaptic terminals [40]. Additionally, the enzyme activity has been observed to vary at different time points, correlating with the sequential development of modality-specific sensory areas including auditory, somatosensory, and visual cortex [38]. TNSALP activity transiently appeared in the white matter, displaying a complementary distributional pattern with myelin staining, exclusively in the myelin-free axonal segments, including the node of Ranvier [38]. Additionally, decreased ATP hydrolysis by TNSALP in somatic stem cells as neuronal stem cells and bone marrow mesenchymal stem cells could alter mitochondrial respiration and oxygen consumption [9,10]. Taken together, TNSALP may play a role in regulating neurotransmitters and stabilizing synapses. This suggests that a deficiency in its activity may lead to a decline in neurocognitive function.

The underlying mechanism responsible for chronic pain remains poorly understood but the involvement of ATP and adenosine in nociception is thought to contribute partly to chronic pain in HPP patients. It is well-known that ATP and adenosine play pivotal roles in nociception. ATP, when it binds to purinergic P2 receptor, has a pro-nociceptive effects in dorsal root ganglia (DRG) neurons [42,43]. Conversely, adenosine, a product of ATP hydrolysis, exerts an anti-nociceptive effect by activating A1 adenosine (A1R) receptor [44,45]. Therefore, it is plausible that lack of TNSALP and the resulting imbalance in ATP/adenosine may disrupt nociceptive circuits in DRG. However, it remains uncertain as other ectonucleotidase such as phosphatidate acid phosphatase (PAP) and 5'-Nucleotidase ecto (NT5E) are presumably intact and functioning in HPP patients.

Finally, there is evidence suggesting that TNSALP deficiency may prevent the progression of neurodegenerative diseases such as Alzheimer disease (AD). Specifically, TNSALP has been observed to express in the AD-vulnerable hippocampal region and cortex particularly thalamo-cortical connections in pyramidal layer [40,41,46]. During the progression of neurodegeneration, intracellular tau protein is released into the interstitial space and subsequently dephosphorylated by TNSALP. This dephosphorylated tau then interacts with muscarinic receptors, leading to increased intracellular calcium levels and ultimately triggering cellular death [47]. Interestingly, TNSALP expression and activity are found to be up-regulated by extracellular dephosphorylated tau in human neuronal cells [47], suggesting a potential positive feedback loop in which TNSALP is stimulated by the very product it generated. Consistently, several observational studies in humans have reported that TNSALP activity levels were increased in the brain and plasma of AD patients compared to control group [48,49]. These findings appear to be at odds with the role of TNSALP as essential component for establishing neuronal regenerative process by promoting axonal growth in the adult brain [38,40,41,46]. Therefore, the precise role of TNSALP in neurodegenerative disease warrants further careful investigation.

5. Management of adult HPP

The primary emphasis in managing adult HPP centers on addressing musculoskeletal complication. Given the high incidence of fracture, evaluating and preventing fracture are of critical importance. However, a significant challenge arises when dealing with adult HPP patients who frequently exhibit normal BMD, and the current practice, which is

heavily dependent on DXA, does not provide an effective means to assess bone quality in such cases. Another complicating factor is the presence of concurrent osteoporosis, which is a common condition in the general population and cannot be solely attributed to HPP.

Asfostase alfa (Strensiq®) is now available for adult patients with juvenile onset. It is a recombinant fusion protein consisting of the TNSALP ectodomain, the constant region of the human IgG1 Fc domain, and a terminal deca-aspartate motif. The TNSALP ectodomain is responsible for its enzyme function, while the deca-aspartate motif, with an affinity to hydroxyapatite crystals, enables bone targeting [50].

In studies using TNSALP-homozygous null (*Akp2^{-/-}*) mice, which phenocopied severe form of HPP, asfostase alfa treatment normalized ALP levels, improved skeletal mineralization and prevented seizures [51]. In humans, after 24 weeks of enzyme replacement, patients with life-threatening infantile or perinatal HPP showed healing of rickets, improvement in muscle function and pulmonary function as well as decrease in inorganic PPI and PLP [52].

The use of the enzyme replacement therapy in milder forms of HPP is still largely unknown whether it is necessary and, if needed, whether it should be administered lifelong or on-demand, particularly in situations like fracture. Limited evidence suggests the potential musculoskeletal benefits of asfostase alfa in adult HPP patients. Studies have shown clinical and radiographical improvements in adult HPP patients who received enzyme replacement after experiencing multiple refractory fractures [53,54]. In one case report involving a 24-year-old female patient, a detailed skeletal analysis after 2 years of asfostase alfa replacement showed +4.2% increase in BMD at lumbar spine and +3.9% increase in BMD at the left hip. Although microskeletal structure showed no significant changes by high resolution-peripheral quantitative computed tomography (HR-pQCT), histomorphometry revealed a substantial reduction in osteoid, replaced by mineralization, as confirmed by quantitative backscattered electron imaging (qBEI) and fourier transform infrared (FTIR) [55]. Long-term data, extending up to 5 years of asfostase alfa in adult HPP patients over 50 years, indicated that the mean T-score for lumbar spine and total hip remained within the normal range at the baseline (+1.1 to +3.2) and throughout up to 5-year treatment (−0.1 to +1.7) [56]. Similarly, in Case 1, the patient who had undergone hip osteotomy for hip dysplasia experienced delayed healing and persistent pain. Two months after starting asfostase alfa, significant pain relief was reported, and follow-up X-ray hip indicated healing changes at the osteotomy sites. In addition, the vitamin B6 level decreased to 5.1 µg/L from 42.7 µg/L (2.0–32.8).

The challenge lies in the management of adult HPP who present mild or no symptoms but concurrent with osteoporosis, as seen in Case 2. Firstly, attributing prevalent osteoporosis solely to HPP, a rare genetic disorder, without detailed skeletal assessment like histomorphometry is problematic. Secondly, the first line treatment, often anti-resorptive, should be avoided considering the skeletal characteristics of HPP, which are characterized by low bone turnover and hypomineralization. There is an overlap between bisphosphonate-associated atypical femur fracture (AFF) and HPP-related fracture, and reported cases indicate that AFF can occur in HPP patients receiving bisphosphonate [26,27,57]. Furthermore, it's worth noting that 67% of patients who developed AFF had bi-allelic mutation [58].

In certain instances, off label use of PTH agonist has been attempted, resulting in inconsistent outcomes. Teriparatide treatment was tried in adult HPP patients with heterozygote missense mutation (p. D378V) and resulted in the successful healing of metatarsal stress fracture [59]. Also, 2 cases receiving PTH 1–84 treatment reported improvements in pain, mobility, and fracture repair [60]. However, there have also been cases without positive outcomes [61]. The anti-sclerostin monoclonal antibody, which has demonstrated a dual effect by exerting both anti-resorptive and anabolic effects with an increased ALP enzymatic activity [62]. However, similarly to PTH agonists, there remains uncertainty regarding how to manage patients once the anabolic treatment is completed.

Having said that, the range of treatment options for managing osteoporosis in adult HPP patients is very limited. Following a discussion of potential treatment options, the patient in Case 2 opted not to initiate enzyme replacement or anti-osteoporotic medications. He considered these approaches invasive and unnecessary at this point, given his asymptomatic condition and overall state of good health.

Other extra skeletal manifestations, particularly musculoskeletal pain and neurocognitive symptoms often necessitate multidisciplinary support. Painful calcific periarthritis or osteoarthritis resulting from calcium pyrophosphate deposition (CPPD) or hydroxyapatite crystal deposition can be addressed with NSAIDs [21,23]. Persistent myalgia, limited motion or joint pain should be further evaluated by specialists in Pain Medicine or Physical Medicine and Rehabilitation. Early recognition and timely assessment of neurocognitive symptoms like fatigue, headache, anxiety, depression, sleep disturbance and neuropathy can contribute to improved patient satisfaction. Patients may benefit from additional support from therapists or psychiatrists. The patient in Case 1 reported notable improvement in overall health status initially. However, she continued to grapple with persistent neck pain from disc herniation and cervical stenosis, for which she underwent anterior cervical discectomy and fusion. Despite ongoing afofostase alfa, she still reported experiencing fatigue and mental fogging, which, at times, became severe enough to impair her day-to-day activities. Soft Bones Inc., a USA-based patient organization, offers educational resources and peer support services for both physicians and patients. Since the current enzyme replacement is specifically targeted to bone, exploring the conjugation of enzyme with other peptides or molecules may hold promise for addressing the pathology at other sites in the future.

6. Conclusions

The 3 cases presented in the review highlight the broad spectrum of adult HPP, ranging from asymptomatic carrier to full-blown conditions with musculoskeletal and neurocognitive symptoms. The available genetic testing for *ALPL* gene has enabled us to detect and confirm the condition, facilitating the informed approaches that help avoid unnecessary and potentially harmful interventions (ie, bisphosphonate use in HPP patients with osteoporosis). Asfostase alfa has saved lives of severe forms of HPP and is effective in improving skeletal health. However, its impact on the other organ system is nearly non-existent. The long-term use of asfostase alfa in adult HPP remains a topic of debate. Unfortunately, the current understanding of neurocognitive symptoms in adult HPP is quite limited, and the treatment options are primarily supportive. Understanding the role of TNSALP in mood and cognition and exploring improved delivery for enzyme replacement, such as intranasal administration, could enhance the management of neurocognitive symptoms of adult HPP.

Conflicts of interest

The authors declare no competing interests.

Acknowledgments

ORCID Se-Min Kim: 0000-0003-0877-7562. Funda Korkmaz: 0000-0002-9174-8369. Steve Sims: 0000-0002-1636-084X. Vitaly Ryu: 0000-0001-8068-4577. Tony Yuen: 0000-0001-8283-5076. Mone Zaidi: 0000-0001-5911-9522.

References

- [1] Whyte MP. Hypophosphatasia - aetiology, nosology, pathogenesis, diagnosis and treatment. *Nat Rev Endocrinol* 2016;12:233–46.
- [2] Rathbun JC. "HYPOPHOSPHATASIA": a new developmental anomaly. *Am Dis Child* 1948;75(6):822–31.
- [3] Sanabria-de la Torre R, Martínez-Heredia L, Gonzalez-Salvatierra S, Andujar-Vera F, Iglesias-Baena I, Villa-Suarez JM, et al. Characterization of genetic variants of uncertain significance for the *ALPL* gene in patients with adult hypophosphatasia. *Front Endocrinol* 2022;13:863940.
- [4] Mornet E. Hypophosphatasia. *Metabolism* 2018;82:142–55.
- [5] Greenberg CR, Taylor CL, Haworth JC, Seargeant LE, Philipps S, Triggs-Raine B, et al. A homoallelic Gly317->Asp mutation in *ALPL* causes the perinatal (lethal) form of hypophosphatasia in Canadian mennonites. *Genomics* 1993;17:215–7.
- [6] Mornet E, Yvard A, Taillandier A, Fauvert D, Simon-Bouy B. A molecular-based estimation of the prevalence of hypophosphatasia in the European population. *Ann Hum Genet* 2011;75:439–45.
- [7] Garcia-Fontana C, Villa-Suarez JM, Andujar-Vera F, Gonzalez-Salvatierra S, Martinez-Navajas G, Real PJ, et al. Epidemiological, clinical and genetic study of hypophosphatasia in a Spanish population: identification of two novel mutations in the *ALPL* gene. *Sci Rep* 2019;9:9569.
- [8] Fedde KN, Blair L, Silverstein J, Coburn SP, Ryan LM, Weinstein RS, et al. Alkaline phosphatase knock-out mice recapitulate the metabolic and skeletal defects of infantile hypophosphatasia. *J Bone Miner Res* 1999;14:2015–26.
- [9] Zhang Z, Nam HK, Crouch S, Hatch NE. Tissue nonspecific alkaline phosphatase function in bone and muscle progenitor cells: control of mitochondrial respiration and ATP Production. *Int J Mol Sci* 2021;22:1140.
- [10] Sato M, Saitoh I, Kiyokawa Y, Iwase Y, Kubota N, Imano N, et al. Tissue-nonspecific alkaline phosphatase, a possible mediator of cell maturation: towards a new paradigm. *Cells* 2021;10:3338.
- [11] Del Angel G, Reynders J, Negron C, Steinbrecher T, Mornet E. Large-scale in vitro functional testing and novel variant scoring via protein modeling provide insights into alkaline phosphatase activity in hypophosphatasia. *Hum Mutat* 2020;41(7):1250–62.
- [12] Berkseth KE, Tebben PJ, Drake MT, Hefferan TE, Jewison DE, Wermers RA. Clinical spectrum of hypophosphatasia diagnosed in adults. *Bone* 2013;54:21–7.
- [13] Hofmann C, Girschick H, Mornet E, Schneider D, Jakob F, Mentrup B. Unexpected high intrafamilial phenotypic variability observed in hypophosphatasia. *Eur J Hum Genet* 2014;22:1160–4.
- [14] Kadota T, Ochiai M, Okawa R, Nakano K. Different dental manifestations in sisters with the same *ALPL* gene mutation: a report of two cases. *Children* 2022;9.
- [15] McKiernan FE, Shrestha LK, Berg RL, Fuehrer J. Acute hypophosphatasemia. *Osteoporos Int* 2014;25:519–23.
- [16] Alonso N, Larraz-Prieto B, Berg K, Lambert Z, Redmond P, Harris SE, et al. Loss-of-function mutations in the *ALPL* gene presenting with adult onset osteoporosis and low serum concentrations of total alkaline phosphatase. *J Bone Miner Res* 2020;35:657–61.
- [17] Calmarza P, Lapresta C, Martínez García M, Ochoa J, Sienes Bailo P, Acha Pérez J, et al. Musculoskeletal pain and muscular weakness as the main symptoms of adult hypophosphatasia in a Spanish cohort: clinical characterization and identification of a new *ALPL* gene variant. *J Bone Miner Metabol* 2023;41:654–65.
- [18] Dahir KM, Seefried L, Kishnani PS, Petryk A, Hogler W, Linglart A, et al. Clinical profiles of treated and untreated adults with hypophosphatasia in the Global HPP Registry. *Orphanet J Rare Dis* 2022;17:277.
- [19] Schmidt T, Mussawy H, Rolvien T, Hawellek T, Hubert J, Rüter W, et al. Clinical, radiographic and biochemical characteristics of adult hypophosphatasia. *Osteoporos Int* 2017;28:2653–62.
- [20] Chuck AJ, Patrick MG, Hamilton E, Wilson R, Doherty M. Crystal deposition in hypophosphatasia: a reappraisal. *Ann Rheum Dis* 1989;48:571–6.
- [21] Lassere MN, Jones JG. Recurrent calcific periarthritis, erosive osteoarthritis and hypophosphatasia: a family study. *J Rheumatol* 1990;17:1244–8.
- [22] Whyte MP, Murphy WA, Fallon MD. Adult hypophosphatasia with chondrocalcinosis and arthropathy. Variable penetrance of hypophosphatasemia in a large Oklahoma kindred. *Am J Med* 1982;72:631–41.
- [23] Guanabens N, Mumm S, Möller I, González-Roca E, Peris P, Demertzis JL, et al. Calcific periarthritis as the only clinical manifestation of hypophosphatasia in middle-aged sisters. *J Bone Miner Res* 2014;29:929–34.
- [24] Genest F, Claußen L, Rak D, Seefried L. Bone mineral density and fracture risk in adult patients with hypophosphatasia. *Osteoporos Int* 2021;32:377–85.
- [25] Pazianas M, Kim SM, Yuen T, Sun L, Epstein S, Zaidi M. Questioning the association between bisphosphonates and atypical femoral fractures. *Ann N Y Acad Sci* 2015;1335:1–9.
- [26] Whyte MP. Atypical femoral fractures, bisphosphonates, and adult hypophosphatasia. *J Bone Miner Res* 2009;24:1132–4.
- [27] Genest F, Seefried L. Subtrochanteric and diaphyseal femoral fractures in hypophosphatasia-not atypical at all. *Osteoporos Int* 2018;29:1815–25.
- [28] López-Delgado L, Riancho-Zarrabeitia L, García-Unzueta MT, Tenorio JA, García-Hoyos M, Lapunzina P, et al. Abnormal bone turnover in individuals with low serum alkaline phosphatase. *Osteoporos Int* 2018;29:2147–50.
- [29] Desborough R, Nicklin P, Gossiel F, Balasubramanian M, Walsh JS, Petryk A, et al. Clinical and biochemical characteristics of adults with hypophosphatasia attending a metabolic bone clinic. *Bone* 2021;144:115795.
- [30] Whyte MP, Mahuren JD, Vrabel LA, Coburn SP. Markedly increased circulating pyridoxal-5'-phosphate levels in hypophosphatasia. Alkaline phosphatase acts in vitamin B6 metabolism. *J Clin Invest* 1985;76:752–6.
- [31] Wilson MP, Plecko B, Mills PB, Clayton PT. Disorders affecting vitamin B(6) metabolism. *J Inher Metab Dis* 2019;42(4):629–46.
- [32] Colazo JM, Hu JR, Dahir KM, Simmons JH. Neurological symptoms in hypophosphatasia. *Osteoporos Int* 2019;30:469–80.
- [33] Durrrough C, Colazo JM, Simmons J, Hu JR, Hudson M, Black M, et al. Characterization of physical, functional, and cognitive performance in 15 adults with hypophosphatasia. *Bone* 2021;142:115695.

- [34] Waymire KG, Mahuren JD, Jaje JM, Guilarte TR, Coburn SP, MacGregor GR. Mice lacking tissue non-specific alkaline phosphatase die from seizures due to defective metabolism of vitamin B-6. *Nat Genet* 1995;11:45–51.
- [35] Whyte MP, Zhang F, Wenkert D, Mack KE, Bijanki VN, Ericson KL, et al. Hypophosphatasia: vitamin B(6) status of affected children and adults. *Bone* 2022; 154:116204.
- [36] Baxter P. Pyridoxine-dependent seizures: a clinical and biochemical conundrum. *Biochim Biophys Acta* 2003;1647:36–41.
- [37] Brichacek AL, Brown CM. Alkaline phosphatase: a potential biomarker for stroke and implications for treatment. *Metab Brain Dis* 2019;34:3–19.
- [38] Fonta C, Negyessy L, Renaud L, Barone P. Postnatal development of alkaline phosphatase activity correlates with the maturation of neurotransmission in the cerebral cortex. *J Comp Neurol* 2005;486:179–96.
- [39] Langer D, Hammer K, Koszalka P, Schrader J, Robson S, Zimmermann H. Distribution of ectonucleotidases in the rodent brain revisited. *Cell Tissue Res* 2008;334:199–217.
- [40] Fonta C, Negyessy L, Renaud L, Barone P. Areal and subcellular localization of the ubiquitous alkaline phosphatase in the primate cerebral cortex: evidence for a role in neurotransmission. *Cerebr Cortex* 2004;14:595–609.
- [41] Negyessy L, Xiao J, Kantor O, Kovacs GG, Palkovits M, Doczi TP, et al. Layer-specific activity of tissue non-specific alkaline phosphatase in the human neocortex. *Neuroscience* 2011;172:406–18.
- [42] Hamilton SG, McMahon SB, Lewin GR. Selective activation of nociceptors by P2X receptor agonists in normal and inflamed rat skin. *J Physiol* 2001;534(Pt. 2): 437–45.
- [43] Hamilton SG, Wade A, McMahon SB. The effects of inflammation and inflammatory mediators on nociceptive behaviour induced by ATP analogues in the rat. *Br J Pharmacol* 1999;126:326–32.
- [44] Aley KO, Green PG, Levine JD. Opioid and adenosine peripheral antinociception are subject to tolerance and withdrawal. *J Neurosci* 1995;15:8031–8.
- [45] Zylka MJ. Pain-relieving prospects for adenosine receptors and ectonucleotidases. *Trends Mol Med* 2011;17(4):188–96.
- [46] Diez-Zaera M, Diaz-Hernandez JI, Hernandez-Alvarez E, Zimmermann H, Diaz-Hernandez M, Miras-Portugal MT. Tissue-nonspecific alkaline phosphatase promotes axonal growth of hippocampal neurons. *Mol Biol Cell* 2011;22:1014–24.
- [47] Diaz-Hernández M, Gómez-Ramos A, Rubio A, Gómez-Villafuertes R, Naranjo JR, Miras-Portugal MT, et al. Tissue-nonspecific alkaline phosphatase promotes the neurotoxicity effect of extracellular tau. *J Biol Chem* 2010;285:32539–48.
- [48] Kellett KA, Williams J, Vardy ER, Smith AD, Hooper NM. Plasma alkaline phosphatase is elevated in Alzheimer's disease and inversely correlates with cognitive function. *Int J Mol Epidemiol Genet* 2011;2:114–21.
- [49] Vardy ER, Kellett KA, Cocklin SL, Hooper NM. Alkaline phosphatase is increased in both brain and plasma in Alzheimer's disease. *Neurodegener Dis* 2012;9:31–7.
- [50] Nishioka T, Tomatsu S, Gutierrez MA, Miyamoto K, Trandafirescu GG, Lopez PL, et al. Enhancement of drug delivery to bone: characterization of human tissue-nonspecific alkaline phosphatase tagged with an acidic oligopeptide. *Mol Genet Metabol* 2006;88:244–55.
- [51] Millan JL, Narisawa S, Lemire I, Loisel TP, Boileau G, Leonard P, et al. Enzyme replacement therapy for murine hypophosphatasia. *J Bone Miner Res* 2008;23: 777–87.
- [52] Whyte MP, Greenberg CR, Salman NJ, Bober MB, McAlister WH, Wenkert D, et al. Enzyme-replacement therapy in life-threatening hypophosphatasia. *N Engl J Med* 2012;366:904–13.
- [53] Klidas P, Severt J, Aggers D, Payne J, Miller PD, Ing SW. Fracture healing in two adult patients with hypophosphatasia after asfotase alfa therapy. *JBMR Plus* 2018; 2(5):304–7.
- [54] Magdaleno AL, Singh S, Venkataraman S, Perilli GA, Lee YY. Adult-onset hypophosphatasia: before and after treatment with asfotase alfa. *AAACE Clin Case Rep* 2019;5:e344–8.
- [55] Rolvien T, Schmidt T, Schmidt FN, von Kroge S, Busse B, Amling M, et al. Recovery of bone mineralization and quality during asfotase alfa treatment in an adult patient with infantile-onset hypophosphatasia. *Bone* 2019;127:67–74.
- [56] Kishnani PS, Rockman-Greenberg C, Rauch F, Bhatti MT, Moseley S, Denker AE, et al. x-year efficacy and safety of asfotase alfa therapy for adults and adolescents with hypophosphatasia. *Bone* 2019;121:149–62.
- [57] Sutton RA, Mumm S, Coburn SP, Ericson KL, Whyte MP. "Atypical femoral fractures" during bisphosphonate exposure in adult hypophosphatasia. *J Bone Miner Res* 2012;27:987–94.
- [58] Rassie K, Dray M, Michigami T, Cundy T. Bisphosphonate use and fractures in adults with hypophosphatasia. *JBMR Plus* 2019;3:e10223.
- [59] Whyte MP, Mumm S, Deal C. Adult hypophosphatasia treated with teriparatide. *J Clin Endocrinol Metab* 2007;92:1203–8.
- [60] Schalin-Jäntti C, Mornet E, Lamminen A, Välimäki MJ. Parathyroid hormone treatment improves pain and fracture healing in adult hypophosphatasia. *J Clin Endocrinol Metab* 2010;95:5174–9.
- [61] Camacho PM, Mazhari AM, Wilczynski C, Kadanoff R, Mumm S, Whyte MP. ADULT hypophosphatasia treated with teriparatide: report of 2 patients and review of the literature. *Endocr Pract* 2016;22:941–50.
- [62] Seefried L, Baumann J, Hemsley S, Hofmann C, Kunstmann E, Kiese B, et al. Efficacy of anti-sclerostin monoclonal antibody BPS804 in adult patients with hypophosphatasia. *J Clin Invest* 2017;127:2148–58.
- [63] Taillandier A, Domingues C, Dufour A, Debiais F, Guggenbuhl P, Roux C, et al. Genetic analysis of adults heterozygous for ALPL mutations. *J Bone Miner Metabol* 2018;36:723–33.
- [64] Tenorio J, Alvarez I, Riancho-Zarrabeitia L, Martos-Moreno GA, Mandrile G, de la Flor Crespo M, et al. Molecular and clinical analysis of ALPL in a cohort of patients with suspicion of hypophosphatasia. *Am J Med Genet* 2017;173:601–10.
- [65] Li DF, Lan D, Zhong JZ, Dewan RK, Xie YS, Yang Y. [Infantile hypophosphatasia caused by a novel compound heterozygous mutation: a case report and pedigree analysis]. *Zhong Guo Dang Dai Er Ke Za Zhi* 2017;19:539–44.
- [66] Whyte MP, Zhang F, Wenkert D, McAlister WH, Mack KE, Benigno MC, et al. Hypophosphatasia: validation and expansion of the clinical nosology for children from 25 years experience with 173 pediatric patients. *Bone* 2015;75:229–39.
- [67] Chang KC, Lin PH, Su YN, Peng SS, Lee NC, Chou HC, et al. Novel heterozygous tissue-nonspecific alkaline phosphatase (TNAP) gene mutations causing lethal perinatal hypophosphatasia. *J Bone Miner Metabol* 2012;30:109–13.
- [68] Taillandier A, Domingues C, De Cazanove C, Porquet-Bordes V, Monnot S, Kiffer-Moreira T, et al. Molecular diagnosis of hypophosphatasia and differential diagnosis by targeted Next Generation Sequencing. *Mol Genet Metabol* 2015;116: 215–20.
- [69] Seefried L, Kishnani PS, Moseley S, Denker AE, Watsky E, Whyte MP, et al. Pharmacodynamics of asfotase alfa in adults with pediatric-onset hypophosphatasia. *Bone* 2021;142:115664.
- [70] Xu L, Pang Q, Jiang Y, Wang O, Li M, Xing X, et al. Four novel mutations in the ALPL gene in Chinese patients with odonto, childhood, and adult hypophosphatasia. *Biosci Rep* 2018;38:BSR20171377.