

Computed tomographic appearance of abdominal lymph nodes in healthy cats

Michael Perlini¹ | Andrew Bugbee²  | Scott Secret¹

¹Department of Veterinary Biosciences and Diagnostic Imaging, University of Georgia College of Veterinary Medicine, Athens, Georgia

²Department of Small Animal Medicine and Surgery, University of Georgia College of Veterinary Medicine, Athens, Georgia

Correspondence

Scott Secret, Department of Veterinary Biosciences and Diagnostic Imaging, University of Georgia College of Veterinary Medicine, Athens, GA 30602.
Email: secrests@uga.edu

Funding information

Diplomate Research Award, American College of Veterinary Radiology

Background: Computed tomography (CT) is commonly used in veterinary medicine and plays an important role in disease identification and cancer staging. Identification of abnormal abdominal lymph nodes is important for clinical, therapeutic, and prognostic decision making. No published study describes the CT appearance of abdominal lymph nodes in healthy cats.

Hypothesis/Objectives: All abdominal lymph centers will be identified on CT with the majority of lymph nodes being elongated and homogeneously contrast enhancing.

Animals: Sixteen healthy cats without clinical or biochemical evidence of disease.

Methods: Precontrast and postcontrast CT images of sedated healthy cats were used to identify the presence and descriptive characteristics of intra-abdominal lymph nodes. These assessments then were compared with patient characteristics to identify possible correlations.

Results: Abdominal lymph nodes were readily identified on CT with caudal mesenteric, colic, hepatic, inguinal, and pancreaticoduodenal lymph nodes identified in 16/16 cats. Lymph node size and shape varied among lymph centers with nearly all lymph nodes homogeneously contrast enhancing in 515/525. Significant negative correlations were identified between age and length ($P = .0166$) and width ($P = .0387$) of abdominal lymph nodes as well as age and number of sacral lymph nodes ($P = .0493$). Intranodal fat was present in 18/525 lymph nodes.

Conclusions and Clinical Importance: CT readily permitted identification and characterization of feline abdominal lymph nodes. This study provides subjective and objective data on the CT characteristics of abdominal lymph nodes in 16 healthy cats, with younger cats having larger abdominal lymph nodes and a higher number of sacral lymph nodes.

KEYWORDS

contrast, enhancement, shape, size

Abbreviations: CT, computed tomography; HU, Hounsfield unit; GEE, generalized estimating equation; ROI, region of interest; SD, standard deviation.

This study was done at the University of Georgia, College of Veterinary Medicine, Athens, GA 30602.

This is an open access article under the terms of the Creative Commons Attribution-NonCommercial License, which permits use, distribution and reproduction in any medium, provided the original work is properly cited and is not used for commercial purposes. © 2018 The Authors. Journal of Veterinary Internal Medicine published by Wiley Periodicals, Inc. on behalf of the American College of Veterinary Internal Medicine.

1 | INTRODUCTION

Computed tomography (CT) is commonly used in veterinary medicine and plays an important role in disease identification and cancer staging. The CT appearance of several infectious, inflammatory and neoplastic

conditions has been described in cats including mycobacterial infections, peritonitis, pancreatitis, mediastinal masses, adipose masses, and fibrosarcoma.^{1–5} Differentiation of normal versus disease-affected abdominal lymph nodes on CT is important not only for clinical and therapeutic decision making, but also for cancer staging and prognostication.

The ultrasonographic appearance of normal abdominal lymph nodes in cats has been described,⁶ but no study has described their appearance on CT. Computed tomography has superior spatial and contrast resolution and overcomes many of the limitations of ultrasonography including interoperator variability and superimposition of structures. In addition, with increasing access to multislice CT scanners, image acquisition can be obtained rapidly using only a restraint device⁷ or sedation alone.

Our objectives were to describe the presence, number, size, shape, attenuation, and enhancement pattern of abdominal lymph nodes on CT in healthy cats and assess for correlations to patient characteristics. We hypothesize that all abdominal lymph centers will be identified on CT and that the majority of lymph nodes would be elongated and homogeneously contrast enhancing.

2 | MATERIALS AND METHODS

Healthy cats without clinical signs of illness were recruited from students and staff of a veterinary teaching hospital for participation in this prospective descriptive study. All procedures were approved by the University of Georgia Clinical Research Committee and informed owner consent was obtained for each enrolled cat. A physical examination, CBC, serum biochemistry, urinalysis, quantitative pancreatic lipase immunoreactivity, and serum total thyroxine concentration were obtained at enrollment. Cats were excluded from analysis if any clinically relevant abnormalities were identified on physical examination, screening biochemical testing or CT. The age, sex, reproductive status, and body weight of each cat was recorded.

All cats enrolled in the study underwent CT of the abdomen under sedation. A cephalic venous catheter was placed and each cat was sedated using a standardized protocol: butorphanol (Torbugesic, Zoetis Inc, Kalamazoo, Michigan), 0.3–0.5 mg/kg IV; diazepam (Diazepam, Hospira Inc, Lake Forest, Illinois), 0.3–0.5 mg/kg IV; and, ketamine (Ketaset, Zoetis Inc, Kalamazoo, Michigan), 2–5 mg/kg IV. Each patient was placed in sternal recumbency on the couch of a 64-slice helical CT scanner (Siemens Somatom sensation, Munich, Germany). Images of the abdomen were acquired using 120 kVp, 200 mAs, and a pitch of 0.8 and reconstructed into 1-mm thick slices using an abdominal algorithm. Noncontrast images of the abdomen were acquired from cranial to the diaphragm caudally to the level of the coxofemoral joints. Iohexol (Omnipaque 350, GE Healthcare, Princeton, New Jersey) then was administered IV at 600 mg/kg using a power injector at a rate of 5 mL/s. Postcontrast CT images of the entire abdomen then were acquired 3–4 minutes after contrast injection using the same scan protocol as used in the noncontrast study.

All images were transferred to a dedicated workstation and viewed using post-processing viewing software (Osirix v.5.7, Pixmeo, Geneva,

Switzerland). Studies were anonymized, randomized, and reviewed in a soft tissue window with the ability to adjust window level and width as desired. The number, size, shape, attenuation, enhancement pattern, and presence of intranodal fat of the following lymph node centers were evaluated: aortic lumbar, renal, hepatic, splenic, gastric, pancreaticoduodenal, jejunal, ileocecal, colic, caudal mesenteric, medial iliac, sacral, and inguinal lymph nodes. Identification of each lymph node center was based on prior anatomic description.^{8,9}

A single author (M. Perlini) recorded the number and size (length and width) of lymph nodes in each lymph center, with measurements subsequently confirmed by a board-certified veterinary radiologist (S. Secret). Size was measured using electronic calipers with 3 measurements taken for each dimension and then averaged to account for any discrepancies in caliber placement. Lymph node length was defined as the largest dimension with width defined as the second largest dimension, being perpendicular to the length. Length and width measurements were obtained on transverse, sagittal, or dorsal reconstructions depending on the orientation of the lymph node.

Lymph node shape, attenuation, enhancement pattern, and presence of intranodal fat were assessed by 1 of the authors (M. Perlini) and confirmed by a board-certified veterinary radiologist (S. Secret). The shape of each lymph node was classified into 1 of 3 categories: (1) elongated, (2) round, or (3) other. An elongated shape was defined as having a short axis/long axis ratio of <0.5 , with round lymph nodes having a short axis/long axis ratio >0.5 . Bilobed lymph nodes or those with shapes other than elongated or round were categorized as other. When visible on ≥ 3 consecutive slices, lymph node attenuation was measured in Hounsfield units (HU) on both noncontrast and postcontrast images by placing a circular region of interest (ROI) over the largest cross-sectional area on transverse images. The ROI was placed in the same location on both the noncontrast and postcontrast images, excluding the hilus and intranodal fat, if present. Lymph node enhancement pattern was assessed on postcontrast images and classified as (1) homogeneous, (2) heterogeneous, or (3) peripheral (centrally more hypoattenuating). The presence of intranodal fat was defined as a focal fat attenuation within the lymph node.

2.1 | Statistical analysis

All statistical analyses were performed using commercially available software (SAS V 9.4 Cary, North Carolina). A significance threshold of 0.05 was used. Each set of *P*-values from all centers from each pair of a demographic variable and a lymph node variable were adjusted for multiple comparisons using the Holm-Bonferroni method. Pearson's correlations were used to test for correlations between total cat lymph node counts and lymph node counts by center with age and body weight. Student *t*-tests were used to test for differences between total cat lymph node counts and lymph node counts by center between male neutered and female spayed cats. The folded form *F* statistic was used to test if variances were equal between male neutered and female spayed cats. If unequal, Satterthwaite's approximation for degrees of freedom for the student's *t*-test was used.

TABLE 1 Number of lymph nodes identified at each lymph center in 16 healthy cats on CT

Lymph center	0 n (%)	1 n (%)	2 n (%)	3 or more n (%)
Aortic lumbar (n = 28)	4 (25.0%)	5 (31.3%)	2 (12.5%)	5 (31.3%)
Renal (n = 29)	2 (12.5%)	5 (31.3%)	3 (18.8%)	6 (37.5%)
Hepatic (n = 19)	0 (0.0%)	13 (81.3%)	3 (18.8%)	0 (0.0%)
Splenic (n = 41)	2 (12.5%)	2 (12.5%)	2 (12.5%)	10 (62.5%)
Gastric (n = 31)	4 (25.0%)	1 (6.3%)	4 (25.0%)	7 (43.8%)
Pancreaticoduodenal (n = 22)	0 (0.0%)	10 (62.5%)	6 (37.5%)	0 (0.0%)
Jejunal (n = 81)	0 (0.0%)	0 (0.0%)	0 (0.0%)	16 (100.0%)
Ileocecal (n = 36)	0 (0.0%)	1 (6.3%)	12 (75.0%)	3 (18.8%)
Colic (n = 65)	0 (0.0%)	1 (6.3%)	3 (18.8%)	12 (75.0%)
Caudal mesenteric (n = 39)	0 (0.0%)	4 (25.0%)	7 (43.8%)	5 (31.3%)
Medial iliac (n = 32)	1 (6.3%)	0 (0.0%)	14 (87.5%)	1 (6.3%)
Sacral (n = 38)	1 (6.3%)	0 (0.0%)	8 (50.0%)	7 (43.8%)
Inguinal (n = 64)	0 (0.0%)	0 (0.0%)	5 (31.3%)	11 (68.8%)

Abbreviation: n, number.

A linear mixed-effects model was used to test for differences in length, width, and preattenuation and postattenuation associated with age, body weight, or sex for each center separately and pooled. The full linear mixed-effects model included a fixed factor of sex or a covariate of age or body weight and a random factor of cat. A generalized estimating equation (GEE) approach was used to examine differences in shape, enhancement, or intranodal fat associated with age, body weight, or sex for each center separately and pooled. The full model included a fixed factor of sex or a covariate of age or body weight and a random factor of cat. A binomial distribution with a logit link function was used for

shape and intranodal fat and a multinomial distribution with a cumulative logit link function was used for enhancement. An exchangeable correlation structure was assumed for shape and an independent correlation structure was assumed for enhancement. Intranodal fat was summarized by cat as percentage of nodes with intranodal fat and analyzed by Pearson's correlations to test for correlation to age or student's *t*-tests to test for differences between male neutered and female spayed cats. The folded form *F* statistic was used to test if variances were equal between male neutered and female spayed cats. If unequal, Satterthwaite's approximation for degrees of freedom for the student's *t*-test was used.

TABLE 2 Mean lymph node length and width in 16 healthy cats on CT

Lymph center	Length (range; cm)	Width (range; cm)
Aortic lumbar (n = 28)	0.4 (0.2-0.9)	0.2 (0.1-0.3)
Renal (n = 29)	0.6 (0.2-1.4)	0.2 (0.1-0.5)
Hepatic (n = 19)	0.7 (0.2-2.3)	0.3 (0.1-0.7)
Splenic (n = 41)	0.5 (0.1-0.8)	0.3 (0.1-0.8)
Gastric (n = 31)	0.6 (0.2-1.9)	0.3 (0.1-0.5)
Pancreaticoduodenal (n = 22)	0.7 (0.2-1.4)	0.4 (0.2-0.8)
Jejunal (n = 81)	1.7 (0.3-4.8)	0.5 (0.2-1.0)
Ileocecal (n = 36)	0.6 (0.2-1.3)	0.4 (0.1-0.7)
Colic (n = 65)	0.7 (0.2-2.0)	0.4 (0.2-0.8)
Caudal mesenteric (n = 39)	0.8 (0.1-2.0)	0.4 (0.1-1.0)
Medial iliac (n = 32)	1.3 (0.5-2.5)	0.4 (0.2-0.9)
Sacral (n = 38)	0.7 (0.3-1.6)	0.3 (0.1-0.5)
Inguinal (n = 64)	0.9 (0.2-2.0)	0.4 (0.1-0.8)

Abbreviation: n, number.

3 | RESULTS

Sixteen cats were enrolled in the study, including 12 domestic short-hair, 2 Himalayans, 1 domestic medium hair, and 1 domestic longhair. Cats ranged in age from 1 to 15 years old, with a median of 9 years. There were 9 male neutered and 7 female spayed cats. Cats weighted between 2.8 and 6.4 kg, with a median of 4.5 kg.

Five-hundred and twenty-five abdominal lymph nodes were readily identified on CT. The number, size, and shape of lymph nodes at each lymph center are summarized in Tables 1–3. The caudal mesenteric, colic, hepatic, inguinal, and pancreaticoduodenal lymph nodes were identified in 100% (16/16) of cats. The sacral and medial iliac lymph nodes were identified in 94% (15/16) of cats. The renal and splenic lymph nodes were identified in 88% (14/16) of cats with the aortic lumbar and gastric lymph nodes identified in 75% (12/16) of cats. Body weight and sex were not associated with differences in the overall number of lymph nodes identified (*P*-values = .3845 and .8565, respectively). A significant negative correlation however was found in the number of sacral lymph nodes and age ($r = 0.68$; *P*-value = .0493), with older cats having fewer. A negative association also was identified between age and lymph node length (*P*-value = .0166) and width

TABLE 3 Shape of abdominal lymph nodes on CT in 16 healthy cats

Lymph center	Elongated	Round
Aortic lumbar (n = 28)	18 (64%)	10 (36%)
Renal (n = 29)	16 (55%)	13 (45%)
Hepatic (n = 19)	8 (42%)	11 (58%)
Splenic (n = 41)	11 (27%)	30 (73%)
Gastric (n = 31)	18 (58%)	13 (42%)
Pancreaticoduodenal (n = 22)	6 (27%)	16 (73%)
Jejunal (n = 81)	58 (72%)	23 (28%)
Ileocecal (n = 36)	10 (28%)	26 (72%)
Colic (n = 65)	23 (35%)	42 (65%)
Caudal mesenteric (n = 39)	17 (44%)	22 (56%)
Medial iliac (n = 32)	32 (100%)	0 (0%)
Sacral (n = 38)	28 (74%)	10 (26%)
Inguinal (n = 64)	43 (67%)	21 (33%)

Abbreviation: n, number.

(P -value = .0387), with younger cats having larger lymph nodes. The majority of abdominal lymph nodes were classified as elongated 54% (288/525), with the remainder categorized as round. No lymph nodes were categorized as other. No associations between lymph node shape and age (P -value = .1879), body weight (P -value = .2723), or sex (P -value = .0762) were identified.

Abdominal lymph node attenuation is listed in Table 4. No significant association of age, body weight, or sex with precontrast and postcontrast attenuation or postcontrast enhancement pattern was found

TABLE 4 Mean CT lymph node attenuation in 16 healthy cats

Lymph center	Pre contrast HU (range)	Post contrast HU (range)
Aortic lumbar (n = 28)	31 (19–39)	106 (91–127)
Renal (n = 29)	27 (13–49)	140 (108–230)
Hepatic (n = 19)	32 (15–56)	138 (79–260)
Splenic (n = 41)	34 (17–60)	112 (71–156)
Gastric (n = 31)	32 (20–56)	106 (67–140)
Pancreaticoduodenal (n = 22)	33 (10–56)	120 (50–204)
Jejunal (n = 81)	33 (16–50)	157 (100–263)
Ileocecal (n = 36)	36 (19–52)	137 (90–180)
Colic (n = 65)	34 (20–49)	135 (71–207)
Caudal mesenteric (n = 39)	33 (13–49)	129 (62–196)
Medial iliac (n = 32)	33 (24–50)	137 (91–213)
Sacral (n = 38)	35 (23–46)	136 (87–203)
Inguinal (n = 64)	32 (12–57)	124 (71–173)

Abbreviation: HU, Hounsfield units; n, number.

TABLE 5 P -values for age, body weight, and sex compared with precontrast attenuation, postcontrast attenuation, and enhancement pattern.

	Age	Body Weight	Sex
Precontrast attenuation	0.8380	0.4310	0.7870
Postcontrast attenuation	0.5233	0.1567	0.6161
Enhancement pattern	0.2041	0.5211	0.1328

with P -values listed in Table 5. Contrast enhancement was homogeneous in all aortic lumbar, caudal mesenteric, ileocecal, colic, gastric, hepatic, medial iliac, renal, sacral, and splenic lymph centers. The inguinal lymph nodes were homogeneously contrast-enhancing in 97% (62/64) of instances, with the other 2 lymph nodes enhancing peripherally. Ninety-three percent (75/81) of jejunal lymph nodes were homogeneously contrast-enhanced with 6% (5/81) heterogeneously contrast-enhancing and 1% (1/81) peripherally contrast-enhancing (Figure 1). The pancreaticoduodenal lymph nodes were homogeneously contrast-enhancing in 91% (20/22) instances, with 1 heterogeneously enhancing and the other peripherally enhancing. Intranodal fat (Figure 2) was identified in 18 lymph nodes, including 6 pancreaticoduodenal, 3 jejunal, 2 each of hepatic, sacral, and inguinal and 1 of each of the following: renal, splenic, and colic. No significant difference in the presence of intranodal fat was identified when compared to age (P -value = .9936), body weight (P -value = .4676), and sex (P -value = .1167).

4 | DISCUSSION

The use of CT to image the abdomen in cats is becoming more common. An understanding of the normal appearance of abdominal structures is important for the identification and differentiation of disease, ultimately used to direct clinical decision-making. No previous study has described the imaging findings of normal abdominal lymph nodes in cats on CT. In this prospective study, CT readily enabled assessment of abdominal lymph nodes in 16 clinically normal cats. Normal abdominal lymph nodes in cats in this study varied in size and shape on CT depending of the lymph center evaluated, with younger cats having larger abdominal lymph nodes and more sacral lymph nodes. Most abdominal lymph nodes were soft tissue-attenuating with homogenous contrast enhancement and only occasional intranodal fat.

In our study, 525 lymph nodes were identified, which included individual lymph nodes from all abdominal lymph centers. The frequency of abdominal lymph center identification (75%–100%) was better than that observed in a previous study that detected normal abdominal lymph centers in cats only 20%–100% of the time using ultrasonography.⁶ This difference is likely because gas and ingesta in the gastrointestinal tract do not obscure identification of deeper structures on CT as compared with ultrasound examination, as well as CT having superior contrast and spatial resolution, which facilitates differentiation of smaller soft tissue structures. All lymph centers may not be present in every cat, and the number of lymph nodes within a lymph center may vary.^{8,10,11} Thus, it is unknown whether all lymph centers

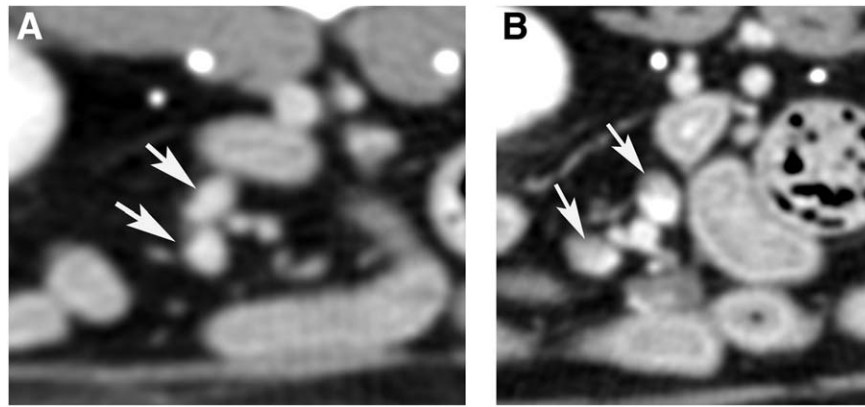


FIGURE 1 Transverse post contrast CT images of jejunal lymph nodes (white arrow) with homogenous (A) and heterogeneous (B) contrast enhancement (window level 40, window width 350)

truly were not identified in our study or if they were simply absent. The cat in which a medial iliac lymph node was not identified had a metallic pelvic implant, which precluded definitive identification. A negative correlation was identified between the number of sacral lymph nodes and age, but it is unclear why older cats would have fewer sacral lymph nodes and why other lymph centers would not have a similar correlation. This difference may be because of the relatively small size of the sacral lymph nodes preventing identification or our study could have been underpowered to detect this finding in other lymph centers.

The size and shape of abdominal lymph nodes in these cats varied among lymph centers. Mean lymph node length ranged from 0.4-1.7 cm and width from 0.2-0.5 cm with the jejunal lymph nodes being the largest overall, similar to prior ultrasonographic and anatomic reports.^{6,10,11} A negative correlation was found between age and lymph node length and width with younger cats having larger abdominal lymph nodes. This finding is consistent with those of previous studies evaluating normal medial retropharyngeal lymph node size in both dogs¹² and cats¹³ as well as abdominal lymph nodes in dogs.^{14,15} This finding is clinically important, indicating patient age should be considered when evaluating feline patients for abdominal lymphadenomegaly. Depending on the specific lymph center, some lymph nodes were more likely to be round versus elongated. The majority of the aortic lumbar (64%), renal (55%), gastric (58%), jejunal (72%), medial iliac (100%), sacral (74%), and inguinal (67%)

lymph nodes had an elongated shape, whereas the hepatic (58%), splenic (73%), ileocecal (72%), colic (65%), caudal mesenteric (56%), and pancreaticoduodenal (73%) lymph nodes tended to be rounded. These findings are similar to anatomic reports of cats as well as a previous CT study of dogs.^{11,16} Knowing the expected shape of lymph nodes in each lymph center is important for differentiation of disease. A rounded appearance of lymph nodes in dogs previously has been reported to be indicative of malignancy,¹⁷⁻¹⁹ and thus this finding should be used with caution depending on the individual feline lymph center assessed.

The attenuation of abdominal lymph nodes in healthy cats has previously not been reported. In our study, mean precontrast and postcontrast attenuation ranged from 27 to 36 HU and 106 to 157 HU, respectively, similar to the CT attenuation of normal canine lymph nodes¹⁶ and feline medial retropharyngeal lymph nodes.²⁰ Postcontrast attenuation of any structure however will vary depending on the time from contrast injection to image acquisition. Assessment of lymph node attenuation over time was not an objective of our study, and it is unknown what the attenuation of abdominal lymph nodes would be at other time points, but should be considered in future investigations. The majority of all abdominal lymph nodes (98%) had homogenous contrast enhancement with 6 lymph nodes having heterogeneous enhancement and 4 demonstrating peripheral enhancement. Five of the 10 lymph nodes with heterogeneous or peripheral contrast

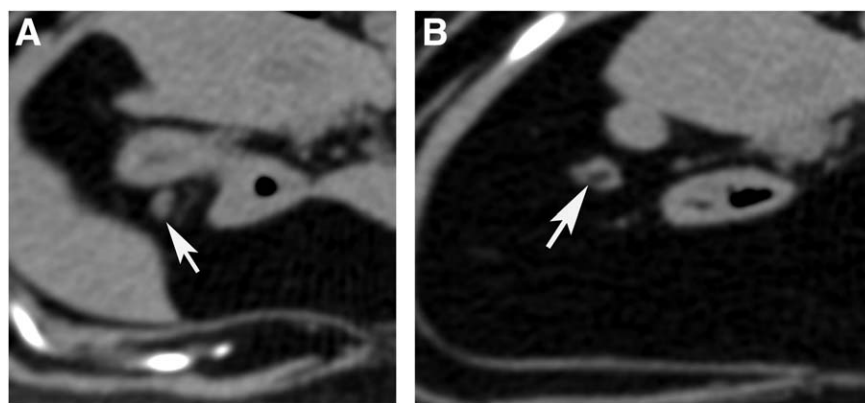


FIGURE 2 Transverse precontrast images of pancreaticoduodenal lymph nodes (white arrow) without (A) and with intranodal fat (B) (Window level 40, window width 350)

enhancement also had intranodal fat, which may play a role in explaining this appearance. Other potential causes for lack of homogenous contrast enhancement include abscessation, necrosis, cystic change, areas of hemorrhage, mineralization, or circulatory disturbances as well as neoplasia.^{18,19,21,22} On ultrasonography, heterogeneity of abdominal lymph nodes in cats has been shown not to be associated with malignancy.²³ Histopathology was not performed in our study, and it is unknown if nonhomogenous contrast enhancement can be normal in feline abdominal lymph nodes or if it represents occult disease.

Intranodal fat was visible in just 3% of all abdominal lymph nodes identified. Lymph node-associated fat of the canine sternal²⁴ and feline medial retropharyngeal¹³ lymph nodes previously has been described and assessed for differentiation of inflammatory versus neoplastic conditions.²⁰ In people, the presence of intranodal fat in pulmonary hilar lymph nodes has been reported as a benign change.²⁵ Small amounts of fat may have been present in additional lymph nodes in our study, but may not have been identified because of volume averaging from slice thickness. The clinical relevance of intranodal fat is unclear, but it should be recognized and not always assumed to represent pathology.

Limitations of our study included relatively small sample size and lack of histopathology. The small sample size may have prevented identification of associations between CT features and patient variables. All cats in our study were client-owned and free of clinically apparent disease and consequently histopathology was not performed. Histopathology would have allowed confirmation that all lymph nodes were truly normal and would have allowed histologic correlation with the few lymph nodes that had non-homogenous contrast enhancement. Cytology of the lymph nodes by fine needle aspiration also was not performed because of the concern for obtaining samples that do not reflect true disease status depending on the location from which the sample was obtained.

In conclusion, our study provides objective data on the CT characteristics of abdominal lymph nodes in 16 healthy cats. Computed tomography readily facilitated identification of all abdominal lymph centers. Abdominal lymph nodes in cats in our study varied in size and shape on CT, depending of the lymph center evaluated, with younger cats having larger abdominal lymph nodes and more sacral lymph nodes. Otherwise, most abdominal lymph nodes should be soft tissue-attenuating with homogenous contrast enhancement and only occasionally have intranodal fat. This information should be considered when trying to identify diseased lymph nodes and for cancer staging purposes.

ACKNOWLEDGMENT

The authors acknowledge Dr Deborah Keys, PhD for the statistical analysis.

CONFLICT OF INTEREST DECLARATION

The authors declare that they have no conflict of interest with the contents of this article.

OFF-LABEL ANTIMICROBIAL DECLARATION

Authors declare no off-label use of antimicrobials.

INSTITUTIONAL ANIMAL CARE AND USE COMMITTEE (IACUC) OR OTHER APPROVAL DECLARATION

Authors declare no IACUC or other approval was needed.

ORCID

Andrew Bugbee  <http://orcid.org/0000-0001-7997-0154>

REFERENCES

- Travetti O, di Giancamillo M, Stefanello D, et al. Computed tomography characteristics of fibrosarcoma - a histological subtype of feline injection-site sarcoma. *J Feline Med Surg*. 2013;15:488-493.
- Spoldi E, Schwarz T, Sabattini S, Vignoli M, Cancedda S, Rossi F. Comparisons among computed tomographic features of adipose masses in dogs and cats. *Vet Radiol Ultrasound*. 2017;58:29-37.
- Yoon J, Feeney DA, Cronk DE, Anderson KL, Ziegler LE. Computed tomographic evaluation of canine and feline mediastinal masses in 14 patients. *Vet Radiol Ultrasound*. 2004;45:542-546.
- Major A, Holmes A, Warren-Smith C, et al. Computed tomographic findings in cats with mycobacterial infection. *J Feline Med Surg*. 2016;18:510-517.
- Head LL, Daniel GB, Tobias K, Morandi F, DeNovo RC, Donnell R. Evaluation of the feline pancreas using computed tomography and radiolabeled leukocytes. *Vet Radiol Ultrasound*. 2003;44:420-428.
- Schreurs E, Vermote K, Barberet V, Daminet S, Rudolf H, Saunders JH. Ultrasonographic anatomy of abdominal lymph nodes in the normal cat. *Vet Radiol Ultrasound*. 2008;49:68-72.
- Oliveira CR, Mitchell MA, O'Brien RT. Thoracic computed tomography in feline patients without the use of chemical restraint. *Vet Radiol Ultrasound*. 2011;52:368-376.
- Barone R. Système lymphatique du chat. In: Barone R, ed. *Anatomie Comparée Des Mammifères Domestiques*. Tome 5 Angiologie. Paris: Editions Vigot; 1996:833-844.
- Nomina Anatomica Veterinaria. *Nomina Anatomica Veterinaria*, 5th edition (revised). Prepared by the International Committee on Veterinary Gross Anatomical Nomenclature (ICVGAN) and authorized by the General Assembly of the World Association of Veterinary Anatomists (WAVA), Knoxville, TN (USA) 2003. Hannover, Columbia, Gent, Sapporo: Editorial Committee; 2012.
- Tompkins MB. Lymphoid system. In: Hudson LC, Hamilton WP, eds. *Atlas of Feline Anatomy for Veterinarians*. Philadelphia: W.B. Saunders Company; 1993:113-126.
- Saar LI, Getty R. Carnivore lymphatic system. Part II: feline. In: Getty R, ed. *Sisson and Grossman's the Anatomy of the Domestic Animals*. 5th ed. Philadelphia: W.B. Saunders Company; 1975:1661-1669.
- Burns GO, Scrivani PV, Thompson MS, Erb HN. Relation between age, body weight, and medial retropharyngeal lymph node size in apparently healthy dogs. *Vet Radiol Ultrasound*. 2008;49:277-281.
- Nemanic S, Nelson NC. Ultrasonography and noncontrast computed tomography of medial retropharyngeal lymph nodes in healthy cats. *Am J Vet Res*. 2012;73:1377-1385.
- Pugh CR. Ultrasonographic examination of abdominal lymph nodes in the dog. *Vet Radiol Ultrasound*. 1994;35:110-115.
- Stander N, Wagner WM, Goddard A, Kirberger RM. Normal canine pediatric gastrointestinal ultrasonography. *Vet Radiol Ultrasound*. 2010;51:75-78.

- [16] Beukers M, Grosso FV, Voorhout G. Computed tomographic characteristics of presumed normal canine abdominal lymph nodes. *Vet Radiol Ultrasound*. 2013;54:610–617.
- [17] Llabrés-Díaz F. Ultrasonography of the medial iliac lymph nodes in the dog. *Vet Radiol Ultrasound*. 2004;45:156–165.
- [18] Nyman HT, Kristensen AT, Skovgaard IM, McEvoy FJ. Characterization of normal and abnormal canine superficial lymph nodes using gray-scale B-mode, color flow mapping, power and spectral Doppler ultrasonography: a multivariate study. *Vet Radiol Ultrasound*. 2005;46:404–410.
- [19] De Swarte M, Alexander K, Rannou B, D'Anjou MA, Blond L, Beauchamp G. Comparison of sonographic features of benign and neoplastic deep lymph nodes in dogs. *Vet Radiol Ultrasound*. 2011;52:451–456.
- [20] Nemanic S, Hollars K, Nelson NC, Bobe G. Combination of computed tomographic imaging characteristics of medial retropharyngeal lymph nodes and nasal passages aids discrimination between rhinitis and neoplasia in cats. *Vet Radiol Ultrasound*. 2015;56:617–627.
- [21] Rossi F, Patsikas M, Wisner E. Abdominal lymph nodes and lymphatic collecting system. In: Schwarz T, Saunders J, ed. *Veterinary Computed Tomography*. UK: Wiley; 2011:371–379.
- [22] Ballegeer EA, Adams WM, Dubielzig RR, Paoloni MC, Klauer JM, Keuler NS. Computed tomography characteristics of canine tracheo-bronchial lymph node metastasis. *Vet Radiol Ultrasound*. 2010;51:397–403.
- [23] Kinns J, Mai W. Association between malignancy and sonographic heterogeneity in canine and feline abdominal lymph nodes. *Vet Radiol Ultrasound*. 2007;48:565–569.
- [24] Milovancev M, Bobe G, Nemanic S. Computed tomographic assessment of sternal lymph node dimensions and attenuation in healthy dogs. *Am J Vet Res*. 2017;78:289–294.
- [25] Nambu A, Kato S, Saito A, Araki T. Appearances of mediastinal and pulmonary hilar lymph nodes on thin-section CT: comparison with 5 mm slice thickness CT. *Clin Imaging*. 2007;31:375–378.

How to cite this article: Perlini M, Bugbee A, Secret S. Computed tomographic appearance of abdominal lymph nodes in healthy cats. *J Vet Intern Med*. 2018;32:1070–1076. <https://doi.org/10.1111/jvim.15088>