

## Original Article

# Anterior and middle superior alveolar nerve block for anesthesia of maxillary teeth using conventional syringe

Ignacio Velasco<sup>1</sup>, Reinaldo Soto<sup>1</sup>

<sup>1</sup>Department of Oral and Maxillofacial Surgery, Los Andes University, School of Dentistry, Santiago, Chile

## ABSTRACT

**Background:** Dental procedures in the maxilla typically require multiple injections and may inadvertently anesthetize facial structures and affect the smile line. To minimize these inconveniences and reduce the number of total injections, a relatively new injection technique has been proposed for maxillary procedures, the anterior and middle superior alveolar (AMSA) nerve block, which achieves pulpal anesthesia from the central incisor to second premolar through palatal approach with a single injection. The purpose of this article is to provide background information on the anterior and middle superior alveolar nerve block and demonstrate its success rates of pulpal anesthesia using the conventional syringe.

**Materials and Methods:** Thirty Caucasian patients (16 men and 14 women) with an average age of 22 years-old, belonging to the School of Dentistry of Los Andes University, were selected. All the patients received an AMSA nerve block on one side of the maxilla using the conventional syringe, 1 ml of lidocaine 2% with epinephrine 1:100.000 was injected to all the patients.

**Results:** The AMSA nerve block obtained a 66% anesthetic success in the second premolar, 40% in the first premolar, 60% in the canine, 23.3% in the lateral incisor, and 16.7% in the central incisor.

**Conclusions:** Because of the unpredictable anesthetic success of the experimental teeth and variable anesthesia duration, the technique is disadvantageous for clinical application as the first choice, counting with other techniques that have greater efficacy in the maxilla. Although, anesthetizing the teeth without numbing the facial muscles may be useful in restorative dentistry.

**Key Words:** AMSA nerve block, dental anesthesia, local anesthesia, maxillary nerve

Received: January 2012  
Accepted: April 2012

### Address for correspondence:

Dr. Ignacio Velasco. Calle  
10 1022 depto 2, Urb  
Villa Nevarez. San Juan,  
Puerto Rico 00926-5225  
E-mail: iavelasco@  
miuandes.cl

## INTRODUCTION

Traditionally, maxillary teeth have been anesthetized by administering an injection in the mucobuccal supraperiosteal fold in the proximity to the apices of teeth to be anesthetized.<sup>[1]</sup> It is a convenient, safe, and effective way to achieve pulpal anesthesia in maxillary teeth and associated tissues.<sup>[2]</sup> The disadvantage is that it requires multiple injections to cover more than

one tooth and causing concomitant anesthesia of the lip and facial muscles.<sup>[3]</sup>

However, the maxillary teeth can also be anesthetized with troncular techniques (eg, infraorbital, maxillary) or intraosseous and intraligamentary injection.<sup>[4]</sup> The literature did not describe a technique that is produced with a single injection, multiple teeth anesthesia in maxilla, and without causing collateral anesthesia of the face. Therefore, Friedman and Hochman (1998) proposed an anesthetic technique in maxilla, the anterior and middle superior alveolar (AMSA) nerve block.<sup>[5]</sup> The authors state effective pulpal anesthesia from the central incisor to second premolar through palatal approach with a single injection and an expected anesthesia duration of 45 minutes to an hour [Figure 1], using a computer-controlled injection

Access this article online

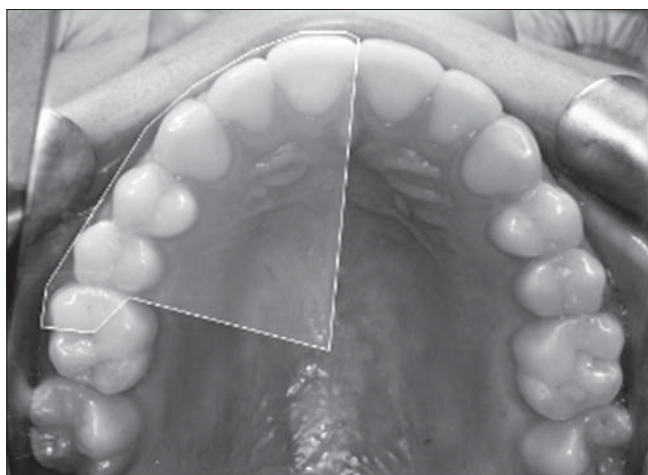


Website: [www.drj.ir](http://www.drj.ir)

system: the Wand Plus® (Milestone Scientific, Deerfield). Furthermore, the authors affirm that the anesthesia is achieved without causing lip numbness and no interference with the muscles of the facial expression.<sup>[5]</sup>

AMSA nerve block derives its name from the supposedly anesthesia of the anterior and middle superior alveolar nerves due to diffusion of the anesthetic solution via numerous nutrient channels on the palatal process of the maxillary bone [Figure 2].<sup>[5,6]</sup> Both nerves are collateral branches of the infraorbital nerve in the homonymous canal and part of the maxillary nerve.<sup>[1,7-10]</sup> The anterior superior alveolar (ASA) nerve originates approximately 5-8 mm posterior to the infraorbital foramen. It is responsible for the pulpal innervation of the central incisor, lateral incisor, and canine.<sup>[1,7-10]</sup> Meanwhile, the middle superior alveolar (MSA) nerve originates approximately 10 mm posterior to the infraorbital foramen. It is responsible for pulpal innervation of the premolars and the mesiobuccal root of the first molar.<sup>[1,7-10]</sup> However, the MSA nerve is not always present in several human dissection studies, which shows their presence in a range of 30-72%.<sup>[7-10]</sup> When the MSA nerve is absent, a plexus is formed between the posterior superior alveolar nerve and the ASA nerve to supply its innervation.<sup>[7-10]</sup>

The AMSA nerve block injection site is located palatally at a point that bisects the premolars and is approximately halfway between the midpalatine raphe and the crest of the free gingival margin [Figure 3]. This injection site is the confluence area of the ASA



**Figure 1:** Anesthetic area of AMSA injection: buccal gingiva, teeth (central incisor, lateral incisor, canine, first premolar, second premolar and mesiobuccal root of first molar), palatine gingiva and mucosa to midline

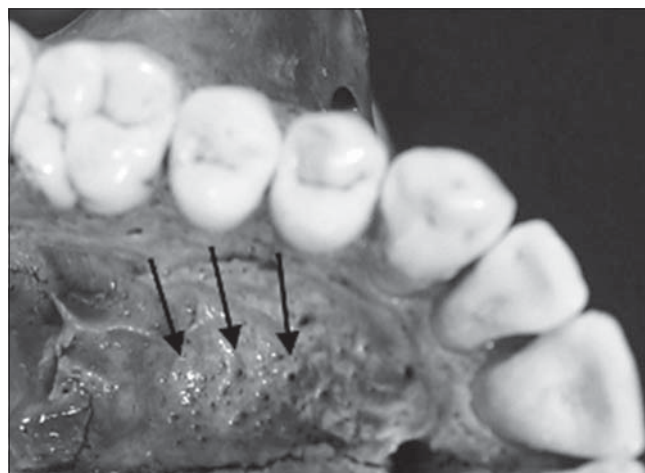
and MSA nerves, or the plexus when the last nerve is absent.<sup>[5]</sup> Theoretically, this technique would be beneficial, because a bilateral AMSA nerve block technique supposedly anesthetizes 10 maxillary teeth extending from the second premolar of one side to the opposite side without causing anesthesia of the facial muscles, making it a great advantage in restorative dentistry.<sup>[5,11,12]</sup>

Fukayama *et al.*<sup>[11]</sup> and Lee *et al.*<sup>[12]</sup> evaluated the efficacy of this technique using the computer-assisted injection system (Wand®), but the percentages of pulpal anesthesia obtained were questionable. Other studies have reported its application in periodontal surgery but using the conventional syringe instead of the computer-assisted injection system. The benefits are excellent hemostatic control of palatal soft tissue, avoiding collateral facial anesthesia and fewer cumulative injections.<sup>[13,14]</sup>

Due to few studies about this technique in literature, the aim of our study is to determine the success rates of pulpal anesthesia with the AMSA nerve block technique using the conventional syringe (carpule® type).

## MATERIALS AND METHODS

In this controlled clinical study, 30 Caucasians patients (16 men and 14 women), with an average age of 22 years-old (range, 21-25 years-old), belonging to the School of Dentistry of Los Andes University (Santiago, Chile), were selected. During the selection of patients, the following exclusion criteria were established: presence of systemic pathologies that contraindicate local anesthetics with vasoconstrictors, pregnancy, use of medications that alter pain perception, active orthodontic treatment, extractions,

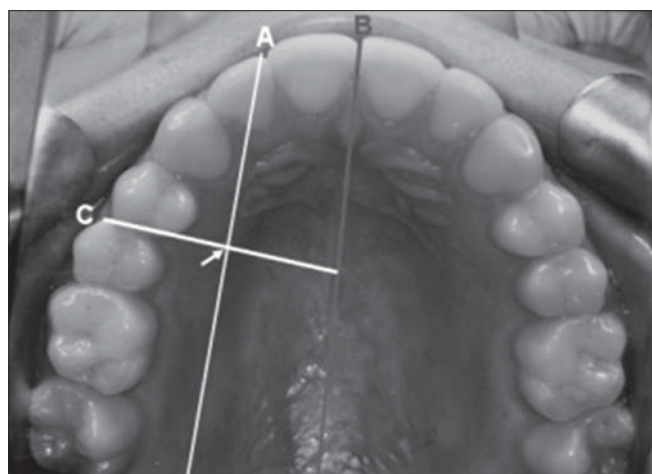


**Figure 2:** Palatal nutrient channels (arrows)

fixed prostheses, extensive fillings, and/or endodontic treatment in the experimental teeth (maxillary central incisor, lateral incisor, canine, and first and second premolars). All this information was obtained through a written questionnaire and clinical examination. This study was approved by the ethics committee of the School of Dentistry (Los Andes University), and patients voluntarily decided to participate in the study by signing the written informed consent.

The 30 patients received an AMSA nerve block on one side of the maxilla randomly selected using the conventional syringe (carpule® type, Hu-Friedly), 1 ml of lidocaine 2% with epinephrine 1:100,000 (Octocaine100, novocol pharmaceutical) was injected to all patients. All injections were given by the same investigator.

The teeth that were tested are, the maxillary central incisor, lateral incisor, canine, and first and second premolars of the side previously chosen. The mandibular canine was used as the non-anesthetized control tooth to ensure that the pulp tester was operating adequately during the study. At the beginning of each appointment and before any injections were given, the experimental teeth and control canine were tested with the pulp tester (Sybron Endo, vitality scanner) to record baseline vitality. After isolation with cotton rolls, the topical anesthetic (benzocaine 20%; Alpha dental) was applied to the tip of the pulp tester, which was placed midway between the gingival margin and the incisal or occlusal border of the tooth to be tested. The current rate was set on the pulp tester at 25 seconds to increase from no output (0) to the maximum output (80).



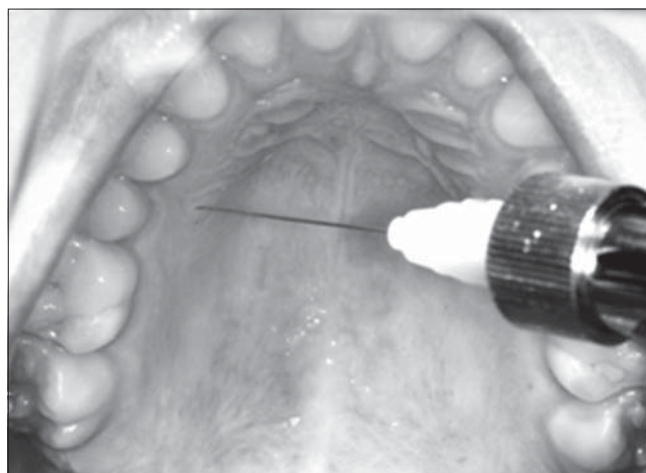
**Figure 3:** Injection site (arrow), halfway along an imaginary line (a) connecting the mid-palatal suture (b) to the free gingival margin (c)

To establish the injection site on the palate, the parameters described in the original technique by Friedman and Hochman were followed.<sup>[5]</sup> The AMSA injection site was centered halfway between the midpalatine raphe and the gingival margin of the first and second premolars [Figure 3]. A cotton-tip applicator was used to apply the topical anesthetic (benzocaine 20%; Alpha dental) at the injection site for a minute.

The injection was given with a 30-gauge needle, 22 mm (Terumo dental needle). The needle with the bevel against the bone was oriented at an angle of 45°. Then slowly the needle penetrated the palatal mucosa to establish contact with the palatal bone, to deposit 1 ml of anesthetic solution (Lidocaine 2% with epinephrine 1:100,000; Octocaine100, pharmaceutical novocol) in three minutes [Figure 4].

The anesthetic success was monitored with the electric pulp tester (Sybron Endo, vitality scanner), and we followed the protocol established by Lee *et al.*<sup>[12]</sup> in their study. A minute after the AMSA injection, pulp test readings were obtained for the first and second premolars. At two minutes, the canine was tested. At three minutes, the lateral and central incisors were tested. At four minutes, the mandibular control canine was tested. The testing continued in four-minute cycles for a period of an hour. No response from the subject to the maximum output (no response at the 80 reading) of the pulp tester was used as the criterion for pulpal anesthesia. Anesthetic success only considers when two consecutive 80 readings occur at some point over an hour.

The induction time (time it takes to succeed anesthetic) and the duration of anesthetic success was also registered. Additionally, we verify that there was



**Figure 4:** Execution of the technique

anesthesia in the palatal soft tissue, upper lip, and the surface of the face.

## RESULTS

Thirty adult patients participated in this study, 16 men and 14 women with an average age of 22 years- old (range, 21-25 years- old). All the patients received an AMSA nerve block on one side of the maxilla randomly selected using the conventional syringe (carpule® type, Hu-Friedly), 1 ml of lidocaine 2% with epinephrine 1:100,000 (Octocaine100, novocol pharmaceutical) was injected to all patients. The anesthetic success of the AMSA nerve block technique using conventional syringe is presented in Table 1. Successful pulpal anesthesia ranged from 16 to 66% in the experimental teeth. The anesthetic induction times ranged from 6 to 12 minutes and the duration of pulpal anesthesia ranged between 23-40 min [Table 1].

All the subjects obtained palatal soft tissue anesthesia, extending from the central incisor to the mesial of the first molar, never crossing the midline. No patient obtained pulpal anesthesia from the second premolar to the central incisor and facial anesthesia. While, in eight patients (26.7%) had no anesthetic success in any of the experimental teeth. No severe pain was recorded during the administration of the local anesthetic in the palate. Any complications or adverse reactions during and/or after completion of the anesthetic technique were neither observed nor reported by the patients involved.

## DISCUSSION

The main theoretical advantage of this AMSA nerve block is that it reduces the number of injections and the quantity of anesthetic solution administered in

**Table 1: Percentages of anesthetic success (two consecutive no response at the 80 reading of the pulpal tester), mean anesthetic induction time (min) and mean anesthetic duration time (min) for every experimental tooth with AMSA nerve block**

Tooth	Percentage of anesthetic success	Anesthetic induction	Anesthetic duration
Second premolar	66,6% (20/30)	6 min	40 min
First premolar	40% (12/30)	7 min	35 min
Canine	60% (18/30)	5 min	33 min
Lateral incisor	23,3% (7/30)	8 min	26 min
Central incisor	16,7% (5/30)	8 min	23 min

comparison with the conventional supraperiosteal infiltrative anesthesia applied in multiple injections for each tooth.<sup>[5]</sup> In addition, it would be ideal to use in cosmetic dentistry as it does not cause numbness of the lip and face.<sup>[5,12,13]</sup>

However, our results show pulpal anesthetic success rates (two readings in 80 of the pulp tester) ranging from 16.7 to 66.6%. Failure to respond to 80 (maximum output of the pulp tester) was the criterion for pulpal anesthesia based on clinical studies by Dreven *et al.*<sup>[15]</sup> and Certosimo *et al.*<sup>[16]</sup> because their studies showed that the readings below 80 resulted in pain during operatory procedures.

In our study, the anesthetic blockade of the five experimental teeth was not obtained in any of our patients as expounded by Friedman and Hochman.<sup>[5]</sup> The duration of pulpal anesthesia was gradually declining during the 60 minutes; we cannot confirm the clinical impression of the authors that there is duration of pulpal anesthesia for 60 minutes. On the other hand, we can say that there is no anesthesia of the lips and facial muscles of expression.

Studies of this technique using a computer-controlled system, which was made by Fukayama *et al.*,<sup>[11]</sup> obtained anesthetic success in the range of 42-86% and 35-58% by Lee *et al.*<sup>[12]</sup> In our study, the success rates were significantly low with the use of conventional syringe (17-66%). The low success rates of conventional syringe system could be due to the superiority of the computer-controlled system to inject the anesthetic solution with a controlled and continuous flow.<sup>[12]</sup> With the conventional syringe system, the flow pressure depends on the operator although all injections were performed by the same investigator. The anesthetic flow cannot be controlled as precisely as with the computer-controlled system. Lee *et al.*<sup>[12]</sup> speculated that the injection with the computer-controlled system creates an improved pressure gradient environment for diffusion of the anesthetic solution through the numerous nutrient channels of the palatal vault.

In the case of the low anesthesia percentages, the central and lateral incisor could be attributed to an increased presence of the MSA nerve in the patients of the study. Thus, in such cases, the MSA nerve is anesthetized, and not the ASA nerve, due to its distance from the puncture site. Anatomical studies on dissection of cadavers have found the presence of the MSA nerve in the range of 30-72%, and when

it is absent, its innervation is supplied from a plexus formed by the ASA and the posterior superior alveolar nerves.<sup>[1,8-10]</sup> The exact role of the absence of the MSA nerve in the AMSA nerve block success is not known.

This technique is described by its authors as a nerve block. Malamed<sup>[17]</sup> defines a nerve block when the solution is deposited in the vicinity of the main nerve trunk, so that the anesthetic should be placed close to the ASA or MSA nerves, resulting in high rates of anesthetic success, but we saw that this did not happen because the solution is deposited on the palatine process of the maxilla for its diffusion, searching the terminal branches of the alveolar nerves. So based on our clinical observations, it is more of an infiltrative technique than a nerve block.

On the other hand, the reduction of multiple injections reduces the total amount of delivered vasoconstrictor and may be useful for cardiovascular-compromised patients that required maxillary anesthesia. For maxillary mucogingival procedures, the AMSA nerve block with palatal delivery of anesthetic with vasoconstrictor provides excellent hemostasis and reduces the need for multiple re-injections to obtain hemostatic control during periodontal procedures or graft harvest.<sup>[13,14]</sup>

One of the main disadvantages of the AMSA nerve block is that palatal injections are generally considered the most painful injections.<sup>[18]</sup> Wahl *et al.*<sup>[19]</sup> showed that palatal injections caused significantly more pain than other intraoral injections, probably due to the result of pressure. However, in our study, severe pain during the technique was not reported, possibly due to the prior application of topical anesthetic and the slow and controlled injection of the anesthetic solution. Other problem of this technique is that it is restricted only for the five anterior maxillary teeth and procedures such as periodontal surgeries require anesthesia of the full maxillary arch that may complement with another technique.

A second technique that would produce anesthesia from the central incisor to second premolar with a single injection is the infraorbital nerve block (IONB). Having the advantage that the injection site is not in the palate, it is therefore less painful, but with the inconvenience of causing facial numbness. Karkut *et al.*<sup>[20]</sup> in their study found that IONBs were ineffective in providing profound pulpal anesthesia of the maxillary central incisor (15% success rate) and lateral incisor (22% success rate). The pulpal

anesthesia success rate was 92% for the canine and 80% for first and second premolars. Pulpal anesthesia did not last for an hour in any of the teeth.<sup>[20]</sup> Moreover, Berbeich *et al.*<sup>[21]</sup> obtained similar results in 40 patients with IONB where pulpal anesthesia was ineffective in providing profound anesthesia of maxillary central and lateral incisors. Successful pulpal anesthesia of the canine and first and second premolars ranged from 75-92%.

These previously discussed studies occupy anesthetic evaluation protocols similar to those in our study, but getting better rates of success with the IONB. Although Corbett *et al.*<sup>[22]</sup> conducted a study to compare the efficacy of the AMSA nerve block with that of the IONB in achieving pulpal anesthesia in the anterior maxilla, anesthetic success was significantly greater with the AMSA nerve block than with the IONB in central and lateral incisors; however, anesthesia was achieved in only 42.9% of central incisors with the AMSA nerve block. The authors observed a significantly greater number of anesthetic success episodes in the premolar and canine teeth after IONB. The incidence of subjective lip numbness was 100% after IONB and 14.3% after AMSA nerve block. There was no significant difference in the rates of injection discomfort between the two techniques. The authors conclude that the IONB has better success rates of pulpal anesthetic, but AMSA has the advantage that the same injection has the same potential to provide pulpal anesthesia from central incisor to second premolar. In addition, the AMSA nerve block anesthetize palatine tissue without causing facial numbness.

The shape of the palate was not recorded but we believe that there was a homogeneous distribution between the deep and shallow palate in this study. Because this anesthetic technique was applied to young population, the results may not be applied to children or the elderly.

## CONCLUSION

Because of the unpredictable anesthetic success of the experimental teeth and variable anesthesia duration, the technique is disadvantageous for clinical application as the first choice, counting with other techniques that have greater efficacy in the maxilla. However, it may be clinically useful in restorative dentistry (by not anesthetizing the facial muscles and not affecting the smile line) and in periodontal surgery

due to the excellent hemostatic control in palatal soft tissues.

## REFERENCES

- Blanton PC, Roda RS. The anatomy of local anesthesia. *J Cal Dent Assoc* 1995;23:55-69.
- Malamed SF, Trieger NT. Intraoral maxillary nerve block: An anatomical and clinical study. *Anesth Prog* 1983;30:44-8.
- Gomolka KA. The AMSA block: Local anesthesia without collateral numbness. *CDS Rev* 2000;93:34.
- Haas DA. An update on local anesthetics in dentistry. *J Can Dent Assoc* 2002;68:546-51.
- Friedman M, Hochman M. The AMSA injection: A new concept for local anesthesia of maxillary teeth using a computer-controlled injection system. *Quintessence Int* 1998;29:297-303.
- Roda RS, Blanton PL. The anatomy of local anesthesia. *Quintessence Int* 1994;25:27-38.
- Olsen NH, Teuscher GW, Vehe KL. A study of the nerve supply to the upper anterior teeth. *J Dent Res* 1955;34:413-20.
- Fitzgerald MJT, Scott JH. Observations on the anatomy of the superior dental nerves. *Br Dent J* 1958;104:205-8.
- McDaniel WL. Variations in nerve distributions of the maxillary teeth. *J Dent Res* 1956;35:916-21.
- Heasman PA. Clinical anatomy of the superior alveolar nerves. *Brit J Oral Maxillofac Surg* 1984;22:439-47.
- Fukayama H, Yoshikawa F, Kohase H, Umino M, Susuki N. Efficacy of anterior and middle superior alveolar (AMSA) anesthesia using a new injection system: The Wand. *Quintessence Int* 2003;34:537-41.
- Lee S, Reader A, Nusstein J, Beck M, Weaver J. Anesthetic efficacy of the anterior middle superior alveolar (AMSA) injection. *Anesth Prog* 2004;51:80-9.
- Holtzclaw D, Toscano N. Alternative anesthetic technique for maxillary periodontal surgery. *J Periodontol* 2008;79:1769-72.
- Acharya AB, Banakar C, Rodrigues SV, Nagpal S, Bhadbhade S, Thakur SL. Anterior middle superior alveolar injection is effective in providing anesthesia extending to the last standing molar in maxillary periodontal surgery. *J Periodontol* 2010;81:1174-9.
- Dreven L, Reader A, Beck M, Meyers W, Weaver J. An evaluation of the electric pulp tester as a measure of analgesia in human vital teeth. *J Endod* 1987;13:233-8.
- Certosimo A, Archer R. A clinical evaluation of the electric pulp tester as an indicator of local anesthesia. *Oper Dent* 1996;21:25-30.
- Malamed SF. *Handbook of Local Anesthesia*, 5<sup>th</sup> ed. St. Louis: Mosby; 2004. p. 213-6.
- Hutchins HS, Young FA, Lackland DT, Fishburne CP. The effectiveness of topical anesthesia and vibration in alleviating the pain of oral injections. *Anesth Prog* 1997;44:87-9.
- Wahl MJ, Schmitt MM, Overton DA, Gordon MK. Injection pain of bupivacaine with epinephrine vs. prilocaine plain. *J Am Dent Assoc* 2002;133:1652-6.
- Karkut B, Reader A, Drum M, Nusstein J, Beck M. A comparison of the local anesthetic efficacy of the extraoral versus the intraoral infraorbital nerve block. *J Am Dent Assoc* 2010;141:185-92.
- Berberich G, Reader A, Drum M, Nusstein J, Beck M. A prospective, randomized, double-blind comparison of the anesthetic efficacy of two percent lidocaine with 1:100,000 and 1:50,000 epinephrine and three percent mepivacaine in the intraoral, infraorbital nerve block. *J Endod* 2009;35:1498-504.
- Corbett IP, Jaber AA, Whitworth JM, Meechan JG. A comparison of the anterior middle superior alveolar nerve block and infraorbital nerve block for anesthesia of maxillary anterior teeth. *J Am Dent Assoc* 2010;141:1442-8.

**How to cite this article:** Velasco I, Soto R. Anterior and middle superior alveolar nerve block for anesthesia of maxillary teeth using conventional syringe. *Dent Res J* 2012;9:535-40.

**Source of Support:** Nil. **Conflict of Interest:** None declared.