

# Overexpression of COX-2 in oral squamous cell carcinoma patients undergoing chemoradiotherapy

Departments of Oral and Maxillofacial Surgery, <sup>1</sup>Pathology, <sup>2</sup>Radiotherapy, CSM Medical University (erstwhile King George Medical University), Lucknow, India

Shadab Mohammad, Hari Ram, Prem Narayan Gupta, Nuzhat Husain<sup>1</sup>, M.L.B. Bhatt<sup>2</sup>

## ABSTRACT

**Aims and Objectives:** To evaluate the prognostic significance of cyclooxygenase-2 (COX-2) overexpression in oral squamous cell carcinoma (OSCC) patients undergoing chemoradiation therapy. Purpose of the study was to determine whether COX-2 could be used as a diagnostic and prognostic index in OSCC. **Materials and Methods:** Forty-four patients of SCC were included in the present study and immunohistochemical examination was done for COX-2 expression. Negative and <5% COX-2 positivity were taken as negative expression and ≥5% COX-2 positivity as positive expression group. ≥30% COX-2 positivity was taken as overexpressed group and <30% COX-2 positivity was taken as underexpressed group. All the data were analyzed statistically. **Results:** COX-2 overexpression in OSCC was found in 15.90% cases. The proportion of COX-2 overexpression was higher in patients with large tumor size than in those with small tumor size. The proportions of COX-2 positive expression cases were higher with cervical lymph node metastasis. Negative COX-2 expression was higher in well-differentiated OSCC and positive expression was higher in moderately differentiated tumors. COX-2 underexpressed cases had better response to chemoradiation therapy as compared to cases with overexpressed COX-2. **Conclusion:** COX-2 expression in OSCC can be used as a prognostic marker. Studies with large sample size and long-term follow-up are required to find out the exact role and prognostic significance of COX-2 expression in OSCC.

**Key words:** COX-2 enzyme, immunohistochemistry, oral squamous carcinoma, radiochemotherapy

### Address for correspondence:

Dr. Prem Narayan Gupta,  
Departments of Oral and  
Maxillofacial Surgery, CSM  
Medical University, Lucknow –  
226003, Uttar Pradesh, India.  
E-mail: drpremgupta@gmail.  
com

## INTRODUCTION

Despite the recent advances made in diagnosis and the surgical, radiotherapeutic and chemotherapeutic treatment of head and neck squamous cell carcinoma (HNSCC), the 5-year survival rate has improved only marginally.<sup>[1]</sup> Failure to primary therapy is often caused by unresectable lesions, recurrence of regional lymph node metastasis and a high incidence of second primary

tumors caused by field cancerization and multistep carcinogenesis.<sup>[2,3]</sup> The identification of new diagnostic and prognostic factors and setting of novel therapeutic targets is thus necessary to improve the 5-year survival rates in oral squamous cell carcinoma (OSCC).

Cyclooxygenases (COXs) are the rate-limiting enzymes for high output production of prostanoids (prostaglandins, thromboxanes) from arachidonic acid,<sup>[4]</sup> which can play an important role in various pathophysiological conditions.

In recent years, overexpression of COX-2 has been reported in various cancers, including those arising from colon,<sup>[5]</sup> stomach,<sup>[6]</sup> breast,<sup>[6,7]</sup> lung,<sup>[8]</sup> esophagus,<sup>[9]</sup> pancreas,<sup>[10]</sup> bladder,<sup>[11]</sup> prostate<sup>[12]</sup> and in OSCC.<sup>[7,13-15]</sup>

COX-2 has been paid attention because it could play an

Access this article online	
	<b>Quick Response Code:</b>
	<b>Website:</b> www.njms.in
<b>DOI:</b> DOI:10.4103/0975-5950.85848	

important role in initiation and progression of carcinomas of various organs. Enhanced synthesis of prostaglandins, which results from upregulation of COX-2, increases the proliferative activity of neoplastic cells, cancer invasiveness and metastasis,<sup>[16]</sup> promotes angiogenesis<sup>[17]</sup> and inhibits immune surveillance<sup>[18]</sup> and apoptosis.<sup>[19]</sup>

Available evidences suggest that COX-2 is related to carcinogenesis. However, only limited information is available on COX-2 expression in OSCC and the relation of tumor size, regional lymph node metastasis and chemoradiation response outcome.

In the present study, we immunohistochemically examined COX-2 and its relation to various clinicopathological variables (tumor size, lymph node involvement, histological grade of tumor) and chemoradiation response. The purpose of this study was to determine whether COX-2 could be used as a diagnostic and prognostic index in OSCC.

## MATERIALS AND METHODS

A total of 44 patients of OSCC were included in the present study. The patients were taken randomly irrespective of their age, sex, caste and creed. The patients were previously untreated and with normal hemogram, renal and hepatic function. Patients with concurrent malignancy, chronic diseases (diabetes mellitus, renal disease, hepatitis, HIV, etc.), recurrence cases of SSC and those who refused to participate in the study were excluded from the study. The study protocol was explained to the patients in detail, and then written informed consent of the patients was obtained.

Orthopantomogram (OPG), posteroanterior view of chest (PA chest), computerized tomography scan (GTCT/e spiral single slice) of face including neck and high-resolution ultrasonography (log c C5/GE) of neck were done.

The biopsy specimens were taken from the lesion including the normal marginal tissue, under local anesthesia and placed in 10% formalin solution. Paraffin-embedded formalin-fixed tissues were processed and 4–5 µm-thick sections were prepared by routine method. H and E stained sections were evaluated for histological diagnosis and histological grade of tumor. The expression of COX-2 in the above tissue was evaluated by immunohistochemistry (IHC).

Sections were immunostained with primary rabbit monoclonal antibody for COX-2 (BioGenex Life Sciences Pvt. Ltd., India). Sections were incubated overnight at 4°C with primary antibody in a humid chamber. The following day, sections were stained using labeled horse

radish peroxidase (HRP) secondary antibody solution (Mach-4 polymer detection kit, Diagnostic Biosystem, India). Bound peroxidase was revealed using 0–5% 3-diaminobenzidine tetrahydrochloride (DAB) in TBS. Sections were dehydrated, cleared and mounted. COX-2 positive cells which showed staining for IHC were subjected to manual counting. Percentage positive cells in individual cases were counted in five high-power fields in hot spots on slide.

The stained sections were observed for positivity of COX-2 expression. The positivity was expressed in terms of percentage of tumor cells positive for COX-2 expression.

-ve staining	-	
+ve staining	Grade 1	<5%
	Grade 2	5–30%
	Grade 3	>30

Negative and <5% COX-2 positivity were taken as negative expression and ≥5% COX-2 positivity as positive expression group. The >30% COX-2 positivity was taken as overexpressed [Figure 1] group and ≤30% COX-2 positivity was taken as underexpressed [Figure 2] group.

IHC was done in 44 cases for COX-2 expression. Seven patients were in Stage I and II and were managed by surgical method, and therefore excluded from the study. Chemoradiation was started in 37 patients, but 8 patients defaulted and did not complete their chemoradiation and 1 patient showed reaction to chemotherapy. Therefore, they were excluded from the study. Remaining 28 patients completed their chemoradiation and were evaluated for response.

Patients were given radiotherapy with cobalt-60 (Theratron 78°C, AECL, Ottawa, Canada) teletherapy machine. A dose of 70 Gy was given in 7 weeks as 2 Gy fractions, 5 days a week, by shrinking field technique. Patients were given chemotherapy synchronous with radiotherapy starting from day 1 of the radiation treatment. Chemotherapy was given in the form of cisplatin, 30 mg/m<sup>2</sup> intravenous weekly, with adequate hydration, antiemetics and diuresis. A total of seven cycles of weekly chemotherapy was planned.

### Assessment of response

#### *Complete response*

Disappearance of all tumors at 4 weeks after completion of treatment.

#### *Partial response*

Tumor shrinkage less than 50% of the initial size or tumor increase not more than 25% of the initial size at 4 weeks after completion of treatment.

**No response**

Tumor size increase of more than 25% of the initial size or appearance of new lesions at 4 weeks after completion of treatment.

Data were analyzed using suitable statistical analysis.

**RESULTS**

In our study, the most common age group for occurrence of OSCC of oral cavity was 40–60 years (59.10%), and males (70.45%) definitely outnumbered females.

Negative expression (<5% COX-2 positivity) was higher in small tumor size (T<sub>1</sub> and T<sub>2</sub>); as the tumor size increases (T<sub>3</sub> and T<sub>4</sub>), the percentage of negative-expressed sample decreases and thus shows an inverse relation. Positive expression (≥5% COX-2 positivity) was less in small tumor size (T<sub>1</sub> and T<sub>2</sub>); as the tumor size increases (T<sub>3</sub> and T<sub>4</sub>), the percentage of positive-expressed sample increases and thus shows a direct relation [Table 1 and Figure 3]. The difference between the above was significant.

Number of positive-expressed cases in N<sub>0</sub> was 9 (64%) and in N<sub>1</sub> 18 (90%), in N<sub>2</sub> 7 (87.5%) and in N<sub>3</sub> nil. Overall, nodal metastasis was present in 34 (77.27%) COX-2 positive-expressed cases [Table 2]. Negative expression (<5%) was higher in well-differentiated tumor and positive expression (≥5%) was higher in moderately differentiated tumor.

Underexpressed (<30%) cases showed better response to chemoradiation as compared to cases with overexpressed COX-2 [Table 3].

**DISCUSSION**

Highest percentage of SSC was observed in the age group of 41–50 and 51–60 years (29.55% in both) followed by 61–70 years (18.18%), and males outnumbered females [31 (70.45%) and 13 (29.55%), respectively]. This is consistent with the finding of Khandekar<sup>[20]</sup> who observed that the most common age groups of occurrence of OSCC were 51–60 years (43.8%) and 41–50 years (22.5%), and males and females formed

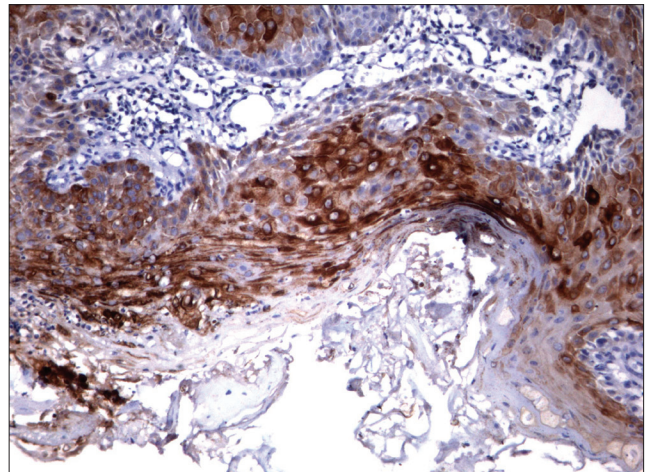


Figure 1: COX-2 overexpression

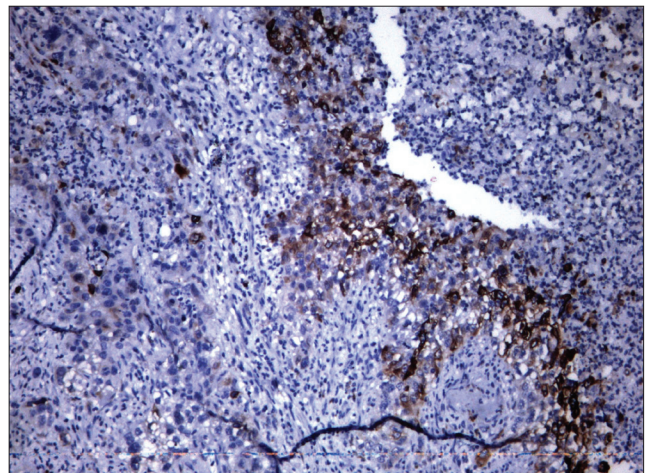


Figure 2: COX-2 underexpression

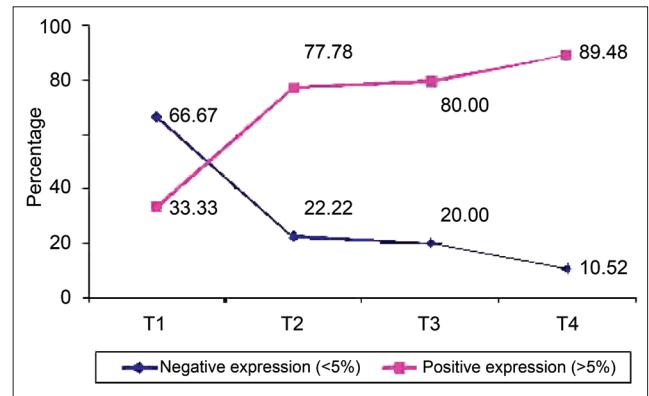


Figure 3: Association of tumor size ("T" stage) and COX-2 expression

**Table 1: The association of tumor size ("T" stage) and COX-2 positive expression**

COX-2 positivity	T <sub>1</sub>		T <sub>2</sub>		T <sub>3</sub>		T <sub>4</sub>		Total	
	n	%	n	%	n	%	n	%	n	%
Negative	01	16.77	02	22.22	02	20.00	02	10.52	07	15.90
< 5%	03	50.00	-	-	-	60.00	-	-	03	6.80
5–30%	02	33.33	05	55.56	06	-	14	73.68	27	61.13
> 30% overexpressed	-	-	02	22.22	02	20.00	03	15.78	07	15.90
Total	06	100.00	09	100.00	10	100.00	19	100.00	44	100.00

**Table 2: The association of cervical lymph node and COX-2 positivity expression**

COX-2 positivity	N <sub>0</sub>		N <sub>1</sub>		N <sub>2</sub>		N <sub>3</sub>		Total	
	n	%	n	%	n	%	n	%	n	%
<5%	05	35.62	02	10.00	01	12.50	02	100.00	10	22.73
≥5%	09	64.28	18	90.00	07	87.50	-	-	34	77.27
Total	14	100.00	20	100.00	08	100.00	02	100.00	44	100.00

**Table 3: The association of chemoradiation response and COX-2 positivity**

COX-2 positivity	No response		Partial response		Total	
	n	%	n	%	n	%
Overexpression ≥30%	04	33.33	02	12.50	06	21.42
Underexpression <30%	08	66.67	14	87.50	22	78.58
Total	12	100.00	16	100.00	28	100.00

61.3% and 38.7%, respectively. There was considerable difference in Indian and Western populations regarding exposure of carcinogens in males and females. Smoking, alcohol intake and tobacco chewing are less prevalent in females than males in India. However, due to increasing urbanization and changing lifestyle pattern, this trend may change in the future.

COX-2 staining was positive in 37 patients (84.09%) and negative in 7 patients (15.91%) in our study. These results are close to that reported by Sudbo,<sup>[7]</sup> who showed 88% COX-2 positivity in OSCC patients, Goto,<sup>[21]</sup> who showed 97.3% immunostaining in SCC of hypopharynx, and Soland<sup>[22]</sup> who showed 98% COX-2 staining in OSCC. The immunoreactivity for COX-2 was cytoplasmic in cancer cells and it was observed as well in stromal cells including macrophages and some neutrophils, fibroblasts and vascular endothelial cells. These findings suggest that the immunoreactivity for COX-2 may be modulated by interaction of stromal cells with the cancer cells in the process of destructive invasion.

Overexpression (>30%) was observed in 7 (15.90%) cases, while underexpression (≤30%) in 37 (84.10%) cases. COX-2 overexpression was higher in larger tumor size (T<sub>3</sub> and T<sub>4</sub>) than smaller tumor size (T<sub>1</sub> and T<sub>2</sub>). Our results are very similar to the report of Shigeto Itoh<sup>[13]</sup> who found that 13.9% cases were overexpressed and the rest 86.1% cases were underexpressed. The small difference in COX-2 overexpression was seen because we considered ≥30% as overexpression while Shigeto Itoh<sup>[13]</sup> considered >34.6% (mean value of their study) as overexpression.

Negative expression (<5% positivity) was higher in small tumor size (T<sub>1</sub> and T<sub>2</sub>), and as the tumor size increases (T<sub>3</sub> and T<sub>4</sub>), the percentage of cases in this group decreases and thus shows as inverse relation. Positive-expressed COX-2 (≥5%) cases were less in small

tumor size (T<sub>1</sub> and T<sub>2</sub>), and as the tumor size increases (T<sub>3</sub> and T<sub>4</sub>), the percentage of cases in this group increases and shows a direct relation. These results have close similarity with the findings of Kazunari Sakurai,<sup>[14]</sup> who showed that increased tumor size was associated with an increase in COX-2 expression. Cao<sup>[23]</sup> reported the high expression of COX-2 in OSCC was related to tumor size, lymph node metastasis, and the histological grade of tumor. Goto<sup>[24]</sup> found that COX-2 expression has a tendency for higher values in T<sub>3</sub> and T<sub>4</sub> tumor size than in T<sub>1</sub> and T<sub>2</sub> tumor size in hypopharyngeal SCC. Nozo<sup>[25]</sup> reported the strong expression of COX-2 with tumor progression and poor differentiation in oesophagus SCC.

Enhanced synthesis of prostaglandins which results from upregulation of COX-2 increases the proliferative activity of neoplastic cells, promotes angiogenesis, enhances invasiveness and inhibits immune surveillance and apoptosis. These mechanisms may be responsible for the positive expression of COX-2 in large tumor size (T<sub>3</sub> and T<sub>4</sub>) samples and promote the hypothesis that expression of COX-2 increases with the increase in tumor size. Upregulation of COX-2 is related to neoangiogenesis in tumor mass which is related to tumor growth and formation of metastasis seen to one of the possible factors for higher expression of COX-2 in large-size (T<sub>3</sub> and T<sub>4</sub>) tumors.

In our study, nodal metastasis was present in 30 cases. Out of these, COX-2 positive expression was seen in 25 (83.33%) cases while negative expression was seen only in 5 (16.67%) cases. The number of positive-expressed cases in N<sub>0</sub> was 9 (64%), in N<sub>1</sub> 18 (90%), in N<sub>2</sub> 07 (87.5%) and in N<sub>3</sub> it was nil. The results of our study are similar to the findings of Shigeto Itoh<sup>[13]</sup> who found that COX-2 positive expression was closely associated with local recurrence and lymph node involvement in SCC of oral cavity, although it showed no correlation with the extent of lymph node involvement. Kazunari Sakurai<sup>[14]</sup> showed that COX-2 expression in primary lesion was significantly higher in cases with lymph node metastasis than in those without lymph node metastasis and expression of COX-2 was associated with poor outcome. Cao<sup>[23]</sup> showed that expression of COX-2 in OSCC was related to lymph node metastasis, tumor size and histological grade. The above studies support our results regarding COX-2 positive expression and nodal metastasis.

Negative expression (<5%) was higher in well-differentiated tumors and positive expression (≥5%) was higher in moderately differentiated tumors. There have been some ambiguous points with regard to relationship between COX-2 overexpression and histological grade of tumors. Jutta Renkonen<sup>[15]</sup> reported

that COX-2 overexpression was closely associated with the histological grade in SCC of tongue, and increased COX-2 expression was associated with differentiation of human squamous epithelium.<sup>[15]</sup> Shigeto Itoh<sup>[13]</sup> found no correlation between COX-2 expression and the histological grade of tumor.

Out of 28 patients, partial response to chemoradiation was seen in 16 patients and no response in 12 patients. COX-2 underexpressed cases showed better response to chemoradiation therapy as compared with the cases having overexpressed group. Our results are supported by the study of Nagaaki Terakado<sup>[25]</sup> who showed that COX-2 positive group shows no effective response for radiation therapy and COX-2 expressed cells show higher radiation resistance than non-expressed cells. Moreover, it was seen that COX-2 inhibiting drugs (celecoxib) potentiate the effect of chemoradiation,<sup>[25]</sup> hence agreement indirectly finding without study.

Chemoradiation therapy is one of the useful treatment modalities of head and neck cancer. Our results suggest that COX-2-overexpressed patients were more resistant to therapy as compared to underexpressed patients, therefore COX-2 expression in OSCC can be used as a prognostic marker. In near future, chemoradiation therapy combined with molecular targeting agents such as COX-2 should be further examined to improve therapy response.

## REFERENCES

- Von Dongen GA, Snow GB. Prospective for future studies in head and neck cancer. *Eur J Surg Oncol* 1997;23:485-91.
- Slaughter DP, Southwick SH, Smejkel W. Field cancerization in oral stratified squamous epithelium: clinical implications of multicentric origin. *Cancer* 1953;9:963-8.
- Lippman SM, Hong WK. Second malignant tumors in head and neck squamous cell carcinoma: The overshadowing threat for patients with early stage disease. *Int J Radiat Oncol Biol Phys* 1989;17:691-4.
- Vane JR, Mitchell JA, Appleton I, Tomlinson A, Bishop-Bailey D, Croxtall X, *et al.* Inducible isoforms of cyclooxygenase and nitric oxide synthase in inflammation. *Proc Natl Acad Sci U S A* 1994;91:2046-50.
- Kargman SL, O'Neill GP, Vickers PJ, Evans JF, Mancini JA, Jothy S. Expression of prostaglandin G/H synthase-1 and -2 protein in human colon cancer. *Cancer Res* 1995;55:2556-9.
- Ristimäki A, Honkanen N, Jankala H, Sipponen P, Harkonen M. Expression of cyclooxygenase-2 in human gastric carcinoma. *Cancer Res* 1997;57:1276-80.
- Sudbø J, Ristimäki A, Sondresen JE, Kildal W, Boysen M, Koppang HS, *et al.* Cyclooxygenase-2 (COX-2) expression in high-risk premalignant oral lesions. *Oral Oncol* 2003;39:497-505.
- Hida T, Yatabe Y, Achiwa H, Muramatsu H, Kozaki K, Nakamura S, *et al.* Increased expression of cyclooxygenase 2 occurs frequently in human lung cancers, specifically in adenocarcinomas. *Cancer Res* 1998;58:3761-4.
- Zimmermann KC, Sarbia M, Weber AA, Borchard F, Gabbert HE, Schror K. Cyclooxygenase-2 expression in human esophageal carcinoma. *Cancer Res* 1999;59:198-204.
- Tucker ON, Dannenberg AJ, Yang EK, Zhang F, Teng L, Daly JM, *et al.* Cyclooxygenase-2 expression is up-regulated in human pancreatic cancer. *Cancer Res* 1999;59:987-90.
- Shirahama T. Cyclooxygenase-2 expression is up-regulated in transitional cell carcinoma and its preneoplastic lesions in the human urinary bladder. *Clin Cancer Res* 2000;6:2424-30.
- Yoshimura R, Sano H, Masuda C. Expression of cyclooxygenase-2 in prostate carcinoma. *Cancer* 2000;89:589-96.
- Itoh S, Matsui K, Furuta I, Takano Y. Immunohistochemical study on over expression of cyclooxygenase-2 in squamous cell carcinoma of the oral cavity: Its importance as a prognostic predictor. *Oral Oncol* 2003;39:829-35.
- Sakurai K, Urade M, Noguchi K, Hashitani S, Takaoka K, Segawa E, *et al.* Prognostic significance of cyclooxygenase-2 and DNA topoisomerase II alpha expression in oral carcinoma. *Head Neck* 2007;29:1002-9.
- Renkonen J, Wolff H, Paavonen T. Expression of cyclo-oxygenase-2 in human tongue carcinoma and its precursor lesions. *Virchows Arch* 2002;440:594-7.
- Tsuji M, Kawano S, DuBois RN. Cyclooxygenase-2 expression in human colon cancer cells increases metastatic potential. *Proc Natl Acad Sci U S A* 1997;94:3336-40.
- Tsuji M, Kawano S, Tsuji S, Sawaoka H, Hori M, DuBois RN. Cyclooxygenase regulates angiogenesis induced by colon cancer cells. *Cell* 1998;93:705-16.
- Huang M, Stolina M, Sharma S. Non-small cell lung cancer cyclooxygenase-2-dependent regulation of cytokine balance in lymphocytes and macrophages: Upregulation of interleukin 10 and down-regulation of interleukin 12 production. *Cancer Res* 1998;58:1208-16.
- Tsuji M, DuBois RN. Alterations in cellular adhesion and apoptosis in epithelial cells overexpressing prostaglandin endoperoxide synthase 2. *Cell* 1995;83:493-501.
- Khandekar SP, Bagdey PS, Tiwari RR. Oral Cancer and Some Epidemiological Factors: A Hospital Based Study. *Indian J Community Med* 2006;31:157-9.
- Goto R, Hoshikawa H, Fujii T, Indo K, Yoshino K, Imaida K, *et al.* Clinicopathological significance of cyclooxygenase-2 expression in hypopharyngeal squamous cell carcinoma. *Oncol Rep* 2008;19:645-50.
- Søland TM, Husvik C, Koppang HS, Boysen M, Sandvik L, Clausen OP. A study of phosphorylated ERK1/2 and COX-2 in early stage (T1-T2) oral squamous cell carcinomas. *J Oral Pathol Med* 2008;37:535-42.
- Cao XP, Zhang ST, Wu HY, Liu XJ, Zhang YY. Relationship between the expression of cyclooxygenase-2 and microvessel density in oral squamous cell carcinoma. *Hua Xi Kou Qiang Yi Xue Za Zhi* 2005;23:431-3.
- Nozoe T, Ezaki T, Kabashima A, Baba H, Maehara Y. Significance of immunohistochemical expression of cyclooxygenase-2 in squamous cell carcinoma of the esophagus. *Am J Surg* 2005;189:110-5.
- Terakado N, Shintani S, Yano J, Chunnan L, Mihara M, Nakashiro K, *et al.* Overexpression of cyclooxygenase-2 is associated with radioresistance in oral squamous cell carcinoma. *Oral Oncol* 2004;40:383-9.

**How to cite this article:** Mohammad S, Ram H, Gupta PN, Husain N, Bhatt M. Overexpression of COX-2 in oral squamous cell carcinoma patients undergoing chemoradiotherapy. *Natl J Maxillofac Surg* 2011;2:17-21.

**Source of Support:** Nil. **Conflict of Interest:** None declared.