

Z Rheumatol 2022 · 81:509–512
<https://doi.org/10.1007/s00393-022-01159-8>
Accepted: 25 December 2021
Published online: 19 May 2022
© The Author(s), under exclusive licence to
Springer Medizin Verlag GmbH, ein Teil von
Springer Nature 2022

Redaktion

Mike Oliver Becker, Zürich
Paula Hoff, Berlin
Axel Hueber, Erlangen
Frank Moosig, Neumünster



COVID-19 vaccination-related small vessel vasculitis with multiorgan involvement

Yunkyung Kim¹ · Jihun Kang² · Seung-Geun Lee³ · Geun-Tae Kim¹

¹ Division of Rheumatology, Department of Internal Medicine, Kosin University College of Medicine, Busan, Korea (Republic of)

² Department of Family Medicine, Kosin University Gospel Hospital, Kosin University College of Medicine, Busan, Korea (Republic of)

³ Division of Rheumatology, Department of Internal Medicine, Pusan National University Hospital, Pusan National University School of Medicine, Busan, Korea (Republic of)

Abstract

Since its first outbreak in 2019, coronavirus disease 2019 (COVID-19), caused by the severe acute respiratory syndrome coronavirus 2, has been ongoing, and the pandemic is not over yet. Vaccines developed against COVID-19 have been approved and widely used since 2020; however, vaccine safety concerns need to be addressed. Autoimmune symptoms have been reported as a side effect of many COVID-19 vaccines. In particular, several cases of COVID-19 vaccine-induced vasculitis have recently been reported. Herein, we report the case of a 77-year-old woman who developed small-vessel vasculitis with multiorgan involvement after receiving the BNT162b2 COVID-19 vaccine (Pfizer and BioNTech, New York City, NY, USA).

Keywords

COVID-19 · Vaccination · Vasculitis adverse effect

Introduction

The outbreak of coronavirus disease 2019 (COVID-19), caused by severe acute respiratory syndrome coronavirus 2 (SARS-CoV-2), in 2019 eventually led to a global pandemic situation. Vaccines developed against COVID-19 became available for use in late 2020, playing an important role in preventing the spread of COVID-19.

Among the several available COVID-19 vaccines, those approved by the United States Food and Drug Administration include the BNT162b2 vaccine (Pfizer and BioNTech, New York City, NY, USA), mRNA-1273 vaccine (Moderna Therapeutics, Cambridge, MA, USA), and AZD1222 vaccine (AstraZeneca and Oxford University, UK). Although the safety of these vaccines has been established in several trials, various side effects have been reported. These include symptoms related to autoimmune diseases such as inflammatory arthritis and alopecia, as well as

other autoimmune symptoms such as a skin rash [9, 13]. Vasculitis is a rare autoimmune disease that affects blood vessels, leading to tissue damage [15]. Its clinical features vary depending on the type of affected vessel. The possible causes of vasculitis include drugs, infection, and vaccination [15]. Herein, we report the case of a patient who developed small-vessel vasculitis with multiorgan involvement after receiving a COVID-19 vaccine.

Case

A 77-year-old woman visited the emergency room because of weakness and weight loss persisting for 1 month. She had received the second dose of the Pfizer-BioNTech COVID-19 vaccine 1 month previously, following which she experienced fever and myalgia. The symptoms persisted and were accompanied by anorexia, sweating, and weight loss. Furthermore,

The authors Jihun Kang and Geun-Tae Kim contributed equally to the manuscript.



Scan QR code & read article online

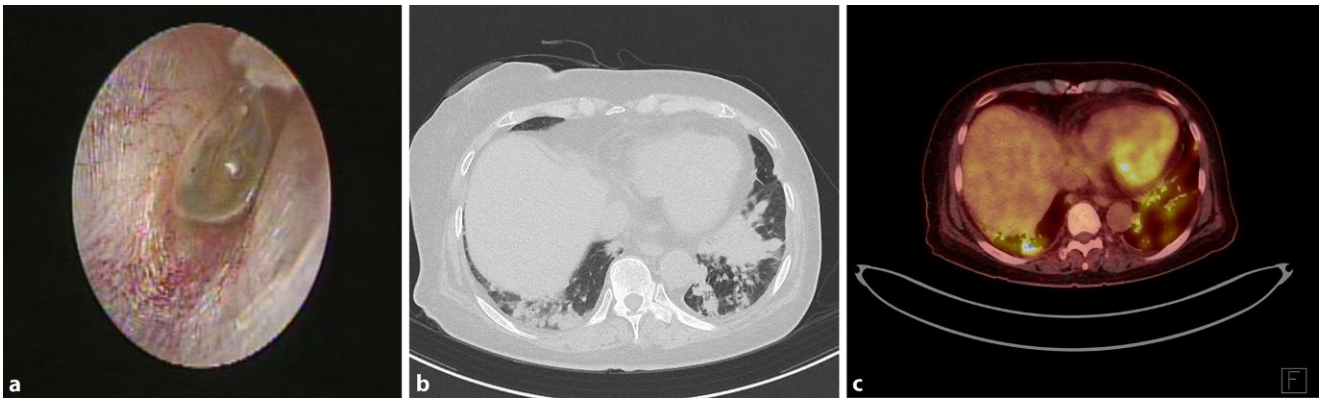


Fig. 1 ▲ a tympanogram of the left ear with effusion of tympanic membranes; b computed tomography (CT) image of the chest showing variable sized enhancing nodules in both lungs, with lower lung zone predominance; c positron-emission tomography/CT image

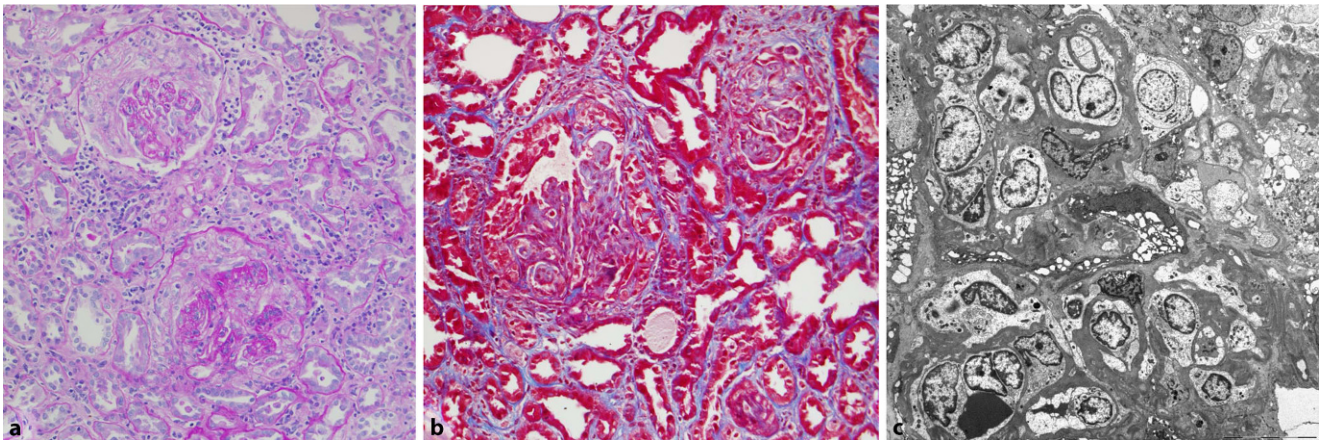


Fig. 2 ▲ a Light microscopy of the glomerulus (periodic acid-Schiff, $\times 200$); b Masson trichrome stain, $\times 200$; c electron microscopy, $\times 2000$

she presented with dyspnea, dizziness, and an ear fullness sensation. She had no specific medical history except for hypertension, and no other new drug history. Her vital signs were stable: blood pressure 120/80 mm Hg; pulse rate 71 beats/min; respiratory rate 21 breaths/min; and temperature 36.5°C. Physical examination revealed hyperemia in both eyes and livedo reticularis of the upper and lower extremities; however, joint swelling or tenderness was not observed. Blood test results revealed a white blood cell count of 15,000/ μL and markedly elevated high-sensitivity C-reactive protein levels at 38 mg/dL. Furthermore, she had azotemia accompanied by high creatinine levels (6 mg/dL); urinalysis showed 200 erythrocytes/ μL (3+) and 15 leukocytes/ μL . The spot urine protein-to-creatinine ratio was 4700 mg/g Cr, showing nephrotic-range proteinuria.

Regarding hyperemia in both eyes, slit-lamp examination was performed, showing conjunctivitis. Tympanometry was performed for the ear fullness sensation, and bilateral otitis media with effusion was confirmed (■ Fig. 1a).

Chest computed tomography (CT) imaging revealed enhancing nodules of variable sizes in bilateral lungs; the nodules were predominantly observed in the lower lung zone, suggesting atypical pneumonia or pulmonary metastasis (■ Fig. 1b). Empirical antibiotic therapy was initiated for managing pneumonia. Positron-emission tomography/CT was performed for the differential diagnosis of the pulmonary lesions; the findings showed inflammatory changes suggestive of vasculitis rather than metastasis (■ Fig. 1c).

Serologic test results revealed an elevated antinuclear antibody titer (1:320),

moderate anticentromere antibody titer, and low rheumatoid factor titer; renal biopsy was performed to determine the cause of severe proteinuria. Crescentic glomerulonephritis was observed using light microscopy (■ Fig. 2a, b); no immune complexes were observed using immunofluorescence and electron microscopy (■ Fig. 2c).

Small-vessel vasculitis was diagnosed on the basis of systemic symptoms (weight loss and fever), conjunctivitis, otitis media, livedo reticularis, lung nodules leading to the suspicion of vasculitis, and pauci-immune glomerulonephritis.

Methylprednisolone (1 mg/kg and day) was initiated for vasculitis management. Hemodialysis was performed to correct azotemia and acidosis. The patient exhibited gradual improvement in general and respiratory symptoms. One month after starting the treatment, follow-up chest

CT imaging revealed markedly decreased nodules; furthermore, the inflammatory marker levels had recovered to normal. However, the patient had to undergo permanent dialysis owing to several irreversible glomerular sclerotic changes. During steroid dose tapering, she was started on azathioprine. She remains well without recurrence.

Discussion

Although the safety of COVID-19 vaccines has been recognized and their use approved, several cases of autoimmune-related side effects of these vaccines have been reported [2, 4, 7, 9, 11, 12, 16]. Arthralgia is a common adverse reaction observed as a side effect of COVID-19 vaccines; however, inflammatory arthritis has rarely been reported. An et al. reported a case of reactive arthritis in a young woman [2]; further, Chan et al. reported a case of severe but self-limiting inflammatory polyarthritis occurring after the first dose of ChAdOx1 nCoV-19 vaccination in an elderly patient [7]. Similarly, Manzo et al. reported the case of a patient who developed polymyalgia rheumatica (PMR) after receiving the Pfizer vaccine [10]. The pathophysiological mechanism of PMR is thought to be similar to that of giant cell arteritis (GCA), which is a large-vessel vasculitis [14].

Vasculitis has been reported as an autoimmune-related side effect following COVID-19 vaccination. Reportedly, vasculitis accounted for 2.9 and 0.7% of the cutaneous side effects in patients receiving the first doses of Pfizer-BioNTech and Moderna (mRNA-1273) vaccines, respectively [11]. The disease was limited to cutaneous vasculitis in most patients [5, 6, 8]; however, organ involvement was reported in some cases. Shakoor et al. reported renally limited ANCA-associated vasculitis after Pfizer-BioNTech COVID-19 vaccine administration [16], whereas Mucke et al. reported immunoglobulin A vasculitis with arthritis, abdominal pain, and purpura after BNT162b2 vaccine administration [12].

Although vasculitis can be caused by drugs or viral infection, vaccination is considered a triggering factor [3]. Typically, several cases of vasculitis following in-

Kleingefäßvaskulitis mit Multiorganbeteiligung im Zusammenhang mit einer COVID-19-Impfung

Seit dem ersten Ausbruch im Jahr 2019 besteht die Coronaviruserkrankung 2019 (COVID-19) nun fort, verursacht durch SARS-CoV 2 (Schweres-akutes-respiratorisches-Syndrom-Coronavirus 2), und die Pandemie ist noch nicht vorbei. Gegen COVID-19 entwickelte Impfungen sind seit 2020 zugelassen und weit verbreitet im Einsatz, jedoch müssen Bedenken zur Sicherheit der Impfung angesprochen werden. Autoimmunsymptome wurden als eine Nebenwirkung vieler COVID-19-Impfungen angegeben. Insbesondere wurde vor Kurzem über verschiedene Fälle einer durch die COVID-19-Impfung induzierten Vaskulitis berichtet. In der vorliegenden Arbeit wird über den Fall einer 77-jährigen Frau berichtet, bei der eine Kleingefäßvaskulitis mit Multiorganbeteiligung nach Erhalt einer Pfizer-BioNTech-COVID-19-Impfung auftrat.

Schlüsselwörter

COVID-19 · Impfung · Vaskulitis als Nebenwirkung

fluenza vaccination have been reported [4]. Soriano et al. reported 10 cases of GCA/PMR after the administration of an influenza vaccine; most patients exhibited a genetic predisposition, such as harboring the *HLA-DRB1* gene, showing that both environmental and genetic factors play an important role in the pathogenesis of vasculitis [17].

The underlying mechanism of vasculitis occurring after COVID-19 vaccination remains to be elucidated. It has been postulated that host antibody production against the SARS-CoV-2 spike protein via molecular mimicry initiates immune complex formation [1]. Furthermore, it is speculated that the mRNA vaccine itself activates Toll-like receptors, thus increasing interleukin-6 production, which is possibly linked to the development of diseases such as PMR and vasculitis [10]. Further investigation of these interactions is warranted to determine the underlying pathophysiological processes.

Conclusion

We report the development of small-vessel vasculitis with multiorgan involvement following Pfizer-BioNTech COVID-19 vaccination in a female patient. Interestingly, the patient exhibited involvement of the lungs and kidneys, which are commonly affected by vasculitis, but did not exhibit the symptoms of skin involvement such as purpura. We believe that this case, with its radiological and histological findings,

will help in the management of vaccine-induced vasculitis in the future.

Corresponding address

Jihun Kang, MD MS

Department of Family Medicine, Kosin University Gospel Hospital, Kosin University College of Medicine
262, Gamcheon-ro, Seo-gu, 49267 Busan, Korea (Republic of)
josua85@naver.com

Geun-Tae Kim, MD PhD

Division of Rheumatology, Department of Internal Medicine, Kosin University College of Medicine
262, Gamcheon-ro, Seo-gu, 49267 Busan, Korea (Republic of)
gtah311@gmail.com

Declarations

Conflict of interest. Y. Kim, J. Kang, S.-G. Lee, and G.-T. Kim declare that they have no competing interests.

For this article no studies with human participants or animals were performed by any of the authors. All studies mentioned were in accordance with the ethical standards indicated in each case. For images or other information within the manuscript which identify patients, consent was obtained from them and/or their legal guardians.

References

1. Agmon-Levin N, Paz Z, Israeli E et al (2009) Vaccines and autoimmunity. *Nat Rev Rheumatol* 5:648–652
2. An Q-J, Qin D-A, Pei J-X (2021) Reactive arthritis after COVID-19 vaccination. *Hum Vaccines Immunother.* <https://doi.org/10.1080/21645515.2021.1920274>

3. Bologna JL, Schaffer JV, Cerroni L (2018) *Dermatologia*. Elsevier, Rio de Janeiro
4. Bonetto C, Trotta F, Felicetti P et al (2016) Vasculitis as an adverse event following immunization—systematic literature review. *Vaccine* 34:6641–6651
5. Bostan E, Gulseren D, Gokoz O (2021) New-onset leukocytoclastic vasculitis after COVID-19 vaccine. *Int J Dermatol*. <https://doi.org/10.1111/ijd.15777>
6. Cavalli G, Colafrancesco S, De Luca G et al (2021) Cutaneous vasculitis following COVID-19 vaccination. *Lancet Rheumatol*. [https://doi.org/10.1016/S2665-9913\(21\)00309-X](https://doi.org/10.1016/S2665-9913(21)00309-X)
7. Chan JEZ, Irimpen A (2021) Severe but self-limiting polyarthralgia with functional impairment following ChAdOx1 nCov-19 vaccination in an elderly recipient. *Vaccines* 9:1220
8. Dash S, Behera B, Sethy M et al (2021) COVID-19 vaccine-induced urticarial vasculitis. *Dermatol Ther*. <https://doi.org/10.1111/dth.15093>
9. El-Shitany NA, Harakeh S, Badr-Eldin SM et al (2021) Minor to moderate side effects of Pfizer-BioNTech COVID-19 vaccine among Saudi residents: a retrospective cross-sectional study. *IJGM* 14:1389
10. Manzo C, Natale M, Castagna A (2021) Polymyalgia rheumatica as uncommon adverse event following immunization with COVID-19 vaccine: A case report and review of literature. *Aging Med*. <https://doi.org/10.1002/agm2.12171>
11. McMahon DE, Amerson E, Rosenbach M et al (2021) Cutaneous reactions reported after Moderna and Pfizer COVID-19 vaccination: a registry-based study of 414 cases. *J Am Acad Dermatol* 85:46–55
12. Mücke VT, Knop V, Mücke MM et al (2021) First description of immune complex vasculitis after COVID-19 vaccination with BNT162b2: a case report. *BMC Infect Dis* 21:1–6
13. Riad A, Pokorná A, Attia S et al (2021) Prevalence of COVID-19 vaccine side effects among healthcare workers in the Czech Republic. *JCM* 10:1428
14. Salvarani C, Cantini F, Hunder GG (2008) Polymyalgia rheumatica and giant-cell arteritis. *Lancet* 372:234–245
15. Savage C, Harper L, Cockwell P et al (2000) Vasculitis. *BMJ* 320:1325–1328
16. Shakoor MT, Birkenbach MP, Lynch M (2021) ANCA-associated vasculitis following Pfizer-BioNTech COVID-19 vaccine. *Am J Kidney Dis* 78:611–613
17. Soriano A, Verrecchia E, Marinaro A et al (2012) Giant cell arteritis and polymyalgia rheumatica after influenza vaccination: report of 10 cases and review of the literature. *Lupus* 21:153–157