



Retropharyngeal edema: A rare manifestation of eosinophilic granulomatosis with polyangiitis

Osamu Matsuno^{*}, Seijiro Minamoto

Department of Medicine for Allergic Disease, Osaka Habikino Medical Center, 3-7-1 Habikino, Habikino City, Osaka, 583-8588, Japan

ARTICLE INFO

Keywords:

Case report
Dysphagia
Eosinophilic granulomatosis with polyangiitis
Neck swelling
Retropharyngeal edema

ABSTRACT

Eosinophilic granulomatosis with polyangiitis (EGPA) is characterized by excessive eosinophil accumulation in the peripheral blood and affected tissues with development of granulomatous vasculitic organ damage. Although upper airway and neck involvement is seen in patients with EGPA, retropharyngeal inflammation has never been reported. We report a case of retropharyngeal edema in a 70-year-old woman with EGPA. Her symptoms improved and the retropharyngeal edema disappeared on computed tomography following treatment. EGPA should be considered as a differential diagnosis in patients with asthma presenting with neck swelling and dysphagia.

1. Introduction

Eosinophilic granulomatosis with polyangiitis (EGPA) is defined as granulomatous vasculitis that affects small- and medium-sized arteries. EGPA is characterized by asthma and eosinophilia and may affect the lungs, heart, kidneys, and gastrointestinal tract. Anti-neutrophil cytoplasmic antibodies (ANCA) against myeloperoxidase (MPO-ANCA) are observed in approximately 40–70% of patients with EGPA [1]. Associations between EGPA and sinusitis, nasal polyps, rhinitis, anosmia, otitis media, sensorineural hearing loss, mastoiditis, intracranial abscess, and facial nerve palsies have been reported [2]. Retropharyngeal involvement has never been reported in patients with ANCA-associated vasculitis.

2. Case presentation

A 70-year-old woman was admitted after an episode of dysphagia and paresthesia of the right arm and foot. Neurological examination revealed distal asymmetrical paraparesis of the upper and lower extremities without motor neuron involvement, and she was diagnosed with asymmetrical distal sensory polyneuropathy by a neurologist. She had a 37-year history of asthma and was diagnosed with allergic rhinitis at the age of 34 years. Neck computed tomography (CT) revealed

swelling of the retropharyngeal soft tissue (Fig. 1A). Results of testing for inflammatory marker levels revealed that the blood eosinophil count (9840/ μ L) was high, the C-reactive protein level (2.91 mg/dL) was mildly elevated, and the fraction of exhaled nitric oxide level was elevated (137 ppb). The serum total immunoglobulin (Ig)E and IgG4 levels were 4230 IU/mL and 641 mg/dL, respectively. The results of indirect immunofluorescence testing for MPO-ANCA were negative, and the forced expiratory volume in 1 second was 68.8% of the predicted value. The Asthma Control Test score was 19, indicating poorly controlled asthma. Random skin biopsy revealed perivascular eosinophilic dermatitis without plasma cell infiltration. We diagnosed the patient with EGPA because her clinical course matched that outlined in the Japanese Ministry of Health and Welfare diagnostic criteria for “allergic granulomatosis with polyangiitis/Churg–Strauss syndrome (AGA/CSS),” which is now known as EGPA [3]. The following criteria were met: 1) preceding history of asthma and allergic rhinitis, 2) peripheral eosinophilia, and 3) polyneuropathy. Treatment with prednisone (20 mg daily) was initiated. Her symptoms rapidly improved and the prednisone dosage was gradually reduced. Two months later, the retropharyngeal edema on CT disappeared (Fig. 1B). Written consent for the publication of this report was obtained from the patient.

Abbreviations: EGPA, eosinophilic granulomatosis with polyangiitis; ANCA, anti-neutrophil cytoplasmic antibodies; MPO-ANCA, anti-neutrophil cytoplasmic antibodies against myeloperoxidase; CT, computed tomography; Ig, immunoglobulin; HES, Hypereosinophilic syndrome; IgG4-RD, immunoglobulin G4-related disease.

^{*} Corresponding author.

E-mail address: matsunoo@ra.opho.jp (O. Matsuno).

<https://doi.org/10.1016/j.rmcr.2021.101539>

Received 30 August 2021; Received in revised form 7 October 2021; Accepted 19 October 2021

Available online 21 October 2021

2213-0071/© 2021 Published by Elsevier Ltd. This is an open access article under the CC BY-NC-ND license (<http://creativecommons.org/licenses/by-nc-nd/4.0/>).

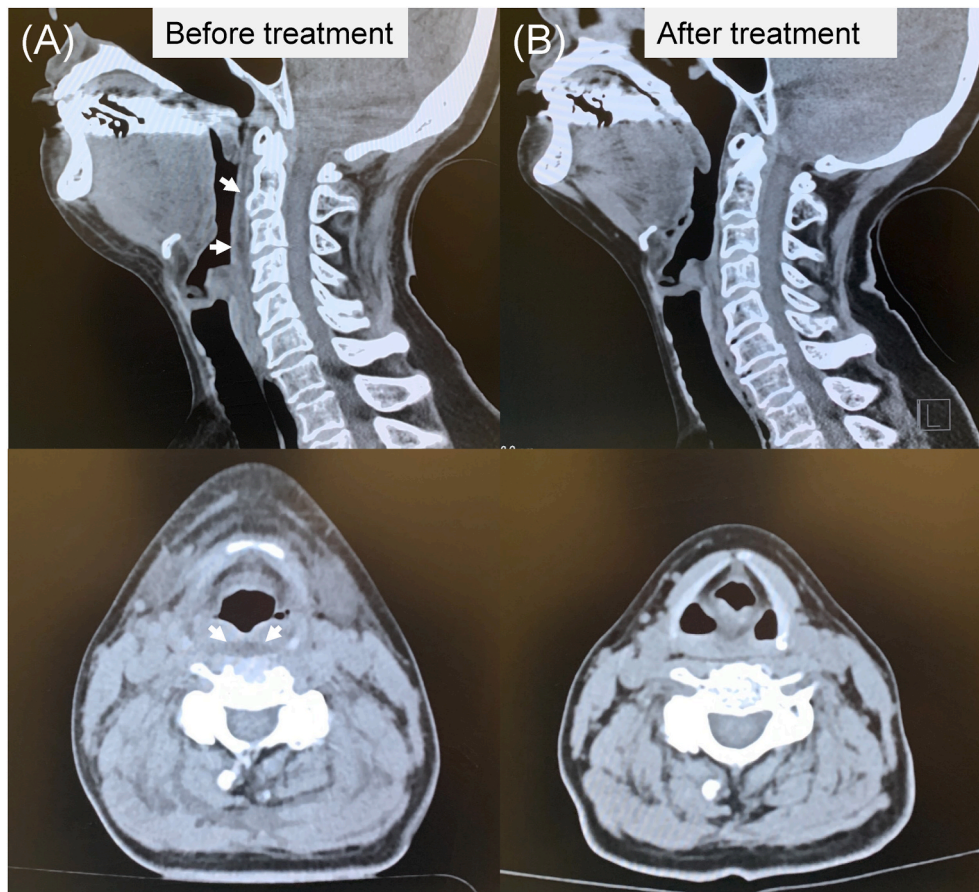


Fig. 1. (A) Neck computed tomography (CT) showing prevertebral thickening with edema (white arrows). (B) Resolution of retropharyngeal swelling seen on follow-up CT 2 months later.

3. Discussion

Ear, nose, and throat signs are observed in 48% of patients with EGPA [4]. Nevertheless, retropharyngeal edema has not yet been reported in these patients. This is the first reported case of retropharyngeal edema in a patient with EGPA, who underwent complete examination, including neck CT, during the episode. Kawasaki disease, a mucocutaneous vasculitis that primarily affects infants and young children, is occasionally associated with retropharyngeal lesions [5].

Hypereosinophilic syndrome (HES) and immunoglobulin G4-related disease (IgG4-RD) were important differential diagnoses in our case. HES and ANCA-negative EGPA share many features, such as peripheral hypereosinophilia and tissue eosinophilia with organ dysfunction or damage. Our patient's history of asthma supported the diagnosis of EGPA, as all potential causes of hypereosinophilia should be excluded before diagnosing HES [6]. However, asthma may occur secondary to HES [7]. Ahn et al. reported that patients with ANCA-negative EGPA exhibited asthma, peripheral neuropathy, and histopathological findings of extravascular eosinophils more frequently than those with HES; all these features were observed in our patient [8].

Our patient's IgG4 level was elevated. However, IgG4 elevation is not a specific biomarker for IgG4-RD. Serum IgG4 level elevation is also seen in patients with active EGPA, and it is correlated with the number of organ manifestations and disease activity [9]. Furthermore, our patient did not meet the 2019 American College of Rheumatology/European League Against Rheumatism criteria for IgG4-related disease [10].

4. Conclusion

EGPA should be considered a differential diagnosis in patients with asthma presenting with neck swelling, dysphagia, and retropharyngeal space inflammation.

Consent for publication

Written consent for publication of this report was obtained from the patient, and a copy of the consent form can be shared, if required.

Ethics approval and consent to participate

The presented data are part of our clinical work, and there are no ethical conflicts.

Funding

This research did not receive any specific grant from funding agencies in the public, commercial, or not-for-profit sectors.

Declaration of competing interest

The author declare that they have no competing interests.

Acknowledgements

We thank Kyoko Uekawa, Shoko Tachibana and Marina Miyazaki for assisting in the preparation of this manuscript.

References

- [1] A. Vaglio, C. Buzio, J. Zwerina, Eosinophilic granulomatosis with polyangiitis (Churg-Strauss): state of the art, *Allergy* 68 (2013) 261–273, <https://doi.org/10.1111/all.12088>.
- [2] J.M. Goldfarb, M.R. Rabinowitz, S.R. Basnyat, G.G. Nyquist, M.R. Rosen, Head and neck manifestations of eosinophilic granulomatosis with polyangiitis: a systematic review, *Otolaryngol. Head Neck Surg.* 155 (2016) 771–778, <https://doi.org/10.1177/0194599816657044>.
- [3] S. Ozaki, ANCA-associated vasculitis: diagnostic and therapeutic strategy, *Allergol. Int.* 56 (2007) 87–96, <https://doi.org/10.2332/allergolint.R-07-141>.
- [4] C. Comarmond, C. Pagnoux, M. Khellaf, J.F. Cordier, M. Hamidou, J.F. Viillard, F. Maurier, S. Jouneau, B. Bienvenu, X. Puéchal, O. Aumaître, G. Le Guenno, A. Le Quellec, R. Cevallos, O. Fain, B. Godeau, R. Seror, B. Dunogué, A. Mahr, P. Guilpain, P. Cohen, A. Aouba, L. Mouthon, L. Guillevin, French Vasculitis Study Group, Eosinophilic granulomatosis with polyangiitis (Churg-Strauss): clinical characteristics and long-term followup of the 383 patients enrolled in the French Vasculitis Study Group cohort, *Arthritis Rheum.* 65 (2013) 270–281, <https://doi.org/10.1002/art.37721>.
- [5] M. Hibino, Y. Urabe, S. Horiuchi, Y. Uchida, K. Miyahara, Adult recurrence of Kawasaki disease mimicking retropharyngeal abscess, *Intern. Med.* 56 (2017) 2217–2221, <https://doi.org/10.2169/internalmedicine.8399-16>.
- [6] H.U. Simon, M.E. Rothenberg, B.S. Bochner, P.F. Weller, A.J. Wardlaw, M. E. Wechsler, L.J. Rosenwasser, F. Roufosse, G.J. Gleich, A.D. Klion, Refining the definition of hypereosinophilic syndrome, *J. Allergy Clin. Immunol.* 126 (2010) 45–49, <https://doi.org/10.1016/j.jaci.2010.03.042>.
- [7] H.R. Noh, G.G. Magpantay, Hypereosinophilic syndrome, *allergy. Asthma, SAVE Proc.* 38 (2017) 78–81, <https://doi.org/10.2500/aap.2017.38.3995>.
- [8] S.S. Ahn, J. Yoo, Y.B. Park, J.W. Park, J.H. Lee, S.W. Lee, A new index for distinguishing hypereosinophilic syndrome and antineutrophil cytoplasmic antibody-negative eosinophilic granulomatosis with polyangiitis, *Asian Pac. J. Allergy Immunol.* (2020), <https://doi.org/10.12932/AP-080420-0805>.
- [9] A. Vaglio, J.D. Strehl, B. Manger, F. Maritati, F. Alberici, C. Beyer, J. Rech, R. A. Sinico, F. Bonatti, L. Battistelli, J.H.W. Distler, G. Schett, J. Zwerina, IgG4 immune response in Churg-Strauss syndrome, *Ann. Rheum. Dis.* 71 (2012) 390–393, <https://doi.org/10.1136/ard.2011.155382>.
- [10] Z.S. Wallace, R.P. Naden, S. Chari, H. Choi, E. Della-Torre, J.F. Dicaire, P.A. Hart, D. Inoue, M. Kawano, A. Khosroshahi, M. Lanzillotta, K. Okazaki, C.A. Perugino, A. Sharma, T. Saeki, N. Schleinitz, N. Takahashi, H. Umehara, Y. Zen, J.H. Stone, Members of the ACR/EULAR IgG4-RD classification criteria working group, the 2019 American College of Rheumatology/European League against rheumatism classification criteria for IgG4-related disease, *Ann. Rheum. Dis.* 79 (2019) 77–87, <https://doi.org/10.1136/annrheumdis-2019-216561>.