

Acquisition of sensorimotor fMRI under general anaesthesia: Assessment of feasibility, the BOLD response and clinical utility

Adam Kenji Yamamoto^{a,b,*}, Joerg Magerkurth^c, Laura Mancini^{a,b}, Mark J. White^{a,d}, Anna Miserocchi^e, Andrew W. McEvoy^e, Ian Appleby^f, Caroline Micallef^b, John S. Thornton^{a,b}, Cathy J. Price^g, Nikolaus Weiskopf^{g,h}, Tarek A. Yousry^{a,b}

^a *Neuroradiological Academic Unit, Department of Brain Repair and Rehabilitation, UCL Queen Square Institute of Neurology, University College London, London, United Kingdom*

^b *Lysholm Department of Neuroradiology, National Hospital for Neurology and Neurosurgery, London, United Kingdom*

^c *UCL Psychology and Language Sciences, Birkbeck-UCL Centre for Neuroimaging, London, United Kingdom*

^d *Medical Physics and Biomedical Engineering, University College London Hospital, London, United Kingdom*

^e *Department of Neurosurgery, National Hospital for Neurology and Neurosurgery, London, United Kingdom*

^f *Department of Neuroanaesthesia, National Hospital for Neurology and Neurosurgery, London, United Kingdom*

^g *Wellcome Centre for Human Neuroimaging, UCL Queen Square Institute of Neurology, University College London, London, United Kingdom*

^h *Department of Neurophysics, Max Planck Institute for Human Cognitive and Brain Sciences, Leipzig, Germany*

ARTICLE INFO

Keywords:

fMRI
Anaesthesia
Brain tumour
Intra-operative
Neurosurgery

ABSTRACT

We evaluated whether task-related fMRI (functional magnetic resonance imaging) BOLD (blood oxygenation level dependent) activation could be acquired under conventional anaesthesia at a depth enabling neurosurgery in five patients with supratentorial gliomas. Within a 1.5 T MRI operating room immediately prior to neurosurgery, a passive finger flexion sensorimotor paradigm was performed on each hand with the patients awake, and then immediately after the induction and maintenance of combined sevoflurane and propofol general anaesthesia. The depth of surgical anaesthesia was measured and confirmed with an EEG-derived technique, the Bispectral Index (BIS). The magnitude of the task-related BOLD response and BOLD sensitivity under anaesthesia were determined. The fMRI data were assessed by three fMRI expert observers who rated each activation map for somatotopy and usefulness for radiological neurosurgical guidance.

The mean magnitudes of the task-related BOLD response under a BIS measured depth of surgical general anaesthesia were 25% (tumour affected hemisphere) and 22% (tumour free hemisphere) of the respective awake values. BOLD sensitivity under anaesthesia ranged from 7% to 83% compared to the awake state. Despite these reductions, somatotopic BOLD activation was observed in the sensorimotor cortex in all ten data acquisitions surpassing statistical thresholds of at least $p < 0.001_{\text{uncorr}}$. All ten fMRI activation datasets were scored to be useful for radiological neurosurgical guidance.

Passive task-related sensorimotor fMRI acquired in neurosurgical patients under multi-pharmacological general anaesthesia is reproducible and yields clinically useful activation maps. These results demonstrate the feasibility of the technique and its potential value if applied intra-operatively. Additionally these methods may enable fMRI investigations in patients unable to perform or lie still for awake paradigms, such as young children, claustrophobic patients and those with movement disorders.

Abbreviations: fMRI, (functional magnetic resonance imaging); BOLD, (blood oxygenation level dependent); iMRI, (intra-operative MRI); CBF, (cerebral blood flow)
* Corresponding author at: Neuroradiological Academic Unit, Department of Brain Repair and Rehabilitation, UCL Queen Square Institute of Neurology, University College London, Box 65, 8-11 Queen Square, London, WC1N 3BG, United Kingdom.

E-mail addresses: a.yamamoto@ucl.ac.uk (A.K. Yamamoto), j.magerkurth@ucl.ac.uk (J. Magerkurth), lmancini@nhs.net (L. Mancini), mark.white4@nhs.net (M.J. White), anna.miserocchi@nhs.net (A. Miserocchi), a.mcevoy@ucl.ac.uk (A.W. McEvoy), ian.appleby@nhs.net (I. Appleby), caroline.micallef@nhs.net (C. Micallef), john.thornton@ucl.ac.uk (J.S. Thornton), c.j.price@ucl.ac.uk (C.J. Price), weiskopf@cbs.mpg.de (N. Weiskopf), t.yousry@ucl.ac.uk (T.A. Yousry).

<https://doi.org/10.1016/j.nicl.2019.101923>

Received 16 January 2019; Received in revised form 28 May 2019; Accepted 30 June 2019

Available online 02 July 2019

2213-1582/ © 2019 The Authors. Published by Elsevier Inc. This is an open access article under the CC BY-NC-ND license (<http://creativecommons.org/licenses/by-nc-nd/4.0/>).

1. Introduction

Image guidance using awake, pre-operatively acquired functional magnetic resonance imaging (fMRI) is in many neurosurgical units an essential tool when resecting brain tumours. It enables accurate planning and intra-operative guidance, especially in the initial phase of the procedure. As surgery progresses however, cerebral structures on average shift by up to 9 mm (Hill et al., 1998; Nimsky et al., 2000), thereby compromising the spatial correspondence of pre-operatively acquired images. This ‘brain shift’ phenomenon, if unaccounted for, can therefore lead to inadvertent damage to critical brain areas.

One way of addressing this problem is through the acquisition of intra-operative task-related fMRI (Nimsky, 2011). Acquiring intra-operative task-related fMRI is more challenging than intra-operative structural MRI because fMRI relies on (i) the detection of blood oxygenation level dependent (BOLD) activation (Ogawa et al., 1990a) which is known to be affected by anaesthesia (Keressens et al., 2005; Marcar et al., 2006; Ogawa et al., 1990b); and (ii) activation paradigms that are applicable to unconscious patients. To establish the feasibility of intra-operative task-related fMRI, it is important to establish whether task-related BOLD activation can be detected in patients anaesthetised to the depth required for neurosurgery. Recent studies have shown that BOLD activation in the resting state can be detected in neurosurgical patients (Bisdas et al., 2016; Qiu et al., 2017; Roder et al., 2016) and prior to these there have been several studies that have shown task-related BOLD activation can be detected in anaesthetised patients (Dueck et al., 2005; Gasser et al., 2005a, 2005b; Marcar et al., 2006). In all of these studies however only a single anaesthetic technique, either intravenous (propofol with or without an opioid) or inhalational (sevoflurane), was used but not propofol and sevoflurane together. Furthermore in none of these studies was there a measure to quantify the depth of the subjects' anaesthesia at the time of fMRI. In standard clinical practice for tumour surgery, general anaesthesia is usually achieved with multiple pharmacological agents (which may include intravenous and inhalational anaesthesia) acting on the central nervous system to suppress consciousness and pain detection (Dinsmore, 2007; Ravussin and Wilder-Smith, 2001).

Establishing the feasibility of detecting task-related BOLD activation in conventionally anaesthetised patients is a pre-requisite prior to the introduction of intra-operative fMRI and its acquisition under general anaesthesia following a craniotomy and exposure of the brain. The aims of our study were firstly to evaluate whether sensorimotor BOLD fMRI activation could be obtained under general anaesthesia at a depth permitting neurosurgery, using a simple, readily implemented passive finger flexion sensorimotor paradigm. We also aimed to determine the relative magnitude of the task-related BOLD response before and after general anaesthesia and the change in BOLD sensitivity, and finally to assess the accuracy of sensorimotor cortex localisation in the context of radiological neurosurgical guidance.

2. Methods

2.1. Patients

This prospective study received institutional review board approval and all patients gave written informed consent prior to participation. Five patients with intrinsic tumours within the right cerebral hemisphere (two male, three female, mean patient age 33.7 years, SD = 8.9 years) were prospectively recruited following referral for neurosurgical management. None of the patients had undergone previous treatment of their tumours. The inclusion criteria for the study were: a) supratentorial glioma b) undergoing intra-operative MRI-guided resection and c) no significant cardiovascular co-morbidity to preclude prolonged imaging under general anaesthesia. Images of each patient's tumour are shown in Fig. 1. Patient A's tumour was a World Health Organization (WHO) grade II oligoastrocytoma measuring 13.0

cm³ and was centred on the right anterior cingulate gyrus. Patient B's tumour was a grade III anaplastic oligodendroglioma measuring 36.5 cm³ centred on the right superior and middle frontal gyri. The posterior margin of the tumour was 1.8 cm from the hand motor region of the right pre-central gyrus and did not result in any distortion of the sensorimotor cortex. Patient C's tumour was a grade II oligoastrocytoma measuring 60.2 cm³ and was centred on the right posterior temporal lobe involving the middle and inferior temporal gyri. Patient D's tumour was a grade II oligoastrocytoma measuring 38.2 cm³ involving the right cingulate and superior frontal gyri. The posterior margin of the tumour was 2 cm from the hand motor region of the right pre-central gyrus with no distortion of the sensorimotor cortex. Patient E's tumour was a grade II oligodendroglioma measuring 0.5 cm³ centred on the right supra-marginal gyrus.

2.2. Clinical management

The study was performed within an intra-operative MRI (iMRI) operating room at the National Hospital for Neurology and Neurosurgery, a UK national neurosurgical referral centre. The iMRI operating room consists of a 1.5 T MRI system within the operating theatre (White et al., 2015). The pharmacological agents used at induction of anaesthesia are listed in Table 1. These were the intravenous anaesthetic agent propofol, the opioid analgesic fentanyl and the neuromuscular blocking agent atracurium. General anaesthesia was then maintained using the inhalational anaesthetic agent sevoflurane. All patients, except patient D, also received an infusion of a second opioid analgesic remifentanyl. The anaesthetic regimen and the dosages of the drugs administered by the neuroanaesthetists were not modified because of study participation. Systemic blood pressure, carbon dioxide concentration and oxygen saturations under anaesthesia were recorded (Table 1). Carbon dioxide concentrations were maintained within the normal physiological levels of between 4 to 5.7 kilopascals (kPa), with a respiratory rate of 10 to 15 breaths per minute (normoventilation) and blood oxygen saturations were maintained >98% with the use of increased inspired oxygen concentration as is standard clinical practice.

To quantify the depth of anaesthesia, measurement was performed with the Bispectral Index (BIS) Brain Monitoring System (Covidien, MN, USA). This system records a processed electroencephalography (EEG) measurement with scalp electrodes, resulting in a dimensionless number ranging from 100 (fully awake) to 0 (an isoelectric EEG), this value being the weighted sum of three descriptors which correlate with the depth of the hypnotic state. BIS is used in everyday clinical neurosurgical practice to measure the depth of anaesthesia and can minimise the risk of unintended awareness or excessively deep anaesthesia (Myles et al., 2004). A BIS value of between 40 to 60 is considered appropriate for surgical anaesthesia (Gan et al., 1997). The BIS measurement was performed twice, immediately before and after the fMRI was completed.

2.3. Functional imaging task

The sensorimotor paradigm involved passive flexion of the patient's digits II to V at the metacarpophalangeal and interphalangeal joints at a frequency of 1 Hz (Magerkurth et al., 2015). The paradigm was performed by the same trained clinician (A.K.Y.) who performed the task on each of the five patients to limit any potential variability between patients. A single scanning run consisted of 10 blocks of finger flexion alternating with 10 blocks of rest. Both the task and rest blocks were 16 s each in duration. The total imaging time was 5 min 32 s. Right and left hand data were acquired in two different scanning runs, first on the right hand and then repeated for the left hand, eliciting activation in the cerebral hemispheres without and with the tumour.

To ensure correct timing for the task, a monitor was displayed within the iMRI operating room which showed the second by second countdown for the periods of task and rest. The paradigm was

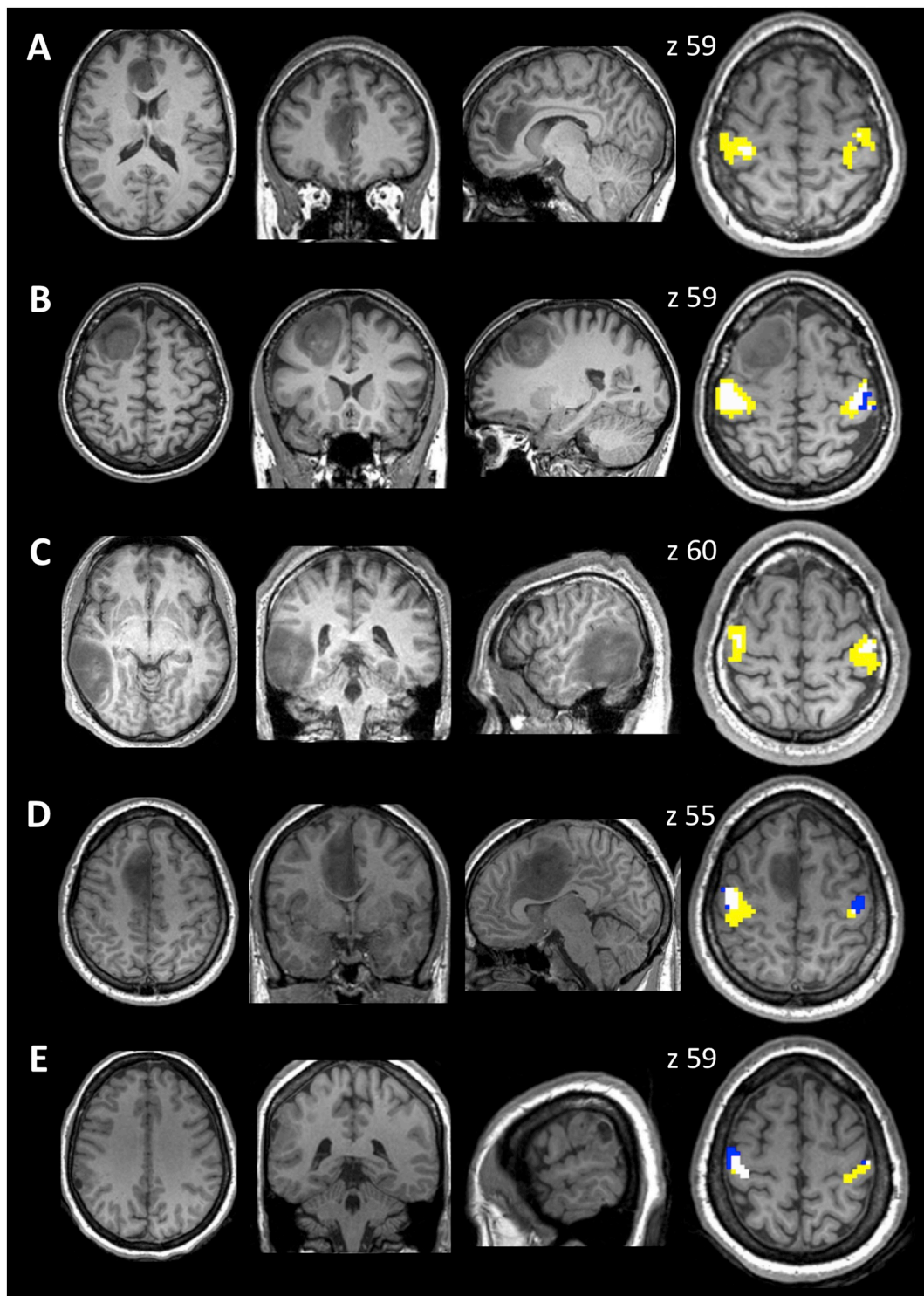


Fig. 1. The figure shows selected T1-weighted images of the patients A to E oriented in radiological convention showing the location of the tumour within the right cerebral hemisphere and fMRI activation clusters (image on far right). The clusters of voxels are colour coded to indicate the activation across the awake and anaesthetised states. Yellow voxels = activation seen only in the awake state. Blue voxels = activation seen only in the anaesthetised state. White voxels = activated in both states. In all patients the tumour was in the right cerebral hemisphere and so movement of the fingers of the left hand resulted in activation in the sensorimotor cortex of the right hemisphere. z = MNI co-ordinate for the slice.

performed firstly with the patients awake and repeated immediately after anaesthesia, before the craniotomy. When awake, patients were instructed to relax and not to contribute to the movement. The paradigm was selected for its ease of use, applicability to anaesthetised patients and its inter-subject consistency in eliciting activation in the pre-central and post-central gyri (primary motor and sensory cortices).

2.4. MRI parameters

Data were acquired on a 1.5 T intra-operative MAGNETOM Espree Tim system whole-body MRI (Siemens, Erlangen, Germany) using a 12-channel head coil. Functional acquisitions consisted of gradient-echo echo-planar images (EPI) with voxel size $3 \times 3 \times 3 \text{ mm}^3$,

Table 1

The table lists the demographical, clinical and anaesthesia details of the five patients (A to E) participating in the study. Gender F = female M = male, Age = age in years at time of study entry. All patients had tumours in the right cerebral hemisphere and tumour location refers to the lobe containing the tumour (F = frontal, T = temporal, P = parietal). Tumour volume is in cm³ and was measured following manual segmentation using ITK-SNAP 3.6.0 (Yushkevich et al., 2006). Tumour type refers to the histological diagnosis of the tumour (OA = oligoastrocytoma, AO = anaplastic oligodendroglioma, OD = oligodendroglioma, 2 = WHO grade II, 3 = WHO grade III). Anaesthesia refers to the drugs and dosages (mg = milligram, mcg = microgram, %) administered to the patients at induction of general anaesthesia (induction) and at the time of fMRI acquisition (during fMRI). For patient D, remifentanyl was not administered (n/a = not applicable). BIS refers to the Bispectral index measurement of the depth of anaesthesia at the time when the fMRI was acquired, with a level of < 60 considered surgical anaesthesia. The BIS value is the average of the two measurements performed before and after fMRI. Three main physiological variables measured under anaesthesia are listed, these are (a) blood pressure measured in mm of mercury (mmHg) (b) end tidal carbon dioxide levels measured in kilopascal (kPa) and (c) oxygen saturation measured as a percentage (%). For sevoflurane and the physiological variables, the values during the left and right hand fMRI acquisitions are listed.

Patients	A	B	C	D	E
Gender	F	F	M	M	F
Age/years	34.9	44.1	25.5	23.9	40.2
Tumour location	F	F	T	F	P
Tumour volume/cm ³	13.0	36.5	60.2	38.2	0.5
Tumour type	OA (2)	AO (3)	OA (2)	OA (2)	OD (2)
Anaesthesia: induction					
Propofol (mg)	150	200	200	170	160
Fentanyl (mcg)	300	100	100	300	100
Atracurium (mg)	50	50	50	50	50
Anaesthesia: during fMRI					
Sevoflurane (end tidal %)					
Left hand (tumour)	1.94	1.54	1.87	2.29	1.62
Right hand (non tumour)	1.83	1.63	1.87	2.37	1.61
Remifentanyl (mg/h)	0.2	0.2	0.2	n/a	0.2
BIS	48	56	29	52	34
Physiological variables					
Blood pressure (mmHg)					
Left hand (tumour)	91/47	74/38	97/32	78/46	84/46
Right hand (non tumour)	91/47	70/39	89/32	80/47	85/47
Carbon dioxide (kPa)					
Left hand (tumour)	4.5	5.7	4.7	4.3	4.3
Right hand (non tumour)	4.6	4.1	4.7	4.3	4.3
Oxygen saturation (%)					
Left hand (tumour)	100	99	100	100	100
Right hand (non tumour)	100	99	100	100	100

repetition time TR/echo time TE/flip angle = 3100 ms/40 ms/90°, field of view (FOV) = 192 × 192 mm², matrix size = 64 × 64, and 42 slice whole brain coverage. A static magnetic field (B₀) map using a double gradient-echo sequence was acquired for correction of susceptibility-induced geometric distortion of the EPI images with the following parameters: TR/TE₁/TE₂/flip angle = 630 ms/4.92 ms/9.68 ms/60°, FOV = 192 × 192 mm², matrix size = 64 × 64, 42 slices. High resolution T1-weighted images were acquired using a sagittally-acquired three-dimensional magnetization prepared rapid acquisition gradient echo (MPRAGE) sequence with voxel size 1.1 × 1.1 × 1.2 mm³, TR/TE/TI/flip angle = 2250 ms/3.7 ms/1100 ms/15°, FOV = 220 × 220 mm², matrix size = 192 × 192, 192 slices.

2.5. fMRI data processing and analysis

Preprocessing and statistical analysis of the fMRI data were performed in SPM12 (Wellcome Centre for Human Neuroimaging, London, UK), running in MATLAB 2012a (Mathworks, MA, USA). Spatial distortions in the functional data, resulting from non-linearities in the MRI

gradient system, were corrected by use of an in-house developed software (NoGradWarp, SPM Toolbox) and applied to the EPI volumes and the voxel displacement map (VDM). Functional images were then unwarped to correct for susceptibility related distortion based on the VDM, spatially realigned to the first EPI volume, co-registered to the anatomical T1-weighted image, spatially normalised to the Montreal Neurological Institute (MNI) template and spatially smoothed with a 6 mm full-width-half-maximum isotropic Gaussian kernel to permit application of Gaussian random-field theory (Friston et al., 1995). Subject-specific fixed effect analyses compared functional volumes for task and rest, for each hand separately. Activation was assessed in the pre- and post-central gyri (sensorimotor cortex), which was defined anatomically using the Automated Anatomical Labelling (AAL) atlas (Tzourio-Mazoyer et al., 2002). The statistical threshold was corrected for multiple comparisons within these anatomical regions and across the whole brain ($p < 0.05$). Results were also reported at an uncorrected threshold of $p < 0.001$ ($p < 0.001_{\text{uncorr}}$) to replicate the clinical neuroradiological application of fMRI to neurosurgical planning, where too stringent a statistical threshold can lead to false negative areas of activation and inadvertent damage to functionally important areas.

2.6. Evaluation of the effect of anaesthesia on a) the magnitude of the task-related BOLD response and b) BOLD sensitivity

The magnitude of the task-related BOLD response compared to rest was firstly measured using a region of interest (ROI) defined by the largest cluster of activation during the awake state within the MarsBar toolbox in SPM (Brett et al., 2002), scaling the parameter estimates for each voxel to the mean value across the entire ROI and expressed as a percentage (%). This was performed for each patient on each of their data sets relating to right and left hand activation when awake and under anaesthesia. The ROI was defined from the activation in the awake state because it was likely to provide a better indicator of anaesthesia's effect on the task-related BOLD response across a larger region of the sensorimotor cortex. It also ensured that the measurement was not biased to the anaesthetised state.

To assess how the task-related BOLD response was affected by anaesthesia and the presence of the tumour, we performed a repeated measures ANOVA with factor 1, state (awake versus anaesthesia) and factor 2, hemisphere (ROI in tumour affected versus tumour free hemisphere). This was conducted in SPSS (IBM SPSS 22, NY, USA) with a statistical threshold of $p < 0.05$.

Anaesthesia's effect on BOLD sensitivity was assessed by the use of t-score histograms (Todd et al., 2015) which represented the number of activated voxels within each patient's ROI. Histograms were calculated for the tumour affected hemisphere when the patients were awake and under anaesthesia (t-score threshold of 3.1) with BOLD sensitivity defined as the ratio of activated voxels_{anaesthesia}/voxels_{awake} × 100%. The order of fMRI data acquisition, with the patients awake then anaesthetised, and selection of the region of interest for data extraction (voxels activated during the awake state) were both expected to bias sensitivity towards the awake state. Our approach therefore ensured that sensitivity in the anaesthetised state was not over-estimated.

To assess for any association between anaesthesia (sevoflurane concentration and the BIS measurements) and any observed changes in the task-related BOLD response, the data were firstly visually assessed with scatter plots of the independent variables plotted against the ratio of: $\frac{\text{BOLD response anaesthesia}}{\text{BOLD response awake}}$. Data were formally assessed for association using the Spearman's correlation coefficient (r_s), with a one-tailed significance level of $p < 0.05$. BOLD response values are reported to 1 decimal place (DP) with correlation analyses performed on the raw data BOLD values to 4 DP.

Table 2

The table lists the fMRI statistical results. These are shown for each of the patients A to E for the task in each sensorimotor cortex when awake and anaesthetised. Hand L = left R = right hand movement. All patients had tumours in the right cerebral hemisphere and so left hand movement resulted in activation in the right sensorimotor cortex (tumour affected hemisphere). Movement of the right hand resulted in activation in the left sensorimotor cortex (tumour free hemisphere). k = number of voxels in the largest cluster, the height threshold was set at $t = 4.97$ (awake) and $t = 3.1$ (anaesthesia). $x y z$ = MNI co-ordinates for the peak voxel activation in the cluster. The t-score is listed for the peak voxel of activation and the p values are given at three thresholds: uncorrected (P_{Uncorr}), correction for multiple comparisons within the sensorimotor cortex ROI ($P_{\text{FWE-Corr ROI}}$) and across the whole brain ($P_{\text{FWE-Corr Brain}}$).

Patient	State	Hand	k	x	y	z	t-score	P_{Uncorr}	$P_{\text{FWE-Corr ROI}}$	$P_{\text{FWE-Corr Brain}}$
A	Awake	L	147	36	-25	56	12.0	<0.001	<0.001	<0.001
		R	248	-42	-16	62	10.1	<0.001	<0.001	<0.001
	Anaesthesia	L	17	36	-25	59	5.6	<0.001	<0.001	0.003
		R	2	-39	-16	56	3.7	<0.001	0.294	1.000
B	Awake	L	226	48	-13	56	12.9	<0.001	<0.001	<0.001
		R	211	-36	-28	59	12.9	<0.001	<0.001	<0.001
	Anaesthesia	L	133	42	-22	65	8.5	<0.001	<0.001	<0.001
		R	109	-45	-16	59	6.1	<0.001	<0.001	<0.001
C	Awake	L	178	42	-13	56	12.1	<0.001	<0.001	<0.001
		R	202	-39	-25	56	7.2	<0.001	<0.001	<0.001
	Anaesthesia	L	13	42	-19	59	3.9	<0.001	0.106	0.981
		R	26	-45	-19	59	5.2	<0.001	0.001	0.016
D	Awake	L	246	42	-19	53	10.2	<0.001	<0.001	<0.001
		R	22	-36	-28	56	6.3	<0.001	<0.001	<0.001
	Anaesthesia	L	80	45	-16	53	9.0	<0.001	<0.001	<0.001
		R	47	-42	-19	53	6.7	<0.001	<0.001	<0.001
E	Awake	L	86	42	-22	56	9.0	<0.001	<0.001	<0.001
		R	40	-33	-28	59	7.2	<0.001	<0.001	<0.001
	Anaesthesia	L	159	45	-16	62	7.6	<0.001	<0.001	<0.001
		R	10	-42	-22	53	3.6	<0.001	0.384	1.000

2.7. Assessment of the clinical utility of anaesthesia fMRI data

Three expert observers in fMRI (T.A.Y., consultant neuroradiologist with 21 years experience, L.M., senior clinical scientist with 14 years experience and A.K.Y, neuroradiological fellow with 5 years experience) reviewed each data set at a statistical threshold of $p < 0.001_{\text{uncorr}}$ to determine if the activation was in the expected region of the pre- and post-central gyrus based upon localisation of the primary motor cortex using anatomical landmarks (Yousry et al., 1997). The data were determined to be either a) useful or b) suboptimal, based upon somatotopy, as to whether they could be used for clinically informing the neurosurgeon as to the location of sensorimotor fMRI activation.

Table 3

The magnitude of the task-related BOLD response are shown for the individual patients and the group. The upper table lists the magnitude of the BOLD response (%) for the left hand and right hand activation in patients A to E (to 1 DP). All patients had tumours in the right cerebral hemisphere and so left hand movement resulted in activation in the right sensorimotor cortex (tumour affected hemisphere). Movement of the right hand resulted in activation in the left sensorimotor cortex (tumour free hemisphere). The lower table lists the group results for the five patients.

Patients	A	B	C	D	E
Left hand					
Awake	1.2	0.8	1.1	1.4	1.4
Anaesthesia	0.1	0.5	0.1	0.3	0.5
Right hand					
Awake	0.9	0.7	1.2	1.0	0.9
Anaesthesia	0.1	0.3	0.2	0.3	0.1

Group	Mean	SD	Median	Range
Left hand				
Awake	1.2	0.3	1.2	0.8 to 1.4
Anaesthesia	0.3	0.2	0.3	0.1 to 0.5
Right hand				
Awake	0.9	0.2	0.9	0.7 to 1.2
Anaesthesia	0.2	0.1	0.2	0.1 to 0.3

3.2. fMRI performed under general anaesthesia

At the time of fMRI acquisition in the anaesthetised state, BIS measurements ranging from 29 to 56 (Table 1) confirmed the surgically-appropriate depth of general anaesthesia in all five patients. Under general anaesthesia, activation was observed in both the tumour affected and tumour free sensorimotor cortex in all patients (Fig. 1, Table 2). The clusters were mostly reduced in extent under anaesthesia, the exceptions were right hand activation (in the tumour free hemisphere) for patient D and left hand activation (in the tumour affected hemisphere) for patient E. The peak voxel activation in every acquisition surpassed a statistical threshold of $p < 0.001_{\text{uncorr}}$ and were also mostly significant ($p < 0.05$) after correcting for multiple comparisons across the entire brain.

The magnitude of the task-related BOLD response under general anaesthesia ranged from 0.1% to 0.5%, the group mean magnitude of the task-related BOLD response was 0.3% (SD = 0.2) in the tumour affected hemisphere and 0.2% (SD = 0.1) in the tumour free hemisphere (Table 3).

3.3. Reduction in the task-related BOLD response under anaesthesia

In all patients, the magnitude of the task-related BOLD response (Table 3) was less in the anaesthesia condition. Compared to awake values, these were 25% in the tumour-affected right hemisphere ((0.3 under anaesthesia/1.2 awake) \times 100%) and 22% in the tumour free left hemisphere ((0.2 under anaesthesia/0.9 awake) \times 100%). This resulted in a main effect of anaesthesia ($F = 8.7$, $p = 0.042$) in the 2×2 ANOVA, with no effect of hemisphere ($F = 0.54$, $p = 0.50$) and no interaction between anaesthesia and hemisphere ($F = 0.008$, $p = 0.93$). Note however, that as the ROIs were defined from the awake state, activation was intentionally biased towards the awake state.

3.4. BOLD sensitivity under anaesthesia

The effect of anaesthesia on the t-score histograms from the tumour affected right hemisphere, is shown in Fig. 2. In all patients, there was a leftward shift of the histogram indicating a reduction in the t-scores and the number of activated voxels surpassing the t-score threshold of 3.1 ($p < 0.001_{\text{uncorr}}$). BOLD sensitivities under general anaesthesia compared to awake were 7% (Patient C), 11% (Patient A), 26% (Patient D), 45% (Patient B) and 83% (Patient E). BOLD sensitivity under anaesthesia correlated with the ratio of $\frac{\text{BOLD response anaesthesia}}{\text{BOLD response awake}}$ (Spearman's correlation coefficient 0.9, $p = 0.019$) with increased sensitivity associated with a greater ratio.

3.5. Assessment for an association between BIS and sevoflurane to the BOLD response

The scatter plots in Fig. 3 show the BIS values (3A,C) and the sevoflurane concentrations (3B,D) plotted against the ratio of $\frac{\text{BOLD response anaesthesia}}{\text{BOLD response awake}}$ in each of the five patients. In none of these was there evidence of a clear trend for the ratio to either increase with BIS or to decrease with increasing sevoflurane and the Spearman's correlation coefficients (r_s) for these did not meet statistical significance. For the BIS these were $r_s = 0.7$ ($p = 0.094$, one-tailed) for both the left hand and right hand. For the sevoflurane concentration, these were $r_s = -0.6$ ($p = 0.142$, one-tailed) for the left hand and $r_s = -0.1$ ($p = 0.436$, one-tailed) for the right hand.

3.6. Clinical utility of anaesthesia fMRI data

In all of the ten data sets, fMRI activation clusters under anaesthesia were assessed to be in the correct somatotopic region of the sensorimotor cortex, being wholly or at least partially encompassed by the cluster when the patients were awake (Fig. 1). Based upon this correct

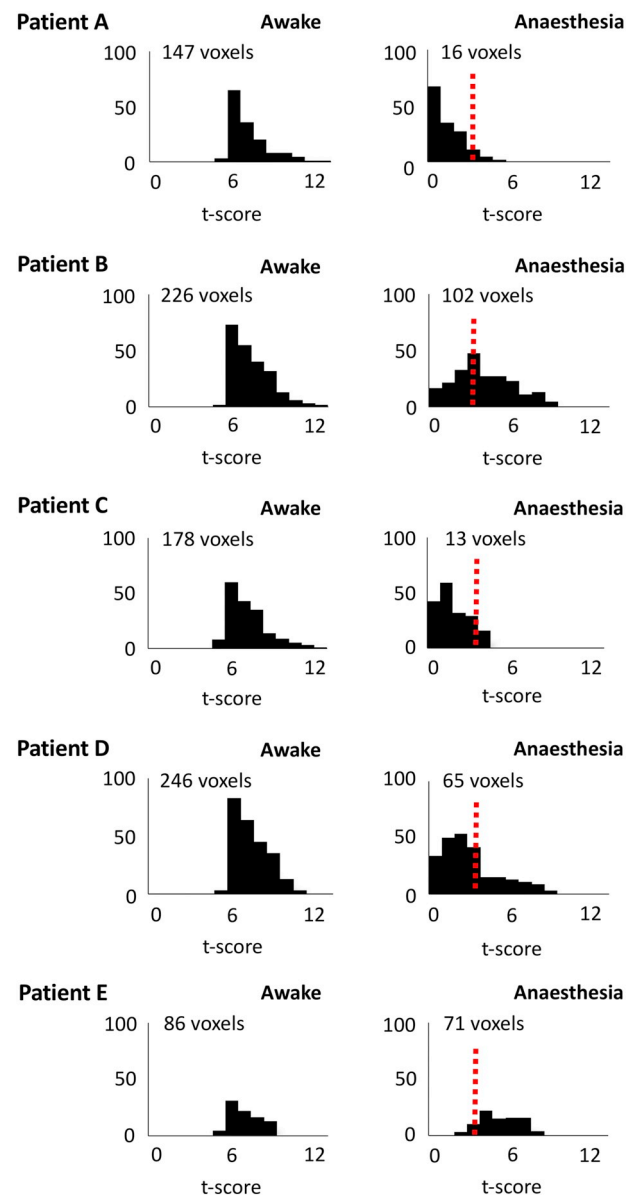


Fig. 2. The figure illustrates the change in BOLD sensitivity under anaesthesia. t-score histograms are shown for the patients A to E for activation in the right sensorimotor cortex (tumour affected hemisphere) resulting from left hand movement. The left histogram for each patient shows the t-score distribution of the voxels within the largest cluster of activation when awake (as listed in Table 2). The right histogram illustrates how the distribution of the t-scores within this cluster is altered under general anaesthesia. Voxels whose t-scores were ≥ 0 are shown. The red dashed line indicates the t-score value 3.1 ($p < 0.001_{\text{uncorr}}$) which was selected to define voxel activation under anaesthesia. Activated voxels are those to the right of this cut-off. The total number of activated voxels when awake and under anaesthesia are listed. BOLD sensitivities ($\frac{\text{anaesthesia voxels}}{\text{awake voxels}} \times 100\%$) for the five patients were: patient A 11% ($16/147 \times 100\%$), patient B 45% ($102/226 \times 100\%$), patient C 7% ($13/178 \times 100\%$), patient D 26% ($65/246 \times 100\%$), patient E 83% ($71/86 \times 100\%$).

somatopy, all ten acquisitions were scored to be useful for radiological neurosurgical guidance.

4. Discussion

In this prospective study we demonstrated that under conventional anaesthesia, using a simple non-invasive passive sensorimotor

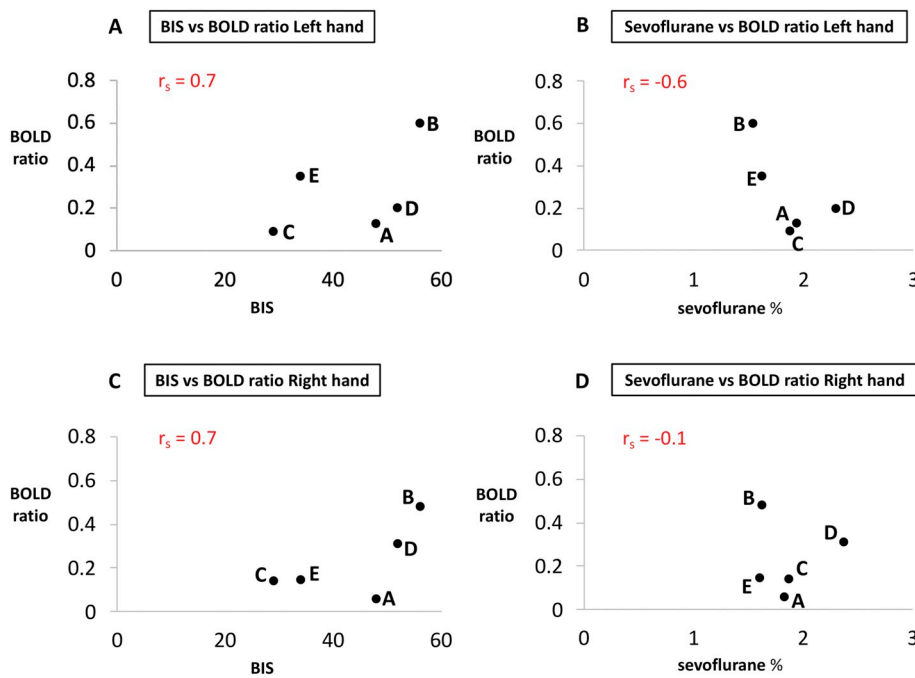


Fig. 3. Scatter plots show the Bispectral Index (BIS) (A,C) and the sevoflurane concentration (end-tidal %) (B,D) plotted against the BOLD ratio for the left hand (tumour affected hemisphere) and right hand (tumour free hemisphere). The BOLD ratio is defined as: $\text{BOLD response anaesthesia} / \text{BOLD response awake}$ (using BOLD values to 4 DP). r_s denotes the Spearman's correlation coefficient.

paradigm, task-related fMRI provides neurosurgically relevant functional information. In five patients with cerebral gliomas anaesthetised with a combination of sevoflurane, propofol and opioids, significant task-related BOLD activation has been reproducibly obtained in a 1.5T intra-operative MRI suite. The pharmacological agents used for anaesthesia reflect real life clinical practice as our goal was for the conditions to replicate those encountered within the intra-operative environment without any alteration in the anaesthetic regimen occurring as a consequence of participation in the study. The surgical depth of anaesthesia at the time of fMRI acquisition was measured and confirmed in each patient using the Bispectral index, a technique unique to this study.

In contrast to a previous peripheral nerve electrostimulation method used to elicit sensorimotor cortical activation in anaesthetised patients (Gasser et al., 2005a, 2005b), the passive finger flexion paradigm performed replicates active finger movement fMRI paradigms which are performed pre-operatively in the work-up of neurosurgical patients. By performing the fMRI twice, firstly with the patients awake immediately prior to the onset of anaesthesia, we demonstrated the robust pattern of activation elicited by this paradigm. The paradigm was readily performed by a trained operator with no reliance on introducing additional specialist equipment into the iMRI environment, facilitating intra-operative implementation in anaesthetised subjects.

In all patients the fMRI activations were in the correct somatotopic region of the sensorimotor cortex with the activation clusters under anaesthesia mostly reduced in extent compared to the awake state. Despite this reduction, all the activation clusters were observed with stringent statistical thresholding. In most cases these activations remained significant after correcting for multiple comparisons across the whole brain ($p < 0.05$), and all were significant after correction for multiple comparisons within the sensorimotor region or when using an uncorrected threshold of $p < 0.001$. In contrast to previous studies (such as Meier et al., 2013), we selected the same arbitrarily high threshold for each patient because the aim was to investigate reproducibility across the patient group. Even though cluster sizes were mostly reduced under anaesthesia these were unlikely to have represented false-positive activation because (a) they were in the expected somatotopic region of the pre-central and post-central gyri and (b) activation was demonstrated in this region when the paradigm was performed with the patients awake using a stringent statistical

threshold of $p < 0.05$ with whole-brain multiple comparison correction.

The magnitudes of the BOLD response under general anaesthesia were 25% (tumour affected hemisphere) and 22% (tumour free hemisphere) of those observed in the awake state. The use of the awake ROI was expected to bias this BOLD measurement towards the awake state, however a reduction in the task-related BOLD response following anaesthesia is in keeping with previous reports in animal (Aksenov et al., 2015) and clinical studies (Dueck et al., 2005; Marcar et al., 2006), as is the reduction in the number of activated voxels (Marcar et al., 2006). Although we were not able to control for the effect of condition order (anaesthesia after awake) upon the BOLD response, a reduction in the magnitude of the task-related BOLD response under anaesthesia was expected because the anaesthetic agents, sevoflurane and propofol, are known to affect cerebral metabolism (Alkire et al., 1995; Schlünzen et al., 2010) through an inhibitory effect on neuronal activation secondary to their action on glutamatergic and GABAergic neurotransmission (Alkire et al., 2008). A reduction in the BOLD response was also predicted by anaesthesia's perturbation of cerebral blood flow (CBF) which has indirectly been shown to modify the BOLD response (Cohen et al., 2002; Sicard et al., 2003). Previous human studies have shown sevoflurane and propofol to both increase (Kolbitsch et al., 2000; Matta et al., 1999) and decrease (Kaisti et al., 2002) global CBF, though at a regional level sevoflurane has been shown to consistently reduce CBF within the fronto-parietal lobes, the location of the sensorimotor cortices, compared to the awake state (Kaisti et al., 2002; Qiu et al., 2008). In these prior studies sevoflurane was administered at concentrations ranging from 0.5% (Qiu et al., 2008) to 4% (Kaisti et al., 2002) with this range including the concentrations of the drug in the current study (range 1.54% to 2.37% (Table 1)). More subtle, localised perturbation of CBF and neurovascular coupling within the sensorimotor cortex may in part, have accounted for the presence of activated voxels under anaesthesia which were not observed in the awake state (for patients A,B,D,E).

Alterations in the BOLD response under anaesthesia could have also related to changes in carbon dioxide levels which have been shown to alter CBF (Cohen et al., 2002; Posse et al., 2001) however as the carbon dioxide levels were controlled at the normal awake physiological range throughout the duration spent under anaesthesia, this is less likely to have been a contributory factor. The reduction in the task-related BOLD

response may have also in part, related to the difference in voluntary motor activity when the patients performed the paradigm awake, though a previous study comparing activation elicited by active and passive finger motor tasks on awake subjects showed that BOLD activation in the passive state was comparable to that achieved in the active state (Blatow et al., 2011).

Concomitant with a reduction in the magnitude of the task-related BOLD response, anaesthesia also reduced BOLD sensitivity, illustrated in Fig. 2, with reduced t-scores observed for all five patients. BOLD sensitivity under anaesthesia intuitively correlated with the ratio of $\frac{\text{BOLD response anaesthesia}}{\text{BOLD response awake}}$. There was no clear relationship however between the BIS values or the sevoflurane concentration and this ratio (Fig. 3). As all patients were anaesthetised with sevoflurane, propofol, fentanyl and a continuous opioid infusion of remifentanyl (except in patient D), it was expected that the BIS measurement would be the best overall measure of the depth of anaesthesia rather than relying solely on the sevoflurane concentration alone or an equivalent measure known as the minimum alveolar concentration (MAC). The MAC value has been used in previous sevoflurane fMRI studies (Kerssens et al., 2005; Marcar et al., 2006) and is known to be affected by propofol and opioid analgesics (Aranake et al., 2013).

Overall, the change in the task-related BOLD response brought about by general anaesthesia is likely to reflect the complex effect that each of the anaesthetic agents sevoflurane and propofol have on neuronal metabolism, CBF and their combined effect. Individual patient differences in sensitivity to anaesthesia relating to age, gender and genetic factors (Kato et al., 1993; Searle and Hopkins, 2009; Vuyk et al., 2001) likely also play contributory factors. The small sample in this study limits further interpretation of the effect of anaesthesia on the BOLD response and any association with the BIS and further larger patient studies using a similar quantification method of the depth of anaesthesia would be required to investigate this further.

Previous studies evaluating the effect of gliomas on the BOLD response have demonstrated reduced task activation in the hemisphere ipsilateral to the tumour using sensorimotor fMRI paradigms (Jiang et al., 2010) even when the tumours were not in direct contact with the sensorimotor cortex (Fujiwara et al., 2004; Wang et al., 2012). In the current study none of the patients' tumours directly displaced the sensorimotor cortex, although three of the five tumours were in the frontal lobe with the tumours in patients B and D (Fig. 1) both within 2.0 cm of the hand region of the primary motor cortex. Tumour volumes (except for patient E) were also comparable to those detailed in these previous fMRI studies. Despite these similarities in patient characteristics, we did not find a significant difference in the task-related BOLD response in either the tumour affected or tumour free hemispheres. In other words, the reduction in the BOLD response resulting from general anaesthesia was not greater in the tumour affected hemisphere compared with the tumour free hemisphere. This has important implications for the intra-operative acquisition of task-related fMRI using this technique in patients with tumours.

4.1. Study limitations

Currently, obtaining access to fMRI in anaesthetised human subjects remains extremely challenging: our study, in common with previous task-related fMRI studies performed under anaesthesia (Dueck et al., 2005; Gasser et al., 2005a), was therefore restricted to a modest sized cohort of five patients. Nevertheless, the reproducibility of sensorimotor activation across a total of ten separate fMRI acquisitions suggest that using this paradigm BOLD activation can be obtained within the neurosurgical environment irrespective of patient demographics, differences in tumour characteristics, neurophysiological changes induced by general anaesthesia and, most importantly, the combined effect of multiple pharmacological dosages. The small sample size limits inferential power regarding the trend to association between anaesthesia and BOLD response changes, although our observations are

consistent with prior literature.

The use of an operator dependent finger flexion paradigm may have resulted in slight differences in the timing and frequency of the movement between each patient's acquisition. To limit this potential variability the same trained clinician performed the finger flexion task in all five patients and our technical set-up ensured the paradigm timings were displayed in the intra-operative MRI operating room. Furthermore, our use of a blocked design paradigm versus an event-related design was predicted to limit any potential impact of slight variation across trials.

5. Conclusion

The acquisition of task-related BOLD fMRI in anaesthetised neurosurgical patients presents unique physiological, technical and clinical challenges. Despite this we demonstrated that without recourse to a study-specific anaesthesia protocol outside of routine practice, during deep unconsciousness elicited by conventional neurosurgical anaesthesia, task-related BOLD responses can be detected reproducibly. Further, this could be achieved using a simple passive sensorimotor paradigm readily implemented in the intra-operative situation. Despite the BOLD response being reduced under anaesthesia, fMRI activations were in the correct somatotopic brain region and judged useful to support clinical management. These results provide foundational evidence supporting the next step in the acquisition of fMRI intra-operatively under the conditions associated with the resection of brain tumours, that is general anaesthesia, craniotomy and exposure of the brain. Quantification of the depth of anaesthesia during fMRI may be of benefit in interpreting the activation data. These methods may also be of additional value outside of the intra-operative environment, for example enabling task-related fMRI in patients not able to perform or tolerate awake active paradigms, such as young children or claustrophobic patients and also in patients with movement disorders.

Declaration of Competing Interest

None.

Acknowledgments

The authors thank Professor Martin Smith (Department of Neuroanaesthesia) for his specialist advice and all of the staff of the intra-operative MRI suite at the National Hospital for Neurology and Neurosurgery, London.

This research was funded by a grant provided by the National Institute for Health Research (NIHR) UCLH/UCL Comprehensive Biomedical Research Centre (Project Award reference 74).

References

- Aksenov, D.P., Li, L., Miller, M.J., Iordanescu, G., Wyrwicz, A.M., 2015. Effects of anaesthesia on BOLD signal and neuronal activity in the somatosensory cortex. *J. Cereb. Blood Flow Metab.* 35, 1819–1826. <https://doi.org/10.1038/jcbfm.2015.130>.
- Alkire, M.T., Haier, R.J., Barker, S.J., Shah, N.K., Wu, J.C., Kao, Y.J., 1995. Cerebral metabolism during propofol anaesthesia in humans studied with positron emission tomography. *Anesthesiology* 82, 393–403. <https://doi.org/10.1097/0000542-199502000-00010>.
- Alkire, M.T., Hudetz, A.G., Tononi, G., 2008. Consciousness and anaesthesia. *Science* 322, 876–880. <https://doi.org/10.1126/science.1149213>.
- Aranake, A., Mashour, G.A., Avidan, M.S., 2013. Minimum alveolar concentration: ongoing relevance and clinical utility. *Anaesthesia* 68, 512–522. <https://doi.org/10.1111/anae.12168>.
- Bisdas, S., Charyasz-Leks, E., Roder, C., Tatagiba, M.S., Ernemann, U., Klose, U., 2016. Evidence of resting-state activity in propofol-anaesthetized patients with intracranial tumors. *Acad. Radiol.* 23, 192–199. <https://doi.org/10.1016/j.acra.2015.10.013>.
- Blatow, M., Reinhardt, J., Riffel, K., Nennig, E., Wengenroth, M., Stippich, C., 2011. Clinical functional MRI of sensorimotor cortex using passive motor and sensory stimulation at 3 tesla. *J. Magn. Reson. Imaging* 34, 429–437. <https://doi.org/10.1002/jmri.22629>.
- Brett, M., Anton, J.L., Valabregue, R., Poline, J.B., 2002. Region of interest analysis using

- an SPM toolbox. In: 8th International Conference on Functional Mapping of the Human Brain, [https://doi.org/10.1016/S1053-8119\(02\)90010-8](https://doi.org/10.1016/S1053-8119(02)90010-8).
- Cohen, E.R., Ugurbil, K., Kim, S.-G., 2002. Effect of basal conditions on the magnitude and dynamics of the blood oxygenation level-dependent fMRI response. *J. Cereb. Blood Flow Metab.* 22, 1042–1053. <https://doi.org/10.1097/00004647-200209000-00002>.
- Dinsmore, J., 2007. Anaesthesia for elective neurosurgery. *Br. J. Anaesth.* 99, 68–74. <https://doi.org/10.1093/bja/aem132>.
- Dueck, M.H., Petzke, F., Gerbershagen, H.J., Paul, M., Hesselmann, V., Girnus, R., Krug, B., Sorger, B., Goebel, R., Lehrke, R., Sturm, V., Boerner, U., 2005. Propofol attenuates responses of the auditory cortex to acoustic stimulation in a dose-dependent manner: a fMRI study. *Acta Anaesthesiol. Scand.* 49, 784–791. <https://doi.org/10.1111/j.1399-6576.2005.00703.x>.
- Frison, K.J., Frith, C.D., Turner, R., Frackowiak, R.S., 1995. Characterizing evoked hemodynamics with fMRI. *Neuroimage* 2, 157–165. <https://doi.org/10.1006/nimg.1995.1018>.
- Fujiwara, N., Sakatani, K., Katayama, Y., Murata, Y., Hoshino, T., Fukaya, C., Yamamoto, T., 2004. Evoked-cerebral blood oxygenation changes in false-negative activations in BOLD contrast functional MRI of patients with brain tumors. *Neuroimage* 21, 1464–1471. <https://doi.org/10.1016/j.neuroimage.2003.10.042>.
- Gan, T., Glass, P., Windsor, A., Payne, F., Rosow, C., Sebel, P., Paul, M., 1997. Bispectral index monitoring allows faster emergence and improved recovery from propofol, alfentanil, and nitrous oxide anesthesia. *Anesthesiology* 87, 808–815. <https://doi.org/10.1097/0000542-199710000-00014>.
- Gasser, T., Ganslandt, O., Sandalcioglu, E., Stolke, D., Fahlbusch, R., Nimsky, C., 2005a. Intraoperative functional MRI: implementation and preliminary experience. *Neuroimage* 26, 685–693. <https://doi.org/10.1016/j.neuroimage.2005.02.022>.
- Gasser, T., Sandalcioglu, E., Schoch, B., Gizewski, E., Forsting, M., Stolke, D., Wiedemayer, H., 2005b. Functional magnetic resonance imaging in anesthetized patients: a relevant step toward real-time intraoperative functional neuroimaging. *Neurosurgery* 57, 94–99. <https://doi.org/10.1227/01.NEU.0000163488.91335.C5>.
- Hill, D.L., Maurer, C.R., Maciunas, R.J., Barwise, J.A., Fitzpatrick, J.M., Wang, M.Y., 1998. Measurement of intraoperative brain surface deformation under a craniotomy. *Neurosurgery* 43, 514–526. <https://doi.org/10.1097/00006123-199809000-00066>.
- Jiang, Z., Krainik, A., David, O., Salon, C., Tropres, I., Hoffmann, D., Pannetier, N., Barbier, E.L., Bombin, E.R., Warnking, J., Pasteris, C., Chabardes, S., Berger, F., Grand, S., Segebarth, C., Gay, E., Le Bas, J.-F., 2010. Impaired fMRI activation in patients with primary brain tumors. *Neuroimage* 52, 538–548. <https://doi.org/10.1016/j.neuroimage.2010.04.194>.
- Kaisti, K.K., Metsähonkala, L., Teräs, M., Oikonen, V., Aalto, S., Jääskeläinen, S., Hinkka, S., Scheinin, H., 2002. Effects of surgical levels of propofol and sevoflurane anesthesia on cerebral blood flow in healthy subjects studied with positron emission tomography. *Anesthesiology* 96, 1358–1370. <https://doi.org/10.1097/0000542-200206000-00015>.
- Katoh, T., Suguro, Y., Ikeda, T., Kazama, T., Ikeda, K., 1993. Influence of age on awakening concentrations of sevoflurane and isoflurane. *Anesth. Analg.* 76, 348–352.
- Kerssens, C., Hamann, S., Peltier, S., Hu, X.P., Byas-Smith, M.G., Sebel, P.S., 2005. Attenuated brain response to auditory word stimulation with sevoflurane: a functional magnetic resonance imaging study in humans. *Anesthesiology* 103, 11–19. <https://doi.org/10.1097/0000542-200507000-00006>.
- Kolbitsch, C., Lorenz, I.H., Hörmann, C., Schocke, M., Kremser, C., Zschiegner, F., Löckinger, A., Pfeiffer, K.P., Felber, S., Benzer, A., 2000. A subanesthetic concentration of sevoflurane increases regional cerebral blood flow and regional cerebral blood volume and decreases regional mean transit time and regional cerebrovascular resistance in volunteers. *Anesth. Analg.* 91, 156–162. <https://doi.org/10.1213/0000539-200007000-00029>.
- Magerkurth, J., Mancini, L., Penny, W., Flandin, G., Ashburner, J., Micallef, C., De Vita, E., Daga, P., White, M.J., Buckley, C., Yamamoto, A.K., Ourselin, S., Yousry, T., Thornton, J.S., Weiskopf, N., 2015. Objective Bayesian fMRI analysis—a pilot study in different clinical environments. *Front. Neurosci.* 9, 1–17. <https://doi.org/10.3389/fnins.2015.00168>.
- Marcas, V.L., Schwarz, U., Martin, E., Loenneker, T., 2006. How depth of anesthesia influences the blood oxygenation level-dependent signal from the visual cortex of children. *Am. J. Neuroradiol.* 27, 799–805.
- Matta, B.F., Heath, K.J., Tipping, K., Summers, A.C., 1999. Direct cerebral vasodilatory effects of sevoflurane and isoflurane. *Anesthesiology* 91, 677–680. <https://doi.org/10.1097/0000542-199909000-00019>.
- Meier, M.P., Ilmberger, J., Fesl, G., Ruge, M.I., 2013. Validation of functional motor and language MRI with direct cortical stimulation. *Acta Neurochir.* 155, 675–683. <https://doi.org/10.1007/s00701-013-1624-1>.
- Myles, P.S., Leslie, K., McNeil, J., Forbes, A., Chan, M.T.V., 2004. Bispectral index monitoring to prevent awareness during anaesthesia: the B-aware randomised controlled trial. *Lancet* 363, 1757–1763. [https://doi.org/10.1016/S0140-6736\(04\)16300-9](https://doi.org/10.1016/S0140-6736(04)16300-9).
- Nimsky, C., 2011. Intraoperative acquisition of fMRI and DTI. *Neurosurg. Clin. N. Am.* 22, 269–277. ix. <https://doi.org/10.1016/j.nec.2010.11.005>.
- Nimsky, C., Ganslandt, O., Cerny, S., Hastreiter, P., Greiner, G., Fahlbusch, R., 2000. Quantification of, visualization of, and compensation for brain shift using intraoperative magnetic resonance imaging. *Neurosurgery* 47, 1070–1079. <https://doi.org/10.1097/00006123-200011000-00008>.
- Ogawa, S., Lee, T.M., Nayak, A.S., Glynn, P., 1990a. Oxygenation-sensitive contrast in magnetic resonance image of rodent brain at high magnetic fields. *Magn. Reson. Med.* 14, 68–78. <https://doi.org/10.1002/mrm.1910140108>.
- Ogawa, S., Lee, T.M., Kay, A.R., Tank, D.W., 1990b. Brain magnetic resonance imaging with contrast dependent on blood oxygenation. *Proc. Natl. Acad. Sci. U. S. A.* 87, 9868–9872. <https://doi.org/10.1073/pnas.87.24.9868>.
- Posse, S., Kemna, L.J., Elghahwagi, B., Wiese, S., Kiselev, V.G., 2001. Effect of graded hypo- and hypercapnia on fMRI contrast in visual cortex: quantification of T2* changes by multiecho EPI. *Magn. Reson. Med.* 46, 264–271. <https://doi.org/10.1002/mrm.1187>.
- Qiu, M., Ramani, R., Swetye, M., Constable, R.T., 2008. Spatial nonuniformity of the resting CBF and BOLD responses to sevoflurane: in vivo study of normal human subjects with magnetic resonance imaging. *Hum. Brain Mapp.* 29, 1390–1399. <https://doi.org/10.1002/hbm.20472>.
- Qiu, T., Gong, F., Gong, X., Wu, J., Lin, C., Biswal, B.B., Zhuang, D., Yao, C., Zhang, X., Lu, J., Zhu, F., Mao, Y., Zhou, L., 2017. Real-time motor cortex mapping for the safe resection of glioma: an intraoperative resting-state fMRI study. *Am. J. Neuroradiol.* 38, 2146–2152. <https://doi.org/10.3174/ajnr.A5369>.
- Ravussin, P., Wilder-Smith, O., 2001. General anaesthesia for supratentorial neurosurgery. *CNS Drugs* 15, 527–535. <https://doi.org/10.2165/00023210-200115070-00003>.
- Roder, C., Charyasz-Leks, E., Breitkopf, M., Decker, K., Ernemann, U., Klose, U., Tatagiba, M., Bisdas, S., 2016. Resting-state functional MRI in an intraoperative MRI setting: proof of feasibility and correlation to clinical outcome of patients. *J. Neurosurg.* 125, 401–409. <https://doi.org/10.3171/2015.7.JNS15617>.
- Schlünzen, L., Juul, N., Hansen, K.V., Gjedde, A., Cold, G.E., 2010. Regional cerebral glucose metabolism during sevoflurane anaesthesia in healthy subjects studied with positron emission tomography. *Acta Anaesthesiol. Scand.* 54, 603–609. <https://doi.org/10.1111/j.1399-6576.2010.02208>.
- Searle, R., Hopkins, P.M., 2009. Pharmacogenomic variability and anaesthesia. *Br. J. Anaesth.* 103, 14–25. <https://doi.org/10.1093/bja/aep130>.
- Sicard, K., Shen, Q., Brevard, M.E., Sullivan, R., Ferris, C.F., King, J.A., Duong, T.Q., 2003. Regional cerebral blood flow and BOLD responses in conscious and anesthetized rats under basal and hypercapnic conditions: implications for functional MRI studies. *J. Cereb. Blood Flow Metab.* 23, 472–481. <https://doi.org/10.1097/01.WCB.0000054755.93668.20>.
- Todd, N., Josephs, O., Callaghan, M.F., Lutti, A., Weiskopf, N., 2015. Prospective motion correction of 3D echo-planar imaging data for functional MRI using optical tracking. *Neuroimage* 113, 1–12. <https://doi.org/10.1016/j.neuroimage.2015.03.013>.
- Tzourio-Mazoyer, N., Landeau, B., Papathanassiou, D., Crivello, F., Etard, O., Delcroix, N., Mazoyer, B., Joliot, M., 2002. Automated anatomical labeling of activations in SPM using a macroscopic anatomical parcellation of the MNI MRI single-subject brain. *Neuroimage* 15, 273–289. <https://doi.org/10.1006/nimg.2001.0978>.
- Vuyk, J., Oostwouder, C.J., Vletter, A.A., Burm, A.G., Bovill, J.G., 2001. Gender differences in the pharmacokinetics of propofol in elderly patients during and after continuous infusion. *Br. J. Anaesth.* 86, 183–188. <https://doi.org/10.1093/bja/86.2.183>.
- Wang, L., Chen, D., Olson, J., Ali, S., Fan, T., Mao, H., 2012. Re-examine tumor-induced alterations in hemodynamic responses of BOLD fMRI: implications in presurgical brain mapping. *Acta Radiol.* 53, 802–811. <https://doi.org/10.1258/ar.2012.120118>.
- White, M.J., Thornton, J.S., Hawkes, D.J., Hill, D.L.G., Kitchen, N., Mancini, L., McEvoy, A.W., Razavi, R., Wilson, S., Yousry, T., Keevil, S.F., 2015. Design, operation, and safety of single-room interventional MRI suites: practical experience from two centers. *J. Magn. Reson. Imaging* 41, 34–43. <https://doi.org/10.1002/jmri.24577>.
- Yousry, T.A., Schmid, U.D., Alkadhi, H., Schmidt, D., Peraud, A., Buettner, A., Winkler, P., 1997. Localization of the motor hand area to a knob on the precentral gyrus. A new landmark. *Brain* 120, 141–157. <https://doi.org/10.1093/brain/120.1.141>.
- Yushkevich, P.A., Piven, J., Hazlett, H.C., Smith, R.G., Ho, S., Gee, J.C., Gerig, G., 2006. User-guided 3D active contour segmentation of anatomical structures: significantly improved efficiency and reliability. *Neuroimage* 31, 1116–1128. <https://doi.org/10.1016/j.neuroimage.2006.01.015>.